00109544

THE
ASIATIC SOCIETY OF BOMBAY
TOWN HALL, BOMBAY–400 023.

Digitized with financial assistance from the
Observer Research Foundation
on 25 April, 2019

AN

ATLAS OF ILLUSTRATIONS

OF

PATHOLOGY

(FASCICULI I.–XII.)

ISSUED BY

109544
ac

THE NEW SYDENHAM SOCIETY

1877 TO 1898.

LIBRARY OF THE BOMBAY BRANCH OF THE ROYAL ASIATIC S

TB. d 34

00109544

ATLAS OF PATHOLOGY.

FASCICULI I.—XII.

INDEX.

ATLAS OF ILLUSTRATIONS OF PATHOLOGY.

CONTENTS AND INDEX.

NOTE.—These Fasciculi having been paged independently of each other, the Index to the letterpress becomes somewhat complicated. It is hoped, however, that the accompanying table of contents of the Fasciculi (with the number of pages of letterpress which each contains inserted in parentheses) may assist the reader in finding any page he may require. The Index gives the number of the Fasciculus as well as that of the page.

The only abbreviations made use of in the Index are: Fasc. for Fasciculus; Pl. for Plate; Fig. for Figure; and p. for page.

By mistake in the printing, Plates L. to LXIV. in the Atlas have been numbered I. to XV. Therefore, to avoid mistake, in the Index they are referred to by their correct numbers (L. to LXIV.), the numbers printed in the Atlas (I. to XV.) being put after these in brackets.

FASCICULUS I. (8 pp.)

DISEASES OF THE KIDNEY.

Plate i. Scrofula. Syphilis. Lymph-Adenoma.
,, ii. Nephritis after Diphtheria, Scarlet Fever, Burns.
,, iii. The Granular Kidney in Different Stages.
,, iv. Embolism. Infarction Processes from Pyæmia, Jaundice and Purpura. Scrofula.

FASCICULUS II. (53 pp.)

DISEASES OF THE KIDNEY, SUPRA-RENAL CAPSULES, AND SPLEEN.

Plate v. Amyloid Disease and Cancer of Kidney.
,, vi. Various Diseased Conditions of the Spleen.
,, vii. Diseases of Supra-Renal Capsules and Spleen.
,, viii. Microscopic Pathology of Kidneys.
,, ix. Microscopic Pathology of Kidney and Spleen.
,, x. Microscopic Pathology of Spleen and Supra-Renals.

FASCICULUS III. (8 pp.)

DISEASES OF THE LIVER.

Plate xi. Lymph-Adenoma of Liver.
Plates xii.–xvi. Various Diseased Conditions of Liver.

FASCICULUS IV. (52 pp.)

[D]ISEASES OF THE LIVER, WITH ONE FIGURE OF SPLEEN.

[P]lates xvii., xviii., xix. Diseases of Liver and Spleen.
[P]lates xxi., [x]xii. Microscopic Pathol[o]gy.

FASCICULUS V. (6 pp.)

DISEASES OF THE LIVER.

Plate xxiii. Syphilitic and Lardaceous Disease of Liver.
Plates xxiv., xxv., xxvi. Diseases of Liver.

FASCICULUS VI. (29 pp.)

Plate xxvii. Hydatid Cysts of the Liver.
Plates xxviii.–xxxi. Urinary Calculi.

FASCICULUS VII.

(No letterpress except Plate descriptions.)

Plate xxxii. Urinary Calculi and Gall Stones.
,, xxxiii. Enlargement of the Prostate Gland.
,, xxxiv. Enlargement of Prostate. Urinary Calculi.
,, xxxv. Osteitis Deformans (Paget's Disease).

FASCICULUS VIII.

(No letterpress except Plate descriptions.)

DISEASES OF BRAIN AND SPINAL CORD.

Plates xxxvi.–xli.

FASCICULI IX. AND X. (31 pp.)

DISEASES OF THE TESTIS.

Plates xlii.–xlix.

FASCICULUS XI. (38 pp.)

THE PATHOLOGY, DIAGNOSIS, AND TREATMENT OF NEUROMA.

Plates l.–lxiv.

FASCICULUS XII. (3 pp.)

INFECTIVE DISEASE OF THE LYMPHATIC SYSTEM.

Plates lxv.–lxviii. Lymph-Adenoma, or Hodgkin's Malady.

INDEX.

A.

Abscess on under surface of Right Cerebellar Hemisphere. Pl. xxxvi. Fig. 2.
Abscesses in Liver. Pl. xxiv. Fig. 1.
Accretions on Foreign Bodies. Fasc. VI. p. 25.
Acute Catarrhal Nephritis. Pl. viii. Fig. 15.
Acute Splenic Enlargement in Diphtheria. Pl. vi. Fig. 2.
Acute Yellow Atrophy of Liver. Pl. xx. Fig. 12.
Addison's Disease of Supra-Renal Capsule. Pl. vii. Figs. 5, 6.
Addison's Disease, Section of Supra-Renal Capsules. Pl. x. Figs. 14, 15.
Addison's Disease. (Tuberculous Disease of Supra-Renal Capsules.) Fasc. II. p. 30.
Adenoma of Liver, Primary. Pl. xxii. Figs. 17, 19.
Adenoma of Supra-Renal Capsule. Pl. vii. Figs. 2, 3 and 4. Pl. ix. Fig. 28.
Adenoma and Primary Cancer of Liver. Fasc. IV. p. 43.
Albuminous Nephritis. *See* Nephritis.
Alcoholic Poisoning, Fatty Degeneration of Kidney from. Pl. ix. Fig. 12.
Amyloid Disease of Kidney in Advanced Stage. Pl. v. Figs. 1, 2.
Artery of Spleen in Longitudinal Section; Hyaline Degeneration (Early Scarlatina). Pl. iv. Fig. 19.
Atrophy, Extreme, of One Testis and Epididymis. Pl. xliv. Fig. 2.
Atrophy of Right Optic Nerve and Left Optic Tract, in case where right eye had been destroyed by Small-pox. Pl. lxiv. Fig. 14. [Fasc. XI. Pl. xv.]
Atrophy of Liver. Fasc. IV. p. 12.
Atrophy of Testis. Fasc. X. p. 30.

B.

Bile-Ducts, Cancer of. Pl. xxi. Figs. 9 and 10.
Bone Bodkin-case removed from Bladder. Pl. xxxii. Fig. 1.
Brachial Plexus, showing remarkable fusiform enlargements of roots of median nerve. Pl. lxii. Fig. 10. [Fasc. XI. Pl. xiii.]
Brain, Diseases of. Pls. xxxvi. and xxxvii.
Bright's Disease. Fasc. II. pp. 1 and 21.
Brown Atrophy of Liver. Pl. xvii. Fig. 2. Pl. xxii. Fig. 8.

C.

Calcareous and Cartilaginous Bodies, formed in visceral Layer of Tunica Vaginalis and on Globus Major of Epididymis. Pl. xlii. Fig. 5.
Calcareous Plate in Tunica Vaginalis. Pl. xlii. Fig. 4.
Calculi, Alternation of Layers in. Fasc. VI. p. 12.
Calculi and Cysts in Kidney. Pl. xxxiv. Fig. 4.
Calculi, Carbonate of Lime. Pl. xxxi. Figs. 6, 7, 8, 9 and 10.
Calculi, Composition of. Fasc. VI. p. 2 *et seq.*
Calculi, Earthy Phosphate. Pl. xxx. Figs. 10, 11 and 12.
Calculi, Impaction of, by Ureters. Pl. xxxiv. Fig. 2.
Calculi, Mixed. Fasc. VI. p. 14.
Calculi, Nuclei of. Fasc. VI. p. 14.
Calculi of Unusual Size. Fasc. VI. p. 25.
Calculi, Ordinary "Hemp-seed." Pl. xxx. Fig. 9.
Calculi, Ordinary Phosphate of Lime. Pl. xxx. Fig. 8.
Calculi, Oxalate and the "Phosphatic Diathesis." Fasc. VI. p. 3 *et seq.*
Calculi, Layer of Urate of Ammonia and Uric Acid. Pl. xxx. Figs. 1, 2.
Calculi, Urinary. Fasc. VI. Pls. xxviii. to xxxii.; Pl. xxxiv.
Calculi, Urinary, Bibliography. Fasc. VI. p. 29.
Calculous Concretion formed on piece of straw. Pl. xxiii. Fig. 4.
Calculus, chiefly of Oxalate of Lime, having nucleus of impure Urate of Ammonia. Pl. xxix. Fig. 3.
Calculus, composed of Uric Acid and Urate of Ammonia. Pl. xxviii. Figs. 4, 5.
Calculus, Cystic Oxide, Exterior and Section of. Pl. xxix. Figs. 5 and 6.
Calculus, Cystine (Cystic Acid). Fasc. VI. pp. 4 and 10.
Calculus, external surface of which had undergone partial solution in bladder. Pl. xxxi. Fig. 13; Fig. 14 section of same.
Calculus. Inner tuberculated part and outer layer are nearly pure Oxalate of Lime. Pl. xxxi. Figs. 1 and 2.
Calculus, Large, removed by two forefingers from bladder of woman. Pl. xxxiv. Fig. 7.
Calculus, mainly Uric Acid and Urate of Ammonia, deposited on piece of steel. Pl. xxix. Figs. 7 and 8.
Calculus, Oxalate of Lime. Fasc. VI. p. 3.
Calculus, Oxalate of Lime, white crystalline variety of. Pl. xxxi. Figs. 4 and 5.
Calculus, Phosphate of Lime. Fasc. VI. p. 4.
Calculus, Section of, Centre consisting of Uric Acid, &c. Pl. xxix. Fig. 4.
Calculus, Section of, consisting of Urate of Ammonia with Urate of Lime. Pl. xxx. Fig. 4.
Calculus, Section of, consisting of Urate of Ammonia surrounded by Phosphates. Pl. xxx. Figs. 5, 6 and 7.
Calculus, Section of large, composed of three distinct Uric Acid stones. Pl. xxix. Fig. 3.
Calculus, showing thin layer of Uric Acid deposited on mass of Oxalate of Lime. Pl. xxxi. Fig. 3.
Calculus, consisting of nucleus of Urate of Ammonia surrounded by Oxalate of Lime with intervening layers of Phosphates. Pl. xxxi. Fig. 12.
Calculus, Triple Phosphate. Fasc. VI. p. 5.
Calculus, Uratic. Fasc. VI. p. 3.
Calculus, Uric Acid. Pl. xxviii. Figs. 1 to 7; Fasc. VI. p. 2.
Calculus, Uric Acid, Central portion and one of fragments of. Pl. xxxi. Fig. 11.
Calculus, Uric Acid, from Kidney, Section of. Pl. [illegible] Figs. 1, 2.
Calculus, Uric Acid, Pisiform. Pl. xxix. Fig. [illegible]
Calculus, Uric Acid, Section and Exte[illegible] Figs. 10 and 11.
Calculus, Uric Oxide. Fasc. VI. p. [illegible]
Calculus, very large, voided with[illegible] Fig. 6.
Calculus, voided by woman [illegible]
Calculus, Xanthine (Xan[illegible]
Cancer, Fatty Degener[illegible] 13, 14.
Cancer of Bile-Duct[illegible]
Cancer of Gall-B[illegible] Obstruction [illegible]
Cancer of Liver [illegible]
Cancer of Live[illegible]
Cancer of L[illegible] Fig. [illegible]
Cance[illegible]

Caseous Disease of Supra-Renal Capsules. (Synonym for Addison's Disease, *q. v.*)
Casts in Tubes in Interstitial Nephritis (post-scarlatinal). Pl. viii. Fig. 19.
Cavernous Tumour in Liver. Pl. xx. Figs. 11 and 18.
Canda Equina, Fibrous Tumour in. Pl. xli. Fig. 2.
Cell-Vacuolation and Proliferation, Varieties of, illustrating Stages of Cancer in Liver. Pl. xxii. Figs. 14, 15, 16.
Cerebellar Hemisphere, Right, Abscess on under surface of. Pl. xxxvi. Fig. 2.
Cerebellar Hemispheres, Tubercles on, &c. Pl. xxxvii. Fig. 2.
Chronic Parenchymatous Nephritis. Pl. ix. Fig. 8.
Cirrhosis of Liver. Pl. xvii. Fig. 3. Pl. xviii. Figs. 2 and 4. Pl. xx. Figs. 4, 5 and 6. Pl. xxi. Figs. 1 and 2. Pl. xxii. Fig. 2.
Cirrhosis of Liver, resembling Nutmeg Liver. Pl. xvii. Fig. 1.
Cirrhosis of Liver, Early. Pl. xx. Figs. 3 and 14.
Colloid Cast in Interstitial Nephritis. Pl. viii. Fig. 20.
Colloid Degeneration of Kidney. Pl. ix. Fig. 17.
Columnar Epithelioma of Liver. Pl. xx. Fig. 16.
Common "Cirrhosis of Liver (="Multilobular" Cirrhosis). Pl. xxi. Fig. 13.
Contracting Scirrhus of Liver, simulating Cirrhosis. Pl. xxii. Figs. 11, 12 and 13.
Cyst in Kidney, near Base of Pyramid (containing Oxalate of Lime Crystals and Leucine). Pl. ix. Fig. 16.
Cyst, Multilocular, developed between Tunica Vaginalis and Tunica Albuginea Testis. Pl. xlii. Fig. 6.
Cyst, Serous, developed among branches of the Median Nerve distributed to thumb. Pl. lxii. Fig. 7. [Fasc. XI. Pl. xiii.]
Cystic Degeneration of Kidney. Pl. ix. Fig. 15.
Cystic Chondro-Sarcoma of Testis. Pl. xlvi. Fig. 2.
Cystic Disease of Liver. Pl. xix.
Cystic Disease of Testis. Fasc. X. p. 25.
Cystic Disease (? Sarcoma) of Testis. Pl. xliv. Fig. 3.
Cystic Liver. Pl. xxii. Figs. 4 and 5.
Cystic Oxide Calculus, Exterior and Section of. Pl. xxix. Figs. 5 and 6.
Cysts of Liver. Fasc. IV. p. 47.

D.

Dilatation of Bile-Ducts in Liver (from pressure of Gall-Stone). Pl. xii. Fig. 1.
Diphtheria, Acute Splenic Enlargement in. Pl. vi. Fig. 2.
Disseminated Growths of Fibrous Nature in Liver. Pl. xx. Fig. 9.
Dura Mater, Spinal, Tuberculous Tumour on. Pl. xxxix. Figs. 1, 2 and 3.

E.

Embolic Changes in Spleen in Pyæmia. Pl. vi. Fig. 4.
Embolism in Kidney. Pl. iv.
Endocarditis, Ulcerative, Suppurating Infarction of Spleen from case of. Pl. vi. Fig. 3.
[illegible]mis, Globus Major of, Pedunculated Cartilaginous [illegible] attached to. Pl. xlii. Fig. 3.
[illegible]ydrocele of. Fasc. X. p. 3.
[illegible]rocele of. Pl. xlii. Fig. 2.

F.

[illegible] from Alcoholic Poisoning.

[illegible] Cancer. Pl. ix. Figs.

[illegible]. Fig. 9.

[illegible]ohæmus. Pl. xviii.

[illegible]s in Chron[illegible]
[illegible]nd 10.
[illegible]e.

Gall-Stone, Large, voided by woman upwards of 80. Pl. xxxii. Fig. 14.
Gall-Stones, causing Perforation of Ilium. Pl. xxxii. Figs. 15, 16 and 17.
Gall-Stones, Series of, passed per Anum. Pl. xxxii. Figs. 5, 6, 7, 8, 9, 10, 11, 12.
Glomerulus of Kidney, Multiplication of Nuclei on. Pl. viii. Fig. 11.
Goitre, Supra-Renal. Fasc. II. p. 53.
Granular Contracted Kidney; Swelling of inner coat of small artery. Pl. ix. Fig. 10.
Granular Contracted Kidney. Pl. viii. Figs. 7 and 8.
Gumma, Breaking Down, in Testis. Pl. xlv. Fig. 1.
Gummis of Testis, due to inherited Syphilis. Pl. xlv. Fig. 2.
Gumma of Testis, with Hydrocele. Pl. xlvi. Fig. 3.
Gumma (Syphilitic) in Kidney. Pl. I. Fig. 4.
Gummatous Deposit in Testis and Epididymis, from Acquired Syphilis. Pl. xlv. Fig. 5.
Gummatous Disease of Testis and Lung. Pl. xlv. Figs. 3 and 4.
Gummatous Disease of Testis, with great enlargement of organ. Pl. xlv. Fig. 6.
Gummatous Infiltration of Liver, Early. Pl. xxi. Fig. 12.

H.

Hæmatocele of Testis. Fasc. X. p. 29.
Hæmorrhage into Right Hemisphere and Median Lobe of Cerebellum. Pl. xxxvii. Fig. 1.
Hæmorrhage into Spinal Canal, External to Vertebral Theca. Pl. xxxviii. Fig. 3.
Hæmorrhagic Sarcoma of Testicle. Pl. xlviii. Fig. 3.
Hemisphere, Right, and Median Lobe of Cerebellum, Hæmorrhage into. Pl. xxxvii. Fig. 1.
Hepatic Abscess. Fasc. IV. p. 39.
Hepatitis, Syphilitic. Fasc. IV. p. 38.
Hodgkin's Disease. Fasc. XII. *See Sub-headings.*
Hodgkin's Disease (Lymph-Adenoma), Kidney in. Pl. i. Fig. 5.
Hodgkin's Disease of Spleen (Lympho-Sarcoma). Pl. vi. Fig. 1.
Hodgkin's Disease, Section of Spleen in. Pl. ix. Fig. 22.
Hodgkin's Disease, Spleen in Case of. Pl. x. Fig. 8.
Hyaline Changes in Splenic Arteries in Certain Febrile Conditions. Pl. ix. Figs. 18, 19, 20 and 21.
Hyaline Degeneration of Artery of Spleen (Longitudinal Section). Pl. ix. Fig. 19.
Hydatid Disease of Liver. Pl. xxvii. and Fasc. IV. p. 48.
Hydatid in Posterior Cornu of Right Lateral Ventricle. Pl. xxxvi. Fig. 1.
Hydrocele, Common, of Tunica Vaginalis. Pl. xliii. Fig. 1.
Hydrocele of Cord. Fasc. X. p. 1.
Hydrocele of Epididymis. Fasc. X. p. 3.
Hydrocele of Epididymis. Pl. xlii. Fig. 2.
Hydrocele of Spermatic Cord. Pl. xlii. Fig. 1.
Hydrocele of Tunica Albuginea Testis. Pl. xlviii. Fig. 1.
Hydrocele of Tunica Vaginalis. Fasc. X. p. 4.
Hydrocele of Upper Part of Tunica Vaginalis. Pl. xlii. Fig. 7.
Hypertrophy of Cervical Ganglia of Sympathetic Nerve. Pl. lxiv. Fig. 4. [Fasc. XI. Pl. xv.]
Hypertrophy of Liver. Fasc. IV. p. 11.

I.

Idiopathic Anæmia, Specimen of Liver in. Pl. xxi. Figs. 8 and 15.
Ilium, Perforation of, by Gall-Stones. Pl. xxxii. Figs. 15, 16 and 17.
Induration and Atrophy of Spleen. Pl. x. Fig. 11.
Infarction Processes from Pyæmia in Kidney. Pl. iv.
Infective Disease of Lymphatic System (Hodgkin's Disease); iliac fossa and upper part of thigh dissected. Pl. lxvi. Figs. 1, 2, 3, 4 and 5.
Infective Disease of Lymphatic System; neck and armpit dissected. (Hodgkin's Disease.) Pl. lxv.
[illegible]ective Disease of Lymphatic System; section through [illegible]iver. (Hodgkin's Disease.) Pl. lxvi[illegible] 1 and 2.
[illegible]ve Disease of Lymphatic Syste[illegible]
[illegible]ction. (Hodgkin's Disease.)

Injuries to Spinal Column attended by Contusion of Cord. Pl. xxxviii. Figs. 1, 2 and 3.

J.

Jaundice and Purpura, Kidney in. Pl. iv.

K.

Kidney, Amyloid Disease of, in advanced stage. Pl. v. Figs. 1 and 2.
Kidney and Ureter, Scrofulous Disease of. Pl. i. Fig. 1.
Kidney, Colloid Degeneration of. Pl. ix. Fig. 17.
Kidney, Cyst in, near base of pyramid. Pl. ix. Fig. 16.
Kidney, Cystic Degeneration of. Pl. ix. Fig. 15.
Kidney, Degenerations of. Fasc. II. p. 15.
Kidney, Diseases of. Fasc. I., II. Pls. i. to v. Pls. viii. and ix.
Kidney, Diseases of, Classification of. Fasc. II. p. 14.
Kidney, Elementary Lesions of. Fasc. II. p. 3.
Kidney, Embolic Changes in, in Pyæmia. Pl. iv. Figs. 1 and 2.
Kidney, Embolism in. Pl. iv.
Kidney, Fatty. Fasc. II. p. 4.
Kidney, Fatty Degeneration of, from alcoholic poisoning. Pl. ix. Fig. 12.
Kidney, Fatty Degeneration of, in Cancer. Pl. ix. Figs. 13 and 14.
Kidney, Granular. Pl. iii. Figs. 1 and 2, extremely granular; Fig. 3, less granular (contracted); Fig. 4, granular (of Bright); Figs. 5 and 6, granular (contracted); Fig. 7, granular (large); Fig. 8, granular (large, with cysts).
Kidney, Granular Contracted. Fasc. II. p. 1.
Kidney, Granular Contracted. Pl. viii. Figs. 7 and 8.
Kidney, Granular Contracted; swelling of inner coat of small artery. Pl. ix. Fig. 10.
Kidney, Gumma in. Pl. i. Fig. 4.
Kidney in Hodgkin's Disease. Pl. i. Fig. 5.
Kidney in Jaundice and Purpura. Pl. iv.
Kidney in Leucocythæmia. Pl. ix. Fig. 9.
Kidney, Infarction Processes in, from Pyæmia. Pl. iv. Figs. 1, 2, 3 and 4.
Kidney, Infiltrations and Morbid Growths of. Fasc. II. p. 29.
Kidney, Lardaceous Degeneration of. Pl. viii. Figs. 1 to 6.
Kidney, Large, White, Smooth. Fasc. II. p. 1.
Kidney, Lymph-Adenoma of. Pl. i. Fig. 5.
Kidney, Medullary Cancer of. Pl. v. Fig. 5.
Kidney, Mottled. Fasc. II. p. 1.
Kidney, Pale Flabby. Pl. v. Figs. 3 and 4.
Kidney, Pyæmic Deposits in. Pl. iv. Figs. 3 and 4.
Kidney, Results of Jaundice and Purpura on. Pl. iv. Fig. 5.
Kidney, Scrofulous Disease of. Pl. i. Figs. 2 and 3.
Kidney, showing numerous Calculi, and Cysts caused by their lodgment. Pl. xxxiv. Fig. 4.
Kidney, Structure of. Fasc. II. p. 2.
Kidney, Syphilitic Deposit in Cortical Substance of. Pl. i. Fig. 4.

L.

Lardaceous Degeneration of Kidney. Pl. viii. Figs. 1 to 6.
Lardaceous Degeneration of Supra-Renal Capsules. Fasc. II. p. 50.
Lardaceous Disease of Liver. Pl. xx. Figs. 1 and 10; also Fasc. IV. p. 28.
Lardaceous Liver. Pl. xv. Figs. 1 and 2.
Lardaceous Spleen. Pl. vii. Fig. 9. Pl. x. Figs. 12 and 13.
Lateral Ventricle, Right, Hydatid in Posterior Cornu of. Pl. xvi. Fig. 1.
[illegible]æmia, Kidney in. Pl. ix. Fig. 9.
[illegible]ic Spleen. Pl. x. Figs. 6 and 7.
[illegible]. Pl. xxii. Fig. 18.
[illegible] in. Fasc. IV. p. 20. Pl. xxiv. Fig. 1.
[illegible]w and Red Atrophy of. Pl. xiv. Figs.
[illegible] Atrophy of. Fasc. IV. p. 14; [illegible]
[illegible]nd Pl. xx. Fig. 12.
[illegible] Primary Cancer of. Fasc. [illegible]
[illegible] Primary. Pl. xxii. Figs. [illegible]
Liver and its Capsule, Diseases of. Fasc. IV. p. 11 *et seq.*
Liver, Atrophy of. Fasc. IV. p. 12.
Liver, Brown Atrophy of. Pl. xvii. Fig. 2; Pl. xxii. Fig. 8.
Liver, Cancer of. Pl. xii. Fig. 2; Pl. xvi. Fig. 1.
Liver, Cancer of, Cell-Vacuolation and Proliferation in. Pl. xxii. Figs. 14, 15 and 16.
Liver, Cancer of, Early. Pl. xxii. Fig. 6.
Liver, Cancer of, spreading from Biliary Ducts. Pl. xxi. Fig. 11.
Liver, Carcinoma of. Pl. xii. Fig. 2.
Liver, Cavernous Tumour in. Pl. xx. Figs. 11 and 13.
Liver, Cells of, Morbid Changes in. Fasc. IV. pp. 5–11.
Liver, Changes in, in Phosphorus Poisoning. Fasc. IV. p. 20; p. 52 (Appendix).
Liver, Cirrhosis of. Pl. xiii.; Pl. xvii. Fig. 3; Pl. xviii. Figs. 2 and 4; Pl. xx. Fig. 3, 4, 5, 6 and 14; Pl. xxi. Figs. 1, 2, 3 and 13; Pl. xxii. Figs. 1 and 2.
Liver, Cirrhosis of, resembling Nutmeg Liver. Pl. xvii. Fig. 1.
Liver, Columnar Epithelioma of. Pl. xx. Fig. 15.
Liver, "Common" Cirrhosis of. Pl. xxi. Fig. 13.
Liver containing several Hydatid Cysts, Part of. Pl. xxvii.
Liver, Contracting Scirrhus of, simulating Cirrhosis. Pl. xxii. Figs. 11, 12 and 13.
Liver, Cysts of. Fasc. IV. p. 47.
Liver, Cystic. Pl. xxii. Figs. 4 and 5.
Liver, Cystic Disease of. Pl. xix.
Liver, Dilatation of Bile-Ducts (from pressure of Gall-Stone). Pl. xii. Fig. 1.
Liver, Diseases of. Fasc. III.–VI. Pls. xi. to xxvii.
Liver, Diseases of, due to Circulatory Disturbance. Fasc. IV. p. 25.
Liver, Diseases of, Résumé of our present knowledge of Pathology of. (By James F. Goodhart, M.D.) Fasc. IV. pp. 1 to 52.
Liver, Disseminated Fibrous Growths in. Pl. xx. Fig. 9.
Liver, Fatty. Fasc. IV. p. 22; Pl. xx. Fig. 2.
Liver, Fatty, from Poisoning by Phosphorus. Pl. xviii. Fig. 1.
Liver, Gummatous Infiltration of, Early. Pl. xxi. Fig. 12.
Liver, Hydatid Disease of. Fasc. IV. p. 48; Pl. xxvii.
Liver, Hypertrophy of. Fasc. IV. p. 11.
Liver in Idiopathic Anæmia. Pl. xxi. Figs. 8 and 15.
Liver in Lymphadenoma. Pl. xi.
Liver, Inflammatory Diseases of. Fasc. IV. p. 26.
Liver, Injuries to. Fasc. IV. p. 49.
Liver, Lardaceous. Pl. xv. Figs. 1 and 2.
Liver, Lardaceous Disease of. Fasc. IV. p. 23; Pl. xv. Figs. 1 and 2; Pl. xx. Figs. 1 and 10.
Liver, Leukæmic. Pl. xxii. Fig. 18.
Liver, Lymphadenoma of. Pl. xi.
Liver, Lymphatic Tumours of. Fasc. IV. p. 45.
Liver, Malformations of. Fasc. IV. p. 49.
Liver, Miliary Gummata of. Pl. xxi. Fig. 7.
Liver, Monolobular Cirrhosis of. Pl. xvi. Fig. 3.
Liver, Morbid Histology of. Fasc. IV. pp. 5 to 11.
Liver, Myxodematous. Pl. xxii. Fig. 10.
Liver, New Growths of. Fasc. IV. p. 40.
Liver, Normal Structure of. Fasc. IV. pp. 1 to 5.
Liver, Nutmeg. Fasc. IV. p. 25; Pl. xvi. Pl. xxi. Figs. 4 and 6; Pl. xxii. Fig. 3.
Liver, "Pericellular" Cirrhosis of. Pl. [illegible]
Liver, Pigmented. Fasc. IV. p. 40.
Liver, Red Atrophy of, Microsc[illegible] Pl. xiv. Fig. 3.
Liver Red Atrophy with Acu[illegible] xiv. Fig. 1.
Liver, Spindle-Cell Sarcom[illegible]
Liver, Syphilitic and La[illegible]
Liver, Syphilitic Cicatr[illegible]
Liver, Syphilitic Cir[illegible]
Liver, Tubercular. [illegible]
Liver, Tubercular [illegible] and 9.
Liver, Yellow S[illegible] Microscop[illegible]
Lymph-Adeno[illegible]
Lymph-Ad[illegible]
Lymphi[illegible]

M.

Malpighian Body, Fibrous Degeneration of (partial), in Chronic Interstitular Nephritis. Pl. viii. Figs. 9 and 10.
Malpighian Corpuscle from Spleen of Case of Early Scarlatina. Pl. ix. Figs. 20 and 21.
Medullary Cancer of Kidney. Pl. v. Fig. 5.
Medullary Cancer of Testis. Pl. xlvi. Fig. 1.
Microscopical Appearances of Red Atrophy of Liver. Pl. xiv. Fig. 3.
Microscopical Appearances of Yellow Swollen Parts of Liver. (Acute Yellow Atrophy.) Pl. xiv. Fig. 2.
Miliary Gummata of Liver. Pl. xxi. Fig. 7.
Monolobular Cirrhosis of Liver. Pl. xxi. Fig. 8.
Multiplication of Nuclei on Glomerulus of Kidney. Pl. viii. Fig. 11.
Muscular Hypertrophy of Spleen. Pl. x. Figs. 4 and 5.
Myelitis, after Concussion of Spine. Pl. xl. Fig. 2.
Myxœdematous Liver. Pl. xxii. Fig. 10.

N.

Nephritis. Fasc. II. p. 1 *et seq.* *See Sub-headings.*
Nephritis, Acute, after Burn. Pl. ii. Figs. 6 and 7.
Nephritis, Acute Catarrhal. Pl. viii. Fig. 15.
Nephritis after Burns. Pl. ii. Figs. 6 and 7.
Nephritis after Diphtheria. Pl. ii. Fig. 1.
Nephritis, Acute, after Scarlet Fever. Pl. ii. Fig. 4.
Nephritis after Scarlet Fever. Pl. ii. Figs. 2, 3, 4 and 5.
Nephritis, Chronic Interstitular, Fibrous Degeneration (partial) of Malpighian Body in. Pl. viii. Figs. 9 and 10.
Nephritis, Chronic Parenchymatous. Pl. ix. Fig. 8.
Nephritis, Interstitial (Post-Scarlatinal), Casts in Tubes in. Pl. viii. Fig. 19.
Nephritis, Interstitial, Chronic. Fasc. II. p. 26.
Nephritis, Interstitial, Colloid Casts in. Pl. viii. Fig. 20.
Nephritis, Parenchymatous, Acute. Fasc. II. p. 22.
Nephritis, Parenchymatous (Catarrhal), Section of Cortex from case of. Pl. viii. Figs. 17 and 18.
Nephritis, Scarlatinal. Fasc. II. p. 23; Pl. viii. Fig. 13; Pl. ix. Figs. 1 to 6.
Nephritis, Subacute, after Scarlet Fever. Pl. ii. Figs. 2, 3 and 5.
Nephritis, Subacute Interstitial (probably Scarlatinal). Pl. ix. Fig. 7.
Nephritis, Subacute Interstitial (probably following Scarlet Fever). Pl. viii. Fig. 14.
Nephritis, Subacute Interstitial, with large White Kidney. Pl. viii. Fig. 12.
Nerve, Median, Fusiform Enlargement of Roots of. Pl. lxii. Fig. 10. [Fasc. XI. Pl. xiii.]
Nerves, Enlargement of. Pl. lxii. Fig. 11. [Fasc. XI. Pl. xiii.]
Nerves, Various, Neuromata on. Fasc. XI. *See* Neuromata.
Neuroma at Extremity of Sciatic Nerve of Stump. Pl. lxiii. Fig. 10. [Fasc. XI. Pl. xiv.]
Neuroma, connected with External Branch of Median Pl. lxii. Figs. 1 and 2. [Fasc. XI. Pl. xiii.]
Neuroma connected with Extremities of Nerve of Brachial Plexus. Pl. lxiii. Figs. 5 and 6. [Fasc. XI. Pl. xiv.]
Neuroma, with Internal Branch of Median to index-finger. Pl. lxii. Fig. 3.
Neuroma, Posterior Part of Right Anterior Pl. liii. Fig. 1. [Fasc.
Neuroma of Popliteal Nerve. Pl.
Neuroma of Lower part of Sciatic Nerve. Pl. lxii. Fig. 9 [Fasc. XI. Pl. xiii.]
Neuroma of Sciatic Nerve, removed from Stump. Pl. lxiii. Figs. 2 and 3. [Fasc. XI. Pl. xiv.]
Neuroma of Ulnar Nerve. Pl. lxii. Fig. 6. [Fasc. XI. Pl. xiii.]
Neuroma of Ulnar Nerve. Pl. lxii. Fig. 8. [Fasc. XI. Pl. xiii.]
Neuroma on Median Nerve from Amputation Stump. Pl. lxiii. Fig. 7. [Fasc. XI. Pl. xiv.]
Neuroma, Traumatic, of Median Nerve. Pl. lxiii. Fig. 11. [Fasc. XI. Pl. xiv.]
Neuroma of Cervical Portion of Right Pneumogastric Nerve. Pl. lv. Figs. 1 and 2. [Fasc. XI. Pl. vi.]
Neuromata of Extremities of Nerves. Pl. lxiv. Figs. 7, 8 and 9. [Fasc. XI. Pl. xv.]
Neuroma of Extremity of Nerve of Stump. Pl. lxiv. Fig. 10. [Fasc. XI. Pl. xv.]
Neuroma of Gasserian Ganglion. Pl. lxiv. Fig. 11. [Fasc. XI. Pl. xv.]
Neuroma of Left Sciatic Nerve. Pl. li. [Fasc. XI. Pl. ii.]
Neuroma of Right Sciatic Nerve. Pl. lii. Fig. 1. [Fasc. XI. Pl. iii.]
Neuroma, Spheroidal, connected with Musculo-Spiral Nerve, front of elbow. Pl. lxii. Fig. 4. [Fasc. XI. Pl. xiii.]
Neuromata occupying Left Sciatic Nerve, Right Vagus in Neck, Right Median in Forearm, &c. Pl. l. [Fasc. XI. Pl. i.]
Neuromata of Anterior Crural Nerve, branches of left. Pl. lix. Fig. 3. [Fasc. XI. Pl. x.]
Neuromata of Cervical Ganglia, superior and inferior. Pl. lxiv. Figs. 5 and 6. [Fasc. XI. Pl. xv.]
Neuromata of Cervical Portion of Left Pneumogastric Nerve. Pl. lv. Fig. 6. [Fasc. XI. Pl. vi.]
Neuromata of Cutaneous Nerves. Pl. lvii. Fig. 1. [Fasc. XI. Pl. viii.]
Neuromata of Extremities of Nerves. Pl. lxiii. Figs. 8 and 9. [Fasc. XI. Pl. xiv.]
Neuromata of Extremities of Nerves (in case of amputation of fore-arm near centre). Pl. lxiii. Fig. 1. [Fasc. XI. Pl. xiv.
Neuromata of Front of Abdomen and Lower Part of Thorax. Pl. lvi. [Fasc. XI. Pl. vii.]
Neuromata of Left Anterior Crural Nerve. Pl. liii. Fig. 2. [Fasc. XI. Pl. iv.]
Neuromata of Left Sciatic Nerve. Pl. lxi. Figs. 1, 2 and 3. [Fasc. XI. Pl. xii.]
Neuromata of Median and Radial Nerves, &c., shown in dissection of amputation stump. Pl. lxiii. Fig. 4. [Fasc. XI. Pl. xiv.]
Neuromata of Median Nerve, Ulnar Nerve, &c. Pl. liv. Fig. 1. [Fasc. XI. Pl. v.]
Neuromata of Nerves of Left Upper Extremity. Pl. lviii. Fig. 2. [Fasc. XI. Pl. ix.]
Neuromata of Nerves of Right Arm and Fore-Arm. Pl. lvii. Fig. 2. [Fasc. XI. Pl. viii.]
Neuromata of Pelvis. Pl. lv. Fig. 7. [Fasc. XI. Pl. vi.]
Neuromata of Pneumogastric Nerves in relation with Œsophagus in Thorax. Pl. lix. Fig. 1. [Fasc. XI. Pl. x.]
Neuromata of Popliteal and Posterior Tibial Nerves (right side). Pl. lix. Fig. 2. [Fasc. XI. Pl. x.]
Neuromata of portions of Phrenic Nerves. Pl. lix. Figs. 4 and 5. [Fasc. XI. Pl. x.]
Neuromata of Right Anterior Crural Nerve and Branches, with portion of Lumbar Plexus. Pl. lviii. Fig. 1. [Fasc. XI. Pl. ix.]
Neuromata, Small, connected with Left Phrenic Nerve in Thorax. Pl. lv. Fig. 5. [Fasc. XI. Pl. vi.]
Neuromata upon Fibrillæ of different Nerves. Pl. lv. Figs. 8, 9, 10 and 11. [Fasc. XI. Pl. vi.]
Neuromata upon Under Surface of Tongue, connected with Branches of Left Hypoglossal Nerve. Pl. lv. Fig. 4. [Fasc. XI. Pl. vi.]
Nutmeg Liver. Pl. xvi. Fig. 2; Pl. xxi. Fig. 1; Pl. xxii. Fig. 3; Fasc. IV. p. 25.

O.

Syphilitic: Fasc. X. pp. 19
Deformans, Illustrations of
2, 3, 4, 5, 6 and 7.

P.

Pacinian Corpuscles, connected with Digital Branches of Median Nerve. Pl. lxiv. Fig. 13. [Fasc. XI. Pl. xv.]
Paget's Disease (Osteitis Deformans). Pl. xxxv. Figs. 1–7.
"Painful Subcutaneous Tubercle," Specimen from Case of. Pl. lxiv. Fig. 1. [Fasc. XI. Pl. xv.]
Pale Flabby Kidney. Pl. v. Figs. 3 and 4.
Papilloma of Gall-Bladder. Pl. xxiv. Fig. 2.
Parenchymatous (Catarrhal) Nephritis, Section of Cortex from Case of. Pl. viii. Figs. 17 and 18.
Pathology of the Testis. (By J. Hutchinson, jun.) Fasc. X. pp. 1 to 31.
Pedunculated Cartilaginous Body attached to Globus Major of Epididymis. Pl. xlii. Fig. 3.
"Pericellular" Cirrhosis of Liver. Pl. xxii. Fig. 1.
Perihepatitis. Fasc. IV. p. 28.
Phosphatic Calculus, removed from bladder of man aged 27. Pl. xxxiv. Fig. 5.
Phosphorus Poisoning, Changes in Liver in. Fasc. IV. p. 20; p. 52 (Appendix).
Pia Mater of Cord, Tubercle in. Pl. xli. Fig. 1.
Pigmented Liver. Fasc. IV. p. 40.
Portal Vein, Diseases of. Fasc. IV. p. 49.
Prostate, Enlarged. Bladder seen laid open from above. Pl. xxxiv. Fig. 1.
Prostate Gland, Enlargement of. Pls. xxxiii. and xxxiv.
Pyæmia, Embolic Changes in Spleen in. Pl. vi. Fig. 4.
Pyæmia, Infarction Processes from, in Kidney. Pl. iv.
Pyelo-Nephritis, Tuberculous. Pl. ix. Fig. 11.

R.

Red Atrophy, with Acute Yellow Atrophy of Liver. Pl. xiv. Fig. 1.
Renal Pathology, Résumé of present knowledge of. (By W. S. Greenfield, M.D.) Fasc. II. pp. 1 to 34.
Renal Pathology, Résumé, List of Authors. Fasc. II. p. 33.
Résumé of Diseases of Liver. Fasc. IV. pp. 1–52.
Résumé of Renal Pathology. Fasc. II. pp. 1–34.
Rupture of Spleen. Pl. vi. Fig. 5.

S.

Sarcoma, Hæmorrhagic, of Testicle. Pl. xlviii. Fig. 3.
Sarcoma involving whole Testicle, and spreading up Spermatic Cord. Pl. xlvi. Fig. 4.
Sarcoma (Round-Celled or Lympho-Sarcoma) of the Testicle. Pl. xlvii. Figs. 1 and 2.
Scarlatina, Early, Section through Spleen in case of. Pl. ix. Fig. 18.
Scarlatinal Nephritis. Pl. viii. Fig. 13; Pl. ix. Figs. 1–6.
Scrofula, Kidney in. Pl. i. Figs. 1, 2 and 3; Pl. iv. Fig. 6.
Scrofulous Disease of Kidney. Pl. i. Figs. 2 and 3.
Scrofulous Disease of Kidney and Ureter. Pl. i. Fig. 1.
Scrofulous Kidney, A variety of. Pl. iv. Fig. 6.
Sealing-Wax, Portion of, removed from Bladder. Pl. xxxii. Fig. 2.
Semilunar Ganglion, Left, Enlargement of. Pl. lxiv. Fig. 2. (Fasc. XI. Pl. xv.)
Semilunar Ganglion, Right, Enlargement of. Pl. lxiv. Fig. 3. (Fasc. XI. Pl. xv.)
Spermatic Cord, Hydrocele of. Pl. xlii. Fig. 1.
Spinal Arachnoid, Cartilaginous, Deposits on. Pl. xl. Fig. 1.
Spinal Canal, Hæmorrhage into, external to Vertebral Theca. Pl. xxxviii. Fig. 3.
Spinal Column, Injuries to, attended by Contusion of Cord. Pl. xxxviii. Figs. 1, 2 and 3.
Spinal Cord, Diseases of. Pl. xxxviii. to xli.
Spinal Cord, Pia Mater of, Tubercle in. Pl. lxi. Fig. 1.
Spindle-Cell Sarcoma of Liver. Pl. xx. Fig. 8.
Spine, Concussion of, Myelitis after. Pl. xl. Fig. 2.
Spleen, Abnormal positions of. Fasc. II. p. 48.
Spleen, Abscess of. Fasc. II. p. 42.
Spleen, Artery of, in longitudinal section; hyaline degeneration (Early Scarlatina). Pl. ix. Fig. 19.
Spleen, Cancer of. Fasc. II. p. 46.
Spleen, Capsulitis of. Pl. x. Fig. 1.
Spleen, Capsulitis of, Chronic. Fasc. II. p. 37.
Spleen, Cysts of. Fasc. II. p. 48.
Spleen, Diseases of. Pl. vi.; Pl. vii. Figs. 7, 8 and 9; Pl. x. Figs. 1–13.
Spleen, Diseases of, Résumé of our present knowledge of. (By James F. Goodhart, M.D.) Fasc. II. pp. 35–48.
Spleen, Embolic changes in, in Pyæmia. Pl. vi. Fig. 4.
Spleen, Embolism of. Fasc. II. p. 40.
Spleen, Fibrosis of. Pl. x. Figs. 2 and 3.
Spleen, Flocculent Vegetations on Convex Surface of. Fasc. II. p. 37.
Spleen, "Hard-Bake." Fasc. II. p. 45.
Spleen, Hodgkin's Disease of. Pl. vi. Fig. 1.
Spleen, Hypertrophy of Muscular Tissue of Trabeculæ of. Fasc. II. p. 38.
Spleen in case of Hodgkin's Disease. Pl. x. Fig. 8.
Spleen, Induration and Atrophy of. Pl. x. Fig. 11.
Spleen, Kidneys, Bladder and Urethra of Dog, Kidney and Bladder containing Calculi. Pl. xxxiv. Fig. 3.
Spleen, Lardaceous. Fasc. II. pp. 39, 40; Pl. vii. Fig. 9; Pl. x. Figs. 12 and 13.
Spleen, Lesions of Pulp and Lymphoid Tissues of. Fasc. II. p. 43.
Spleen, Leucocythæmic. Pl. x. Figs. 6 and 7.
Spleen, Lymphadenoma of. Pl. xvii. Fig. 4.
Spleen, Malformation of. Fasc. II. p. 48.
Spleen, Malpighian Corpuscle of, from case of early Scarlatina. Pl. ix. Figs. 20 and 21.
Spleen, Muscular Hypertrophy of. Pl. x. Figs. 4 and 5.
Spleen, Normal Structure of. Fasc. II. pp. 34, 35.
Spleen, Rupture of. Fasc. II. p. 47; Pl. vi. Fig. 5.
Spleen, Section of, in Hodgkin's Disease. Pl. ix. Fig. 22.
Spleen, Section through, of a case of early Scarlatina. Pl. ix. Fig. 18.
Spleen, Tubercle of. Fasc. II. p. 46; Pl. vii. Figs. 7 and 8; Pl. x. Figs. 9 and 10.
Splenic Arteries, Hyaline changes in, in certain febrile conditions. Pl. ix. Figs. 18, 19, 20 and 21.
Stomach, Cancer of, extending to Cystic Duct. Pl. xxvi.
Struma Supra Renale. Fasc. II. p. 53.
Subacute Interstitial Nephritis, probably following Scarlet Fever. Pl. viii. Fig. 14.
Subacute Interstitial Nephritis, probably Scarlatinal. Pl. ix. Fig. 7.
Subacute Interstitial Nephritis, with large White Kidney. Pl. viii. Fig. 12.
Suppurating Infarction of Spleen, from case of Ulcerative Endocarditis. Pl. vi. Fig. 3.
Supra-Renal Capsule, Addison's Disease of. Pl. vii. Figs. 5 and 6.
Supra-Renal Capsule, Cancer of. Pl. vii. Fig. 1.
Supra-Renal Capsules, Adenoma of. Fasc. II. p. 53; Pl. vii. Figs. 2, 3 and 4; Pl. ix. Fig. 23.
Supra-Renal Capsules, Caseous Disease of (Addison's Disease). Fasc. II. p. 50.
Supra-Renal Capsules, Diseases of. Pl. vii. Figs. 1–6; Pl. ix. Fig. 23. Pl. x. Figs. 14 and 15.
Supra-Renal Capsules, Diseases of, Résumé of our present knowledge of. (By James F. Goodhart, M.D.) Fasc. II. pp. 49 to 53.
Supra-Renal Capsules, Hæmorrhage into. Fasc. II. p. 50.
Supra-Renal Capsules, Section of, in Addison's Disease. Pl. x. Figs. 14 and 15.
Supra-Renal Capsules, Tubercular Disease of (Addison's Disease). Fasc. II. p. 50.
Supra-Renal Capsules, Tumours of. Fasc. II. p. 53.
Supra-Renal Capsules, Structure and Relations of. Fasc. II. p. 49.
Supra-Renal Capsules, Lardaceous Degeneration of. Fasc. II. p. 50.
Supra-Renal Capsules, Inflammation of. Fasc. II. p. 50.
Supra-Renal Goitre. Fasc. II. p. 53.
Syphilis, Kidney in. Pl. i. Fig. 4.
Syphilitic and Lardaceous Disease of Liver. Pl. xxiii.
Syphilitic Cicatrices in Liver. Pl. xiii.
Syphilitic Cirrhosis of Liver. Pl. xiii.
Syphilitic Deposit, Mass of, in Cortical Substance of Kidney. Pl. i. Fig. 4.
Syphilitic Hepatitis. Fasc. IV. p. 38.
Syphilitic Orchitis. Fasc. X. pp. 19–23.

T.

Testes, Retention and Malposition of. Fasc. X. p. 11.
Testicle, Hæmorrhagic Sarcoma of. Pl. xlviii. Fig. 3.
Testicle, Misplaced, in Perineum. Pl. xlix.

Testicle, Sarcoma involving whole. Pl. xlvi. Fig. 4.
Testicle, Sarcoma (Lympho-Sarcoma) of. Pl. xlvii. Figs. 1 and 2.
Testicle, Tumour of, probably Sarcomatous. Pl. xlvii. Fig. 3.
Testicle, Tumour of, Malignant. Pl. xlviii. Fig. 2.
Testicles, Retention and Malposition of. Fasc. X. p. 11.
Testis and Epididymis, Extreme Atrophy of one. Pl. xliv. Fig. 2.
Testis and Epididymis, Gummatous Deposit in, from acquired Syphilis. Pl. xlv. Fig. 5.
Testis and Lung, Gummatous Disease of. Pl. xlv. Figs. 3 and 4.
Testis, Atrophy of. Fasc. X. p. 30.
Testis, Cancer of, Medullary. Pl. xlvi. Fig. 1.
Testis, Cystic Chondro-Sarcoma of. Pl. xlvi. Fig. 2.
Testis, Cystic Disease of. Fasc. X. p. 25.
Testis, Cystic Disease (? Sarcoma) of. Pl. xliv. Fig. 3.
Testis, Diseases of. Fasc. IX., X.; Pls. xlii. to xlix.
Testis, Growths secondary to Tumours of. Fasc. X. p. 27.
Testis, Gumma breaking down in. Pl. xlv. Fig. 1.
Testis, Gumma of, due to inherited Syphilis. Pl. xlv. Fig. 2.
Testis, Gumma of, with Hydrocele. Pl. xlvi. Fig. 3.
Testis, Gummatous Disease of, with great enlargement of organ. Pl. xlv. Fig. 6.
Testis, Hæmatocele of. Fasc. X. p. 29.
Testis, Malignant Tumours of, in early life. Fasc. X. p. 29.
Testis, Pathology of the. Fasc. IX. X.; Pls. xlii.-xlix.
Testis, Retained, Malignant Tumours starting in. Fasc. X. p. 28.
Testis, Tubercular Disease of. Fasc. X. p. 17.
Testis, Tumours of. Fasc. X. p. 23.
Testis, Undescended and Atrophied. Pl. xliv. Fig. 1.
Tubercle of Spleen. Pl. vii. Figs. 7 and 8.
Tubercle in Pia Mater of Cord. Pl. xli. Fig. 1.
Tubercle, Painful Subcutaneous. Pl. lxiv. Fig. 1. (Fasc. XI. Pl. xv.)
Tubercles of various sizes, situated on upper surface of Cerebellar Hemispheres. Pl. xxxvii. Fig. 2.
Tubercular Disease of Liver, Extreme. Pl. xxii. Figs. 7 and 9.
Tubercular Disease of Supra-Renal Capsules (Addison's Disease). Fasc. II. p. 50.
Tubercular Liver. Pl. xviii. Fig. 3; Pl. xxi. Figs. 5 and 14. Pl. xxii. Figs. 7 and 9.
Tubercular Spleen. Pl. x. Figs. 9 and 10.
Tubercular Tumour, situated between left side of Pons Varolii, Medulla Oblongata, and adjacent surface of left Cerebellar Hemisphere. Pl. xxxvi. Fig. 3.
Tuberculous Pyelo-Nephritis. Pl. ix. Fig. 11.
Tuberculous Tumour on Spinal Dura Mater. Pl. xxxix. Figs. 1, 2 and 3.
Tumour, Malignant, of Testis (from boy aged two years). Pl. xlviii. Fig. 2.
Tumour of Testicle, probably of sarcomatous nature. Pl. xlvii. Fig. 3.
Tunica Albuginea Testis, Hydrocele of. Pl. xlviii. Fig. 1.
Tunica Vaginalis and Tunica Albuginea Testis, Multilocular Cyst developed between. Pl. xlii. Fig. 6.
Tunica Vaginalis, Calcareous and Cartilaginous Bodies formed in visceral layer of, &c. Pl. xlii. Fig. 5.
Tunica Vaginalis, Calcareous Plate in. Pl. xlii. Fig. 4.
Tunica Vaginalis, Cartilaginous and Calcareous Bodies in. Fasc. X. p. 8.
Tunica Vaginalis, Hydrocele of. Fasc. X. p. 4.
Tunica Vaginalis, Hydrocele of, Common. Pl. xliii. Fig. 1.
Tunica Vaginalis, Hydrocele of upper part of. Pl. xlii. Fig. 7.

U.

Ulcerative Endocarditis, Suppurating Infarction of Spleen from case of. Pl. vi. Fig. 3.
Ureters, Impaction of Calculi by. Pl. xxxiv. Fig. 2.
Uric Acid Calculi; Layer of Urate of Ammonia between deposits of Uric Acid. Pl. xxx. Figs. 1, 2 and 3.
Uric Acid Calculus, same structure as Fig. 3 (same Plate). Pl. xxviii. Fig. 6. Fig. 7 shows abrupt transition from Uric Acid to Phosphates.
Uric Acid Calculus, Central portion and one of fragments of. Pl. xxxi. Fig. 11.
Uric Acid Calculus, from Kidney, Section of. Pl. xxix. Figs. 1 and 2.
Uric Acid Calculus, Pisiform. Pl. xxix. Fig. 12.
Uric Acid Calculus, Section and Exterior. Pl. xxix. Figs. 10 and 11.
Uric Acid Calculus. Pl. xxviii. Figs. 1 and 2.
Uric Acid Calculus, Section of, largely made up of coarse crystals, disposed in a radiating manner. Pl. xxviii. Fig. 3.
Urinary Calculi, Bibliography of. Fasc. VI. p. 29.
Urinary Calculi, Classification of. Fasc. VI. p. 1.
Urinary Calculi, Enumeration of conditions favouring formation of. Fasc. VI. pp. 27-29.
Urinary Calculi in Lower Animals. Fasc. VI. p. 24.
Urinary Calculi, On. (By Jonathan Hutchinson, F.R.S., LL.D.) Fasc. VI. pp. 1-29.
Urinary Calculus, remarkable shape. Pl. xxxii. Fig. 3.

V

Varicocele. Fasc. X. p. 9.
Varicocele of moderate size, unravelled. Pl. xliii. Fig. 2.
Varicocele, Large (compared to bundle of earth-worms). Pl. xliii. Fig. 3.
Vegetation from Surface of Liver. Pl. xx. Fig. 7.

PRINTED BY WEST, NEWMAN AND CO., HATTON GARDEN, LONDON.

Fig. III.

Fig. I.

Fig. II.

Fig. IV.

Fig. V.

Fig. I.

Fig. II.

Fig. III.

Fig. IV.

Fig. V.

Fig. VI.

Fig. VII

PLATE III.

THE GRANULAR KIDNEY IN DIFFERENT STAGES.

(Eight Figures.)

Fig. 1. Extremely Granular Kidney.—Outer surface of the left kidney of Ann Read. (Hospital for Sick Children. Drawing by H. B. Tuson.) See Appendix, p. 6.

Fig. 2. Extremely Granular Kidney.—Section of the same kidney. (Hospital for Sick Children. Drawing by H. B. Tuson.) See Appendix, p. 6.

Fig. 3. Less Granular (contracted) Kidney.—Outer surface of the right kidney taken from the same subject as the left kidney shown in Figs. 1 and 2. (Hospital for Sick Children. Drawing by H. B. Tuson.) See Appendix, p. 6.

Fig. 4. Granular Kidney of Bright. (Guy's Hospital.)

Fig. 5. Contracted Granular Kidney, in section (Dr. Sutton).—From the body of Celia W—. "A good example of the small contracting granular kidney. The history of the case showed that the disease had probably commenced in acute nephritis, and the small greyish-red masses seen on the surface were apparently the product of inflammation." See Appendix, p. 7.

Fig. 6. Contracted Granular Kidney; exterior (Dr. Sutton).—The whole organ is shrunken and hard. (From the same case as Fig. 5.)

Fig. 7. Large Granular Kidney. (Guy's Hospital.)

Fig. 8. Large Granular Kidney with cysts. (Guy's Hospital.)

Fig. II.

Fig. III

Fig. IV.

Fig. V.

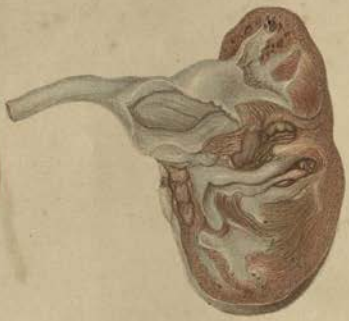

Fig. VI.

Fig. VII.

Fig. VIII.



PLATE IV.

EMBOLISM: INFARCTION PROCESSES FROM PYÆMIA: JAUNDICE AND PURPURA: SCROFULA.

(Six Figures.)

Fig. 1. Embolic Changes in Pyæmia (Dr. Sutton).—Specimen from the body of a man who had disease of bone with abscess over upper part of one femur. The mesenteric and pelvic veins were plugged. There were also infarctions in spleen and bowel. (The London Hospital. Drawing by Burgess.)

Fig. 2. Embolic Changes in Pyæmia.—Fibrinous blocks in kidney with obstruction of renal artery by fibrin, the result of embolism. (St. George's Hospital. Drawing by Tuson.) See Appendix, p. 8.

Fig. 3. Pyæmic Deposits in Kidney.—Secondary deposits scattered over the surface of the kidney, in various stages, from James Springwood. (St. George's Hospital. Drawing by Tuson.) See Appendix, p. 8.

Fig. 4. Pyæmic Deposits in the Kidney (Mr. Hutchinson).—From a boy who died from osteitis and pyæmia. There were deposits in the lungs also. (Burgess.)

Fig. 5. Results of Jaundice and Purpura.—Kidney of a woman who had jaundice from obstruction of the orifice of the common bile-duct by a small medullary tumour in the duodenum. A few days before death she had purpura and profuse hæmorrhage from the intestines. (St. Bartholomew's Hospital.) (Specimen, Series XIX, No. 13. Drawing by Delamotte, October, 1845.)

Fig. 6. A Variety of the Scrofulous Kidney.—The substance of the kidney is wholly destroyed and replaced by cavities containing a white mortar-like substance. Some of these are as large as walnuts, and the bulk of the organ is increased. Some ragged cavities open into the pelvis. The lining membrane of the pelvis is inflamed and thickened. (St. Bartholomew's Hospital. Drawing by Mr. Canton.)

Fig I.

Fig II.

Fig III.

Fig IV.

Fig V.

Fig VI.

APPENDIX.

PLATE I.

Fig. 1. *Scrofulous disease of kidney.*—The kidney was removed from the body of Charles Smith, æt. 38, who died in St. George's Hospital, on August 12th, 1869. Caries of the vertebræ with double psoas abscess, extensive scrofulous disease of the urinary organs, and acute pulmonary tuberculosis, were recorded at the post-mortem examination. The history was that of a fall three years prior to death, followed by pain in the loins, and after a period of twelve months by a swelling in the right thigh.

Profuse sweating, restlessness, and cough, were superadded during the last two months. Death was preceded by severe abdominal pain and persistent vomiting (Post-mortem and Case-book, 1869, p. 240).

Figs. 2 and 3. *"So-called scrofulous disease of the kidney."*—"From Martha D., æt. 32, who was admitted into the London Hospital, January 23rd, 1868, and died February 5th, 1868, of phthisis.

Post-mortem.—The body was much wasted, weighing only 70 lbs. The left pleura was adherent over the upper third, and contained a pint and a half of fluid in the lower part. Over the apex of the right lung the pleura was also adherent. The apex of each lung was indurated, and contained a cavity, which was full of pus. In the indurated portions were scattered bodies which looked like miliary tubercles. These tubercle-like bodies were scattered also throughout the whole of the upper lobes. The lungs were singularly pale looking. The heart seemed healthy, excepting that the wall of the left ventricle was thinner and softer than normal, and of a yellowish colour. The liver was congested, and had the nutmeg appearance to a slight degree. The right kidney (fig. 3) was atrophied and very small. On cutting into it, it was found to consist of little else than a fibroid case or cyst, with loculi, which were filled with a mortar-like substance and milky fluid. The left kidney (fig. 2) was buried in a prominent mass of thickened peritoneum and thickened capsule. This mass of tissue was distinctly made up of two layers, one thickened peritoneum, the other thickened renal capsule. The thickness of these two layers together was about an inch. This kidney was much enlarged. There was a good deal of thickening also around the ureter, which continued as far as the bladder. The kidney substance itself was softened; and it had a dull reddish-white appearance. The cortex and pyramids were ill-defined, and in the substance of the kidney were several abscesses, or cavities with irregular thickened purulent walls (Dr. Sutton, London Hospital).

Fig 4. *A syphilitic gumma in the kidney.*—The plate represents the kidney slit open in such a manner as to exhibit the appearance of the growth both on the surface of the organ and in section. The characteristic yellowish colour and sharply defined outline of the nodule are well represented. The whole organ was congested, and minutely injected, with small paler spots scattered through it; it was apparently in a condition intermediate between that of the congested kidney of acute Bright's disease ("chocolate kidney"), and that of the mottled kidney. (Dr. Sutton, London Hospital.)

Fig. 5. *"Hodgkin's disease."*—The plate represents the kidney of a boy who was in the London Hospital, under the care of Dr. Andrew Clark. He was believed during life to be suffering from 'anæmia lymphatica,' or, as it is sometimes called, 'Hodgkin's disease.' The glands of the neck were very much enlarged and indurated. There were hard, firm, grey masses in the liver; deposits like tubercle in the lungs; and an enlarged thymus gland.

The new material in this kidney gave the whole organ the dull opaque white appearance shown in the plate, variegated in the cortical part by points of congestion and extravasation. It had, at the same time, caused the great and general enlargement of the organ there indicated. Under

the microscope, in this disease of the kidney, the new material is seen extending between the tubules, separating them widely from each other, so that they appear as if embedded in a mass of new tissue. Histologically this tissue has the same appearance as the new growth in the glands, *i. e.*, it is seen to consist of lymph-gland-like tissue. (Dr. Sutton, London Hospital.)

PLATE II.

FIG. 1. *Nephritis after diphtheria.*—Florence Ralph, four and a half years old. Admitted into the Hospital for Sick Children, under care of Dr. West, November 4th, 1866.

Oct. 20th, 1866.—The family moved, and during the cleaning and scrubbing of the rooms all the children took cold. 31st.—Florence seemed worse. Nov. 1st.—She complained of her throat. 3rd.—Her mother saw "ulcers" in her throat; in the evening the child became hoarse.

Nov. 4th.—Temperature, evening, 100·4°. She was put into a tent-bed and steamed; she had an emetic of sulphate of zinc and ipecacuanha, which acted freely; a solution of lunar caustic was applied to the throat; the neck was surrounded by a linseed-meal poultice; she took a mixture of chlorate of potash and cinchona every three hours; and she was put upon a diet of milk, beef-tea, and six ounces of port wine.

5th, morning.—Face and lips livid; moderate inspiratory recession of base of chest; inspiration dry, hissing, croupy; expiration much less loud; voice suppressed, dry, husky; swallows well; not much swelling of neck. Temp. 99·2°; pulse 148, weak, not influenced by inspiration; resp. 44. Fauces swollen; uvula and tonsils coated with a false membrane, rather firmly adherent, not very thick, well limited in places. Urine: sp. gr. 1034, turbid with urate of soda, not albuminous.

In the afternoon the dyspnœa became great. Mr. Thomas Smith performed tracheotomy: a piece of false membrane was expectorated through the wound; the relief was very great, and the child passed a quiet night.

6th.—Breathing a little laboured, yet no recession of chest walls. Urine not very abundant, yellow, trace of albumen.

7th.—Breathing more laboured; false membrane coughed up through tube. Urine: yellow, pretty clear, albumen abundant.

8th.—Much the same. Urine: 310 cub. centims., sp. gr. 1034, excess of mucous flocculence, no saline deposit, orange colour, albumen very abundant.

9th.—Has coughed up several small pieces of false membrane. Urine: 345 cubic centims.; other characters as yesterday.

10th.—Exhausted. Urine: 420 cubic centims.; sp. gr. 1025, less deeply coloured, albumen still very abundant.

11th.—Breathing has become very laborious, has coughed up several pieces of very tough false membrane. She became extremely distressed, "worse than before the operation," sweated profusely, remained conscious until death.

Post-mortem appearances.—Larynx and trachea filled with very tenacious mucus, greenish, no false membrane. The incision had divided the cricoid cartilage and the upper tracheal ring. The anterior part of the thyroid cartilage was a good deal eroded, apparently in consequence of the pressure of the canula. (Preserved in museum.)

Lungs.—Right, 3 oz. 14 dr., highly emphysematous. Left, 3 oz. 8 dr. Lobar pneumonia of a part of the lower lobe of the right lung.

Liver.—26 oz. 6 dr. Tissue looked full; periphery of lobules opaque; centres transparent; not much altered.

Spleen.—1 oz. 14 dr. Malp. bodies enlarged.

Kidneys.—4 oz. 8 dr., plump. Malp. bodies much injected in places. Cortex rather clouded round the pyramids of Bertini. These were all the changes.

FIG. 2. *Subacute nephritis after scarlet fever.*—John Parker, aged 5 years, was admitted into St. Bartholomew's Hospital under the care of Dr. Burrows, April 27th, 1854. He had suffered from scarlet fever five weeks previously, and from dropsy for one week. On admission he was generally anasarcous, and there was blood-stained discharge from his nostrils. The urine was scanty, rather sooty, and albuminous. He was treated by confection of jalap, small doses of calomel, diuretics, and warm baths. On the 23rd of May he began to suffer from attacks of dyspnœa. He died in a state of stupor on the 27th.

The following are the chief facts as to the post mortem, which was conducted by Mr. William Turner.

Heart enlarged, especially on the left side; pale, and not very firmly contracted.

Right auricle a little dilated, and containing a

large recent separated clot. In this cavity, as well as in the left auricle and both the ventricles, entangled amongst the musculi pectenati and carneæ columnæ, were deposits of old clot, pale and completely deprived of their colouring matter; some of the clots were firm, others softening and presenting in their interior a purulent-looking matter, and one especially, about the size of a small nutmeg, placed at the apex of the left ventricle, had its interior softened and hollowed out into a distinct cavity lined by a smooth and glistening vascular membrane.

The *left ventricle* was dilated and its walls hypertrophied; its inner surface presented here and there a faintly marked yellow mottling, and under the microscope the fibres in these parts presented in their interior a number of oil-like particles.

All the *valves* healthy except the aortic, which was slightly thickened at the free border, the corpora arantii being large; the contiguous borders of the cusps were thickened and drawn together, so as to produce a small degree of puckering.

Pleuræ.—Considerable effusion into the left of turbid serum, with soft lymph floating in it; the same description of lymph was also adherent to both the costal and pulmonic pleuræ. A few drachms of clear serum in the right side.

Lungs.—*Right* lung slightly congested in all its lobes.

The *left* compressed, so as to be destitute of air; when placed in water it sank to the bottom of the vessel.

Kidneys.—The *left* about the natural size.

The *right* a little larger; they both presented the same characters. The capsule stripped off readily, and left a perfectly smooth exterior surface, which was mottled all over with a number of yellowish or buff-coloured dots. Some of these were surrounded by a finely marked vascular zone, others were separated from each other by a fine light brownish line. Here and there also upon the exterior were several small well-marked vessels branching in a stellate or radiated manner, and coming to a fine termination. Near the hilus of the kidney the surface was a little elevated, owing to the presence of several small nodules. On section the kidney cut firm, and presented in its interior a yellowish mottling, something similar to that found on the exterior, except that it was a little more diffused, not being present in such distinct dots. The line of demarcation between the cortical and medullary portions was only faintly marked, but there did not appear to be any diminution of thickness of the cortical portion.

FIG. 3. *Subacute nephritis after scarlet fever.*—Ellen Foster, six and a half years old. Admitted into the Hospital for Sick Children, under the care of Dr. West, on November 9th, 1866.

On admission, she was suffering from a mild attack of scarlet fever.

About December 3rd, a little albumen appeared in the urine, and she became dropsical. On the 6th, an attack of pulmonary catarrh; œdema of the lungs was feared, but the severe symptoms passed off in a day or two; however, the child was left much worse; the urine was highly albuminous; the dropsy greater.

21st.—Highly dropsical; very pale. Urine: about 150 cubic centims. passed this afternoon, none passed this morning or during the night; pale yellow, turbid, slight saline deposit; excessively albuminous; in sediment, many loose exudation, pyoid, corpuscles, and casts of medium size entangling the same. The urine has never been smoky or bloody.

26th.—She died.

Post-mortem appearances. — *Body :* weight 37¼ lbs.; very anæmic; universal anasarca.

Pleuræ.—Universal and rather tough adhesions.

Heart.—4 oz. 10 drms.; notable dilatation and induration of the left ventricles.

Lungs.—Right, 8 oz. 12 drms.; left, 7 oz. 8 drms. A few miliary tubercles here and there. at base of upper lobe of left lung there was a mass of infiltrated white tubercle, about the size of a walnut, studded around by miliary tubercle.

Bronchial glands.—Largely tuberculized.

Liver.—26 oz., natural.

Spleen.—1 oz. 10 drms., natural.

Kidneys.—6 oz., considerably enlarged. A good specimen of mottled kidneys. Surface smooth. Bases of cortical columns opaque buff, surrounded by indistinct vascular markings. Section shows cortex greatly thickened, mottled with opaque and reddish striæ, some more opaque than others. Malpighian bodies not injected. Whole cortex pale buff. Vascularity of periphery of Bertinian pyramids increased. Cortical processes of these pyramids well marked.

FIG. 4. *Insidious form of nephritis, following scarlatina, with gastric disturbance, but scarcely a trace of œdema. Urine loaded with albumen and*

abounding with fibrinous casts, but without blood. Convulsive attack. Death. Examination of body. —The following case narrative is copied by permission from Dr. Dickinson's work on the 'Pathology and Treatment of Albuminuria.'

Thomas Vallance, nine years old, was attacked with scarlatina, August 8th, 1866. On the 13th he came into the Children's Hospital, under my care. The attack was slight; the throat was affected, but not severely, and the boy became convalescent, the urine being free from albumen. On the 25th, however, the urine was examined, as a matter of routine, and was found to be loaded with albumen (alb. $\frac{7}{8}$); the urine was reduced in quantity, but was not discoloured. The boy looked as well as ever; he had no symptoms which could have drawn attention to the state of the urine. There was no evidence of his having taken cold; nor had he been allowed to leave his bed.

The skin was dry, and was peeling somewhat incompletely. Next day the urine for twenty-four hours was obtained, and found to amount only to 163 c.c., or about six ounces. There was no trace of blood to be discovered. There were a few cells of renal epithelium, and a great multitude of casts, consisting for the most part of simple fibrinous cylinders, perfectly uniform and without structure. A few casts of a granular texture, imbedding epithelial cells, were also seen. The child now had a heavy manner, the pupils were large, and he had been sick; but he looked well, and had no pain nor any trace of œdema; pulse 72. He was now put upon fluid diet, allowing, however, bread and butter; ordered to drink water plentifully, and had two drachms of infusion of digitalis every four hours. Measures were taken to move the bowels, which were obstinately confined. A little brandy was given to counteract the depressing effect of the digitalis.

On the 27th the pulse had fallen to 52, and was not quite regular; the brandy was therefore increased to two ounces daily, and the digitalis given only every six hours. The urine had now fallen to less than three ounces in the twenty-four hours, still retaining the same character. There was frequent vomiting.

On the 28th the pupils were conspicuously large, and the boy's manner very slow. There was a trace of œdema before each tendo-Achillis. He was not pallid, and still looked and felt pretty well. The pulse was 68. He took less food, but very often vomited, especially after the water, which was therefore not pressed. The urine now amounted only to 45 c.c., or less than two ounces. Instead of the digitalis he was ordered a diuretic draught containing scoparium, acetate of potass, and nitric ether; this, however, was always vomited, as was the brandy, the water, and almost everything else. He frequently was sick, although he had taken nothing, bringing up green slimy matter.

On the 29th there was no improvement; he was dry-cupped on the loins, the slowness and irregularity of the pulse appearing to prohibit the removal of blood. The diuretic mixture was changed by the addition of nitre and squills. His manner, however, became more slow and peculiar, the pupils more dilated; no increase took place in the urine, and on the 30th, as had been anticipated, he was seized with epileptiform convulsions, a succession of which came on and caused his death in two hours and a half. They were accompanied by foaming and biting of the tongue. Excepting the trace of œdema which was noticed above the heels, there was no dropsy through the whole course of the disease. The features were always sharp, and the face free from puffiness.

The urine was not in sufficient quantity to allow of the estimation of all the components on any one day. The amount of each was ascertained, some on one day, some on another; the general results are as follows. The urea was estimated on several occasions. The date of each observation is given.

Post-mortem.—The body weighed 38¼ lbs. There was a trace of œdema about the ankles.

The brain and all the other organs were carefully examined; all were natural. There was no serous effusion in any of the cavities. The kidneys only require description.

The kidneys weighed 11 oz. 4 drs. The capsules were natural; the exposed surfaces were smooth and highly vascular, from the presence of a closely-woven network of minute injected vessels, which gave a general pink tint. No vessels of any size could be seen. The cortex was greatly increased, dense and firm in texture. It appeared to consist of a fine intermixture of pink and buff materials, the colours being disposed much in lines radiating from the cones to the surface. Both cortex and cones dripped with blood. The cones were of a deep purple colour. One of the kidneys is well represented.

Under the microscope the epithelium was found to be natural. The part outside the nucleus was generally finely granular, a condition frequently found when no renal disease has existed.

The convoluted tubes were all filled with a fine granular material, in which many epithelial nuclei could be seen. A section hardened in chromic acid showed a general obstruction of the convoluted tubes by a fine, smooth-looking material, which completely plugged them up, generally lying in contact with the basement membrane, which had lost its epithelial lining. There was some dilatation of the capsules of the Malpighian bodies.

The case is peculiar in many respects. From the first it was evident that it was attended with great danger. The worst cases are those in which no blood makes its way into the urine. The inflammation appeared to give rise to a copious exudation of tenacious fibrine throughout the whole tubular structure, so closing the channels that the urine, scarce able to find exit, was voided in a quantity not exceeding a tenth of its proper amount. The reduction of the urinary solids was extreme. It may be observed that the urea fell to its minimum on the day when the urine was most scanty, illustrating the general rule that the amount of the urinary elements varies with the amount of water. With the extreme scantiness of the urine the absence of dropsy is remarkable. This may possibly have been due in some measure to the removal of fluid by vomiting; though, until late in the course of the disease, it did not seem that the quantity so discharged was sufficient to make up for the decrease of urine. The alteration in the pupils and in the patient's manner, taken together with the persistent vomiting, led to an anticipation of a convulsive attack, which was verified by the result.

Although this case has been inserted to illustrate the natural history of the disease, the treatment, in anticipation of what will follow, has been described in some detail, the more particularly to give an example of the failure of a plan which has been very generally successful. This case, and another which closely resembled it, are all which ended fatally of a large number of cases which during the last seven years have been subjected to similar treatment. The rapid and extensive effusion of fibrinous matter throughout the whole gland gave a virulency to the disorder, against which any remedies would probably have contended in vain.

Fig. 5.—*Subacute nephritis after scarlet fever.*—Thomas D. Weller, five years old. Admitted June 24th, 1869. His father was gouty, and his maternal grandmother and two aunts died of phthisis. He had hooping-cough at six weeks. Four months ago his belly swelled, and soon after there was general anasarca, especially of eyelids and scrotum. Urine occasionally very dark, like porter; this was observed at the commencement of his illness.

No history of his catching cold; has had no catarrh, but has been in the habit of sitting on the cold kerb-stone. No scarlet fever at home, but very prevalent in the day-school he attends. No rheumatism; no chorea; no convulsions.

State on admission.—June 24th.—General anasarca; no ascites; percussion of belly indicates œdematous state of peritoneum. Slight basic and infra-clavicular anæmic bruit; otherwise respiration and heart sounds good. Bowels regular. Urine albuminous, cloudy, dark.

July 6th.—Urine averages about one pint. Up to-day for the first time. General puffiness; œdema of conjunctivæ; urine highly albuminous; much granular matter.

8th.—Vomited this morning. Urine less—about ʒxvj per diem.

18th.—Vomited again this morning. In the night a boy in the same ward died; child was much depressed in mind and frightened. This afternoon scarlatina is developed. Urine diminished = ʒxij.

19th.—Rash well developed; fauces injected. Temp. 103° F.; urine still albuminous; hyaline casts with disintegrated epithelium, free and imbedded.

24th.—Small white ulcer on right tonsil. Much languor and depression.

28th.—Desquamation completed. Face puffy. Resp. 40, pulse 104, irritable.

August 2nd.—Urine one fourth albumen by heat; dirty greenish brown colour, ʒxij; granular and hyaline casts; œdema of legs; drowsiness; anæmia.

5th.—Urine three fourths albumen by heat; some vomiting, languor, debility.

6th.—Diarrhœa and vomiting. Taking digitalis. Urine ʒix.

7th.—Urine ʒv, waxy, fatty, epithelial, granular, and hyaline casts, with much uric acid. Much diarrhœa and vomiting, especially after medicine.

10th.—Digitalis stopped; vomiting ceased; diarrhœa continues.

13th.—Diarrhœa continues. Urine ʒxiv, loaded with albumen.

17th.—Urine ʒv. Much diarrhœa. Resp. and heart sounds good.

19th.—Wheezing at chest in larger tubes; vesicular murmur harsh though clear everywhere. No return of vomiting. Pain at epigastrium.

20th.—Much catarrh; resp. harsh and almost croupous, probably from obstruction at glottis.

21st.—Resp. as before; obvious obstructed breathing at glottis. No running at eyes, nose, or mouth. Eyes bright. Dyspnœa. Resp. 40, pulse 108. Died at 6.30 p.m. Continued in the same condition. No convulsions.

Post-mortem examination. — Body: general puffiness; œdema of legs and scrotum. Belly distended, not fluctuating. No rigor mortis. Face somewhat congested.

Pericardium.—Contents 1¼ oz. of clear, serous fluid; membrane apparently healthy.

Heart.—Sulci of coronary arteries and veins white from œdema. Post mortem, dark clot in both ventricles, and in right auricle. Beaded vascular growths at auricular edge of mitral valve. Foramen ovale closed. Weight. 4 oz.

Glottis healthy. The upper opening of the larynx swelled and œdematous, as also base of epiglottis; the aryteno-epiglottidean folds of mucous membrane pitted on pressure. Rima glottidis, healthy. Fauces not ulcerated.

Larynx and trachea healthy. Mucous membrane not congested.

Pleuræ.—Apparently healthy; right contains ¾ oz. of clear, serous fluid; left 1¼ oz. ditto.

Lungs healthy; some œdema; no carnification; pieces of them floated in water. Some frothy mucus in dependent parts. Weight 12 oz.

Bronchial and mesenteric glands healthy.

Peritoneum.—4 oz. of clear serous fluid in cavity; membrane thickened and opaque; mesentery thick, somewhat œdematous.

Intestine.—Coats thickened, opaque, softened. Stomach healthy, but with one or two patches of scarlet congestion on posterior surface. Agminated and solitary glands healthy; the latter prominent, distinct, and large.

Liver large; upper surface of left lobe, and slightly so of small adjoining part of right, puckered from subcapsular deposit of fibrous tissue, like that of syphilis, extending in parts, a short distance into the gland, between the lobules. Weight 30½ oz.

Kidneys large; surface smooth. Colouration of surface very pretty. There was evidently the large white kidney of acute Bright's disease, but superadded to this was a mottling of the surface, also of the substance of the cortex, as seen on cut section, with crimson-red stellate vessels; the most dependent parts were those most congested. The cortex of the kidney was much increased in bulk.

On examination by microscope the most striking feature was under 1-in. power, when the size, distinctness, and apparent thickening and opacity of the Malpighian capsules immediately attracted the eye; the vessels appeared to be swelled and prominent. The epithelium of the tubes was everywhere coarsely granular, the fatty molecules being distinctly seen, both free and contained in the cells. Weight 8¼ oz.

PLATE III.

FIGS. 1, 2, & 3. *Extremely granular kidney after scarlet fever.*—Annie Reed, ten years old. Admitted April 5th, 1867.

History.—Child had scarlet fever two years ago, and became universally dropsical four weeks after; the dropsy lasted four months and then she seemed pretty well. One year ago dropsy recurred, and it has done so at times ever since; is not universal; face only swells. It occurs every five or six weeks. When face swells she vomits watery stuff, and complains of headache; it usually lasts three or four days, and then she appears well again.

Five weeks ago she had a fit which lasted two and a half hours; left side convulsed, foamed at mouth, and bit tongue. Two fits since; in last right side convulsed.

On admission.—The girl is pale, thin, dull; no œdema; no ascites. Skin dry, papillated. Urine yellow, clear, large amount of albumen.

She gradually became worse; passed very little urine; drowsiness increased; constantly screaming out. Pupils much dilated, equally so; contract very little with the light; appears not to be able to see; no facial paralysis. Very little œdema of legs. The quantity of albumen in the urine did not increase, and only a day or two before her death there were only a few flakes on boiling. Death nine weeks after admission.

Post-mortem examination. — Body: weight 32 lbs., great emaciation.

Skull.—The bone is very dense, especially in front.

Brain.—Some fluid beneath the arachnoid with slight opacity of the membrane. No fine injection of pia mater. Lateral ventricles dis-

tended with clear fluid, guessed at over 2 oz. Consistence of brain rather less than natural, few red points on section. Commissures intact. Corpora striata and optic thalami flabby, not pulpy.

Dura mater beneath anterior and left middle lobes is covered with a thin layer of coagulated blood, varying in colour from almost black to an orange tint, easily separable from the subjacent membrane, which is left unchanged.

Arteries at base of brain are very many of them the seat of atheromatous changes, in the majority the opaque yellow spots appearing at considerable intervals. The posterior cerebellar artery is completely changed. On the cerebellum, close to the pons, is a collection of sandy-looking matter, closely connected with the membrane and the superficial layer of brain substance. It resembles closely the condition which is presented by the choroid plexuses—assumed to be degenerative changes. (The above notes given by Dr. Hillier.)

Lungs.—13 oz. Both œdematous.

Pleuræ.—Contain little turbid fluid. Both covered with a thin layer of soft yellowish lymph.

Heart.—6 oz. Pericardium little turbid fluid, thin layer of soft lymph; fine injection about roots of large vessels. Degeneration of coronary arteries, also on flaps of mitral valve and at commencement of aorta are atheromatous and fatty changes.

Left ventricle hypertrophied. Cardiac substance does not break down more readily than usual.

Peritoneum.—Little recent yellowish lymph.

Liver.—24 oz.; hepatic congestion; slightly fatty.

Spleen.—1½ oz; soft. Malpighian bodies large, pale.

Stomach.—The coats are much thickened. The mucous membrane presents a mottled appearance, a reddish-brown, studded with black points; it is tough. No ulcers.

Kidneys, right.—Very small indeed. The capsule separates easily; it is much thicker and opaque. The kidney is hard and tough; the surface puckered. The substance is almost entirely destroyed, presenting on section yellowish-grey masses, with a more normal looking texture in between.

Left.—Presents same characters as right, but less marked; it is much larger than right, but smaller than natural.

Figs. 5 and 6. "*Small contracted granular kidneys.*"—From the body of Celia W—, æt. 24, a domestic servant, who was admitted into the London Hospital, on May 18th, 1869, and died July 4th in the same year.

The following is a brief account of the clinical history and of the post-mortem appearances in this case:

The patient had been quite well until three months before her admission into the hospital. She had then began to complain of cough and pain in the chest; for a fortnight her breath had been very short. When admitted she could not lie down on account of her breath, and got hardly any sleep. There was no marked dyspnœa, and no lividity, the face being pallid. Her feet and legs were œdematous. There was no rhonchus in the chest, but there was flatness of percussion resonance over the bases of both lungs. The temperature continued about normal. The urine was pale and albuminous. The subsequent symptoms were troublesome and continued vomiting, which came on after a dose of morphia given to relieve the distressing wakefulness. Indications of effusion into the left pleural cavity; and eventually, a few days before death, pericardial friction, with signs of effusion into the pericardium afterwards appeared.

At the autopsy a collection of serum and lymph was found within the pericardium, and in both pleural cavities. The left ventricle of the heart, though firmly contracted, appeared on measurement to be considerably hypertrophied; the valves and orifices were normal. There was slight atheroma about the aortic valve and in the abdominal aorta. The kidneys were very much reduced in size. They appeared to be about half the normal size. It was found that the left kidney with the bladder and uterus attached to it only weighed five ounces. The renal capsules were thick and very adherent. The surfaces of the kidneys were very markedly granular, and of a reddish colour, everywhere mottled with a yellowish or greyish substance. On section they presented a similar mottled appearance both in the cortical and medullary areas, so that it required care to distinguish between them. The cortical substance did not appear wasted out of proportion to the medullary substance, as is seen in ordinary specimens of granular degenerated kidney. The pelvis of the right kidney was markedly dilated. The right ureter was also dilated. The substance of the kidneys was firm, not tough. The other viscera appeared normal.

The body was well developed, but much wasted; the lower extremities only were œdematous. (Dr. Sutton, London Hospital.)

PLATE IV.

Fig. 2. *Plugging of renal artery, &c.*—The preparation was removed from the body of Robert W—, who was admitted into St. George's Hospital with dyspnœa and dropsical swelling. As a result of spontaneous occlusion of the femoral artery, which was diagnosed during life and subsequently found at the post-mortem examination. The left foot became gangrenous and the patient sank. Several fibrinous deposits were found in the heart, some of which were undergoing disintegration (Post-mortem and Case-book, 1862, p. 23, also 'Path. Soc. Trans.' xiv).

Fig. 3. *Pyæmic deposits on surface of kidney.*—The boy from whom the specimen was derived died in St. George's Hospital from pyæmia after acute periostitis of the *tibia*. Shortly before death a pustular eruption, apparently of pyæmic origin, appeared under the skin. The spleen contained secondary deposits; those found in the kidney were especially abundant at the surface; they were recognised to be in various stages of morbid evolution, some being merely congestive centres, others fibrinous exudations, and many distinctly suppurating (Post-mortem and Case-book, 1862, p. 64).

AN

ATLAS OF ILLUSTRATIONS

OF

PATHOLOGY

COMPILED (CHIEFLY FROM ORIGINAL SOURCES)

FOR

THE NEW SYDENHAM SOCIETY.

FASCICULUS II.

DISEASES OF THE KIDNEY,

SUPRA-RENAL CAPSULES AND SPLEEN;

WITH

PATHOLOGICAL SUMMARIES

BY DR. GREENFIELD AND DR. GOODHART.

LONDON:
THE NEW SYDENHAM SOCIETY.
1879.

AGENT—H. K. LEWIS, 136, GOWER STREET, W.C.

PLATE V.

DISEASES OF THE KIDNEY.

(Five Portraits.)

Fig. 1. Amyloid Disease of Kidney in advanced stage.—A man, aged forty, died in St. George's Hospital, under Dr. Page's care, having suffered for a year from an abscess in his thigh. He had anasarca, and his urine contained much albumen. He died with a large abscess in the right lumbar region. The left kidney, the one shown in the portrait, was very large, weighing 18 ounces. It was in a state of advanced lardaceous disease, and showed the characteristic change with iodine. Its fellow was destroyed by old suppurative disorganisation, and was replaced by fat, in which scattered cheesy deposits occurred. The liver and spleen, to the naked eye, showed lardaceous changes, but the iodine reaction was not obtainable. (St. George's Hospital. Drawing by Tuson, xxi., 15 A.)

Fig. 2. A section of the same Kidney.

Fig. 3. The pale flabby Kidney.—This portrait, from a specimen obtained at St. Bartholomew's Hospital, is given as a good illustration of the common, large, mottled, smooth kidney. It was from a man who suffered from albumenuria and dropsy. (From nature, by Burgess.)

Fig. 4. The same organ seen in section.

Fig. 5. Medullary Cancer of the Kidney.—The patient, a man aged thirty-seven, died in St. George's Hospital, under Mr. Pollock's care. He had been ill about six months, and the first symptom he had noticed was enlargement of the inguinal glands. Subsequently the glands in both groins were affected, and numerous nodules appeared under the skin. At the autopsy encephaloid nodules were found in the liver, in both kidneys, the walls of the bladder, the inguinal glands, and the subcutaneous tissues of many parts. The condition of the right kidney is shown in this portrait. (St. George's Hospital. Drawing by Tuson.)

Fig I

Fig II

Fig V

Fig IV

PLATE VI.

VARIOUS DISEASED CONDITIONS OF THE SPLEEN.

(Five Figures.)

Fig. 1. Hodgkin's Disease of Spleen (Lympho-sarcoma).—From a child, aged seven, in whom the lumbar lymphatic glands also were affected. (Hospital for Sick Children.)

Fig. 2. Acute Splenic enlargement in Diphtheria.—From the same case as Fig. 1 of Plate II. See Appendix to Fascic. I., p. 2. (Hospital for Sick Children.)

Fig. 3. Suppurating infarction of Spleen from a case of Ulcerative Endocarditis.—From a man, aged twenty-five, who died after rheumatic disease of heart, with cerebral abscesses and infarctions in kidneys and spleen. (Guy's Hospital. Drawing by Hurst.)

Fig. 4. Embolic changes in Pyæmia.—See Fig. 1 of Plate IV., Fascic. I., from the same case. (The London Hospital.)

Fig. 5. Rupture of the Spleen.—The man lived twelve days after having been run over. Several ribs had been fractured. Much blood was in the peritoneal cavity, and a large coagulum was attached to the lacerated spleen. (Guy's Hospital. Drawing by Hurst.)

Fig. I

Fig. II

Fig. III

Fig. IV

Fig. V

F. Burgess del. W. West & Co. lith.

PLATE VII.

DISEASES OF THE SUPRA RENAL CAPSULES AND SPLEEN.

(Nine Figures.)

Fig. 1. Cancer of the Supra Renal Capsule.—Only part of the gland is destroyed, remains of it being seen on the inner side of the tumour. William Godfrey, aged thirty-seven, who had carcinoma of the ribs, mediastinum, and lungs. A very doubtful discoloration of the skin existed during life. The case is recorded in Dr. Addison's work. (Guy's Hospital. Drawing by W. Hurst.)

Figs. 2, 3, 4. Adenoma of the Supra Renal Capsule.—
Fig. 3. External surface.
Figs. 2 & 4. The same in section.
(Guy's Hospital. Drawing by Dr. Moxon.)

Fig. 6. Addison's Disease of the Supra Renal Capsule (in section).—The entire organ is the seat of an albumino-fibroid tissue undergoing decay. Henry Mercer, aged thirty-eight. He had been ailing for a year without apparent cause. The skin was not discoloured. (Guy's Hospital. Drawing by W. Hurst.)

Fig. 5. Addison's Disease of the Supra Renal Capsule.—"Fibro-calcareous or strumous disease." Case of Henry Patten, aged twenty-six. Dr. Addison's work, Case 3. (Guy's Hospital. Drawing by W. Hurst.)

Fig. 7. Tubercle of the Spleen (external surface).—From an infant, aged eleven months. (Guy's Hospital. Drawing by W. Hurst.)

Fig. 8. Tubercle of the Spleen (in section).—From the same patient as Fig. 7. (Guy's Hospital. Drawing by W. Hurst.)

Fig. 9. Lardaceous Spleen.—In part stained with iodine. From a case of prolonged suppuration. (Guy's Hospital. Drawing by W. Hurst.)



PLATE VIII.

FIG. 1. LARDACEOUS DEGENERATION OF THE KIDNEY.—Section of cortex seen with low power (25 diam.) One of the interlobular arteries (*a*) with glomeruli (*b*) in connection with it, which have undergone lardaceous degeneration.

FIG. 2. LARDACEOUS DEGENERATION.—*g*. A glomerulus from the same kidney as in Fig. 1, which has undergone lardaceous degeneration and is becoming fatty; the capillaries swollen and fused into a homogeneous mass, with nuclei seen here and there. At *a* is a convoluted tubule, the epithelium of which has undergone lardaceous degeneration; the cells are transformed into a number of highly refractile fragments which are angular. (Wrongly represented as round in the Plate). (100 diam.)

FIG. 4. Part of the same seen with a higher power (200 diam.), showing contents of one of the tubules. The cells are swollen, fused together, and broken up into a number of angular masses which are highly refractile. (These characters are not well brought out in the Plate).

FIG. 4. LARDACEOUS DEGENERATION in earlier stage combined with interstitial fibrous change. (100 diam.)

a. Glomerulus which has undergone partial waxy degeneration; its central portion has become an amorphous granular mass.

bb'. So-called waxy or colloid casts in tubes.

c. Tubules with partly detached and flattened epithelium.

d. Interstitial fibroid growth.

FIGS. 5 & 6. LARDACEOUS DEGENERATION (after Cornil).—Sections stained with methylaniline violet, and mounted with acetic acid and glycerine to show the parts affected with lardaceous degeneration. The parts in dull line shading, as at *a*, were stained reddish violet in the section, the characteristic reaction of lardaceous degeneration; those in dotted shading, as at *b*, of a bluish purple, the ordinary staining of protoplasm.

FIG. 5. Section showing the hyaline membranous wall of the tubules *aa* much swollen, stained violet-red, showing waxy degeneration. Epithelium healthy, their nuclei stained blue. *b*. A so-called waxy cast stained also blue, showing the absence of lardaceous degeneration (350 diam. reduced).

FIG. 6. Transverse section of one of the pyramids, near summit of cone; *a*, degenerated wall of collecting tube cut across; *a'*, wall of one of the venulæ rectæ also degenerated; *b*, a so-called waxy cast in tubule stained blue. (200 diam. reduced). (The above two figures are from drawings by M. Cornil, *loc. cit.*, reduced to ½ size).

FIG. 7. GRANULAR CONTRACTED KIDNEY.—Section perpendicular to surface, seen under a low power (50 diam.), showing advanced interstitial change, the tissue consisting of thickened and degenerated vessels and glomeruli, with a few tubules filled with colloid casts; the intervening tissue mainly composed of nucleated fibroid tissue; *a*, thickened and adherent capsule; *bb*, thickened vessels; *c*, glomerulus filled with granular contents and with much thickened walls; *d*, colloid casts in tubes.

FIG. 8. From the same. A thickened arteriole surrounded by fibroid growth. The thickening is mainly due to hypertrophy of the muscular coat, with also some thickening of the inner coat. (100 diam.)

a. Junction of middle and inner coats.

b. Outer coat.

Plate VIII. (*continued*).

Fig. 9. Partial Fibrous Degeneration of Malpighian body in slight chronic intertubular nephritis.—*a*, thickened capsule; *b*, compressed capillary tuft; *c*, amorphous granular material in capsule; *d*, surrounding fibroid growth. (100 diam.)

Fig. 10. From the same kidney; showing early changes around Malpighian body. *a*, cavity from which the capillaries have fallen out in preparation; *a'*, epithelial cells lining capsule; *b*, scar-like tissue forming a small patch in neighbourhood of glomerulus. (100 diam.)

Fig. 11. Multiplication of nuclei on glomerulus with adhesion of capillary tuft to wall of capsule. The capsule does not appear thickened, but is involved in the surrounding scar tissue. (150 diam.)

Fig. 12. Subacute Interstitial Nephritis with large white kidney. Malpighian body in centre completely degenerated into a fibroid nodule composed of concentric laminæ, *a*, with interposed nuclei. (These were not so close as in Plate). At *b*, in the centre, is seen a growth of younger cells. Nucleated fibroid growth surrounds the glomerulus. (150 diam.)

Fig. 13. Scarlatinal Nephritis.—Intertubular exudation in a case fatal on 7th day of fever.

a. Tubules with somewhat swollen epithelium.

b. Leucocytes crowded in interstitial tissue.

Fig. 14. Subacute Interstitial Nephritis, probably following scarlet fever. (This drawing is from the centre of Fig. 7, Plate IX., where the section is seen under a low power.) (About 200 diam.)

aa. A cluster of dilated convoluted tubules.

b. Connective tissue growth around tubules.

c. Remains of wasted tubules filled with altered epithelium.

Fig. 15. Acute Catarrhal Nephritis fatal about end of 2nd week with suppression of urine. Showing swelling and granular degeneration of epithelium. (100 diam.)

Fig. 16. Part of the same seen with a higher power. (200 diam.)

a. Epithelial cells greatly swollen and granular.

Fig. 17. Section of cortex from a case of parenchymatous (catarrhal) nephritis at a later stage (so-called "fatty" kidney). *a*, convoluted tubes filled with granular epithelium and fragments of degenerated cells; *b*, ascending branch of loop of Henle, also containing swollen and fragmented epithelium and exudation cells; *c*, part of hyaline capsule of Malpighian body seen on surface (drawn so as to appear somewhat too granular); *d*, colloid casts in tubes. (100 diam.)

Fig. 18. From nearly transverse section near base of pyramid in similar case. *a*, straight tubes filled with pus-like cells or exudation corpuscles; *b*, tube with swollen granular epithelium; *c*, straight tube; *d*, tube containing blood. (100 diam.)

Fig. 19. Casts in tubes in interstitial nephritis (post scarlatinal). — From same case as Fig. 14. (100 diam.)

a. Colloid or gelatinous cast.

b. Central fibrinous cast surrounded by exudation cells.

c. Granular cast containing some blood.

Fig. 20. Colloid cast, *b*, in tubule; *a*, unaltered epithelium. (200 diam.)

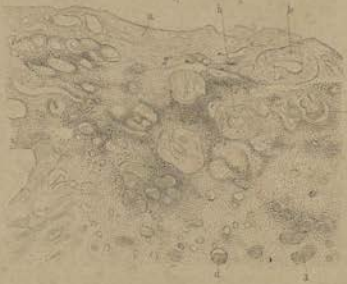

Plate VIII. (*continued*).

Fig. 9. Partial Fibrous Degeneration of Malpighian body in slight chronic intertubular nephritis.—*a*, thickened capsule; *b*, compressed capillary tuft; *c*, amorphous granular material in capsule; *d*, surrounding fibroid growth. (100 diam.)

Fig. 10. From the same kidney; showing early changes around Malpighian body. *a*, cavity from which the capillaries have fallen out in preparation; *a'*, epithelial cells lining capsule; *b*, scar-like tissue forming a small patch in neighbourhood of glomerulus. (100 diam.)

Fig. 11. Multiplication of nuclei on glomerulus with adhesion of capillary tuft to wall of capsule. The capsule does not appear thickened, but is involved in the surrounding scar tissue. (150 diam.)

Fig. 12. Subacute Interstitial Nephritis with large white kidney. Malpighian body in centre completely degenerated into a fibroid nodule composed of concentric laminæ, *a*, with interposed nuclei. (These were not so close as in Plate). At *b*, in the centre, is seen a growth of younger cells. Nucleated fibroid growth surrounds the glomerulus. (150 diam.)

Fig. 13. Scarlatinal Nephritis.—Intertubular exudation in a case fatal on 7th day of fever.

a. Tubules with somewhat swollen epithelium.

b. Leucocytes crowded in interstitial tissue.

Fig. 14. Subacute Interstitial Nephritis, probably following scarlet fever. (This drawing is from the centre of Fig. 7, Plate IX., where the section is seen under a low power.) (About 200 diam.)

aa. A cluster of dilated convoluted tubules.

b. Connective tissue growth around tubules.

c. Remains of wasted tubules filled with altered epithelium.

Fig. 15. Acute Catarrhal Nephritis fatal about end of 2nd week with suppression of urine. Showing swelling and granular degeneration of epithelium. (100 diam.)

Fig. 16. Part of the same seen with a higher power. (200 diam.)

a. Epithelial cells greatly swollen and granular.

Fig. 17. Section of cortex from a case of parenchymatous (catarrhal) nephritis at a later stage (so-called "fatty" kidney). *a*, convoluted tubes filled with granular epithelium and fragments of degenerated cells; *b*, ascending branch of loop of Henle, also containing swollen and fragmented epithelium and exudation cells; *c*, part of hyaline capsule of Malpighian body seen on surface (drawn so as to appear somewhat too granular); *d*, colloid casts in tubes. (100 diam.)

Fig. 18. From nearly transverse section near base of pyramid in similar case. *a*, straight tubes filled with pus-like cells or exudation corpuscles; *b*, tube with swollen granular epithelium; *c*, straight tube; *d*, tube containing blood. (100 diam.)

Fig. 19. Casts in tubes in interstitial nephritis (post scarlatinal). — From same case as Fig. 14. (100 diam.)

a. Colloid or gelatinous cast.

b. Central fibrinous cast surrounded by exudation cells.

c. Granular cast containing some blood.

Fig. 20. Colloid cast, *b*, in tubule; *a*, unaltered epithelium. (200 diam.)

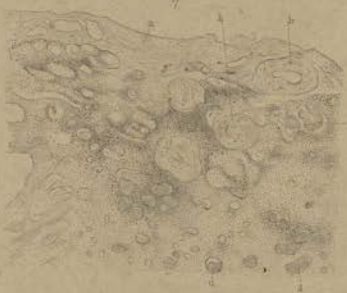

PLATE IX.

FIG. 1. SCARLATINAL NEPHRITIS.—(From a case fatal on the 42nd day from onset of scarlet fever.—Segment of cortical portion under a low power (1 inch) to show general alteration in structure. (25 diam.)

a. Surface of organ; the capsule has been removed.

bb'. Somewhat wedgeshaped tract extending inwards from surface, consisting mainly of fibrous tissue with atrophied tubules and glomeruli.

c. A somewhat similar tract in which the fibrous change is less advanced.

dd'. Glomeruli in various stages of alteration. Those indicated at *d'* are represented in Fig. 2 under a higher power.

The drawing also shows general thickening of the intertubular structures with atrophy of the tubules. The contents of many of these have fallen out in course of mounting; others contain, as at *c*, a mass of granular cells.

FIG. 2. Shows two of the glomeruli from same section as Fig. 1, *d'*, under a higher power. (120 diam.)

a. Capillary tuft obscured by nuclei, and having a granular appearance.

b. Capsule of glomerulus apparently unaltered.

c. Cell-growth from lining of capsule forming a mass of cells accumulated between the capsule and glomerulus.

d. A glomerulus more completely degenerated, the capsule entirely filled with a mass of cells, nuclei, and granular material, in which the outlines of the original structure can hardly be distinguished; at *d* there appear to be the remains of the capillary tuft, and at *e* of the cells accumulated around, as at *c*.

f. Some fibrous thickening around the Malpighian capsule.

FIG. 3. Section from the same. Part of the wall of a Malpighian body from which the capillary tuft has fallen out. Seen under a higher power. (300 diam.)

a. Membranous wall of capsule, which is unaltered.

b. Cell-growth in its interior, forming somewhat stratified layers. At *c* is a trace of imperfectly-formed fibrous tissue; *d*, more regularly stratified cells, which are somewhat more flattened or fusiform.

FIG. 4. SCARLATINAL NEPHRITIS.—(From a case fatal about 12 weeks from attack of fever).—Two glomeruli, *aa*, under nearly the same power as Fig. 2. (120 diam.)

aa. Glomeruli thickly studded with nuclei, and considerably shrunken; the capillaries obscured.

b. Capsule thickened and fibrous.

c. Growth of cells apparently from lining of capsule, as at Fig. 3.

FIG. 5. SCARLATINAL NEPHRITIS.—(From a case fatal 15 months after attack of scarlet fever).—Kidney typical "large white," but rather tough. Shows advanced interstitial growth, with secondary changes in tubules.

aa. Interstitial connective tissue growth everywhere surrounding the tubules.

b. Convoluted tubules, dilated, and the epithelium flattened.

c. Straight tubules which have undergone similar changes, but are less altered. Other tubules are so altered as to be hardly recognisable.

d. Large cells with multiple nuclei in an altered tubule.

FIG. 6. From same kidney as Fig. 5, but in a deeper part of cortex, close to medulla. Similar growth of interstitial connective tissue. The drawing is chiefly to show the large cells, some with several nuclei, which are contained in the tubules; at *aa* and *bb* are tubes containing several large epithelial cells.

FIG. 7. SUBACUTE INTERSTITIAL NEPHRITIS, probably Scarlatinal, under low power; showing diffuse infiltration and cluster of dilated tubules. (25 diam.)

a. Cluster of dilated convoluted tubes.

b. Interstitial connective tissue growth, containing here and there remains of atrophied tubules and glomeruli.

FIG. 8. CHRONIC PARENCHYMATOUS NEPHRITIS (large white kidney) with little or no interstitial change. Section of cortex, showing changes in epithelium of convoluted tubules. (200 diam.)

a. A convoluted tubule filled with swollen epithelium and angular granular masses irregularly heaped together, due to degenerative processes in the epithelium.

b. A tubule in which the individual cells are better seen.

c. Tubule with granular contents and some small angular cells.

d. Straight (?) tubule, with proliferated epithelium.

FIG. 9. Kidney in leucocythæmia—to show localisation of changes around glomeruli and vessels. (25 diam.)

FIG. 10. Swelling of inner coat of small artery in granular contracted kidney. (120 diam.)

aa. Fibrous thickening of outer coat of larger artery of which it is a branch.

b. Middle coat of small artery.

c. Inner coat greatly swollen, hyaline, but somewhat granular. (It is represented much too granular).

d. Outer coat, merged in connective tissue growth *g* around it.

e. Detached endothelium and leucocytes filling interior of vessel. (Probably a post-mortem change).

f. Part of a looped tubule.

FIG. 11. TUBERCULOUS PYELO-NEPHRITIS.—Section of cortex near surface under low power (25 diam.) showing circumscribed tracts of infiltration *aa'*, which to naked eye appear as grey granulations.

a. Tract of infiltration (occupying lower third of drawing) with glomeruli at its periphery, in which the tubular structure is hidden by the exudation.

a'. Points to nearly the centre of a similar tract, at which there is a caseous patch.

The glomeruli show various alterations.

FIG. 12. FATTY DEGENERATION FROM ALCOHOLIC POISONING (after Lancereaux).—The tubules and glomerulus are filled with oil-droplets due to fatty degeneration.

FIG. 13. FATTY DEGENERATION IN CANCER.—Fresh section examined in water under low power, showing convoluted tubules filled with fattily degenerated epithelium. (50 diam.)

FIG. 14. Individual epithelial cells from the preceding section; in various stages of fatty degeneration. (300 diam.)

FIG. 15. CYSTIC DEGENERATION OF KIDNEY (after Lancereaux).—Contents of cyst. Cholesterine plates *a*, blood corpuscles *b*, and granular cells *c* from the fluid contents of a cyst.

FIG. 16. From a cyst in kidney near base of pyramid. Oxalate of lime crystals *a*, and leucine *b*, contained in the cyst. (After Lancereaux).

FIG. 17. COLLOID DEGENERATION OF KIDNEY (after Lancereaux).

FIGS. 18, 19, 20, and 21, illustrate the hyaline changes found in the splenic arteries in certain febrile conditions. (After Klein, Path. Soc. Trans., vol. xxviii., Pl. 34.)

FIG. 18. From a section through the spleen of a case of early scarlatina, showing hyaline degeneration of the coat of an artery, transversely cut. (After Klein.)

a. Hyaline degeneration.

FIG. 19. Artery in longitudinal section.

a. Hyaline degeneration of intima. (220 diam.)

FIG. 20. Malpighian corpuscle from the spleen of a case of early scarlatina, showing three different zones, *a*, *b*, *c* (about 50 diam).

FIG. 21. Part of the central and intermediate zone of the same Malpighian corpuscle as in Fig. 20, only more highly magnified (180 diam.)

FIG. 22. HODGKIN'S DISEASE.—Section of a spleen to show the overgrowth of the lymphatic sheath in Hodgkin's disease. (1 inch.)

aa. Lymphatic sheath much enlarged by an overgrowth of its cellular elements.

bb. Central artery of the lymphatic sheath.

cc. Cavernous tissue of the pulp.

FIG. 23. ADENOMA OF THE SUPRA RENAL CAPSULE, showing the columns stuffed with fatty granules, *aa; bb*, stroma. (After Moxon.)

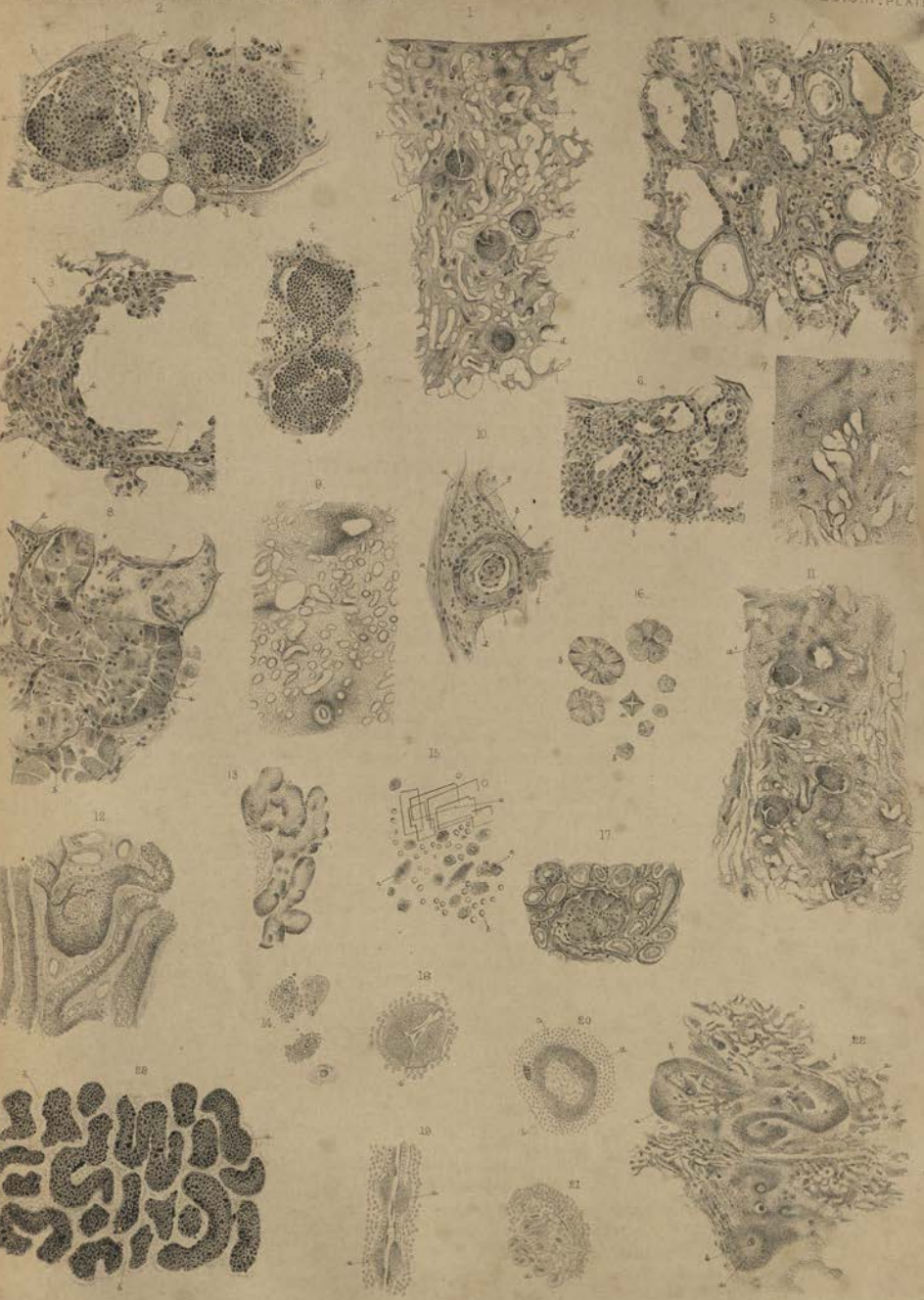

J.F.Bright ad nat. del. (figs. 1 to 11)

Hart, Newman & Co. sc.

KIDNEY & SPLEEN.

PLATE X.

FIG. 1. CAPSULITIS OF THE SPLEEN.—Vertical section of fibrous nodule in the capsule of the spleen, showing that the thickening of the capsule takes place by cellular growth in its deeper layers. 1 inch objective; 37 diam.

a. Surface of the spleen.

b. Thickened trabecula.

c. Limit of the thickening.

dd. Splenic pulp.

FIG. 2. FIBROSIS OF THE SPLEEN.—From the enlarged spleen of a ricketty child. The figure shows a small arteriole with its lymphoid sheath. In place of a regular and close arrangement of cells around the artery, the coats of the vessel are swollen and hyaline, and the proper lymphoid tissue is replaced by a quantity of hyaline fibroid material, comparatively very sparely sprinkled with cellular elements. (250 diam.)

a. Section of arteriole cut somewhat obliquely.

a'. Transverse muscular bands in the arterial wall.

b. Limit of outer coat of vessel.

cc. Hyaline fibroid material replacing the proper splenic lymphoid sheath.

c'. More strongly-marked fibroid material.

dd. Splenic cells.

FIG. 3. FIBROSIS OF THE SPLEEN.—From an enlarged spleen in a ricketty child. Showing a more advanced or fibrous condition spreading round some dilated veins. (250 diam.)

aa. Dilated venous channels.

bb. Fibro-muscular tissue spreading into

cc. Splenic pulp.

FIG. 4. MUSCULAR HYPERTROPHY.—Over-growth of muscular trabeculæ in the spleen. (250 diam.)

a. Section of vein.

bb. Limits of muscular trabecula. The elongated nuclei of organic muscular fibre are present in large numbers.

cc. Splenic pulp. From a child who died from acute tuberculosis.

FIG. 5. MUSCULAR HYPERTROPHY.—Extreme stage of fibro-muscular growth in the spleen. (250 diam.)

a. Fibroid tissue.

b. Nuclei of muscular tissue. From a slide in the possession of Dr. Coupland.

FIG. 6. THE LEUCOCYTHÆMIC SPLEEN.—Section of the edge of a Malpighian corpuscle, showing the compressed fibrous tissue between it and the splenic pulp. The structure is normal, but is taken from the enlarged spleen of leucocythæmia. (250 diam.)

a. Small arteriole entering the Malpighian tuft near its side.

bb. Fibrous tissue condensing, and thus forming pseudo-capsule between *c*, the lymphoid tissue inside it, and *d* the more open textured tissue of the pulp.

FIG. 7. THE LEUCOCYTHÆMIC SPLEEN.—The pulp and stroma are normal (*a*), but rather crowded. The veins are a little dilated (*b*). (250 diam.)

FIG. 8. HODGKIN'S DISEASE.—The texture of a lymphoid nodule in the spleen of Hodgkin's disease. Transactions of Pathological Society of London, vol. xxi., Plate ix. (After Bristowe.) (220 diam.)

FIG. 9. TUBERCULAR SPLEEN. (37 diam.)

a. A tubercle caseous in the centre, but cellular towards the circumference.

a'. Portion of similar mass.

b. Shows the spread of tubercle round a small artery. (See also Fig. 10.)

c. Adjacent Malpighian capsule with slight excess of cellular elements round it, but itself healthy. Most of the contents lost; a small artery with some surrounding cells alone remaining.

FIG. 10. TUBERCULAR SPLEEN.—The drawing shows a small arteriole in the centre surrounded by tubercular growth. The cells are closely but regularly packed; they are more closely arranged, and have a different stroma to the healthy lymphoid tissue, which is quite healthy in the adjacent neighbourhood. At the circumference of the figure the splenic pulp is becoming healthy. (250 diam.)

aa. Healthy splenic tissue.

b. Small arteriole.

c. Tubercular part.

FIG. 11. INDURATION AND ATROPHY.—A section of the spleen from a case of heart disease. It shows the normal arrangement to be quite lost; large spaces are seen bounded by tough-looking fibrous trabeculæ (dilated veins of the pulp), and the lymphoid sheaths cannot be distinguished. The disease thus corresponds with the nutmeg liver. (37 diam.)

aa. Thickened capsule.

bbb. Thickened trabeculæ, many of them containing vessels.

ccc. Dilated venous spaces.

FIG. 12. LARDACEOUS SPLEEN.—The sago spleen. (37 diam.) Showing the Malpighian corpuscles and small arteries mapped out by structureless hyaline lardaceous matter. (The engraving of this and Fig. 13 convey an erroneous impression of the diseased parts, which are represented as *distinctly fibrous*. They should have a blurred appearance, with hardly any trace of fibrous structure.) (37 diam.)

aa. Lardaceous zone round small arteries of a Malpighian corpuscle.

a'a'. Longitudinal and transverse sections of small arteries, with lardaceous change in their walls.

b. Earlier stage of the disease, with the lardaceous matter less well defined.

b'. Transverse section of vessel, with lardaceous changes in its walls.

c. Fibrous septum, with lardaceous change in it.

c'. Fibrous septum containing vessels.

dd. Splenic tissue, much of it with a cloudiness about it, indicating early lardaceous change.

FIG. 13. LARDACEOUS SPLEEN.—Transverse section of a Malpighian corpuscle, or small artery, with its surrounding lymphoid sheath. It shows the same hazy blending of the various textures, and the stroma and cellular elements are no longer well defined. Here again the fibrous texture is too pronounced. The darker part, which is all lardaceous, should be of a more homogeneous appearance; the contrast between trabeculæ and spaces but faintly visible, and any distinctly fibrous appearance lost. (250 diam.)

a. Central artery, with swollen hyaline walls.

bb. Lardaceous disease of the surrounding sheath.

c. Healthy splenic pulp.

FIG. 14. ADDISON'S DISEASE.—Vertical section of a supra renal capsule from the exterior inwards, to show the early changes in Morbus Addisonii. (250 diam.)

a. Limit of investing capsule.

b. Rounded spaces of the cortex, with their granular cells.

cc. Elongated spaces nearer the medulla.

dd. Closely-set small-cell infiltration, which characterises the early stage of caseous disease of the supra renal capsules.

FIG. 15. ADDISON'S DISEASE.—Section of a supra renal capsule, to show the late, or fibro-calcareous, stage of Morbus Addisonii. (After Coupland.)

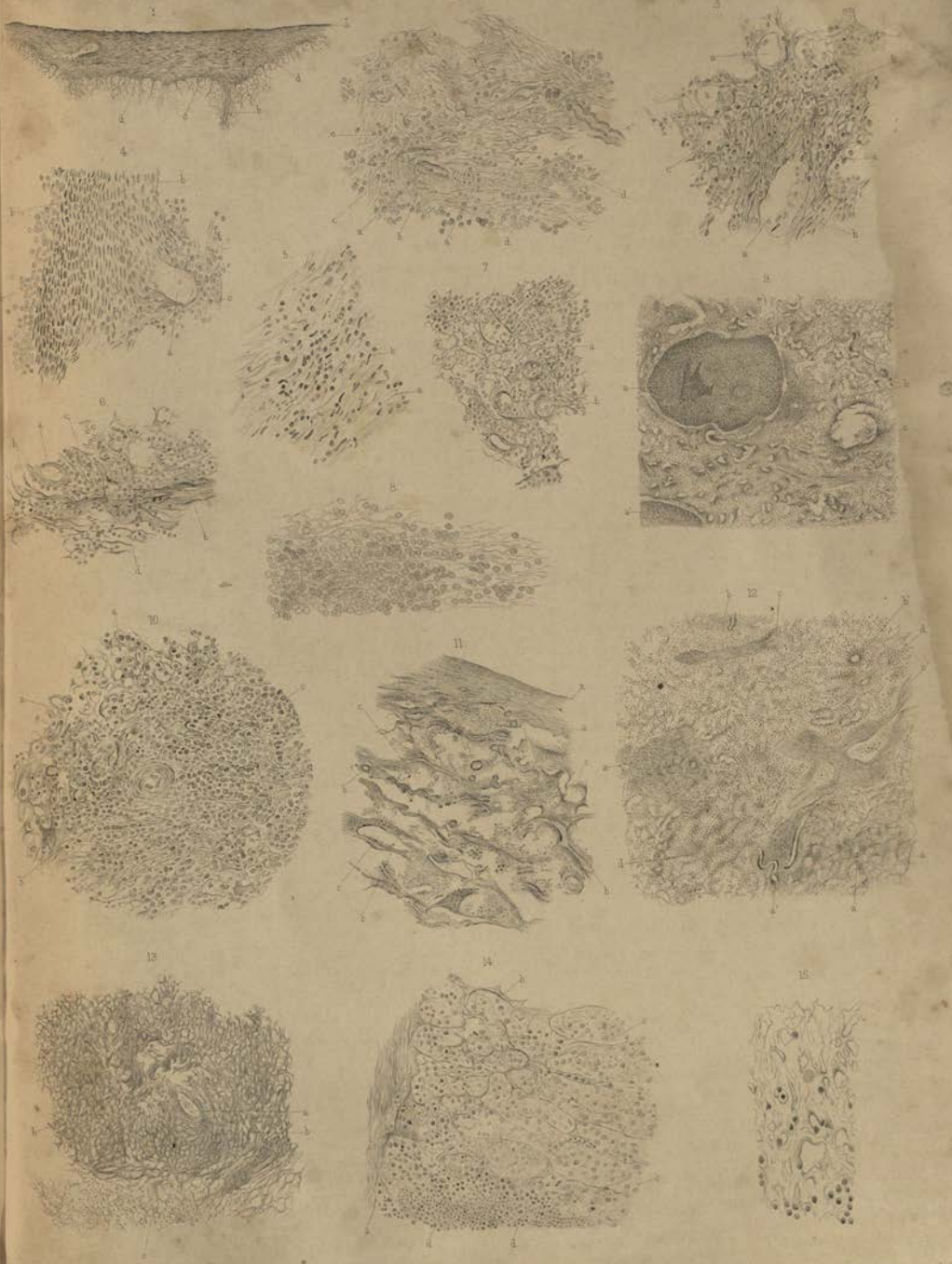

SPLEEN & SUPRA-RENAL CAPSULES

A RÉSUMÉ

OF THE PRESENT KNOWLEDGE OF

RENAL PATHOLOGY.

By W. S. GREENFIELD, M.D.

GENERAL CONSIDERATIONS.

The morbid changes found in the kidneys after death are very numerous and varied. In common with other organs the kidneys are subject to degenerative changes, which may be limited to them or associated with similar degeneration in other parts of the body; they are liable to be affected by causes operating through their ducts, or acting directly upon the organs themselves; they may be the seat of morbid growths and infiltrations of primary or secondary nature; they have also special forms of disease peculiar to themselves, which depend upon changes in their own proper elements, and are usually of the class known as inflammatory; and to these we must add the changes, temporary and permanent, of excessive or diminished blood supply, as well as those due to congestive engorgement and obstruction of vessels.

The most important of these changes are those which are comprised under the name of "Bright's disease," changes proper to the kidneys, usually of inflammatory nature, and by some spoken of as *nephritis*, or, by some foreign writers, "albuminous nephritis" (Rayer; Cornil., &c.) *

Since the discoveries of Bright were made, renal pathology, has made great advances; especially since the use of the microscope has become general. But so great was the accuracy of his observations, and so wide his grasp of pathology, that even to the present day the great divisions which he sketched out remain as the basis of modern doctrine. There is still, however, great diversity of opinion both as to the exact limitation of Bright's disease and as to the distinctions between its different forms.

When we come to study the minute anatomy we meet with great difficulties in connecting the general features of each clinical form with any definite grouping of histological changes. Microscopic research has shown that in kidneys, taken from two cases with very similar symptoms, and almost indistinguishable with the naked eye, the changes found may present very great dissimilarity; hence some have tried to frame a classification solely based upon pathological histology. Thus the "large, white, smooth" kidney of Bright may present changes limited to the tubules and their epithelium, or the most extensive interstitial connective tissue growth, with only secondary wasting of the epithelium; in the one case the disease being called "parenchymatous nephritis;" in the other, "interstitial nephritis." In opposition to this view there are some who maintain the doctrine of the "unity of Bright's disease," and hold that all the forms of "mottled" kidney, "large white," and "fatty" kidney, and "granular contracted" kidney—are only different phases or stages of the same morbid process; thus the form characterized by diffuse interstitial growth would be regarded as only one phase in the transition from acute to chronic Bright's disease.

Another difficulty, and no slight one, has arisen from the fact that in studying with the microscope

* It is difficult to give any absolute definition of "Bright's disease." Bright's observations were upon "Renal Disease accompanied with the secretion of albuminous urine," as he defines it. Others have spoken of it as renal disease associated with albuminuria and dropsy (*e.g.*, Roberts). But as Bright himself remarked, the presence or absence of albumen in the urine is not an unerring test of the existence of nephritis, and we now know that a large number of cases of granular contracted kidney may during long periods present no perceptible albuminuria or dropsy; moreover, both albuminuria and dropsy may co-exist with renal congestion of cardiac origin, which would not usually be classed as Bright's disease. Nor does the use of the term "albuminuria" as synonymous with Bright's disease appear to us likely to do anything but increase the confusion.

the kidneys of those dying from other causes than Bright's disease, changes are often found similar to those seen in Bright's disease, but limited in extent and degree, and not giving rise to any change in the appearance of the organ, or to any known consequences. Obviously these changes might be regarded as slight degrees of Bright's disease; but to classify them as such would produce still greater disparity between the descriptions of morbid anatomy and clinical medicine.

In the absence of a generally accepted classification of nephritis we shall follow an intermediate course, and describe first of all the various changes which the constituents of the kidney may undergo; we shall then endeavour to show how these are associated in the commonly-recognized forms of acute and chronic Bright's disease, and to what extent they are met with in other diseases. The object of this sketch will be to state only the results of the most modern researches; referring but briefly to the many disputed points. The other general diseases of the kidney will then be briefly described, as to their morbid anatomy and histology.

STRUCTURE OF THE KIDNEY.

In studying renal disease it is highly important that the minute structure of the kidney should be kept clearly in view. (For a complete account of this, see article, "Kidney," by Ludwig, in Stricker's Histology, New Syd. Soc. Trans.) Separate changes, essentially distinct, affect the glomeruli, the convoluted tubules, the uriniferous tubes proper, the vessels and the interstitial connective tissue; and both the intimate structure and the relations of these elementary constituents are of great importance.

The kidney may be regarded as made up of an immense number of compound glands, of elongated pyramidal shape, closely packed together; the bases of these glands being at the surface of the cortex, their apices joined together in bundles in the pyramids. These elementary constituent glands are the so-called "primitive cones" ("lobules" Rindfleisch), all of which have a similar structure and arrangement, and each of which forms a unit both in health and disease.

Each primitive cone corresponds to a single collecting tube in the pyramid (Ludwig); its central portion is formed by the straight tubes, which unite at very acute angles to form the collecting tube. The bundle of straight tubes in the centre of the cone forms a so-called "medullary ray," and reaches nearly to the surface of the cortex. Between the primitive cones the arterial branches pass up straight into the cortex parallel to the medullary rays, giving off short afferent twigs to the glomeruli, which are thus situated at the outer part of each cone, and are connected with the straight tubes by the convoluted and the looped tubules, the former composing a labyrinthine mass which lies between the arterial branches and the central cluster of straight tubes.

On a transverse section of the cortex, there will be seen with a low power a number of clusters of tubes cut across; at regular intervals, arranged between them in such a way as to mark out polygonal spaces are the glomeruli; and between these and the central clumps of straight tubes, with the ascending branches of the looped tubules, are seen the convoluted tubes cut in various directions.

It will be remembered that each glomerulus or Malpighian tuft hangs free in a capsule which opens by a narrow mouth into a convoluted tubule; that the convoluted tubule in turn opens at the other extremity into a very narrow tube, the descending branch of the "looped tube of Henle," this first descends into the pyramid for a long distance, and then ascends, hugging the straight tubules in the centre of the cone, until it opens into a wider short tube which connects it with a descending branch of the straight tubes, and these latter by union with others finally form the collecting branches in the pyramid.

The Malpighian body, composed of the *glomerulus* (Malpighian tuft) and its capsule, constitutes the first part of the excreting structure. The glomerulus itself is a tuft of looped capillaries attached to a terminal arterial twig (or more rarely two). These penetrate the capsule and immediately break up into from four to eight branches, which give off loops of capillaries, and these again unite into one small trunk (efferent vessel) which finds its exit close to the afferent artery. The capillaries are of pretty uniform size.

The capillary tuft thus formed is loosely covered by a layer of epithelial cells of somewhat polygonal shape, with spherical nuclei and ill-defined outlines (Ludwig), and is nowhere in actual contact with the capsule. *

* This epithelium is well seen in some morbid conditions, especially in early lardaceous degeneration of the capillaries, and in some cases of chronic congestive induration.

The *capsule* of the glomerulus is formed by a very delicate membrane which is apparently structureless (though said by Ludwig to be composed of a thin mosaic of cells); externally it is covered by a delicate layer of connective tissue; internally there is a continuous layer of flat cells resembling those forming the endothelium of blood-vessels; but whether there is actually a basis-membrane between the two is undetermined. The capsule opens into the convoluted tube by a narrow aperture which gradually widens out into the width of the tube.

The intimate structure of the tubules may best be considered in relation to the changes to which they are subject.

The arrangement of the blood-vessels, though important, cannot here be fully described. Most important for our purpose are the interlobular arteries, which supply the cortical portion: these are straight branches which radiate towards the surface, lying in the spaces between the adjacent medullary cones and parallel to the medullary rays; in their course they give off short twigs which form the *afferent arteries* of the glomeruli above mentioned. Before the entrance of the latter into the glomerulus small branches are sometimes given off which break up into capillaries, forming a plexus between the convoluted tubes. The *efferent* vessel breaks up into a network of capillaries which surrounds the convoluted and straight tubules, and is continuous throughout the cortex; uniting again into veins, these vessels reach ultimately a venous trunk (interlobular vein) which passes downwards adjacent to the interlobular artery.

ELEMENTARY LESIONS.

We may now study the elementary lesions to which the various constituent parts of the organ are subject, and, in doing so, we shall follow an order suggested rather by convenience than strictly scientific.

Taking first the Malpighian body together with its afferent arteriole, we pass next to the interstitial connective tissue, then to the vessels, and lastly the tubules.

a. Malpighian Body.

Changes in the glomeruli.—These are very important. They affect (1) the blood-vessels, including the afferent arteriole and capillary tuft; (2) the capsule; (3) the epithelium; and (4) the glomerulus as a whole.

(1) *Blood-vessels.* The capillaries are liable to various affections. In rare cases of long-continued hyperæmia from cardiac hypertrophy, and as a late occurrence in chronic congestion from cardiac or pulmonary disease, the capillaries become permanently distended, their walls thickened and rigid. This condition is the essential one in the induration following long-continued congestion.

Fatty degeneration of the capillaries rarely occurs except in cases of phosphorus poisoning, and occasionally in rapid alcoholic poisoning; it occurs also to a limited degree in some of the late stages of parenchymatous nephritis; as a part of general necrobiosis of the kidney due to obstruction of the renal artery; and secondarily to lardaceous degeneration. It therefore hardly ever comes into the first rank as a sole morbid change. It may also, to a slight degree, occur in simple fatty degeneration in wasting diseases. (*see* Plate ix., fig. 12.)

Lardaceous degeneration * ("amyloid" or "waxy" degeneration, "leucomatosis") nearly always begins in the afferent arterioles and the capillary tufts of the glomeruli (*see* Plate viij., figs. 1—4.). The walls of the afferent arteriole (inner coat chiefly, but also middle) and the walls of the capillaries become swollen, translucent, waxy-looking, and yellowish. The outlines of the capillaries at first become unusually distinct, then blend together into a more homogeneous mass, and as the change advances minute oily granules appear here and there, until at last the greater part or whole of the tuft breaks down into a granular detritus with oily droplets. At the earlier periods the epithelium covering the tuft becomes often unusually distinct,—probably from the difference in refraction of the unaffected protoplasm of the nuclei, from that of the altered capillaries; but also from a change presently to be mentioned. The lardaceous material stains deeply with iodine or methylaniline violet, but the iodine reaction is lost when the granular disintegration commences.

Hyaline swelling of the walls of the afferent arterioles is described by Dr. Klein as one of the early changes in scarlatinal nephritis. (Eighth Report of Med. Off. of Local Govt. Board; and Pathological Transactions, vol. xxviii., p. 430.) The intima appears swollen up here and there into cylindrical or spindle-shaped hyaline masses,

* This is regarded by some (*e.g.*, Dickinson; Wilks) as an infiltration, not a degeneration; the commonly used expression is here employed.

which at some places produce a distinct narrowing of the lumen of the vessel. The capillaries of the glomerulus also undergo a similar degeneration, in the course of which greater or smaller parts of the glomerulus become impermeable, the degenerated parts being at first hyaline and later more fibrous.

Other less important changes need not here be described.

(2) *Capsule of the glomerulus.*—The changes which occur in the capsule, both in its own structure and in the connective tissue surrounding and adjacent to it, are of great interest and importance, for they constitute some of the most essential changes in the granular-contracted kidney. In scarlatinal nephritis, as has been shown by Kelsch, Klebs, Klein, and others, the morbid process starts most frequently around the glomeruli; hence Klebs has proposed the term "glomerular nephritis" for this form.

We may trace the changes which occur in these various conditions by the aid of the drawings (*see* Plate viii., figs. 9—12, and Plate ix., figs. 1—3.)

The most common changes have all as their result a thickening of the capsule. They may occur in three ways: either by nuclear growth around the glomerulus, with consequent contraction, by swelling of the capsule itself, or by nuclear growth internal to the capsule. The latter process appears to be the most common,—the thickening occurring by a multiplication of the endothelial cells lining the capsule, or of those which cover the capillary tufts, or in some cases probably by growth from migrated leucocytes. It is only in the more acute cases that the mode of thickening can be readily traced, especially in post-scarlatinal nephritis and in the more acute form of diffuse interstitial nephritis,—in which the various stages can be watched side by side.

We shall study with the aid of the drawings the several forms of this change and the results upon the contained capillary tuft.

Peri-capsular growth.—In most cases this change is associated with alterations in the capsule itself, when it forms a part of ordinary acute or chronic Bright's disease. But it may be observed alone in acute nephritis, in scarlatinal nephritis, or in the early stages of chronic interstitial nephritis. In leucocythæmia an appearance almost indistinguishable from it is often seen, and the same may be said of syphilitic infiltration in the early stages. We find (as in Plate ix., fig. 16) that with a low power very numerous deeply-stained nuclei are seen densely aggregated around and in the neighbourhood of the glomeruli and their arterioles, spreading outwards into the intertubular textures adjacent. In the case of leucocythæmia a higher power shows that they are merely outwandered leucocytes,—no doubt escaping here because of the higher pressure at this point; but in the other cases mentioned, connective tissue growth no doubt plays an important part.

In the earlier stages of the granular contracted kidney we frequently find a similar localization of the fibroid change which, starting as a growth of connective tissue around the capsule, extends thence outwards, surrounding and constricting the convoluted tubules, and forming a scar-like patch in the cortex. This change is well seen in fig. 10, Plate viii.; *a* is a capsule from which the capillary tuft has fallen out in the preparation; *b*, a mass of fibrous tissue adjacent, with branching connective tissue nuclei; *c* is probably another Malpighian body which has become completely converted into fibrous tissue. In this drawing we may also observe at *a'* the slight internal thickening of the capsule, and the nucleated cells adhering to its inner surface.

It is extremely difficult to assign to the processes of out-wandering of leucocytes and connective tissue proliferation their respective share in the production of this cell-growth. It is not improbable that in some cases obstruction in the glomerulus is the primary change, and the consequent increased blood pressure in the afferent arteriole leads to exudation of blood-plasma and leucocytes. This may be the explanation of its occurrence in scarlatina, gout, lead-poisoning, &c. Dr. Klein (*loc. cit.*) attributes the changes in scarlatinal nephritis to embolic plugging of the arterioles.

Hyaline swelling of the capsule itself has been observed, under similar conditions, associated with other results of irritation of whatever origin. Thus in scarlatinal nephritis, in the earlier stages of chronic interstitial nephritis, and in diffuse nephritis, it is seen alone or in combination. The swelling and thickening varies considerably in degree; when slight the capsule may appear homogeneous and translucent, but when it reaches any marked degree some lamination or fibrillation may soon be observed, and in many cases layers of nuclei are seen between the hyaline layers. The process of thickening appears in many cases to resemble closely that which takes place in the elastic

laminæ of the arteries in endarteritis deformans. Instead of a single delicate hyaline lamina we find a number of superimposed laminæ with nuclei between. It is perhaps unimportant to inquire in what way this thickening occurs; sometimes it is distinctly due to growth from the endothelial cells lining it, which form successive layers, and are more or less rapidly converted into fibrous tissue (*see* Plate ix., fig. 1, and Plate vii., fig. 12.) Comparatively slight thickening is well seen in Plate viii., fig. 9, where it is somewhat fibrillated, and this may be advantageously compared with figs. 10, 11, and 12.

Cell growth in the interior of the capsule.—Figs. 11 and 12, Plate viii., and figs 1, 2, and 3, Plate ix., will illustrate some of the stages of the process.

As we have already hinted, thickening of the capsule may take place by growth of the cells lining its interior, and this process may go on rapidly forming successive lamellæ within one another, the capillary tuft meanwhile becoming shrivelled and wasted, and gradually quite obliterated. But it is very difficult to say that the nuclei or cells covering the tuft do not participate in the change. Fig. 11, Plate viii., and fig. 2, Plate ix., show how this occurs. A multiplication of nuclei over the capillary tuft and inside the capsule is first observed, sometimes so great as almost to obscure the capillaries, and these become at points heaped up between the tuft and the wall. Very rapidly the opposed surfaces become united by cell-growth, the organization of which proceeds from without inwards until the stage represented at fig. 12 is reached, where numerous hyaline lamellæ with interposed nuclei fill the greater part, and at the centre the active process of growth continues.

It is evident that so soon as the adhesion of the capillary tuft to the wall becomes complete the function of the Malpighian body is destroyed. For the performance of its function it is essential that the capillary tuft should be free in the capsule, so that the watery contents may freely transude. When this is thus checked the action of the glomerulus has ceased, and there remains no other issue than atrophy or sclerosis.

This change has been very completely studied in its early stages by Dr. Klein (*loc. cit.*) in scarlatinal nephritis. My own observations, made independently at about the same time, had led me to the same view, and they appear to afford an explanation of the anomalous course of some cases of scarlatinal dropsy, which can here be only briefly indicated. The nuclear growth appears to occur quite early in the disease, yet often the symptoms of nephritis appear late, and there may be no perceptible albuminuria during the acute illness. It is clear that some little time must elapse before the cell proliferation leads to complete adhesion and obstruction of the outflow of water; at a certain period of the growth this takes place. Every glomerulus thus destroyed is an obstacle to the blood-flow through the kidney, and a cause of watery accumulation and increased blood-pressure throughout the system. Each glomerulus, too, dominates a convoluted tubule, the function of which is correspondingly impaired, if not destroyed. And it is probable that this alone may in many instances be sufficient to account for the subsequent results. This change will be more fully detailed under the head of scarlatinal nephritis.

In its ultimate evolution thickening of the capsule, with atrophy of the capillary tuft, leads to complete induration and the transformation of the glomerulus into a fibrous nodule.

Other changes may, however, occur in the Malpighian body together with or independently of this change. One of these is the accumulation of watery or colloid material in the capsule, and the changes which may lead to the formation of cysts.

Such are the more important changes which occur in the Malpighian body; there are others, such as the results of embolism, &c., which space forbids us here to mention.

b. Interstitial Connective Tissue.

The interstitial connective tissue of the kidney varies much in amount and importance in the different parts of the organ. It is most abundant in the papillæ, where it forms the sole wall of the collecting tubules for a short distance up from the tip, thence it is continuous along the walls of the vessels and tubules. The quantity of fully-formed connective tissue in the cortex, especially around the convoluted tubes, is small; in well-injected kidneys the capillaries, with the tubules and glomeruli, appear to compose almost the entire structure. The walls of the capillaries and tubules, &c., are of course composed of some modification of the tissue, but of interstitial connective tissue there is only a very delicate network of cells enclosing the lymphatic spaces

which everywhere permeate the interstices. Some have, therefore, maintained that there is no connective tissue proper between the convoluted tubes of the cortex, but this, although true as regards fully-formed fibrillated connective tissue, is not true of its more elementary cellular form. The controversy is, in reality, one grounded on an erroneous explanation of a pathological fact. It is maintained, on the one hand, that in the granular contracted kidney the fibrous wasted patches are the result of an interstitial overgrowth of connective tissue; on the other, that they are simply the remains of atrophied tubules and capillaries. We shall endeavour to show that they may be either one or the other, the proportion of each change varying in different cases. But it does not appear that this fact tells either way as to the presence or absence of connective tissue in the normal condition. For we can hardly doubt now that, even if absent in the healthy condition, new connective tissue might be formed from migrant leucocytes, or that it might, if normally present, remain in an unaltered condition during the progress of other changes in the tubules. The controversy has entered upon a new phase since the researches of Cohnheim and others on inflammation.

The interstitial tissue may be the seat of great overgrowth in the course of inflammation, as we shall see in relation to acute and subacute interstitial nephritis. It is also especially affected in the growth of tumours, &c. A more moderate degree of overgrowth occurs in senile changes, and in conditions of chronic venous congestion. We cannot dissociate the connective tissue from the lymphatics. Hence all growths which especially involve or extend in lymphatic tissue must involve the connective tissue. All irritative and inflammatory processes affecting the vessels or tubules are liable to involve their connective tissue sheath, and thence to extend into the contiguous regions of the same structure. This we shall find to be of common occurrence.

c. Vascular Changes.

These have acquired an especial interest of late years owing to the discussions as to the nature of the change in the granular contracted kidney. To these conflicting views we can only allude in passing; space forbids discussion of the question. But all changes in the vascular apparatus are highly important in renal pathology, owing to their effects upon the function of the kidney. Any change which impedes the ready expansion and contraction of the arterioles disturbs the function by preventing that graduation of blood-pressure which is so highly important for the outflow of water, and whether the change be in the arteries of larger size, causing at one time too low a pressure, or not allowing at another of the turning off of blood supply, or in the minute arterioles causing increased tension in the larger, any widespread change in their structure leads to serious results. We must, however, leave the consideration of the nature and mechanism of these results, and limit ourselves to a bare statement of the known facts.

Arteries.

Endarteritis and Atheroma. — The larger arterial branches are, like the other arteries of the body, subject to chronic endarteritis and atheroma. The change differs in no respect from that seen elsewhere in the body; the inner coat becomes swollen irregularly by a multiplication of the hyaline laminæ between the internal elastic lamina of the middle coat and the endothelium; the cells lying between them undergo multiplication and subdivision, in some cases to a marked degree, in others to a less extent; lastly, the deeper layers (*i. e.*, those nearest the middle coat) undergo fatty degeneration, caseate, or become calcified. The usual results, loss of elasticity of the walls, narrowing or partial occlusion of the channel, and possibly secondary thrombosis, are then observed. Together with endarteritis, some changes may often be seen in the middle and outer coats. The latter becomes thicker, more fibrous, and often surrounded by an area of fibroid change. The middle coat is in some cases distinctly thickened. The precise nature of the change in the muscular layer is difficult to ascertain. It often bears the appearance of distinct muscular hypertrophy; the layers of muscular fibre cells appear more numerous than natural, preserving, however, their ordinary character. In other cases a larger proportion of connective tissue appears to be intermingled with the muscular bundles; and, in my opinion, there is hyperplasia both of the muscular and connective tissue elements. It can hardly be believed that the appearance of true hypertrophy is in all cases delusive, though it may well be that the hyperplasia of the

muscle-cells is not always attended with a corresponding functional result. In what way this is related to the change in the inner coat, and what its results are upon the rest of the tissues, we must not here discuss. In some cases the muscular coat is alone affected, yet appears to remain rigid; it may be that a peculiar change associated with increase of bulk, but diminished activity, is here the condition. This is seen in association with miliary aneurisms in the brain. (Charcot et Bouchard, *loc. cit.*) The occurrence of true muscular hypertrophy has been denied by Charcot, but Dr. Klein has observed proliferation of muscular nuclei of the afferent arterioles of the glomeruli occurring early in scarlet fever.

In the smaller arteries and more minute arterioles a hyaline swelling of the intima appears to replace the multiplication of laminæ seen in the larger arterioles. Though unlike in aspect, this change probably coincides in nature with the latter change, differing only on account of the lesser degree of differentiation of structure in the smaller vessels (*see* fig. 10, Plate ix.)

Lardaceous degeneration is observed in the larger arteries at the base of the pyramids in the later stages of that affection. The vasa vasorum are first involved, but later some bundles of muscular fibres, or even large tracts of the middle coat, are found to have undergone the peculiar change.

Capillaries.

Glomeruli.—These are best considered in relation to the Malpighian body as a whole. (See p. 3.)

Intertubular plexus.—The changes which affect these important capillaries have been less studied than those of the larger arteries and the glomeruli. They supply the part of the organ which secretes or excretes the special constituents of the urine, and are therefore of capital importance. Swelling of the tubules by catarrh or accumulation compresses and obstructs them. In chronic renal congestion from cardiac disease they undergo distension, become more rigid, and their walls thicker than natural. But the changes which occur in their structure are interwoven with those in the connective tissue and the walls of the tubules, with which they are so closely connected—in some parts indeed so intimately that, as has already been mentioned, they may be regarded as forming a great part of the framework of the labyrinth of convoluted tubes. In interstitial nephritis, whether by change in their proper coats or of the surrounding connective tissue, they become involved in the progressive fibrous change which, usually starting in the glomerular capsule, invades the secreting structure and obliterates the capillaries. With the advance of this destruction of vascular supply the tubules wither and shrivel.

In the more acute forms of diffuse interstitial nephritis these vessels seem to take a more active part in the process, a general exudation of lymph probably taking place along their course.

The other important changes to which they are subject are lardaceous degeneration, less frequently seen in them than elsewhere, and rarely fatty degeneration.

Vasa recta and capillaries of the medullary portion.—It will be remembered that the vascular supply of the medullary portion is, to a large extent, separate from and independent of that of the cortex, and grouping together the vessels which convey this supply under the name of *vasa recta*, their pathological changes may be conveniently studied separately. These vessels are mainly derived from the arterial branches at the base of the pyramids, which also give off the interlobular arteries. They pass downwards between the bundles of straight tubules and divide into bundles of straight capillaries for their supply. Together with these are other branches from the efferent arterioles of the glomeruli in the neighbourhood of the medulla, which form other arteriolæ rectæ and are similarly distributed. The capillary plexus thus formed communicates freely with that of the cortex, especially with the elongated meshes which surround the bundles of straight tubes.

These vessels are probably subject to changes similar to those just described as affecting those of the cortex. But the only morbid change which is especially prominent here is lardaceous degeneration. In the later stages of this change, and also in some cases at an early period, it is found that the vessels which run between the collecting tubes of the papillæ stain very readily with iodine, especially those nearest the tip of the papilla.

Veins.—No special changes, beyond those due to chronic congestion, have, so far as we are aware, been discovered in the veins.

Syphilitic disease of the renal arteries.—(*Vide* Syphilitic disease.)

d. Uriniferous Tubules.

The changes in the *uriniferous tubules* are necessarily of great importance in renal disease. These constitute not only the proper excreting structure of the organ, but through them the products of excretion must find their outlet. They are liable to be affected by all the changes to which the organ is subject, and so long as they remain healthy there may be extensive interstitial changes with but little functional result.

A part of the morbid changes which they undergo are referable to extraneous causes, and not to a primary alteration in their own structure. Such are the results of degeneration of the glomerulus, of constriction by fibrous tissue, and the like; some however, are due to the direct action of morbid conditions on their own proper structure. In the study of these changes we must distinguish the several parts into which each tubule is divided, parts not only structurally, but physiologically and pathologically distinct, viz., the convoluted tube, the looped tube of Henle, the intercalated portion, and the straight or collecting tubes. The changes may also be grouped as they affect the membranous wall, the epithelium, or the contents; and to these we may add the results of changes around them.

It will be well to take separately each of the different parts of the excretory tract, and treat of its morbid changes.

The *convoluted tubes* form the first part of the excretory tract, each extending from its Malpighian body to the looped tube of Henle, where it becomes suddenly contracted. The wall or basis-membrane is continuous with the capsule of the glomerulus, which may indeed be regarded as an expansion of the tube; this opens into it by a narrow orifice, which widens out gradually. In structure the basis-membrane is probably analogous to the walls of capillaries, but nuclei can very rarely be seen in it. (Ludwig.) It is in close contact with the capillary meshwork which surrounds the tubules, but separated, according to Ludwig, by a lymphatic space. The *epithelium* of the convoluted tubules has a very peculiar construction; it is composed of a layer of protoplasm, with nuclei arranged at pretty regular intervals, but with a comparatively indefinite division into separate cells; there is at least no distinct cell-wall. (Von Wittich.) The protoplasm is highly granular and dusky, differing markedly from that of the straight tubes, which is clear and more highly refractile. Hence, even in healthy conditions, the nuclei are not always visible without staining. This granular appearance of the cells is due, according to Heidenhain, to their being composed of rods lying parallel to one another, and vertical to the wall of the tube. But although there may be some doubt as to the exact structure, we find that in disease the changes in the epithelium are such as to lead us to regard the cells as distinct and independent, although so closely ranged together, and devoid of distinct cell-wall.

Morbid changes in the convoluted tubes.—The *basis-membrane* is comparatively little affected alone. It is sometimes swollen and more distinct, very rarely it undergoes lardaceous degeneration. In old age it may be more distinctly fibrous. But nearly all the changes are those associated with intertubular fibrosis; and it is difficult to say what part the wall of the tubule itself plays in this process. It is not improbable that it may undergo changes similar to those which take place in the similarly-constructed Malpighian capsule.

Epithelium.—Simple separation of the epithelium from the basis-membrane as a uniform layer is a change often observed in microscopic preparations. It is probably not to be regarded as evidence of a morbid change. This epithelium has much less cohesion with the basis-membrane than most epithelia; hence it readily comes off as a protoplasmic ring.

Simple *fatty degeneration* of the epithelium is of rare occurrence. It may occur as the result of the direct action of some morbid poison, such as phosphorus, or more slowly in alcoholic poisoning, though we have little positive evidence as to the latter. It also takes place in necrobiosis of the tissue, due to obstruction of vascular supply, whether of the whole organ or only of a part. It does not hold an important rank as a primary morbid change. It occurs in chronic wasting diseases,—cancer, diabetes, phthisis, &c., a fact, we believe, first noticed by Dr. George Johnson. (*See* fig. 13, Plate ix.)

Lardaceous degeneration is also of somewhat rare occurrence, though met with in some cases of the later stages of waxy kidney. Such a condition is seen in the drawing, fig. 3, Plate viii., from the kidney of a phthisical patient affected

with marked lardaceous degeneration and some fatty change. The cortical substance was mottled with small, opaque, yellowish white spots, mainly due to the change here seen in the epithelium. The epithelium of the convoluted tubes presents various stages of the degeneration: in some parts of the tubes it is nearly healthy; in others the cells are swollen into irregularly anfractuous masses, highly refractile, and presenting in a marked degree the typical features of lardaceous degeneration. Side by side with this lardaceous change is seen some fatty degeneration, both of the cells and of the connective tissue. Waxy degeneration, in fact, rarely affects the epithelium until the vascular system has been long involved, and a general malnutrition of the tissue leading to fatty change is coincident with it. It is rare to see waxy degeneration of the epithelium so advanced as in this case, and some observers (*e. g.* Cornil) state that they have never met with it.

Cloudy swelling, granular and fatty degeneration, and catarrh.—Under the influence of a large number of morbid conditions the epithelium swells, becomes more granular and opaque, and assumes the condition known as "cloudy swelling." This occurs in many acute specific and other fevers, in pneumonia, and in other conditions of general blood-poisoning, such as acute yellow atrophy of the liver. The change is seen in Plate viii., figs. 15 and 16. The swelling of the cells is very irregular, so that the inner line of the epithelial layer is uneven and ragged-looking; the protoplasm is more turbid and granular than natural. Not unfrequently the nuclei are even better seen in the early stages than in the natural condition; and the distinction between individual cells, which is often not apparent in the normal state, comes out clearly under the morbid influence.

A further stage in the same direction of change is that which occurs under more intense irritation, and especially in the various forms of Bright's disease. These changes are analogous to those which take place in other protoplasmic masses, especially when highly organized, in their course to degeneration and death. The protoplasm swells, becomes more granular, then quite opaque, and minute oily molecules make their appearance; these sometimes coalesce into larger and more distinct oil-droplets as the degenerative change advances. The nuclei are then obscured or lost. This is what takes place in the renal epithelium during the progress of acute catarrhal nephritis and its sequelæ. Together with this, multiplication and fission of the cells is observed; these accumulate in the tubule and block up its channel.

These changes are well seen in drawings, figs. 15—18, Plate viii., and fig. 8, Plate ix.

Figs. 15 and 16 show simple "cloudy swelling."

Fig. 17 is from a case of acute nephritis, fatal at a very early period: the cells of the convoluted tubes *a* are here seen to be more granular, their nuclei still visible on staining, but otherwise obscured; the cells appear to have multiplied, and many of them, of angular shape, fill up the central part of the tube.

Fig. 8, Plate ix., is a later stage, from chronic tubular nephritis, the so-called fatty kidney, in which the epithelium of the convoluted tubes has become still more granular; distinct oil-drops may be here and there seen with higher powers, and the nuclei of many of the cells cannot be discerned even with the aid of reagents, showing their complete death. It is, however, by no means exceptional to find that, even in the latest stages of this change, few or no oil-droplets are formed; hence the term "fatty kidney" as applied to this form of disease is unquestionably erroneous. When this late stage of degeneration has been reached the broken-down cells may become moulded together and form a cast, or may possibly be absorbed. We shall see that there is reason to believe that similar changes take place in the granular contracted kidney.

The nature of this catarrhal change, the immediate cause of the swelling and fission of the cells, and the mechanism of the cell multiplication, are matters on which some difference of opinion exists. The swelling of the cells and the degenerative changes which they undergo are by many regarded as due to the direct effect of inflammation upon them; but some pathologists regard these changes as necrotic processes due to the deranged vascular conditions in acute nephritis, and to destruction of blood supply in the case of chronic interstitial nephritis. The actual fission and multiplication of the epithetial cells is also denied by some; the evident accumulation of smaller cells in the tubes is explained partly by the breaking down of cells, the fragments of which are carried down farther into the tubules, partly by the migration of leucocytes from the capillaries into the tubes. The supposed breaking down and desquamation of the epithelium is the ground

for the use of the term desquamative, as applied by some to the acute or catarrhal nephritis; we believe that, in so far as the term is intended to imply that a complete desquamation of the epithelium occurs in any part of the convoluted tubules, it is grounded upon insufficient evidence. The erroneous interpretation of the apparent emptiness of the tubes in sections, due, as has already been explained, to post-mortem changes, or to the more ready detachment in certain pathological conditions, has no doubt contributed to this view. Another cause of error is the appearance in the urine of so-called epithelial cells, supposed to be derived from the epithelium of the convoluted tubes—a view which the more accurate knowledge of the structure of the kidney, and of the characters of these cells, should have served entirely to dispel.

In spite of the denial of some distinguished authorities, there seems to be little doubt that actual multiplication of the epithelium does occur in catarrh, and that the newly-formed cells, which are smaller than the original cells, accumulate in and block up the passage of the tubules.

Under certain other more chronic conditions the epithelial cells of the convoluted tubules become altered in shape and character; this is especially the case in the more acute forms of diffuse interstitial nephritis. Some of the tubes are much dilated, owing to the retraction of the fibrous tissue which surrounds them, as in fig. 14, Pl. viii., and fig. 5, Pl. ix.; others are constricted at one point, and in consequence dilated above the point of stricture. Where the distension is slight and gradual the epithelium may be simply flattened out so as to form a thinner layer. But frequently the epithelial cells become flattened and much altered in shape. More elongated or spindle-shaped cells appear to replace the normal epithelium, especially when the intertubular spaces are occupied by abundant small-celled growth of connective tissue. It seems doubtful whether this change so frequently occurs in the convoluted tubes as the other tubes, but it is extremely difficult to distinguish the several kinds of tubes from one another in so advanced conditions of disease; for their shape, calibre, and relative arrangement are completely distorted. The change has been described as a process of regeneration of the epithelium, and is so figured by Bartels after Colberg. (Ziemssen's Encyc., English edition, vol. xv., p. 347). It is seen in figs. 5 and 6, Pl. ix. Dr. George Johnson has also described a similar regenerative process after desquamation. Whether it is so may be doubted, but the possibility cannot be denied.

There is often seen, under similar conditions with this change, a peculiar degeneration of the epithelium, which may be described as colloid or mucoid. In the tubes are seen sometimes very abundant large globular bodies of gelatinous appearance, with one or two nuclei, or in some cases with no visible nucleus. These are well seen in fig. 6, Pl. ix. Similar globules are sometimes seen in the Malpighian body between the glomerulus and the capsule, and it is a question whether they may not originate from the epithelium of the glomerulus, and not solely from that of the tubes. It is considered by Rindfleisch and some others that these bodies unite to make up the gelatinous casts often found in the tubules.

Looped tubules of Henle.—These are continuous with the convoluted tubes, each of which narrows gradually to form the descending branch of a looped tubule, which descends to near the base of the papilla. The descending portion is a very narrow tube, lined by flattened epithelium with prominent nuclei, and somewhat resembles a capillary when seen on section, though the cells are much more prominent. Either at the bend of the loop or at some point near it the tube enlarges slightly, and the character of the epithelium changes, becoming much more voluminous and granular, and this condition continues through the whole of the ascending branch of the tube. The epithelium of the ascending limb of the looped tubes closely resembles in its structure that of the convoluted tubes; it is composed of a highly granular and dusky epithelium, which, according to Heidenhain, has a similar striation. The individual cells are indistinct, and the nuclei somewhat irregularly arranged.

Pathological changes in the looped tubules.—We know little of any changes specially affecting these tubules, but from what we do know there appears to be a close sympathy both in function and in the effects of disease between their ascending portion and the convoluted tubules. This relation is suggested by the very close resemblance in structure of the epithelium in these two sets of tubes, a structure which is analagous to that of some other specially endowed secretory cells. It has been shown

by Heidenhain that if indigo is injected into the blood it is excreted by these epithelial cells of the looped and convoluted tubules alone, and that if the circulation in the kidney is sufficiently arrested to check the outflow of water, or a similar result is attained by ligature of the ureter, these cells alone become stained by the colouring agent.*

Such observations as have been made in disease confirm this view of the analogy of the ascending branches of the looped tubes with the convoluted tubes. In phosphorus poisoning the epithelium is said to be especially affected, and in acute catarrhal nephritis the various stages of catarrh are here well marked, as in the convoluted tubules.

We know nothing of any special changes in the walls of the looped tubules. The epithelium of the descending portion probably also shares in the catarrhal process, though to a much less degree than the ascending.

On the other hand, the peculiar arrangement of the looped tubes, and their narrow calibre and long course, have possibly a very important mechanical bearing on the excretion of the urinary products in disease of the organ, and on the formation and elimination of casts, and may materially impede the passage of urine when the organ is swollen.

Straight or collecting tubules.—These are united with the ascending limb of the looped tubes by an intermediate somewhat contorted tube, the intercalated portion, which has an epithelium transitional in character between that of the convoluted and the straight tubes. The collecting tubes unite at acute angles to form larger tubes until they reach the papilla. They are circular, composed of a distinct membranous wall lined by clear epithelium with distinct nuclei, which in some of the larger tubes is more or less cylindrical, but for the most part cubical or spheroidal. Their channels are relatively large.

Pathological changes.—The walls of the straight tubes are liable to become thicker and more fibrous, especially in connection with an interstitial fibroid growth, though at times independently of it.

Lardaceous degeneration of the walls occurs usually at an advanced stage of this disease. It affects first and chiefly the portion in the medulla, much more rarely that in the cortex, and very frequently the degeneration of the adjacent capillaries may be mistaken for it.

* Heidenhain, 'Versuche über der Vorgang der Harn absonderung.' Pflüger's Archiv, 1874, Bd. 9, p. 1.

The epithelium of the straight tubes is far less liable to degeneration from ordinary causes than that of the convoluted tubules, and the same may be said both of catarrhal changes and of those which are due to interstitial growth. Not unfrequently, indeed, they may be seen to persist unaltered in the midst of a tract of newly-formed connective tissue, though they are liable to become stretched or distorted.

Catarrhal changes occur both during the late stages of catarrhal nephritis and in the changes consecutive to interstitial nephritis, as well as by extension upwards of the catarrhal process from the pelvis. Very frequently these tubes are found to be filled with small round cells, which have come from above and merely accumulated in them. In advanced catarrhal changes their own epithelium may be entirely removed, the channel being filled with cells usually of small size, as in fig. 18, Pl. viii., which are derived either from the epithelial cells themselves or from exuded leucocytes. The other changes in these tubules are of much less importance, and will be described in connection with the diseases in which they occur.

Casts in the renal tubules.—These may conveniently be considered together. The casts formed in the looped and straight tubes probably correspond with those which are found in the urine during life. It is believed by many that casts formed in the convoluted tubes cannot under any circumstances pass into the urine, owing to the small calibre and long course of the looped tubes which they must traverse. But it must be remembered that these tubes are elastic, and that although the completely formed casts may not pass through the whole system of tubes, the elements from which they are built up in the straight tubes may be derived from the convoluted tubes. Beyond question, however, the common source of the casts found in the urine is that part of the system of tubules which extends from the ascending branch of the looped tube to the papilla.

Casts are often found in the convoluted tubes of diseased kidneys, more especially in the chronic forms. *Blood casts*, composed of blood more or less altered by its stay in the tubes, are most frequently present in acute nephritis, and more rarely in cases of severe congestion. The blood is probably derived from the glomerulus, and sometimes the space between the capsule and the capillary tuft is found to be filled with

blood. When by the long stay in the tubes the blood becomes altered and in parts absorbed, a more or less crystalline mass, mainly composed of blood pigment, remains, and forms what is called by some a *Haematoidin* cast. *Epithelial* casts in the ordinary sense of the word "cast" are hardly seen in this position; not uncommonly the tube is more or less completely filled with imperfectly-formed or degenerated cells, mingled with leucocytes, as already described, but this condition can hardly be described as cast-formation. They may also be filled with a sort of granular détritus, which is probably composed of broken-down cells mixed with an albuminous exudation. Perhaps the most common casts in the convoluted tubes are the large homogeneous, translucent, waxy-looking casts, which are variously described as *gelatinous*, *colloid*, and *waxy*. These form masses, often of considerable length, which nearly fill the channel of the tube in which they lie; they are highly refractile, of somewhat yellowish colour, and stain deeply with colouring materials, such as carmine, logwood, or aniline dyes. Their nature and mode of formation have been the subject of much dispute. Many pathologists have considered them to be of albuminoid nature—that is, composed of some modified form of albumen; some regard them as fibrinous, others as colloid, and not a few as lardaceous. Their precise chemical composition is unknown, but there is some probability in the view that they consist of a modified form of fibrin derived from the blood plasma, which forms casts in the tubes and undergoes a chemical change in consequence of long soaking in the acid urine. Whether, however, the original exudation is albuminous or fibrinous must be doubtful. Klebs suggests that a fibrinogenous material may be excreted and become converted into fibrin by means of a fibrinoplastic substance excreted by the epithelial cells. Another view of their nature has been suggested by Rindfleisch, who regards them as due to the coalescence of altered epithelial cells which have undergone a colloid degeneration. This view has not been very commonly accepted, but observation has convinced me that such an origin is very probable for some of them, although it may not be the cause in every case. These casts very commonly shew upon the surface markings which look very much as if they were due to the massing of numerous elements, but this appearance may possibly be due to the fact that they have been moulded in contact with the epithelial tube-lining. It is also difficult when they are *in situ* to eliminate the source of error arising from looking through the epithelial covering. (See fig. 20, Pl. viii.) But in spite of this, numerous observations lead me to believe in this method of formation, and a point in favour of it is the occurrence in many cases where they are present in large numbers of bodies in the tubules (as in fig. 6, Pl. ix.), which have all the appearance of epithelial cells which have undergone colloid or some similar degeneration. (They are represented as too granular in the drawing).

Although these casts are often called "waxy," are of waxy appearance, and stain a deep brown with iodine, they are not composed of lardacin, and give a different reaction with methyl-aniline violet. Dr. Dickinson, who maintains the lardaceous nature of many of the casts which are found in lardaceous disease of the kidney, allows that the majority of them are not composed of lardaceous material. True lardaceous casts are probably very rare, and exist, even in the waxy kidney, probably solely by the coalescence of epithelial cells which have undergone lardaceous degeneration.

These large colloid or "waxy" casts are found in nearly all the forms of acute and chronic Bright's disease. They are especially abundant in the subacute forms of interstitial nephritis. They may be seen represented in figs. 4, 5, 6, 7, 17, 19, and 20 of Plate viii., in different forms of Bright's disease. Possibly the stasis in some of the tubes, which is produced by the contraction of fibrous tissue, favours the gradual degenerative changes needed for their production.

In the looped and straight tubules we also find blood casts and waxy casts, but the latter far less frequently than in the convoluted tubes. The forms which predominate here are the hyaline, epithelial, and exudation casts, which are found in the urine. As these are so commonly described in clinical works they will receive but brief notice here.

Hyaline fibrinous casts sometimes exist in the looped tubes of healthy kidneys (Klebs), but do not appear in the urine. They have also been observed in the straight collecting tubes of healthy dogs. But in diseased conditions they are found in great abundance both in the looped tubules and in the straight tubes. They are

usually translucent, hyaline, with little or no striation, and not of high refractive power. Where they co-exist with active inflammatory processes they may form the centre of casts composed of exudation corpuscles, or altered epithelial cells; and where degenerative changes of the epithelium (see fig. 19, Pl. viii.) predominate, they become covered with granules, and sometimes with oil-globules. The latter is much less frequent than usually supposed; it has been shown by Dr. Stone that with the polariscope the apparently oily particles have a very different action on light from that of oil-globules. Hyaline casts sometimes contain crystals, or other elements present in the tubules.

Epithelial casts, found most frequently in the straight tubes, consist either of masses of altered epithelial cells or of these mixed with leucocytes, often with a central core of hyaline cast. The nature of the "epithelial" cells is doubtful; that is to say, whether they are derived from the epithelium directly by subdivision (*Epitheleiterung*), or from leucocytes exuded into the tubes.

It may be safely asserted that the epithelial cells of the convoluted tubes hardly ever, if at all, appear in the urine, and that even epithelial cells, recognisable as such, of either the looped or straight tubes, do so but rarely in the form of casts. By far the commonest are small round cells hardly distinguishable from leucocytes. (See Pl. viii., fig. 18).

Other forms of casts are occasionally, but more rarely, found.

Uric acid or *urate of ammonia* deposits are frequently seen in the kidneys of newly-born children. On section of the kidney in the usual way clusters of yellowish or brick-red lines are seen radiating from the tips of the papillæ towards the bases of the pyramids, reaching sometimes a considerable distance. In rarer cases they are found only towards the base of the pyramid, near the junction of the cortex with the medulla. On microscopic examination these lines are found to be due to masses of crystalline material occupying the straight collecting tubes, and often projecting into the pelvis at the tip of the papilla. They are either finely granular, or made up of larger, irregular, angular masses, or sometimes of more rounded bodies. These casts were long ago described by Rayer, and later by Schlossberger and Virchow. According to observations collated by Klebs they are never observed in children born dead, nor unless the lungs have been expanded. They are most frequently observed between two to fourteen days after birth, but occasionally earlier and later, and, according to Virchow, even so late as at from three to five months of age. Concerning their cause much dispute has taken place; the most probable explanation seems to be that which attributes them to a physiological process, the increase of urates consequent on commencing digestion, warmth production, &c., together with, probably, defective respiration.

A deposit of urates in a scattered form through the kidney is not uncommon in the granular contracted kidney, and may reach a great degree. Very often this is spoken of as a peculiarity of the "gouty" form, but there is no evidence that it is more common in cases where gout is present than where it is absent. These deposits are commonly found in the cortex, and are in the connective tissue, not in the tubes. Urate deposits may, however, be found in the straight tubes in rare cases.

Bilirubin casts are occasionally found in the tubules in cases of long-standing jaundice. They consist of granules or minute crystals, forming masses which nearly fill some of the tubes. They occur chiefly in the straight tubes of the papillæ, but may also be found in the other parts of the tubes. Granules of similar nature may be found in some cases scattered widely through the organ; sometimes in the epithelium of the convoluted tubes. They occur likewise in newly-born children, though more rarely than urate casts.

Calcareous casts, composed chiefly of carbonate of lime, are found, according to Klebs, in the straight tubes in the papillæ, chiefly in old people, and in cases of absorption of the bones. They may in such cases produce thick clusters of white striæ extending from the tip of the papilla a variable distance into the medulla. They consist of dark, strongly refractile globules or nodular masses, which join together to form nodular rods. Masses of matter which contain carbonate of lime are also occasionally met with in the straight tubes of the cortex, even in apparently healthy kidneys. They appear to consist of an albuminoid basis, infiltrated with carbonate of lime. With colouring reagents they stain very deeply, but may usually be distinguished from simple casts by the irregularity of the staining, some parts being much more deeply stained than others. They

are also distinguishable by the aid of dilute acids.

Cyst formation, which may occur at the expense either of the tubules or the glomeruli, will be described under the head of cystic disease.

DISEASES OF THE KIDNEY.

Classification.

Having studied the elementary lesions of the several parts, we may proceed to their grouping together into the various forms of disease of the organ. In doing so it must be premised that no absolute line of demarcation can be drawn between all the forms of disease, that they are often associated in the same individual, and that cases of the same disease vary greatly in the extent and degree of the pathological change, and thus present very diverse morbid appearances. The classification is therefore, to some extent, arbitrary, especially in so far as it relates to Bright's disease proper.

Moreover, it must be understood that this *résumé* refers mainly to the diseases which especially involve the essentially glandular constituents of the kidney; that many conditions, as, for example, some parasitic diseases, renal calculi, pyelitis, &c., do not come within the scope of the present work, and are therefore not included in the classification.

Classification of principal morbid changes in the kidney:—

I. Atrophy and Hypertrophy.

II. Degenerations. 1. Molecular.
2. Fatty.
3. Lardaceous.
4. Cystic.
5. Calcareous.
6. Colloid.

III. Changes associated with altered conditions of blood supply:—
- Anæmia.
- Hyperæmia, active and passive; acute or chronic.
- Congestive induration.
- Results of obstruction of vessels; thrombosis and embolism.
- Suppurative changes:—
  - Simple.
  - Pyæmic.

IV. *Bright's disease* proper:—
- Acute or parenchymatous nephritis.
- Scarlatinal nephritis.
- Subacute interstitial nephritis.
- Chronic interstitial nephritis.

V. Infiltrations and morbid growths:—
- Syphilis.
- Tubercle.
- Lymphadenoma.
- Leucocythæmia.
- Fibroma.
- Sarcoma, cancer, &c.

VI. Changes due to pyelitis, obstructed outflow, &c.

The anomalies in form, position, and relations of the kidneys do not involve any necessary structural alteration, and are therefore not here considered.

Atrophy of both kidneys occurs in old age, when it is often associated with degenerative changes, and in long-continued wasting diseases, though with far less frequency than atrophy of most of the other glandular organs: the atrophy which results from obstruction of the renal artery is of more importance. Under this head must be classed many of the cases in which one very small and one large kidney are found. In some cases this is due to imperfect development of organ and vessels, but in not a few cases there is evidence that the artery has become partially occluded after development of the organ, and the kidney has consequently atrophied. A similar effect may be produced later in life by narrowing of the vessel by disease, but this is of much rarer occurrence. These cases must be distinguished from those in which one kidney, together with its vessels and ureter, are congenitally deficient.

It has also been experimentally proved by Buchwald and Litten that ligature of the renal vein in the lower animals is followed by atrophic changes in the corresponding organ, with hypertrophy of its fellow. (Virch. Arch., vol. lxvi., p. 145.)

Hypertrophy of one kidney may take place as a compensatory occurrence when the other is atrophied, and the organ may under such conditions reach a size much larger than twice the normal. It is asserted that hypertrophy may also occur under the stimulus of great functional activity, such as exists in diabetes; but this requires further investigation.

Hyperplasia of the epithelium is also said to occur under physiological conditions, but upon doubtful evidence. As a pathological occurrence in tumour formation it will be again referred to.

DEGENERATIONS OF THE KIDNEY.

1. *Molecular* or *parenchymatous* degeneration (*granular* degeneration of Klebs) occurs in a large number of diseases, especially in fevers of all kinds, and in pneumonia; as well as in other conditions which derange the blood supply or the excretory functions. The change has already been partially described under the name of cloudy swelling. The kidney as a whole is usually swollen, the cortex being mainly enlarged; it may be congested, or of a pinkish white colour, the medullary rays, which are but little affected, standing out distinctly from the regions of convoluted tubes, which are usually paler than natural and somewhat swollen. The epithelium, chiefly of the convoluted and looped tubes (ascending branches), is swollen and much more granular than natural. (See p. 9.) The epithelium of the straight tubes is rarely if ever affected to a marked degree from these causes alone.

This condition is often described as an early stage of Bright's disease, and is no doubt very closely allied with it, but it is not necessarily accompanied by albuminuria, and often—usually indeed—completely subsides. But it may go on to Bright's disease. Perhaps the best way to put the relation to Bright's disease is to say that cloudy swelling occurs at the onset of acute Bright's disease, and also under numerous other morbid conditions; but it is not of the essence of the disease, only a common result of different processes. All highly endowed protoplasmic elements of organs are liable to a somewhat similar change when their nutrition or function is deranged.

2. *Fatty* degeneration.—Simple fatty degeneration of the kidney occurs, as was first pointed out by Dr. George Johnson, in the course of wasting diseases, such as phthisis, cancer, diabetes, &c. Here the process is probably a purely necrotic one, due to defective nutrition.

It may also be caused by poisons, such as phosphorus, alcohol, &c.

In the form which results from wasting diseases the organ is usually of its normal dimensions and shape, though it may be somewhat wasted. The general appearance is not greatly altered, but the cortex on section is of more or less yellowish colour, slightly greasy to the touch, and in some cases mottled, owing to the contrast of the tubes filled with fatty epithelium with the blood vessels.

The morbid change consists solely in a true fatty degeneration, which affects principally the convoluted tubules, but in a less degree the other tubules, and more slightly still the stroma and the capillaries.

The change thus produced is well illustrated by the specimen from which figs. 13 and 14, Plate ix., were taken. The case was one fatal from cancer of the stomach with secondary cancer of the liver. The epithelial cells of the convoluted tubules (fig. 14) are swollen; many of them when isolated appear rounded or ovoid, and more or less entirely composed of oil-globules, some of large size. Side by side with these are seen some cells, but little altered, the nuclei distinct, only a few minute fat molecules being apparent. Viewed as a whole the convoluted tubes appear to be filled with masses of granular and fatty material, or with oil-globules, the swollen cells coalescing, and their individual outline being obscured. Hence on examining a fresh section in water with a low power, as in fig. 13, the outlines of the convoluted tubes appear of very dark colour, an appearance due to the masses of oil-globules and their high refractive power. Minute oily specks were also seen in the walls of the capillaries in this kidney.

An equal degree of fatty degeneration is probably never seen in the so-called fatty kidney consecutive to acute nephritis.

The most extreme fatty degeneration occurs as a result of poisoning by phosphorus, and more rarely by alcohol. The epithelium of the convoluted and looped tubules, together with the capillaries of the glomeruli, and even nearly all the structures of the organ, may be involved.

An equal degree of fatty change may sometimes be observed as a result of acute obstruction of the renal artery by embolism or thrombosis.

Fig. 12, Plate ix., shows the change which occurs in advanced alcohol poisoning.

3. *Lardaceous* degeneration of the kidney ("amyloid" or "waxy" degeneration, "leucomatosis") is almost invariably associated with a similar degeneration in other viscera, and is usually secondary to chronic suppurative disease or to syphilis. In the majority of cases following long-continued suppuration the kidney is affected to a less degree than the liver and spleen; but in some cases it is the organ chiefly attacked, and this is especially the case in syphilis, in which the renal disease may exist almost alone.

The nature of this degeneration must not

here be discussed: we may briefly describe the morbid appearances in the kidney at various stages.

In the earliest stage, that of mere degeneration of glomeruli and arterioles (see p. 3), the organ is but slightly, if at all, enlarged; its appearance and consistency are hardly affected; unless on section the glomeruli seem somewhat prominent and glistening. The application of iodine or methylaniline violet alone serve to demonstrate the existence of the morbid change; the double rows of stained dots radiating from the base of the pyramids towards the surface, pointing out the site of the degenerated glomeruli.

By gradual transitions this stage passes into that which is commonly described as the second stage. In this the organ is usually enlarged, its surface still smooth, the capsule readily separable; the density and consistence increased to a considerable extent. On section the organ is usually paler and more translucent than natural, the absence of vascularity, and slight swelling of the cortex, which is somewhat mottled by opaque white and translucent patches, being especially characteristic.

The transition into the third stage is by some described as part of the second; the cortex, more swollen and opaque, is mottled with minute opaque yellowish-white areas, intermingled with more translucent dots and streaks, and various gradations are observed assimilating this form with the kidney secondary to acute tubular nephritis. (See Plate v., fig. 2.) Hence there may be considerable enlargement with opaque mottling of the cortex, or the cortex may be only slightly thickened, and of dull granular aspect, only indistinctly mottled. It is indeed common at this stage to find the lardaceous degeneration combined with degenerative changes in the epithelium similar to those consecutive to catarrh, and with interstitial exudation and fibrosis. Moreover, the parts which have themselves undergone lardaceous degeneration are at this stage often broken down into a granular or oily detritus. It is such changes which have led to the erroneous statement that lardaceous degeneration is a common result or complication of acute Bright's disease, of which there is at least no sufficient proof.

Staining with iodine gives very various results in these more advanced stages. No longer entirely limited to the afferent arterioles and glomeruli, the degeneration affects the efferent arterioles, vasa recta, interlobular arteries, and, later, the hyaline walls of the tubules. The part of the latter first affected, according to Charcot, is the lower part of the collecting tubules in the pyramids. This, however, rarely occurs until the later stages.

In the final stage (3rd of Charcot) the kidney is smaller; it is usually very irregularly pitted on the surface, owing to patches of atrophy and consequent contraction: the capsule is, however, not usually adherent to the surface. On section, the superficial cortex is often much wasted in an irregular manner; it is of somewhat yellowish-white granular appearance, with whitish streaks and veinings. The interpyramidal cortex may be swollen, and is more mottled than the superficial part.

On staining with iodine it is not uncommon to find that there is little or no staining in the cortex, except here and there a dot or streak, but the papillæ present a very deep staining; at the apex and extending up the pyramid are seen bundles of brown lines, so as to form a sort of fascicle. This may in some cases be due mainly to staining of the walls of tubules, but more frequently, we think, to that of the vessels between them.

The condition of the kidney in this stage is explained by the molecular degeneration and breaking down of the lardaceous parts; they lose in consequence the characteristic lardaceous reaction. The combination of more or less fibrous change with the fatty degeneration is also usually found at this period; there are sometimes cysts in the cortex.

It need scarcely be said that there may be an accidental combination of other diseases of the kidney with lardaceous degeneration, and the appearance of the organ will be consequently modified.

4. *Cystic* degeneration occurs either as a primary lesion or, secondarily, as a part of some other disease, especially of the granular contracted kidney. It is at present disputed whether the primary cystic degeneration developes in the same way as the scattered cysts in interstitial nephritis. Two forms of the primary disease are met with,—one congenital, the other occurring in adult life.

Congenital or fœtal cystic degeneration is a somewhat rare affection; when present birth is often premature, and delivery may be impeded; and if the child be born alive the disease is often speedily fatal. The two kidneys are usually equally affected, and converted into a congeries

of small cysts. The enlargement of the organs may be very great, but in some few cases they have been smaller than natural. The cysts appear to be produced by abnormal development of the renal tubules and the glomeruli; according to Virchow this is explained by atresia of the papillæ and consequent obliteration of the pelvis. The cysts are said to contain urinary products.

The form which occurs in adult life is rarely met with before middle age, and most commonly is not fatal until a somewhat advanced period of life. By some it is regarded as the persistence and ultimate development of a congenital condition. Both kidneys are usually affected and much enlarged, though not always to an equal degree; they are converted into a mass of cysts varying from the smallest size up to one or even two inches in diameter, embedded in connective tissue. The cysts contain either colourless or yellow or reddish-brown fluid of varying shade, sometimes almost black, or they may contain gelatinous material of the same colours; they contain albumen and altered blood, together with cholesterin crystals, in rare cases oxalate of lime and leucine (see Pl. ix., figs. 15and 16), but very rarely any urinary products. The cyst-walls are composed of fibrous tissue, partially lined with flattened polygonal cells.

There is no doubt that the cysts result from an alteration either in the Malpighian bodies or the renal tubules; but the primary cause and starting-point of the morbid change are at present obscure.

Secondary cyst-formation is very common in chronic interstitial nephritis. In the granular contracted kidney the presence of cysts is almost constant, and in the slighter degrees of a similar change a few may very often be observed. They are also more rarely seen without any evidence of interstitial nephritis. These cysts may vary in size from the smallest visible with the naked eye to those of the size of a walnut, or much larger. Minute cysts, from a pin's-head to a hemp-seed in size, are often thickly scattered through the cortex in the granular contracted kidney. These generally contain a jelly-like substance of yellowish brown colour, which may often be detached as a solid mass. The large cysts more frequently contain watery fluid, clear or variously coloured by altered blood. Larger cysts, which may even equal or exceed the kidney in size, projecting from its surface, cause a local atrophy of the part of the organ on which they press. Their wall is thin, often pellucid, and very readily ruptured. Such cysts may be solitary or associated with others of smaller size.

The most common position for the formation of cysts is in the cortex, but they may also be more rarely met with in the pyramids, especially near the base.

The mechanism of cyst-formation has been the subject of much controversy. The full discussion of the several methods which have been described or suggested would exceed our limits. Roughly speaking, cysts may be said to be formed in nearly all cases by distension either of Malpighian capsules or of tubes, other modes of origin being probably very rare. And we may say that the cause of this distension is, in the majority of cases, obstruction, either by strangulation by connective tissue growth, or by impaction of a cast. The outlet of a Malpighian capsule may readily be blocked by a gelatinous cast, or by contracting fibrous tissue, or even by adhesion of the capillary tuft to the wall near the outlet, in the manner already described. The capsule then becomes filled either with watery or gelatinous material. Such commencing cysts may often be seen on microscopic examination. In the tubules a process of impaction by a fibrinous cylinder, and the successive deposit of layers of fibrinous or colloid material around it so as to cause distension of the tube, has been described and figured by Cornil.

But in many cases, as was long ago pointed out by Dr. Bristowe (Path. Trans., vol. iii., p. 381, and vol. ix., p. 309), the cysts form irregular moniliform rows, due to their origination through constriction of convoluted tubules at several points by fibrous tissue.

A form of cystic degeneration of the kidney, associated with similar disease of the liver, has also been described by Dr. Bristowe (Path. Trans., vol. vii., p. 229, and vol. x., p. 174) and others.

5. *Calcareous* degeneration is extremely rare. As such has been described a condition in which the walls of the vessels and a part of the surrounding fibrous tissue become infiltrated with calcareous material, so that on section they are gritty, like bits of stone or glass embedded in the substance. In the only case we have seen the kidney was the only organ in which this change was found. It can, however, hardly be called degeneration of the kidney. A like change is sometimes found in the minuter arteries of the brain.

6. *Colloid degeneration.*—A colloid degeneration, somewhat resembling lardaceous in character and distribution, but differing in the fact that the degenerated parts do not display the characteristic reaction with iodine, is described by Lancereaux. Fig. 17, Pl. ix., after Lancereaux, shows this change. (See Lancereaux, Traite d'Anat. Path. and Art. Rein., *loc. cit.*)

III. Vascular Changes.

Anæmia and Hyperæmia.—Concerning general anæmia we need say nothing. The results of complete obstruction of blood supply, total or partial, will be mentioned later.

Hyperæmia of the kidney is of common occurrence. Active hyperæmia occurs under conditions of irritation, and, of course, is an important factor in the early stages of acute inflammation. But the lesser degrees, which lead to no structural change, we shall not here stay to consider. Intense hyperæmia is sometimes met with in cases of poisoning—for example, with turpentine, corrosive sublimate, carbolic acid, iodide of potassium, and no doubt many other substances which are excreted by the kidney. But in all these cases, so far as we have seen, there are other very marked changes in the tubules, and the hyperæmia is merely one result of the irritation. The same may be said of the hyperæmia which occurs in some rapidly fatal cases of scarlet and other fevers, and the change will be best described as a part of the early stage of acute Bright's disease.

Active hyperæmia may be mainly distinguished from passive or congestive hyperæmia by the more generally diffused redness, and its brighter colour, by the injection and prominence of the glomeruli, and the large quantity of blood escaping on section from the cut surface. Hæmorrhages along the vessels and scattered beneath the capsule are met with in some cases where the irritation is intense.

Passive hyperæmia or venous congestion is often met with. When recent or acute it is characterized by a very deep red colour at the base of the pyramids, where the large venous trunks ramify, and of the pyramids themselves; the venæ stellatæ are distended and dark; the whole organ may be of deep red colour.

Chronic venous congestion—cyanotic or *congestive induration.* — In long-standing heart disease, chronic emphysema and bronchitis, and other causes productive of continuous passive venous hyperæmia, the kidney becomes altered, and the resulting condition has received various names and explanations. "Cyanotic induration" is the name proposed by Klebs, but that of "congestive induration" seems preferable, as it is equally distinctive and less open to objection.

It is necessary to adopt some distinctive term, for by many authors this condition is spoken of as a form of Bright's disease dependent on chronic inflammation. In reality the state is the associated and analogous condition in the kidney with "nutmeg" liver, "brown induration" of the lungs, &c., and is due to a similar cause and dependent on similar pathological changes.

During the early stages of this condition the organ is somewhat enlarged, extremely dense, tough and hard, but its shape is unaltered, the capsule separates with ease, the surface is very smooth, and of dark red or purplish colour. On section the normal relations of cortex to medulla are unaltered, the cortex is of very deep red colour, and the glomeruli very distinct, sometimes of brighter red than the rest of the cortex, and the papillæ, especially at the base, very dark and purple, owing to the fulness of the veins. But the most striking change is often the extreme firmness and density of the whole organ.

In the more advanced stages these physical characters persist and are intensified, the organ may be uniformly enlarged, the edge of a section very sharp. The section may still preserve its deep red colour, but not uncommonly it becomes somewhat paler, the glomeruli, however, being very distinct, somewhat prominent, and apparently enlarged, and retaining, even after washing with water, a very deep colour; the cortex is thickened.

In some cases a later stage is reached in which slight adhesion of the capsule occurs, the cortex is much paler, still very tough and fibrous, and sometimes more uniform on section than natural. Throughout the whole course of the changes there is no alteration in the general arrangement of the structure, the primitive cones are regular and free from distortion, there are usually no cysts, and the surface is very smooth and uniform.

The essential morbid change consists in hyperæmia which, starting in the veins, affects gradually the entire vascular system of the organ. In consequence of the peculiar vascular arrangement the glomeruli, though nearest to

the arterial side, are early affected, the stasis telling very markedly upon them, and the greatest obstruction occurring here. Their capillaries become distended, the glomeruli as a whole enlarged, the walls of the capillaries thickened and rigid. The same is true of the vasa recta and the intertubular plexus, which also becomes distended, thickened, and rigid.

After a time there results a distinct fibrous thickening of the walls both of the small and large vessels throughout the organ, and it may be that no other change occurs beyond this universal and essential one, the epithelium of the tubules being absolutely normal. Nor is it rare to find that, on microscopic examination, the evidence of thickening of the walls is very slight, the naked eye appearances being the most characteristic. We must then suppose that the coats of the vessels have undergone a change which is rather of molecular than of structural character, and have merely lost their elasticity. But even this is not essential, for the injection of a healthy organ with water, if forcible, will produce a similar indurated condition, as may be readily seen by making the experiment.

Other changes may, however, be produced. Hæmorrhage into the Malpighian capsule is one of these. Another, which is found in some long-standing cases (especially, so far as I have seen, in aortic disease), is the presence of areas of small-celled growth around some of the arterioles. It is possible that these small tracts may depend on a true fibrous growth resulting from chronic irritation, but their appearance and structure are often suggestive of the outwandering of white blood corpuscles in certain situations, owing to greatly increased intravascular pressure.

The position of these sclerotic patches is entirely different from those seen in ordinary interstitial nephritis, and the glomerular capsule is usually unaffected, unless a secondary inflammation has been set up.

Such are the essential changes; other intercurrent causes may lead to their combination with catarrhal and other processes. The tubules themselves commonly remain unaltered to any appreciable extent, but degenerative changes in the epithelium may ensue.

Embolism, Thrombosis, and their effects.

Embolism of the renal artery, as a whole, is rare, but that of some of its branches is of common occurrence, especially in heart disease. Thrombosis of the entire artery, though rare, is numerically of more frequent occurrence than embolism, as it may result from atheroma of the aorta, or of the renal artery, as well as from external pressure, and other causes; but thrombosis of branches is less common. In whatever way the vascular obstruction is produced the results are similar.

Obstruction of the whole artery, if at first incomplete, may produce atrophy of the organ. This is probably the mechanism of some cases of congenital atrophy or incomplete development of one kidney. But when occurring at a later period it produces a sort of necrobiosis of the organ, the elements fall into a condition of fatty degeneration, and, together with this, there is exudation of leucocytes along the course of the vessels. (See Path. Trans., vol. xxvi., p. 135, and Cohnheim, *loc. cit.*)

Obstruction limited to branches of the artery leads to the phenomenon of "infarction," the results of which are well seen in figs. 1 and 2, Pl. iv. (These are stated to be from a case of pyæmia, but they themselves bear no special stamp of pyæmic nature). Here, however, a large arterial branch is obstructed; more frequently we find obstruction only of smaller branches, down to the most minute, and often a considerable number of infarcts of various dates.

The changes which attend this process have been experimentally studied; we may briefly describe them. At first, when the artery is blocked, there is sudden transient pallor, rapidly followed by a livid red swelling in the region of the tract supplied by the vessel, and on section a sharply defined deep red conical patch is seen extending through the cortex, narrowing towards the medulla. Speedily other changes ensue. The affected tract becomes more dense, paler in the centre, and finally of dead yellowish-white colour, somewhat marbled with red if the tract be large, and more or less granular. Surrounding it appears a dark red line, which varies much in intensity and width. Later, the infarct becomes limited by a fibrous coat which encapsules it, and undergoes more or less complete atrophy, so that if small it may completely disappear, or leave only a fibrous scar, or form a small cyst; or, if larger, only a portion is absorbed, and the remainder becomes caseous or, later, cretified. Hence the numerous scar-like depressions so often seen in the kidneys

of those who have suffered from valvular heart disease.

The intimate changes which attend the process of infarction are now so well known that they need only be briefly indicated. As in all parts supplied by terminal arteries, the following changes ensue:—Firstly, intense congestive hyperæmia; secondly, stasis and migration both of leucocytes, and, if the obstruction be sudden, of red corpuscles into the tissues, and, in the case of the kidney, into the tubules, and then necrobiosis of the elementary organic constituents. This is followed by partial absorption, if the parts be small, and the nutrition of surrounding parts active, or by degenerative changes in the entire infarct leading to caseation, or more rarely to suppuration.

In cases of ulcerative endocarditis, or other conditions in which very minute emboli are disseminated through the blood, very small infarcts are found in the renal cortex, producing minute whitish spots surrounded by a vascular zone upon the surface of the organ, these often being only the size of a pin's-head at the surface, and extending two or three lines deep, along the interlobular artery; sometimes they are clustered, sometimes separate. Such spots are seen in fig. 3, Pl. iv.

In pyæmia there is no essential difference in the results of embolism except that the infarcts undergo rapid softening or suppuration, but even this is not always the case. As a rule the surrounding vascularity is also more intense. The differences observed are possibly not solely due to the infective nature of the embolus, but in part to its softer and more friable character.

Disseminated Suppuration of the Kidney.

Disseminated suppuration.— Acute interstitial nephritis with scattered points of suppuration (Beck.)—Multiple abscesses.—Disseminated suppuration occurs, as we have just said, as a result of multiple septic embolism; it is also common in cases of pyelitis and cystitis, and is then sometimes known as "surgical kidney." The precise nature of the process in the latter form is a matter on which there is much conflict of opinion; by some it is regarded as of septic origin, due to the absorption of material from the urine, which is frequently putrescent (see Dickinson, *loc. cit.*); by others as due to rupture of over-distended glomeruli or tubules (Johnson, *loc. cit.*, p. 125); and yet other causes have been assigned. The complete discussion of this question here would occupy too much space; it would appear that these causes may all act in different cases, whilst no one explanation meets all the varieties which may be observed. (See also Reynolds' System of Medicine, vol v. Art. on Suppuration of Kidney by Mr. Marcus Beck).

In the typical forms associated with cystitis or pyelitis, the minute abscesses are usually seen clustered in groups on the surface, each abscess being from about one to two millimetres ($\frac{1}{25}$ to $\frac{1}{12}$th inch) in width, each surrounded by a red blush, which may also encompass the whole patch. In the centre of each is seen a minute droplet of pus. On section the tracts of suppuration are found to extend downwards for some distance into the cortex, and other small abscesses may be scattered through it. Later, these minute abscesses may coalesce, and larger tracts of suppuration result, and in some cases the whole renal tissue becomes completely riddled with abscesses.

It is common to find in those cases in which the pyelitis is due to obstructed outflow of urine (as in stricture, &c.), that the effects of this mechanical condition are associated with it, the pelvis and calyces are dilated, the conical papillæ flattened or even hollowed out into cystiform saccules, and in these the inflammation is most intense. In such cases, when of long duration, an interstitial fibrous growth in the pyramids is not uncommon, and this may lead to gradual atrophy of the organ (Lancereaux, Bristowe), or may perhaps cause occlusion of some tubules, and consequent local atrophy of some portions of the cortex. (Goodhart, *loc. cit.*)

Many forms and stages of this process might be described, and it is very probable that in a large number of cases of long-continued obstruction less marked changes occur, which are anatomically indistinguishable from the early stages of subacute interstitial nephritis arising from other causes; that is to say, proliferation of cells around the glomeruli, and interstitial exudation, leading to fibrous cicatrices such as are seen in figs. 10 and 11, Pl. viii. But in the suppurative form, or that which we have described in which multiple minute spots, or rather streaks, verging on suppuration are found, or where these have coalesced into larger tracts and produced distinct abscesses, it is very difficult to determine how far mere obstruction has been the cause, notably in some very acute cases of cystitis following paraplegia.

Experimental ligature of the ureter in the lower animals has been found to cause an interstitial growth around the glomeruli of tubules, a process similar to that which occurs in the liver after ligature of the common bile duct (see Charcot and Gombault, Arch. de Physiologie, *loc. cit.*)

On comparison of sections from the early stages of disseminated suppuration, of leucocythæmia, and of tubercle, and even of scarlatinal nephritis, one finds a striking resemblance in the distribution of the lesion, viz., limitation to the neighbourhood of Malpighian bodies, and also in the crowding of small round cells between the tubules. (See figs. 9 and 11, Pl. ix.)

IV. BRIGHT'S DISEASE—NEPHRITIS.

We turn now to the consideration of the forms of renal disease commonly included under the head of "Bright's disease." The various meanings attached to this term, and the different views which prevail, both as to the diseases which should be included under it, and their classification, have already been mentioned. On only one point can we find any universal agreement, viz., that all the forms of renal disease included under this term are inflammatory.

Thus Frerichs classifies Bright's disease only in stages of one morbid process: as 1, hyperæmia with commencing exudation; 2, exudation and commencing organisation; 3, degeneration and atrophy. Klebs classifies nephritis as I. Primary diffuse nephritis (Bright's disease proper), beginning in the cellular tissue of the kidney, with two stages—1, of lymphatic cell infiltration of the interstitial connective tissue; 2, of connective tissue new-formation and contraction. II. Glomerulo-nephritis, in which the connective tissue of the glomeruli is especially affected. III. Syphilitic nephritis. IV. Embolic nephritis, *a*, arterial; *b*, capillary. V. Pyelo-nephritis. VI. Gouty nephritis. These are the classifications of two of the most weighty German authorities, both of whom hold the doctrine of the unity of Bright's disease; regarding the acute and chronic forms as merely stages of one process. On the other hand Bartels, chief amongst German writers, together with most English and many French authorities, regard as essentially distinct the forms which affect the tubules mainly and primarily, and those which commence in the interstitial tissue; describing under various names a primary, acute, tubular, or parenchymatous form which goes on to a chronic stage, and a primary interstitial form which is essentially chronic. Most English writers (*e.g.*, Johnson, Dickinson, Roberts) describe with these, as a third form, the lardaceous kidney. This classification in its entirety is adopted by Charcot, who separates scarlatinal nephritis, but only provisionally. Lecorché proposes to divide nephritis into the two forms of parenchymatous and interstitial; the former he identifies with Bright's disease, the latter he believes to have been known long antecedent to Bright's researches. He divides the parenchymatous or epithelial form (large white kidney) into four periods, those of hyperæmia, hyperplasia, regression or fatty degeneration, and atrophy.

It is not our purpose to discuss all these various classifications, or to show how the diverse names given to each stage and form concur or differ. In our view both of these classifications are erroneous, for that of Frerichs and Klebs cannot be reconciled with many clinical facts; whilst that of Johnson, Dickinson, Charcot, &c., is not borne out in its entirety by the results of autopsies.

The classification provisionally suggested which seems most nearly to accord both with clinical and pathological facts is as follows:—1. Parenchymatous, tubular, or catarrhal nephritis, a primary acute disease affecting mainly the epithelium, and passing on by gradual steps into a chronic stage. 2. Subacute interstitial nephritis, also an acute or subacute form, attended with great interstitial exudation both in and around the glomeruli and the tubules, and leading to extreme changes in the tubules, which probably also share in the inflammatory process at an early period. 3. A form of which the type is observed in scarlatinal nephritis, a subacute form in which the glomeruli and their surroundings are mainly or excessively affected, and the tubules as a secondary result, and it may be but slightly. 4. Chronic interstitial nephritis, leading to the granular contracted kidney; a disease which is essentially chronic from the first, commences in the neighbourhood of the vessels and glomeruli, and leads either simply to atrophic changes in the parts supplied by these vessels, together with some degree of interstitial fibrous overgrowth (small granular contracted kidney); or may be complicated by more acute interstitial overgrowth throughout the kidney, or only in some parts of it (large granular contracting kidney), the latter form

being a transitional one between the chronic and the subacute interstitial forms.

Bartels, the most recent and distinguished German author on renal disease, has severed himself from the views commonly held in Germany, and holds strongly the distinction between parenchymatous nephritis and renal cirrhosis (the name suggested by Grainger Stewart for granular contracted kidney). Bartels divides parenchymatous nephritis into acute and chronic, but holds that the chronic form is not usually the sequel of the acute, but an essentially insidious and chronic form. He allows too that in the later stages this may be complicated with interstitial growth, a view essentially in accordance with that of Dickinson. The classification here suggested differs, therefore, from that of Bartels in holding that the interstitial growth is often the primary and essential morbid change, and that scarlatinal nephritis is essentially distinct from acute or chronic parenchymatous nephritis.

It is very probable that the "chronic parenchymatous nephritis" of Bartels is the clinical synonym of that which we have called "subacute interstitial nephritis" on pathological grounds. These two names would thus represent the clinical and histological aspects of the same fact in a large number of cases.

ACUTE PARENCHYMATOUS NEPHRITIS.

Synonyms.—Tubular or tubal nephritis (Dickinson). Catarrhal nephritis. Desquamative nephritis. Acute nephritis.

This, which is usually regarded as one of the commonest forms of acute renal disease, is very rarely fatal in its acute stage. We exclude the cases of acute nephritis following scarlet fever, as we hope to show that they are not to be regarded as identical with the form of renal disease now under consideration; we must also put aside the cases complicating pregnancy, fevers, or poisoning, and those secondary to and conjoined with chronic interstitial nephritis. Having done this, we find only very few cases fatal within one or two months from the onset of a purely catarrhal nephritis arising from exposure to cold or wet. And it is extremely difficult to give any definite account of the morbid appearances of the kidney in this stage, nearly all writers mixing up the cases sequential to scarlet fever with the primary form. We may, however, with some probability assume that the condition of the organs in cases of moderate severity is not unlike that found in other diseases, such as pneumonia, when accompanied by albuminuria; and that in more severe cases there will be a condition resembling that seen in acute inflammation due to certain poisons. The condition in the later stages is more accurately known.*

In the earlier stages the kidney is enlarged, sometimes considerably so, and becomes more rounded than natural, the capsule is tightly stretched, and separates readily; the venæ stellatæ are well-marked on an otherwise pale surface; on section the cortex is found to be swollen, pale or pinkish, or in some cases much more vascular than natural, more or less mottled with opaque pinkish points, and presenting markedly injected dots due to the swollen vessels and glomeruli. From the slighter grade transitions to an intense uniform or mottled red injection with hæmorrhages are found. The pyramids are usually but little affected, but may be congested and vascular in cases where the vascularity of the cortex is also intense.

In this stage the main change consists in a catarrhal swelling and proliferation of the epithelium, especially of the convoluted tubes and the ascending branches of Henle's loops; in the convoluted tubes are often found blood casts, and masses of swollen cells occluding the channel

* It may be well here to define more precisely the position here taken. It has been commonly assumed, owing to imperfect microscopic examination, that ordinary acute nephritis, as well as that following scarlet fever, is essentially a catarrhal or parenchymatous nephritis, the tubal epithelium being mainly affected—hence the terms tubal, epithelial, catarrhal, applied to this form. It is now shown that, in scarlet fever at least, the epithelial changes are secondary, or may be unimportant; whilst the interstitial and peri-glomerular changes are constant and definite. In the absence of evidence as to microscopic examination, all descriptions of acute catarrhal nephritis drawn from cases following scarlet fever must, therefore, be set aside. Concerning the remaining cases of acute nephritis two views may be held; one, the old one, that the change is mainly catarrhal, in which case they are clearly very distinct from the post-scarlatinal form; the other, that interstitial growth may occur in all cases, though in varying amount, that it is not the essential lesion, and may exist to a large degree without removing the case from the category of catarrhal nephritis. The latter view is that held by Dr. Dickinson. It would be out of the question here to enter into any detailed inquiry into this subject; we shall therefore assume, as generally held, that there is a purely or mainly catarrhal form, which at no part of its course is necessarily combined with interstitial growth, and in which interstitial or glomerular changes do not play any important part.

(*see* fig. 8, Pl. ix.) The straight tubes may contain hyaline casts, and exudation casts, or casts with a central fibrinous cylinder surrounded by puriform cells, but at this stage they may be comparatively free. Fibrinous casts may also exist, especially in the lower parts of the convoluted tubes and Henle's loops (Bartels).

Large white kidney. Fatty kidney.—After the lapse of a certain time, if the disease does not subside, further changes ensue, the organ still continues enlarged, but loses its excessive vascularity; the cortex, still swollen, presents on section a more mottled appearance, small yellowish or opaque white dots being scattered over a dull pinkish surface. Microscopic examination now shows that further changes have occurred in the altered epithelium. Many of the convoluted tubes are filled with masses of granular material in which the outline of cell-forms is only indistinctly traceable, and there may be minute oil-globules in some of them; in many others are large fibrinous (so called gelatinous or colloid) casts, either filling the tube or surrounded by altered epithelial cells. It is, however, rare to find on microscopic examination the distinct oil-globules which are often described as characteristic of the disease at this stage. The straight tubes contain hyaline or fibrinous casts, with exudation cells and granular material.

In its ultimate evolution we may find a greater extension of similar changes and atrophy of certain portions of the cortex; together with the necrotic changes in the epithelium, and in the vascular and interstitial tissues which have been already more minutely described in the account of the elementary lesions.

SCARLATINAL NEPHRITIS.

Histology.—The morbid changes in the kidney consequent on scarlet fever have only of late years received their full elucidation. For a long time after the discoveries of Bright, scarlatinal nephritis was regarded as the type of acute catarrhal nephritis. Bright himself drew some of his most typical clinical illustrations of acute renal disease from cases following scarlet fever. But it was early noted that in many cases of post-scarlatinal dropsy the condition of the kidneys after death was very different from that usually regarded as typical of the acute nephritis following exposure to cold, and that the kidneys might even present an appearance but little removed from that of health. Amongst the earliest cases recorded is one by Dr. Bristowe (Path. Trans., vol. viii., p. 235) in which the Malpighian bodies were mainly affected. He found an exudation within the capsules of the glomeruli compressing the capillary tufts. Fuller observations were made by Klebs (Handbuch der Path. Anat., s. 645), who described a peculiar state of the glomeruli, in which the spaces within the capsule were filled with small angular nuclei, due to a proliferation of cells within the capsule, and probably derived from the interstitial tissue of the glomerulus,—this nuclear proliferation resulting in compression of the tuft. Klebs regarded this as the special lesion of scarlatinal nephritis, although uncertain whether it was peculiar to it. Other observers, however, described a diffuse interstitial nephritis, which, although in some cases especially marked around the glomeruli, were not especially within or limited to them. Thus Biermer (Arch. f. Path. Anat., xix., 5 and 6) reported a case fatal on the thirty-fifth day, in which there were diffuse intertubular growths in the cortical substance. Wagner (Arch. der Heilkunde, 1867, p. 264), in a memoir on the pathological anatomy of scarlatina, describes a case in which there were masses of cells and nuclei, especially around the Malpighian corpuscles. Kelsch again drew attention to the subject in 1874 (Arch. de Phys. Norm. et Path., 1874, p. 746); he examined two cases, in one of which there was a diffuse interstitial growth; in the other, an exudation, especially in the vicinity of the glomeruli.

The careful investigations by Dr. Klein into the minute anatomy of scarlatina (Eight Report to Med. Officer of Privy Council) have not only confirmed the earlier observations, but very completely elucidated their progress and results, and have established beyond a doubt the existence of special changes in and around the vessels and glomeruli as an essential feature of the disease. (See also Path. Trans., vol. xxvii.)*

* My own observations were commenced early in 1873, since which time my attention has been constantly directed to the subject, and I have been able to examine with the microscope the kidneys from thirty cases of scarlatinal nephritis fatal at periods varying from six days to eighteen months after the onset of the fever. In 1874 I had the opportunity of showing some of my sections to MM. Charcot and Kelsch, and comparing them with those of the latter observer. As I have found it necessary to draw to a large extent upon my own observations in the following description, and as those

The changes vary much in different cases, and in various stages of the disease, and these differences cannot be attributed merely to the period at which death occurs.

In a considerable number of cases dying at an early period some alterations are found in the epithelium of the convoluted tubules.

Cloudy swelling and granular degeneration are so frequently present in the course or sequelæ of other fevers that we cannot attribute to them any very great importance. But in a considerable number of cases fatal at a period of several weeks after the fever, we find all the changes in the epithelium which are characteristic of acute nephritis. The convoluted tubes are filled with swollen and proliferated epithelial cells, which are variously cloudy, granular, or containing fatty granulations—all indicative of "catarrhal" changes.

Together with these, however, are constantly found other changes not usually seen in tubular nephritis, and which may exist as the sole morbid change. We must describe them as grades of a process rather than stages of a disease, for they may be extreme at an early period (one of the most advanced cases we have seen, that from which the drawings of figs. 1—4, Pl. ix. were made, was fatal in the sixth week), or they may be comparatively slight after a long time. They occur in the glomeruli, vessels, and intertubular substance.

Glomeruli.—Some of these changes have already been described. (*See* pp. 4 and 5). But we can see two very distinct early processes: one, the multiplication of the nuclei on the capillary tuft, which may exist almost alone (fig. 4, Pl. ix.); the other, a growth inside of and adherent to the capsule, simply compressing the capillary tuft. This growth is well seen in fig. 2, Plate ix., where it is, as often is the case, somewhat unilateral, and much thicker over one part of the capsule than another. The growth is usually composed of somewhat flattened cells, originating apparently from the endothelial cells which line the capsule. In their evolution both these processes have a similar result, viz., the adhesion of the capillary tuft to the capsule, and its compression and atrophy. The change is very unequally distributed, sometimes only a few of the glomeruli being involved, the others apparently remaining intact; at other times a large number together are affected. Close by the one represented in fig. 3, Plate ix., there is another which is scarcely diseased at all. In this case, however, the affection was very widespread.

Together with this change in the glomeruli, tracts of fibroid growth occur in the interstitial tissue in their vicinity, leading to atrophic changes in the convoluted tubes. This may be absent, even in cases of long duration, or may be very extensive at an early period.

It is evident, therefore, that the changes which are constantly present differ somewhat in their character, and the superadded or exceptional changes are highly variable.

In certain very acute cases the kidneys present numerous ecchymoses, most abundant in, but not limited to, the cortex, as in fig. 4, Pl. ii., where they are very slight; sometimes they resemble fig. 5, Pl. i. These apparent hæmorrhages are found on microscopic examination to consist almost entirely of white blood-corpuscles, as in leucocythæmia, such as are seen in fig. 9, Pl. ix.

The other changes found in the more rapid cases consist in the presence of gelatinous or colloid casts in the convoluted tubules, sometimes blood casts, and some plugs in some of the straight tubes.

The changes in the vessels and arterioles have already been described. (*See* page 6.)

It will thus be seen that the commonest and most essential change in scarlatinal nephritis is glomerular and peri-glomerular; together with this, there is an acute interstitial change between the tubules, combined with various degrees of epithelial degeneration. The questions then arise: (1) What is the cause of this change? (2) In what relation does it stand to epithelial degeneration? and (3) What is the ultimate evolution? We can only just refer to these points:—(1) Dr. Klein regards the changes in the glomeruli as due to obstruction of arterioles, partly by plugs of granular material, aided also by swelling of the intima of the vessels. This theory is founded upon the undoubtedly-proved presence of thrombi in the afferent arterioles in some cases. There are strong grounds, however, for dissent from it as an explanation sufficient for all cases.

(2) The degenerative and "catarrhal" changes in the epithelium of the tubules are regarded by Kelsch and others (*loc. cit.*) as secondary to the process of destruction of the glomerulus. Two

observations have not yet been published, I must apologise for making use of them. But it is right to say that, in lectures and demonstrations for the last five years, I have constantly drawn attention to the changes here described.

results necessarily ensue: the watery flow through the convoluted tubules is arrested, and the intertubular capillary plexus corresponding with the glomerulus is to some extent deprived of blood; hence the tubules are both prevented from the regular performance of their function, and their vascular supply is diminished. The epithelium, therefore, becomes altered, and finally atrophied and absorbed. Others regard the cloudy swelling of the epithelium and the catarrh as due to the fever itself, and as not an essential part of the morbid process. Both of these views may have their several truth in different cases.

(3) The ultimate evolution of scarlatinal nephritis is also a matter of some doubt. A large number of well-marked cases are, no doubt, fatal at an early period; others may become cured, the affection being only of limited extent, and the affected tracts being compensated for by the healthy. But, as yet, only a few cases have been recorded in which a long time has elapsed before death. Does this process lead to the large white and fatty kidney, to the granular contracted, or to intermediate forms? There is but little published evidence upon the point. The case of Annie Reed (Pl. iii., figs 1, 2 & 3) shows conclusively that the granular contracted kidney may result. In one case under my own observation, which was fatal fourteen months after the attack of scarlet fever, the kidneys were large and resembled the typical large white smooth kidney of Bright as seen with the naked eye, but the microscope revealed enormous interstitial growth throughout the whole cortex, with disappearance of the majority of the convoluted tubules, and great contraction of the rest. (*See* figs. 5 and 6, Pl. ix., drawn from this kidney.) The changes seen in some cases appear strongly to indicate a tendency to the development of a form of kidney indistinguishable from the granular contracted. (*See* fig. 1, Pl. ix.) The point yet remains open for future investigation.

Naked eye appearances of scarlatinal nephritis.—These, as we have said, vary very greatly. That seen in some acute cases is well represented in fig. 2, Pl. ii. But in a number of cases fatal from the seventh to the fourteenth week we have seen some such appearances as the following:—The kidneys, which are but slightly enlarged, are firm and somewhat dense. The capsule separates readily; it is little or not at all thickened. The external surface, of somewhat pinkish colour and more translucent than natural, is finely dotted with red or brownish-red points, some of which appear to correspond to the glomeruli; others are more angular or stellate. On section the superficial cortex may present at first sight but slight deviation from a healthy aspect. It is of semi-translucent pinkish-white colour; the rows of glomeruli, however, are unusually distinct, and often stand out in a striking manner; the interlobular vessels are also distinct; and, in addition, some minute angular brownish-red points are seen scattered through the cortex. The superficial cortex is not unfrequently thinned uniformly (in one case of a lad of sixteen, it was only one-sixth of an inch thick); it is very tough in some cases, and the cut edge sharp. In the interpyramidal cortex there are usually more distinct changes. This is often swollen, of opaque yellowish or pinkish-white colour, mottled with opaque yellowish-white points. The swelling is in some cases great.

Another form may be described by way of contrast. In the case of a lad seventeen years old, from whose kidney some of the drawings (figs. 1—3, Plate ix.) were taken, the disease was fatal on the forty-third day from the onset of fever; the kidneys weighed seventeen ounces and a half, were large, smooth, with greatly swollen opaque whitish cortex mottled with yellowish points, radiating injection as from rows of glomeruli being here and there visible. The appearance, in fact, differed but little from that of the large white kidney consecutive to acute catarrhal nephritis. Yet in this case, as seen by the drawings, the changes were most strikingly those of acute interstitial nephritis. Other forms are seen in drawings 2, 3, 4 and 5, Plate ii. Hence it seems very probable that the condition found in the case of Annie Reed, æt. 10 (Pl. iii, figs. 1, 2 and 3), could be a common ultimate result of scarlatinal nephritis, if the patient survived long enough.

The bearing of these observations relative to scarlatinal nephritis upon the general subject of acute nephritis is at present uncertain. It may be that the separation of scarlatinal from ordinary acute nephritis is only a provisional step necessitated by the present state of our knowledge, and that future researches will show that common acute nephritis is not essentially a catarrhal process. Thus an amalgamation of the two under a different name may again be effected. The opinion of the late Dr. Murchison was in favour of regarding all Bright's disease occurring under the age of fourteen years as of scarlatinal origin. If this view be correct it is still more probable

that there is no essential distinction between the two.

We have said nothing of the pathological anatomy of nephritis following diphtheria, cholera, typhoid, and other fevers, because so little is known with regard to them beyond the fact of the occurrence of some renal catarrh during the acute disease.. (*See* Pl. iii., fig. 1)

Subacute Interstitial Nephritis.

In speaking of acute nephritis we have mentioned that interstitial exudation may occur during the acute stage of catarrhal nephritis, but that it is usually limited in degree, and does not form an essential part of the morbid change. To what extent this is the case, apart from a scarlatinal origin, is at present undecided. What is certain is that in a number of cases occurring in adults in whom there is no history of scarlet fever, and especially in cases following the albuminuria of pregnancy,* a condition of the kidney is found which is accompanied by the clinical symptoms of "acute desquamative" nephritis, which is very like the large white kidney of post-scarlatinal nephritis, except only greater density and translucency, but is found on microscopic examination to consist almost entirely in an interstitial change, with affection of the Malpighian bodies. By some writers this is described as a separate disease; others regard it as only a variety of the acute nephritis with excess of the interstitial over the catarrhal process. Rindfleisch describes it as the early stage of the granular contracted kidney under the name "diffuse" nephritis, a term adopted by Dr. Dickinson to indicate merely the occurrence of interstitial proliferation.†

Under the head of scarlatinal nephritis we have described the more important changes observed. It is, however, to be noted that the change is often more general in the form now under consideration than in scarlatinal nephritis, —that is, it does not so distinctly commence in and around the Malpighian bodies, but more generally throughout the intertubular spaces.

As yet the etiology of this form of kidney disease and its results are too little understood to allow us to dwell upon it; it certainly demands more attention than it has yet received. Rindfleisch states that it is distinguished from the catarrhal form by a whiter colour, greater elasticity, and a more translucent appearance of the cortex. Together with this the substance is tougher: by some it is compared to caoutchouc. But the essential distinctions are not well appreciated without microscopic examination.

We must add that some writers consider this form as in no way distinct in its origin from the form of large white kidney which results from tubular nephritis. They hold that the inflammatory process begins in, and is most marked in, the tubules, but that side by side with this is interstitial inflammatory growth, varying in degree in different cases according to the intensity of the inflammation; that as the disease continues the interstitial growth also advances, until in course of time the new connective tissue becomes a very marked feature on microscopic examination. Thus a nephritis, primarily "tubular," "catarrhal," or "parenchymatous," comes to be secondarily an interstitial nephritis. From our own observations we incline to the belief that either this must be true or that simple parenchymatous nephritis is a very rare disease, for very few cases are met with of so-called "large white" or "fatty" kidney in which there is not very marked interstitial growth. It has already been observed that this subacute interstitial nephritis is the anatomical equivalent of a large proportion of cases of "chronic parenchymatous nephritis," whether originating from an acute attack or occurring in a latent and insidious form, and apparently chronic from the outset.

It is needless to give any description either of the naked eye or microscopical appearance, as they have already been sufficiently described.

CHRONIC INTERSTITIAL NEPHRITIS.

Granular contracted Kidney.—Cirrhosis of the Kidney.—The "granular degeneration" of Bright included the various forms of acute and chronic nephritis; thus the large pale granular kidney, the flabby or soft and mottled granular, and the contracted granular, are all spoken of by Bright and his contemporaries as forms of the "granular degeneration." It is only of late years that the term "granular" has been applied mainly to the form which Bright called "contracted," and we owe to French writers the application of the term

* See Dickinson (*loc. cit.*), pp. 158 (*et seq.*), who quotes also Braun (*loc. cit.*) Simpson, Sir J. Y., 'Edinburgh Monthly Journal,' Oct. 1852.

† Rosenstein and others use this name as synonymous with "parenchymatous nephritis, Bright's disease, and granular degeneration of the kidney." It seems better, therefore, to avoid the use of so indefinite a term.

"Granulation de Bright" to the nodular projections on the surface of the granular contracted kidney. Even the term "contracted" as applied to this form is now left out by some writers; thus Dr. Dickinson and others apply the term "granular degeneration" to the condition which is commonly known as "granular contracted." Nor is this without reason, if the word "contracted" is to be understood as applying to the kidney as a whole, for it may be larger than natural, even considerably so, just as a cirrhotic liver may attain large dimensions or be very small.

Essentially the granular contracted kidney may be defined as including the whole class of cases of interstitial nephritis attended with contraction of the interstitial growth in such a way as to produce a general unevenness of surface, as well as the cases of essentially atrophic origin more properly so called. But it must be remembered that similar changes may exist to a considerable extent without producing the obvious naked eye characters of the disease, that it is in fact only the generalized and terminal condition of a process which is often found in a less degree and more scattered form.

Thus the drawings, Pl. viii., figs. 9, 10 and 11, are from a kidney which presented none of the ordinary external characters of the granular contracted kidney.

Naked eye appearances.—Though with wide differences in form, size and colour, and probably of origin, the granular contracted kidney presents certain generic features common to all forms. The capsule, more or less thickened, is often adherent to the surrounding fat, and sometimes vessels of some size pass into it from those in the fat. The capsule also adheres more or less intimately to the surface of the organ; on attempting to separate it, it strips off in layers, leaving here and there a delicate lamina adhering to the surface, or if it separates entirely it tears off small portions of the cortex. The surface of the cortex is more or less finely granulated, small rounded projections of pretty uniform size covering the surface, and giving it a rough morocco-like character. The projecting nodules are invariably somewhat paler than the intervening depressions; they may indeed, owing to their pale translucent greyish colour, present a marked contrast to the deep red vascular sulci which separate them. In their size, these granulations vary, usually from a pin's head to a mustard-seed, rarely larger. (*See* Plate iii., fig. 6.) With these more uniform granular projections are often found some more irregular depressions and puckerings, as in fig. 7, Plate iii. Cysts are usually seen, varying in size from the smallest visible with the naked eye to those of a very large size. The most characteristic are the very minute cysts containing gelatinous material. These appearances are well seen in Pl. iii., figs. 1, 2, 6, 7 and 8.

On section of the organ in the usual manner, the fat is often found to penetrate much more deeply into the pelvis than usual; the superficial cortex is wasted, sometimes to such a degree that almost no space intervenes between the bases of the pyramids and the surface. (*See* Pl. iii., fig. 2.) In the wasted cortex the distinct radiating lines of the primitive cones are lost or distorted, and replaced by a confused granular appearance. (Plate iii., figs. 2, 4 and 5.) Vessels of large size and with apparently thickened walls acquire undue prominence in the wasted cortex, and cysts of the various kinds already described are more or less abundantly scattered through it, though they may be scanty or very minute, as in fig. 6, Pl. iii., where they appear as dark points.

The interpyramidal cortex does not share at all equally in this change. Sometimes it is but little altered in appearance; at others, swollen, pale and mottled, contrasting strikingly with the superficial portion. (*See* Pl. iii., fig. 4.) In all cases it is affected later than the superficial cortex, and it is but rarely that it is completely atrophied in uncomplicated cases. The pyramids themselves do not necessarily present any marked change, though they may share in the general atrophy.

It is rarely that the arteries are unaltered. The trunk of the renal artery and its main branches are usually atheromatous, often to a great degree, and we may trace a similar change with the naked eye in those branches which are thus visible. All the arterial branches also appear disproportionately thick, with a narrow lumen; in some cases they have the aspect of translucent rings which stand widely open on the section.

Such are the generic characters common to all forms, but we find great differences in detail. To classify these exactly would be difficult, for the various forms shade off into one another, and there are many stages of the disease, but we may roughly divide them into—

1. The large pale granular kidney. The kidney, as a whole, enlarged; the granulations on

the surface largish, very pale whitish or pinkish-white. On section, the interpyramidal cortex often considerably swollen and mottled. Such a kidney is seen in fig. 8, Pl. iii.

2. The small red granular kidney, such as that seen in figs. 5 and 6, Pl. iii. This is the other extreme; the kidney, which is contracted to a small hard mass, is of deep-red colour; the granulations are small and somewhat irregular in size, but very distinct—generally there is very marked atrophy of the whole cortical substance. It is especially in this form that we sometimes see the abundant deposit of urates throughout the organ; on the surface, especially between the projections, we see minute brick-red dots, as if the surface had been sprinkled with cayenne pepper. On section, similar granules are found throughout the cortex, and occasionally streaks of a like colour in the pyramids, running in the direction of the medullary rays. To this form the name of "gouty kidney" has been given, an error in our opinion, since the other forms are equally associated with that disease, and it may occur independently of any gouty manifestation.

3. Intermediate forms varying very considerably. A large red granular kidney; a large-grained and small-grained form, and so on, which it is hardly needful to describe, for we cannot as yet assign to each particular form a distinct etiology.

Where, as in figs. 1 and 7, Pl. iii., we see large irregular depressions on the surface, we usually find evidence of their production by absorption of cysts, or obstruction of vessels and consecutive wasting.

It is probable that the two forms, the large and small granular kidney, may be regarded as types of two forms of disease, distinct in their evolution, and perhaps also in their etiology. No absolute line can be drawn between the two, but the first is typical of origin by essentially interstitial growth; the second, by atrophic change. In describing the microscopic characters this distinction must be kept in view. It is admitted by some of the most eminent pathologists that a large part of the change, in many cases, is purely atrophic. This is held by Dr. George Johnson and by Drs. Wilks and Moxon (Path. Anat., 2nd edit., p. 509). But whilst this is true of some cases, it is probably not so of others in which extensive interstitial growth occurs.

The changes which occur in both forms have already been to a large extent described under the head of elementary lesions. They may now be grouped together and certain differences pointed out. These depend upon the stage of the process, the amount of interstitial as distinguished from atrophic change, and the diffusion or limitation of the degeneration.

In the form which may be described as essentially atrophic—the granular contracted kidney, properly so-called—the disease starts in the vessels and glomeruli, usually in those situated nearest the surface, that is, at the periphery of the interlobular arteries. To understand this process, we must recur to the account already given of the glomerular changes (pp. 4 and 5). It is very common to find these early changes on microscopical examination of kidneys which present none of the common naked eye appearances of the granular contracted kidney, except, perhaps, very slight adhesion of the capsule, and a few cysts in the cortex. A certain number of the Malpighian bodies are in various stages of the change seen in figs. 9—12, Pl. viii., and these are most numerous near the surface of the cortex. Some of the smaller arteries present thickening of the inner coat, fibro-muscular hypertrophy of the middle coat, and thickening of the fibrous sheath. Some of the tubules in the immediate vicinity of the degenerated Malpighian body are in various stages of atrophy, as in the upper part of fig. 10; but no general changes are observed in the tubes. As the disease advances, more and more glomeruli are involved; and, by progressive stages from the surface inwards, a large number become completely atrophied into fibrous knots. The effect upon the tubes is twofold: the convoluted tube corresponding to each glomerulus loses the exercise of its function, the blood-supply is partly obstructed, partly diverted, watery fluid from the glomerulus no longer flows through its channel, and, either in consequence of these changes alone or of an associated inflammatory process, the tube wastes. There are thus formed, by the consequent contraction and atrophy of certain regions corresponding to some arteries, somewhat irregularly conical fibroid patches running inwards from the surface. These consist mainly of the atrophied glomeruli and tubules, with a slight amount of inflammatory growth. At the base of the conical patch, which is directed towards the surface of the organ, the capsule becomes adherent, and new vessels form, which pass from the capsule into the organ and aid in maintaining the nutrition and circulation. Thus it is to the region of the interlobular arteries and

glomeruli that the earliest and most essential changes belong, by the contraction of these tracts the minute depressions surrounding the prominent granules on the surface are produced, and to the newly-formed or dilated vessels is due the deep red colour of these sulci as distinguished from the paler projecting points.

The bundles of straight tubes forming the medullary rays are least affected, and the corresponding region is therefore more prominent on the surface.

But the contraction of the affected regions does not proceed in a regular and uniform manner, and the regular arrangement of the medullary rays is therefore soon distorted, and finally altogether lost. The dilatation of some of the tubes aids in effecting this irregularity. By successive steps the greater part or whole of the cortex becomes involved, until, in many parts, no trace of the normal structure is visible, and only a confused fibrous mass with the remains of thickened vessels and wasted glomeruli, and a few dilated tubes or cysts are visible. Here and there one or two of the glomeruli, not yet completely atrophied, remain. Such a condition is seen in fig. 7, Pl. viii. When this stage is reached, it would be impossible by microscopic examination to decide by what steps the change has come about, or what constituents of the kidney have been first affected. This can only be done in the early stages.

The process in this form, though essentially atrophic in its results, is attended by changes in the component parts which we cannot hesitate to regard as of a chronic inflammatory character, and they result in the development of connective tissue in place of the normal constituents. But the process is not inflammatory in the commonly-understood sense of being attended with interstitial exudation to any marked degree. It is a transformation of the existing connective tissue elements into fibrous tissue, with atrophy of the organically functional components, rather than a superaddition of new connective tissue around them, compressing and destroying them. But we do not think that there is an absolute line of demarcation between this and the succeeding form.

In the larger form, attended by great swelling of the deeper portions of the cortex in the later stages, there is much more true interstitial growth or exudation. Clinically, this form, though often latent, is probably more acute than the atrophic form, and is more frequently attended by dropsy. With the naked eye the appearances already described are seen, the granulations being coarser, the atrophy of the superficial cortex less marked, and the swelling of the interpyramidal cortex more pronounced. Often, indeed, the latter is in a condition intermediate in appearance between the granular contracted and acute forms, being mottled with yellowish-white points.

Histologically, this form is intermediate in its characters between that already described as subacute interstitial nephritis (*q.v.*) and that just now described. In some sections very extensive connective tissue growth is seen, either in the form of accumulation of leucocytes with connective-tissue corpuscles, or forming a loose highly-cellular fibrous network, very similar to that often described as "adenoid," having abundant meshes. Moreover, the process is not so sharply limited to the immediate vicinity of Malpighian bodies and arterioles, but extends widely, surrounding the straight as well as the convoluted tubules. The coats of the vessels are swollen to an unusual degree, but are often much less atheromatous than in the more chronic form. The condition of many of the glomeruli is that seen in fig. 12, Pl. viii., rather than that in fig. 7, and indicates a more acute process.

But, as we have before said, whilst the differences are great in typical cases which lie at the two extremes, a majority of cases are intermediate in their character, and we cannot draw any sharp dividing line between them. A case, which has been proceeding slowly for some time, perhaps for years, suddenly becomes accelerated in its progress by some accessory cause, and the kidney shews a combination of the two forms.

Intermediate forms produced by combination of acute catarrhal with chronic interstitial changes also occur; indeed, in a large number of cases of apparently acute nephritis occurring in middle life, older changes will be discovered on microscopic examination. But in many of the kidneys which are supposed to exhibit this combination of catarrhal with interstitial nephritis, the acute changes are found on microscopic examination to be, in reality, interstitial.

V. INFILTRATIONS AND MORBID GROWTHS.

Several forms of renal disease do not receive consideration in this *résumé*, as they are not-

amongst the subjects illustrated in the plates. Of these may be mentioned the subjects of renal calculi and their effects upon the organ: hydro- and pyo-nephrosis, abscess of the kidney, parasitic diseases, and tumours. No adequate account of these could be given without the aid both of naked eye and microscopical drawings; hence it has been judged expedient to exclude them. The only exceptions are those forms of renal disease which form part of a general disease, such as syphilis, tuberculosis, leucocythæmia, and lymphadenosis, which we now proceed briefly to consider.

Syphilitic Diseases of the Kidney.

These have been more carefully studied of late years than before, but our knowledge is, as yet, only fragmentary. As in other organs, the effects of syphilis are partly direct, partly indirect. Of the latter the most common form is lardaceous degeneration, concerning which it is now generally admitted that it may occur in constitutional syphilis without any obvious suppurative disease. The direct manifestations present the form of gummatous growth, seen either in the early active stage, or more commonly as caseous patches or mere fibroid scars. In some cases, also, there is disease of the arteries, alone or combined with these other lesions.

Compared with other organs, the kidney is unusually rarely the seat of syphilitic new growth. It is not even mentioned by some of the modern systematic authors. "Gumma in the kidney is curiously rare. Very few cases are on record." (Wilks and Moxon, Path. Anat., p. 519.

The following references to recorded cases may be useful:—

Klebs. Path. Anat., p. 647.

Lancereaux. Treatise on Syph. Syd. Soc. Trans., vol. i., p. 298.

Moxon. Guy's Hosp. Rep., 1868.

Morell Mackenzie. Path. Trans., vol. xxii., p. 34.

Greenfield. Path. Trans., vol. xxvii., p. 313.

In nearly all cases the gummata are situated in the cortex near its surface; they are usually in the form of more or less rounded or wedge-shaped yellow masses, as seen in Plate i., fig. 4; when seen in a very early stage, they may be less defined and more gelatinous in appearance. Their size varies greatly, but the largest in this situation rarely exceeds half an inch in diameter. In all the recorded cases, similar nodules were found in the liver. Not unfrequently in cases of syphilis with gummata in other organs, there are seen small fibrous patches on the surface of the kidney, which extend for a variable distance into the substance. These are usually regarded, and with great probability, as the traces of a bygone gummatous growth which has left only a cicatrix. Of syphilitic disease of the arteries of the kidney we here say little; we have observed it in one case only, and can find no other case on record. (See Path. Trans., vol. xxvii., p. 313.) In this case the walls of the arteries were infiltrated with gummatous growth, the lumen nearly obliterated by endarteritis, and small tracts of the kidney supplied by these vessels resembled infarcts. It is probable that a similar change often occurs to a limited extent, and leads to the atrophied patches so often found. A case of syphilitic disease of the kidney in congenital syphilis is recorded by Klebs, but we are not aware that it is mentioned by any other writer.

Tubercle of the Kidney.

Two forms may be described: disseminated miliary tuberculosis and tuberculous pyelo-nephritis.

Disseminated tuberculosis occurs either as part of a general miliary tuberculosis or as a more local affection, involving only certain organs, or it may be the kidney alone; this, however, very rarely. The characters of the renal affection do not, however, vary much with the cause. Usually only grey granulations are found in the kidney, and they are largely limited to the cortex. Only one or two may be found, or they may be in very large numbers. They appear on the surface as whitish dots the size of pins' heads or less, very slightly, if at all, prominent; on section they are found to extend for some little distance into the organ along the medullary rays. They rarely have the sharply-defined outline and grey gelatinous appearance which they are apt to present in other organs; they are more opaque, and more distinctly elongated—may, indeed, extend nearly the entire depth of the cortex. On microscopic examination they are usually found to commence around the terminal branches of the arterioles, resembling in structure those found in other organs.

Tuberculous Pyelo-nephritis, Strumous Pyelitis, Scrofulous Pyelo-nephritis.—This is usually a

primary affection of the kidney, commencing in its substance, extending to the pelvis, and thence often implicating the entire urinary tract. In its earliest stages the tubercular growth is found in the substance of the papillæ, usually near the centre, or more deeply in the pyramid as a small cluster of granulations; these become caseous, the growth extends by infiltration of the surrounding tissue until it reaches the submucous tissue of the pelvis, when an ulcerated surface is produced. The growth may then spread to the entire mucous membrane of the pelvis and downwards into the ureter. At the same time it invades more deeply the substance of the organ, forming large caseous masses, which break down more or less completely into a putty-like substance. Hence on section of the organ and washing away the softened caseous portion, only a series of irregular ulcerated cavities remain, hollowed out in the renal tissue, of which only a thin shell may persist.

Such a condition is seen in Plate i., fig. 3. The soft putty-like material has been washed away. A somewhat rarer form is that represented in Pl. i., fig. 1. Here there are not only the ragged abscess-like cavities continuous with the pelvis, but in addition a number of small scattered masses of more or less softened tubercular deposit. Essentially the process is the same, but there is a discontinuous extension of the infiltration. The softened masses resemble softened caseous tubercles in other organs.

The affection of the pelvis and ureter, and in some cases of the bladder also, is very characteristic. There is considerable thickening, a ragged, ulcerated surface; not unfrequently the ureter on section appears to be filled with a core of caseous substance. The infiltration extends more deeply than the mucous coat, involving sometimes the whole thickness of the walls. In the male the vas deferens, vesicula seminalis and testicle are not rarely secondarily infected; sometimes also the prostate.

Microscopically, the process differs somewhat from that seen in miliary tuberculosis, especially in the greater extent of common inflammation. It may indeed be difficult to distinguish by microscopical examination between a tubercular nephritis and a simple disseminated suppurative nephritis in the later stages, and it is probable that a simple disseminated suppuration often complicates this form. Usually, however, the microscopic examination of parts of the organ remote from the softened tracts, and in as yet apparently unaffected regions, reveals grey granulations surrounding the vessels. Thus in fig. 11, Pl. ix., the drawing is taken from an apparently healthy part of the cortex in a case of tuberculous pyelitis. Some of the vessels are seen to be surrounded by infiltration of a small-celled growth, which at some points is in a state of incipient caseation.

We must not here stop to discuss the disputed question of the relation of this form of disease with general tuberculosis. Some have questioned the tubercular nature of strumous pyelo-nephritis; the dispute is only a branch of the wider one which has divided pathologists into two schools on the subject of pulmonary phthisis.

Kidney in Leucocythæmia.

In many cases of leucocythæmia the kidneys are not obviously affected, but in some cases there are very marked changes. The organs are enlarged, of dead-white colour, sometimes with a slightly yellowish tint, and the substance may be the seat of ecchymoses or hæmorrhages of various size. The enlargement is commonly uniform, and dependent on a general swelling of the cortex; the organ may be more than doubled in size. Both kidneys are usually affected, and to nearly an equal degree; in this respect there is a striking contrast to that which occurs in lymphadenoma. On section the cortex is usually found to be of nearly uniform whitish colour, not mottled with yellowish spots as in Bright's disease, and this colour contrasts strikingly with the pink colour of the pyramids, and with the hæmorrhages when they are present. Hæmorrhages, which may be either very minute or of considerable size, are almost constant. On the surface there may be abundant ecchymoses, and more or less rounded patches of hæmorrhage which may attain half an inch or more in width. In one case we have seen these caused rounded prominences, and some blood was effused between the capsule and the surface. On section they are found to extend into the substance of the cortex, and streaks of hæmorrhage are also seen running in the direction of the vessels. At the base of the pyramids we have once seen radiating streaks of hæmorrhage forming a uniform corona. The kidney shown in Plate i., fig. 5, might be taken as a typical representation of the leucocythæmic kidney.

On microscopic examination the principal change is found to consist in an accumulation of leucocytes within the capillaries, in which they may form complete plugs, and their migration into the surrounding tissues. This exudation is especially marked around the glomeruli and smaller arteries, dense masses surrounding them and widely separating the tubules in their vicinity. (Plate ix., fig. 9.) According to Virchow, the leucocytes also escape into the space between the capillary tuft and capsule of the glomerulus, as well as around the Malpighian body. If this be the case they may escape into the urine, but this has not, so far as we know, been observed; nor does our own observation confirm the statement of Virchow.

The tubules, though widely separated by the leucocytes which occupy the capillaries and the interstices of the tissue, do not appear to suffer to a marked degree; their epithelium usually appears to be unaltered; nor are leucocytes usually seen in their interior. As to the nature of the masses of cells much difference of opinion exists. Some regard them as lymphatic new growths from the connective tissue, and assert that they form distinct tumours. (Virchow, Waldeyer.) Others consider them to be produced as we have described, by the obstruction of capillaries, migration of leucocytes through their walls, or rupture of the vessels themselves. (Cornil et Ranvier, *loc. cit.*, p. 1028.) That the latter process is common is shown by the existence of multiple ecchymoses; and the probability of the view we have adopted is increased by the fact that one often finds red corpuscles mingled with the white; and conversely, the spots which appear to the naked eye as hæmorrhages are often found on microscopic examination to be composed *almost entirely* of leucocytes. (See Path. Trans., vol. xxix., p. 303.)

Lymphadenoma of the Kidney.

In lymphadenoma or "Hodgkin's disease," in which there is more or less general enlargement and over-growth of the lymphatic glands throughout the body, with extension of growth into surrounding parts, and the formation of similar masses of new growth in the liver or spleen or lungs, the kidneys may also be implicated, though less frequently than the viscera just named. Fig. 5, Plate i., is a representation of one of the forms in which this is said to occur, viz., a general infiltration of the whole organ; but, as we have said, this particular form is far more common in cases of leucocythæmia than in the allied and possibly similar disease known as adénie, anæmia lymphatica, or lymphadenoma. The case from which this specimen is taken forms an interesting link between the two, for there were some glandular swellings. The condition of the blood in this case is not, however, noted. More frequently the morbid change consists in the presence of nodules or masses of new growth, of whitish, pinkish-white, or yellowish-white colour, chiefly in the cortex, varying much in size, number, and position. They differ but little in their external appearance from cancerous or sarcomatous nodules. When at the surface of the organ they may be slightly prominent after separation of the capsule, forming roundish pretty sharply-defined masses, or they may be level with the surrounding surface, and present a more ill-defined outline and less opaque white colour. At the circumference of the nodule there is often a zone of pinkish injection, but this may be wanting. On section of the organ they are found either as roundish masses, or elongated in the direction of the pyramids, or, if near the surface, somewhat conical; or they may be less defined, having the character of a more irregular infiltration, and this is especially the case where they affect the pyramids, when they run as ill-defined masses of elongated shape towards the papilla.

These growths vary in dimensions from the smallest visible point to the size of a pea, a marble, or even larger; indeed, they may occupy a large tract by the confluence of smaller nodules. The small nodules may very closely resemble tubercular granulations, but they are never encapsuled by a fibrous zone, and tend to spread at the edges. They may become yellow or even caseous in the centre, and the larger nodules often present a distinct yellowish tint throughout.

There is then no one character by which they are absolutely distinguishable with the naked eye from all other forms of new growth, and it is only with the microscope and by the associated disease of other organs that they can be distinguished with certainty. But roughly speaking a difference may be found in these characters. They tend to be less sharply outlined than cancerous or sarcomatous nodules, and of less convexity on the surface; they are not so hard as the harder form of cancer, and when of the size of a pea or more

are of more yellowish tinge than the rapidly-growing softer forms. In cancer of the kidney, if secondary, one commonly finds a few isolated nodules of firm consistence, sharp outline, and if of slow growth with central fibrous charge, which spread uniformly in all directions from the centre. Primary cancers of the kidney usually invade a large tract of the organ in direct continuity; but many so-called "cancers" of the kidney in children are primary lympho-sarcomatous growths.

From syphilitic growths, when in an early stage, they are distinguished by their more opaque whitish colour: syphilitic infiltration, when early, being more yellowish and translucent; and, later, they lack the surrounding fibroid zone and smooth, hard, yellow "caseous" nodules which characterise gummata. But in the kidney, as in the liver, growths of lymphadenoma may become caseous throughout.

There are not many representations or descriptions of lymphadenoma of the kidney in English medical literature. There is a very excellent description by Dr. Murchison of such a case in the Trans. Path. Soc. for 1868, vol. xx., p. 196, which is accompanied by a drawing of the kidney, and by microscopic drawings. Other cases are described by Dr. Coupland, Path. Trans. xxviii., 126, and Dr. Turner, Path. Trans., vol. xxix., p. 342.

Such growths in the kidney have been recorded in very few well-marked cases of the disease, and this organ seems to be far less frequently involved than either the liver, spleen, or lungs.

In a few cases the growth extends to the pelvis of the kidney, or even along the ureter, infiltrating the submucous tissue, and forming either a continuous or nodular infiltration. (See Dr. Coupland's case above mentioned). This growth has in some cases a peculiar tendency to form continuous infiltrations, such as are seen in some cases in the pleura, the subpleural connective tissue being occupied by plates of the new growth.

The effect upon the function of the kidney may be slight or almost nil. We are not aware of any case in which symptoms have been induced by its presence in the nodular form. They would depend, if present, solely on destruction of renal tissue, or collateral irritation and hyperæmia; and the analogous case of cancer shows how very large a growth may occur in some cases without leading to obvious functional results.

Microscopic characters of the new growth.—The growths commence in the connective tissue, usually in that in the neighbourhood of the glomeruli, if in the cortex, and appear at first simply as accumulations of nuclei, or small cells of various shapes with large nuclei and scanty protoplasm. In this stage these cells are scarcely, if at all, distinguishable from the aggregations of leucocytes, which are seen in leukæmic kidney. (*Vide supra*, p. 32.) The further growth consists in the formation of a distinct stroma, which, at first only a very delicate branching nucleated protoplasm, becomes distinctly fibrillated, and if the growth be longer continued is transformed into a dense fibrous network, with small meshes, resembling, in fact, the tissue of a chronically indurated lymphatic gland. There is nothing in the growth in the kidney different from the similar growth in other organs, and its relations to the special tissues are not of great importance.

LIST OF AUTHORS.

In order to avoid repeated reference to the same works, we give a list of some of the principal authors to whom reference has been made in the text, or whose works have been consulted:—

Basham. On Dropsy. 3rd edit., London, 1866.

Bartels. Art. on Diffuse Diseases of the Kidney, in Ziemssen's Encyc. of the Practice of Medicine. Vol. xv., 1875.

Beck, Marcus. Art. on Secondary Nephritis and Pyelitis, in Reynolds' System of Medicine, vol. v.

Bright. 1. Reports of Medical Cases, 1827. 2. Cases illustrative of Renal Disease, &c., Guy's Hospital Reports, 1836.

Bristowe. 1. Theory and Practice of Medicine, Art. Kidney, 1st edit., London, 1876. 2. Path. Trans., vol ix., p. 309 (Cysts in Kidney).

Charcot. Leçons sur les Maladies du Foie et des Reins, 1877.

Charcot et Gombault. Arch. de Physiologie, vol. iii., 1877.

Cornil. 1. Les Differentes Espèces de Néphrites. 2. Note sur la Degenerescence Amyloide, Arch. de Physiologie, 1875, p. 671.

Cornil et Ranvier. Manual d'Histologie Pathologique, Paris, 1876.

Dickinson. 1. The Pathology and Treatment of Albuminuria, 2nd ed., London, 1877. 2. On

Disseminated Suppuration of the Kidney, Med. Chir. Trans., 1879.

EBSTEIN. Art. in Ziemssen's Encyc., vol. xv.

FRERICHS. Die Bright'sche Nierenkrankheiten u. deren Behandlung, 1851.

GOODHART. Surgical Kidneys, Path. Trans., vol. xxiv.

GREEN. Pathology and Morbid Anatomy, London, 1875.

GULL (and SUTTON). 1. On the Pathology of Chronic Bright's Disease, with Contracted Kidney (Arterio-capillary Fibrosis), Med. Chir. Trans., vol lv., 1872. 2. On the Arterio-capillary system in connection with Kidney Disease, Path. Trans., vol. xxviii.

HEIDENHAIN. Mikrosk. Beitrage zut Anat. u. Phys. der Nieren, in Schultze's Archiv., Bd. x., 1874.

HOPE. Morbid Anatomy, London, 1834.

JOHNSON, G. 1. On the Diseases of the Kidneys, 1852. 2. Some points in the Anat. and Path. of Bright's Disease, Med. Chir. Trans., vol. xxxiii.. 3. Forms and stages of Bright's Disease, Med. Chir. Trans., vol. xlii., 1853. 4. Lectures on Bright's Disease, London, 1873.

KELSCH. Revue Critique et Récherches Anat. Path. sur la Maladie de Bright, in Arch. de Physiologie, 1874, p. 722.

KLEBS. Handbuch der Pathol. Anatomie (Art. Nieren).

KLEIN (E.) Report on the Minute Anatomy of Scarlatina, Eighth Report of Med Off., Loc. Govt. Board (also in Path. Trans., vol. xxviii.)

LANCEREAUX. 1. Art. Reins, in Dict. Encyc. des Sciences Médicales, Paris, 1877. 2. Traité d'Anatomie Pathologique.

LANCEREAUX et LACKERBAUER. Atlas d'Anatomie Pathologique, Paris, 1871.

LECORCHÉ. Traité des Maladies des Reins, Paris, 1875.

PAYNE (J. F.) Jones and Sieveking's Path. Anatomy, Art. Kidney.

RAYER. Traité des Maladies des Reins, with Atlas, Paris, 1839—41.

RINDFLEISCH. Manual of Path. Anatomy, New Syd. Soc. Trans.

ROBERTS (Dr. WM.) 1. Urinary and Renal Diseases, 2nd ed., London, 1872. 2. Art. on Diseases of Urinary Organs, Reynolds' System of Medicine, vol. v.

ROSENSTEIN (S.) Die Pathologie und Therapie der Nieren Krankheiten, 2nd ed., Berlin, 1870.

SOUTHEY. St. Bartholomew's Hosp. Reports, and Med. Chir. Trans., 1878.

STEWART (GRAINGER). Bright's Diseases of the Kidney, Edin., 1868.

TODD. Clinical Lectures.

WAGNER. General Pathology, 6th ed., Trans. by Seguin, London, 1876.

WILKS. Cases of Bright's Disease, with remarks, Guy's Hosp. Reports, 1853.

WILKS and MOXON. Pathological Anatomy, 2nd edition.

A RÉSUMÉ

OF OUR PRESENT KNOWLEDGE OF

DISEASES OF THE SPLEEN.

By JAMES F. GOODHART, M.D.

Before describing the changes which are observed in the spleen under pathological conditions, it will be necessary to consider the structure of that organ in its normal state. Speaking in general terms, the spleen, like all other tissues, is a mass of cells coherent through several causes. The natural adhesion of the cells to each other; the system of vessels ramifying through the entire gland; the capsule which binds all parts together; and its offshoots or trabeculæ, which spread out in all directions, unite in maintaining the integrity and determining the limits of the spleen.

The *capsule* is a fibro-elastic investing membrane, and its deeper layers contain a few bundles of non-striated muscular fibre. Numerous fibro-elastic bands given off from the capsule traverse the organ and constitute the groundwork and support of the glandular elements. These bands, as part of the investing capsule, also contain bundles of non-striated muscular fibre. This has been disputed by authorities of no less weight than Kölliker, Gerlach, and Henle, but is affirmed by Meissner, Frey, Kyber, and Klein. Some observations from morbid anatomy, to be subsequently mentioned (Plate x., figs. 4, 5), demonstrate the existence of such fibres in the trabeculæ, sometimes even in large quantity, as a fact beyond a doubt, unless this development is held to be a *de novo* occurrence and merely occasional as the result of disease. That there is a hypertrophy in such cases is certain, but an entirely new formation is improbable: we may therefore say that the trabeculæ of the healthy spleen contain muscular fibre in some instances, and what is true for some is probably true for all cases.

The *arteries* and *veins* enter the spleen at the hilus and become invested with a common sheath derived from the capsule. The arteries and veins pair and proceed together, subdividing as they go, till their trunks are reduced to a size commonly stated to be from 3 to 2 millimetres. They then part company, and each system undergoes modification. The arterial sheath becomes gradually transformed into a fine network of membranes, or, as some say, of fibres, in the meshes of which lymph corpuscles are packed, continuously with the cells of the parenchyma. The sheath is traversed by fine capillaries, and dilatations occur at intervals, to which have been given the name Malpighian corpuscles; but it is to be noted, when studying the structure of the human spleen, that there is nothing peculiar in the composition of these bodies distinct from the structure of the sheaths of the smaller arteries, and that it is often difficult to detect any dilatations worthy of the name. The arteries, accompanied by their lymphoid sheaths, ultimately split up into tufts and pass on into capillary vessels. The capillaries lose their walls, or, in other terms, their walls are gradually converted into cytogenous tissue, so that the blood is at last allowed to wander in fine currents in the interstices of the cells of the splenic pulp. Tracing the blood-stream onwards from this point, the fine currents mentioned gradually collect in pools which constitute the cavernous system of the pulp. From these pools the finer veins take origin from passages between the pulp cells, which gradually acquire a continuous wall. They next ramify in the trabeculæ, communicate with each other, and gradually converge to the main branches which have already been described. The capillaries derived from the arteries for the supply of the arterial sheaths and Malpighian corpuscles find their way into the pulp, after ramifying in the lymphoid structures of the sheath.

Upon this view the circulation in the spleen is

analogous to that of a river which gradually loses itself amid the shingle and ooze of an underground bed, to reappear after a time as a distinct and well-banked stream.

This view of the nature of the spleen, accepted by W. Müller, Frey, Peremeschko, and Klein, is that to which I myself incline. But Kölliker, Billroth, Schweigger-Seidel and others interpret the structure of this organ in a different manner. They maintain that the blood-vessels of the spleen form a closed system, with definite walls and lumen, and that the reticulum and cells are always around and outside the vessels. Moreover, Klein, entertaining a third opinion, believes that the pulp is *within* the vessels, or, in other words, that the endothelium of the veins becomes modified.

This *pulp* is composed of cells, some with one nucleus, some with more, and they are bound together by a finely-granular intercellular substance. They often contain pigment and other granular matter which has been considered to be the *débris* of dead corpuscles. All the spaces between the vessels and trabeculæ are filled by the pulp, which forms columns or paths uniting the various Malpighian corpuscles and arterial sheaths. Hence the *pulp-strands* of Billroth. Small vessels run along the axes of the strands and blood-corpuscles wander from them into the intercellular substance of the cell columns. The pulp cells are often described as being separated by a fine intercellular stroma of *fibres*, but there can be very little doubt that this is but an appearance produced by the hardening reagents to which the structures are submitted before examination, and that, if the splenic pulp be examined in the fresh state, this feature is absent. The splenic pulp is then intersected by a "honeycomb of membranes," to adopt Dr. Klein's description.* This observer further states that these membranes contain nuclei which bud into the spaces of which they form the confines, and in this manner the lymph corpuscles are formed, which are the proper contents of the spaces. Upon this view the pulp might be said to be within the vessels.

But little is known of the distribution of the nerves and lymphatics of the spleen, and nothing is certain of the part they play in the production of morbid changes; it is therefore unnecessary to say anything respecting them.

This preliminary anatomical *résumé* will prepare the way for the difficulties to be encountered in the study of the diseases of the spleen. It will help to remind us of the uncertainty that still exists as to the exact details of the splenic parenchyma in a state of health, and will make clear, what might otherwise be forgotten, that we have here to deal with an organ the very structure of which is in itself the greatest obstacle to any conclusive proof of the changes that disease has worked. In other organs, such as the kidney and liver, the elementary cells of their component tissues present definite features, the products of disease, for the most part differing from them greatly: or at least these products are so arranged as to be distinguished from the normal parts with moderate ease. In the spleen the ultimate elements of the healthy gland and the rearrangements of these which are present in disease are so similar that in many cases it is most difficult to decide between them. Hence it follows that the naked eye appearances still assume a more than ordinary importance in the morbid anatomy of the spleen, for they are often the only features which convey any decided indications of structural alteration. We cannot suppose that this will always be the case, but it must be allowed that it is so at present.

The systems of classification most in vogue in treating of the morbid anatomy of the viscera are chiefly two: one deals with diseases, and considers the changes of texture only as they occur in, and are characteristic of, definite disorders; the other groups the altered tissues upon an anatomical basis, leaving the pathology or picture of disease to be built up by a subsequent rearrangement of the various elementary lesions. For several reasons the latter plan recommends itself for adoption here: it conforms to the arrangement which has already been carried out for diseases of the kidney; it allows of a more precise description of some histological conditions than has hitherto been attempted; and, looking to the little variation that is found in the elementary changes in all the diseases of the spleen, it is the only plan, admitting of being at all consistently followed, which does not at the same time involve us in difficulties and repetitions of description both unnecessary and confusing. According to this arrangement, the changes in the skeleton of the spleen—that is, in the capsule and trabeculæ—will come first; next, those which are chiefly vascular; and, lastly, those affecting the pulp and lymphoid tissues.

* On the Structure of the Spleen. 'Quarterly Journal of Microscopical Science,' vol. xv., new series.

Capsule.

The *capsule of the spleen* forms, in health, a uniform thin bluish investment to the whole organ. But it is liable to become coated with lymph; to contract adhesions to the neighbouring parts; to become the seat of flocculent vegetations; and of localized or diffused cartilaginous thickenings. The formation of lymph is, indeed, due to local peritonitis and not to inflammation of the capsule of the spleen; but it is often so purely local that it must be supposed to be dependent upon changes in the organ upon which it occurs, and is therefore one of the diseases of which mention is requisite. The spleen is usually somewhat swollen and firm in texture in these cases; its capsule is opaque, and its lustre dulled by the thin adherent layer of membrane. This is composed, as are other false membranes on the peritoneum, of an overgrowth of the endothelial surface, of an accumulation of lymphoid cells in the meshes of the membrane, and of a fibrillating fibrinous material. Adhesions of this kind are supplied by capillary vessels from the subjacent capsule, and, for the most part, become a medium of adhesion between the spleen and the diaphragm. They occur when the spleen has been subject to chronic congestion and enlargement, and thus are very common in cases of mitral disease and of cirrhosis; they are also found as a part of general peritonitis, acute or chronic, as, for example, in Bright's disease, or with local inflammations extending from the pleura or other neighbouring structures.

Flocculent vegetations are occasionally found upon the convex surface of the spleen, though less commonly there than upon the surface of the liver. They occur under very similar circumstances to those just described, and are probably outgrowths from the peritoneum in the same way, but modified by altered or restricted conditions of growth. They have been regarded by some as of allied nature to the Pacchionian bodies found upon the membranes of the brain.

Chronic capsulitis, the gristly thickening which is found in the splenic capsule, is probably quite a distinct affection. It may be more or less diffused over the convex aspect of the organ, or circumscribed in well-defined plaques. In the former case the surface is interrupted by circular depressions in which the growth has either gone on less rapidly or has been absorbed subsequently to its formation. In either case the disease shows itself as a bluish-white thickening of the capsule of extreme density, and quite like fibro-cartilage. The amount of the thickening varies greatly, but it not unfrequently reaches several millimetres. A vertical section usually shows that, unlike the inflammatory products just described, which form upon the surface, these patches extend inwards from the deeper layers of the capsule, at the expense of the splenic tissue. (Plate x., fig. 1.) They consist of hyaline bands, of almost structureless substance, arranged in lines parallel to the surface. At rare intervals, a small elongated nucleus may be discovered, and as the deeper parts are reached the bands open out and enclose nests of small nuclei which spread irregularly into the splenic pulp. In this part a few nuclei of non-striated muscle may be seen. As a rule, however, the muscular nuclei of the capsule are less evident in disease than in health; all the nuclear elements are, indeed, much diminished, and the active function of the capsule, if there be any in health, must be materially hindered in its application. These thickenings occasionally undergo calcareous degeneration. They occur in a minor degree in the enlarged spleen met with in rachitis and the shrivelled spleen of old age, but in an extreme degree they occur unquestionably most commonly in those addicted to alcoholic intemperance, and in the syphilitic; occasionally in association with renal disease, when there has been no history of either alcoholism or syphilis. MM. Cornil and Ranvier,* following M. Léon Collin, describe the change as occurring constantly in intermittent fever, and give to it the name of fibrous perisplenitis. Our experience of paludal affections of the spleen has not been sufficient to enable us to express a definite opinion upon the point, but from what we have seen we should think that this statement would only apply to the slighter and less marked forms of the disease, not to the extremes of cartilaginous thickening. Expressed in figures, our experience has been that of a total of twenty cases: seven have been found in drunkards or in association with cirrhosis; four with granular kidneys; five in syphilized patients; two with chronic heart disease; two with old peritonitis.

Trabeculæ.

Trabecular changes (*Interstitial splenitis*), though not multiform, are amongst the most frequent of

* 'Manual d'Histologie Pathologique,' tome iii., p. 984.

any of the various diseases of the spleen. They occur under all sorts of conditions, and give rise to somewhat diverse histological appearances. Sometimes there is an increase of hyaline structureless material (Plate x., fig. 2); sometimes a cellular growth or interstitial inflammation; sometimes increase of fibrous tissue (Plate x., figs. 3, 5 and 6); and lastly, it is not uncommon to find thick bands, apparently fibrous, but which are in great measure composed of non-striated muscular fibre (Plate x., figs. 4 and 5). The trabeculæ also often contain more or less pigment, in the shape of fine brown granules; and they undergo amyloid degeneration in common with other elements of the spleen. All these conditions except the last-named may, and indeed do, occur more or less together as the united outcome of any morbid state which is conducive to the production and continuance of chronic congestion, but they can be dissociated anatomically to this extent—that the hyaline change is mostly found around the smaller arteries, particularly those of the Malpighian sheaths, the rest being alterations of the larger septa. The hyaline change appears to be present at the expense of the cellular elements of the cytogenous tissue which properly exists round the smaller arteries; when it is present they are few in number (Plate x., fig. 2),* a correlation which may be, though we are ignorant of its actual significance, of considerable importance in modifying the function of the organ.

Hypertrophy of the muscular tissue of the trabeculæ is another change which requires equally attentive consideration. I have already dwelt upon the disputed question of the presence of this tissue in the normal spleen. There is reason to think that it is by no means uncommon in disease, and sometimes to an extraordinary degree. In Plate x., figs. 4 and 5, two such cases are illustrated. That from which fig. 4 is taken had progressed so far that the section is no longer recognisable as coming from the spleen, and contains more muscular than any other tissue. The specimen is in Dr. Sydney Coupland's possession, and to his kindness I am indebted both for the slide from which I have made the drawing and for the notes of the case. The spleen was rather large, measuring five and a half inches long; remarkable for its extreme induration; was rather pale; creaking under the knife, and had a smooth, glistening aspect. The case was one of cancer of the breast with secondary deposits in the glands and peritoneum, and cirrhosis of the liver, and does not appear to have given any indications of splenic disease during life.

Cases such as these are of some physiological interest because they afford strong presumptive evidence of the occurrence of muscular bands in the trabeculæ of the healthy human spleen. If muscular tissue be present in health it must, of course, find its application in the varied conditions of turgescence which the spleen suffers; and its existence in increased quantity, under morbid conditions, may be no more than a compensatory hypertrophy such as the heart and uterus undergo to overcome excess of work.

But though this may be so, it by no means follows that such hypertrophy is an unmixed boon. Muscular force, when misapplied, is as capable of hindering as of facilitating healthy function; of arresting as of forwarding the circulation: and, in an organ of whose functions as yet we have no accurate knowledge, such a change deserves attentive study. I have found this change in the albuminoid spleen of rickets (Plate x., fig. 3); in the indurated spleen of chronic heart disease; in the enlargement of leukæmia; and in other cases.

An *excess of fibrous tissue* and more or less *interstitial cell-growth* occur together. The former is easy of detection, under the microscope, in the the thickened septa, around the vessels, and interlacing in the labyrinth of the pulp, but any nuclear growth is very difficult to recognise, on account of the cytogenous character of the splenic structure.

The naked eye appearances of these changes present no characteristics sufficiently marked to be indicative of the special change. The spleen is firm, dark in colour, with a smooth surface and sharp edge on section. In the extreme cases the toughness is very great, and the tissue hardly to be broken down under great pressure. When the change is less general the thickening of the trabeculæ is more evident. Malarial poisoning, chronic heart disease, cirrhosis of the liver, rachitis, and chronic peritonitis show these changes most uniformly.

The spleen of heart disease and of cirrhosis will be considered more fully later on, in relation with the venous changes which are more characteristically their own. The *rachitic* or so-called

* See also Virchow's 'Archives,' Bd. 23, p. 478. Zur normalen und pathologischen anatomie der menschlichen Milz, by Th. Billroth, and Taf v., figs. 9 and 10.

albuminoid spleen is due to an interstitial fibrosis. The spleen, in this morbid condition, is firm, of dark colour; it often has some thickening of its capsule, and the Malpighian corpuscles are but little distinct. The coats of the small arteries are swollen and hyaline-looking, while the normal cytogenous tissue around them is replaced by hyaline fibroid material which is comparatively free from cellular elements. (Plate x., fig. 2.) In other cases more fully developed fibro-muscular tissue is present in excess, and is associated with dilatation of the veins and atrophy of the pulp cells. (Plate x., fig. 3.)

In the chronic enlargement of *intermittent fever* the changes appear to be very similar, though more excessive, and with the addition of considerable pigmentation. There is the same thickening of the capsule; the same increase in the fibrous trabeculæ; the same thickening of the walls of the arteries and veins. The spleen, in these cases, may reach an excessive size, and is sometimes so deeply pigmented as to be almost black.

One other form of interstitial disease must yet be added, viz., *gummatous splenitis*. I am not aware that this takes any such diffused form as is occasionally found in syphilis in other organs, notably in the liver; but circumscribed gummata, though they are rare, occur sometimes. Wilks and Moxon,* however, state that, in syphilis—and apparently this applies to the late or tertiary stage—hypertrophic enlargement of the spleen is often met with, and this in bodies quite free from amyloid disease. "In eight such syphilitic subjects the average weight of the spleen was nineteen ounces; no cirrhosis (of the liver) or lardaceous disease being present in them." It seems not unlikely that some diffused interstitial change may have been present in these cases.

Lardaceous disease may be considered more properly amongst the diseases of the vessels of the spleen;† but it may be said here that, when this degeneration is much advanced, the trabeculæ suffer as well as other parts.

The consideration of *pigmentation* in the spleen may also be postponed till the changes in the pulp are in question. It is by no means uncommon to find some slight excess of pigment entangled in the trabeculæ of the organ, but this is usually in association with an excess in the pulp, which is the proper seat of pigment.*

Vascular Changes.

The changes which are found in the vessels may be conveniently considered as *arterial* and *venous*. The former comprise hyperæmia, certain acute changes in the walls of the small arteries, lardaceous degeneration, and embolism; the latter, dilatations of the veins, and possibly some changes in the endothelial lining of the smaller venous radicles. Splenic abscess is sometimes venous, sometimes arterial, in its origin.

Before saying anything of the minute changes, it is necessary to premise that there are many conditions of the spleen, very obviously connected with vascular disturbance within it, the histological structure of which we, at present, know nothing. Hyperæmia of the spleen is exceedingly common, and occurs under the most diverse conditions: it is found in most cases of acute blood poisoning, whether this be from one of the continued fevers, the exanthemata, or what are more strictly known as septic states; it is present in pyrexia, due to other causes; in syphilis, erysipelas, destructive forms of endocarditis; and, most markedly of all, in malarial poisoning. To superficial examination the spleen under such circumstances is large, often two, three, or four times its normal size, and when cut it is remarkable for its softness; it exudes a grumous pulp, and is of a lighter colour than usual. The Malpighian corpuscles are subject to great variation: they may be much swollen and light in colour, or surrounded by a zone of congestion, or hardly visible. In the less acute affections, malarial poisoning and endocarditis, the spleen may be large and firm, rather than soft, though, with few exceptions,

* 'Lectures on Pathological Anatomy,' 2nd ed., p. 475.

† I am not quite convinced of the absolute truth of the generally received statement, for I have seen several cases in which the lardaceous change affected chiefly not the walls of the vessel, but the *adventitia* and the hyaline trabeculæ of the lymphoid sheath.

* Recent observations tend to throw some doubt upon this statement although, as stated in the text, it is the view which is most generally entertained. Klein (*op. cit.* p. 371-2), however, believes that the matrix of the spleen is really the active part of the organ; that it buds off lymph cells from it, and thus forms the pulp cells; and that it also exercises a destructive influence upon the coloured blood corpuscles. He says, with regard to the healthy human spleen, that the lymphoid cells which include coloured blood corpuscles are relatively very rare; they are by no means so frequent as is generally represented. In this I entirely concur, from my own observations.

the spleen of fever is swollen, pulpy, and light-coloured. But this description conveys no idea of the many varieties of hyperæmia which the eye detects by alterations of colour, in different cases, upon the first section of the organ. These obtain but a fleeting recognition, not because they are unimportant, but for the reason that minute examination does not at present enable us to group or even to detect the changes upon which the variations depend.

Arteries.

The following abnormalities are of sufficient constancy to warrant their description:—

Acute swelling of the intima of the smaller arteries.

Lardaceous degeneration of the walls of the arteries.

Plugging of the canals with emboli of various kinds.

(1). *Acute swelling* of the small arteries reveals itself as a hyaline degeneration of the intima which leads to narrowing or occlusion of the vessel; and in multiplication of the nuclei of their muscular coat. These conditions have been observed by Dr. Klein in scarlatina* (Plate ix., figs. 18 to 21), and allied ones in typhoid fever;† and are similar to changes which are present in the arterioles in other viscera in the same disease. Hyaline changes have been recorded by others in the arterioles in other parts of the body in various diseases. They cannot therefore be considered as in any way special to one particular affection or confined to any one organ of the body.

(2). *Lardaceous degeneration* occurs as a diffused change affecting the whole organ or in small grains, thickly studding the parenchyma (Plate vii., fig. 9). In the former case, the spleen is pale and bloodless, enlarged, firm, much like raw bacon when cut, and having a grey translucent appearance, flecked in numberless points by the cut trabeculæ. In the second variety, which is also called the sago spleen, the disease is much more advanced in the arterial sheaths than in the pulp—hence the sago-like appearance of the cut surface, the sago grains being the amyloid vessels and sheaths. The reactions characteristic of the change are that on the addition of a watery solution of iodine, the diseased texture assumes a deep mahogany-brown colour (Plate vii., fig. 9), and this upon the addition of sulphuric acid changes to blue, violet, and then to reddish-brown, ultimately disappearing altogether. The sulphuric acid changes are, however, by no means easy to produce. Lardaceous matter is also deeply stained by other colouring agents, particularly well by picrocarmine and methylaniline. The change is not difficult of recognition under the microscope without the aid of any reagents; the affected tissues are swollen and glassy, lose their outlines, become blended with each other, and ultimately form irregular vitreous glistening cloudy masses, marked with irregular lines, the remnants of the original tissue or cell-boundaries (Plate x., figs. 12 and 13). It affects in the first instance the small arteries and the capillaries, extending thence to the surrounding textures, though, as I have said before,* this rule is by no means so absolute for the spleen as it would appear to be for other viscera.† Next to the kidney, which is affected in about 73 per cent. of all such cases, the spleen is the organ most frequently implicated. In one hundred and fifty consecutive cases of lardaceous disease, it was involved in 99 or 66 per cent. Like the same change in other viscera, with which it is almost invariably associated, the lardaceous spleen is found where chronic suppuration has existed; in old syphilis, and perhaps very occasionally from other causes, as yet unknown.

(3). *Embolism.*—The branches of the splenic artery are frequently plugged by emboli. Till recently the description of the embolic process has been confined to the results produced by the small fibrinous masses which are detached from the valves of the heart, and become lodged in an artery or its branches. But of late a fresh element has been imported into the discussion by the assertion of many distinguished pathologists that masses of minute organisms cause embolism of the vessels in no inconsiderable number of cases.

It is said that in the swollen spleen found in typhoid fever, pyæmia, puerperal fever, septic peritonitis, diphtheria, phthisis, endocarditis, acute rheumatism, &c., colonies of Micrococci have been found plugging the vessels.

The source of these is not always to be assigned, but in all cases their presence is associated with a febrile, and often a septic,

* Trans. Path. Soc. Lond., 1877.

† Report of the Medical Officer of the Privy Council, New Series, No. 6, p. 104, Plate 16.

* Foot-note, p. 39.

† Cornil and Ranvier, Manual d'Histol. Path., p. 990.

state; and in many cases masses of similar composition have been found upon one or other of the valves of the heart. They show themselves as minute, highly refracting, rounded, mobile, or motionless bodies aggregated in masses, often surrounded by a flickering granular jelly. It would seem, also, that they quickly disappear from the spleen, being found there only in the earliest days of the febrile attack. First described by Virchow, in 1857, who found the splenic arteries plugged by granular masses, which resisted the usual reagents, and were, therefore, easily distinguished from mere detritus; they have since then been observed by Waldeyer,* Birch-Hirschfeld,† Friedreich,‡ Socoloff,§ and others.

This condition of the arteries leads to engorgement of the splenic tissues and cells of the pulp; to infiltration of the adventitia of the blood-vessels with young cells; to enlargement of the Malpighian corpuscles; to circumscribed capillary extravasations; and so to enlargement of the whole organ.

Of the plugging of the vessels by masses of *fibrin* detached from the valves and cavities of the heart, or some part of the arterial system between the heart and the obliterated vessel, more is known. The spleen is often very large, and contains numerous red or yellow wedge-shaped blocks, which are the so-called embolisms or infarctions. These are produced as follows:—The ultimate ramifications of the splenic artery are, it will be remembered, terminal: that is to say they do not anastomose with each other. If one of them becomes blocked by an embolon, the circulation beyond is entirely arrested, and the blood-vessels, thus deprived of their function, speedily fall into a state of impaired nutrition. After a short time the *vein* which drains the affected area, still receiving blood from its collateral branches, allows of a retrograde current; at first, according to Cohnheim,‖ partial but continuous, then rhythmical. Thus the blood, finding its way back into the empty and feeble vessels, becomes extravasated, and an infarction is the result. Upon its first occurrence this is a firm wedge-shaped mass of dark purple colour, nearly always situated with its base at the capsule and the apex inwards. It is not always easy to find the plugged vessel. The margin of the mass soon changes to a brick-red, and later the whole infarct alters its colour in like manner. From the brick-red to its final ochre-yellow stage (Plate vi., fig. 4) is a continuous but slow process, which is followed by gradual softening and absorption, till the size of the mass is reduced to a minimum, and nothing but a depressed yellow cicatrix, which occasionally contains calcareous matter, remains behind. It is but seldom that any other termination than gradual resolution occurs; but should the plugging be composed of septic or foul material an abscess may result. Plate vi., fig. 3.

Microscopical investigations have shown that in the early stages of embolism the vessels dilate, when the splenic reticulum in the affected area becomes filled with extravasated blood. Next follow fatty changes in the infarction, and its slow absorption takes place; while at the same time a certain amount of irritative over-growth is kept up at its circumference, which leads to thickening of the neighbouring septa and adjacent vessels. There is also usually a thick layer of orange pigment granules at the circumference of the extravasation and crystals of hæmatoidin.

This will be the place to mention that infarctions are not always embolic in their origin. They occur sometimes in fever, particularly in typhus, typhoid, and relapsing fever,* and other morbid conditions of the blood; and it would seem that the researches of Neelsen† and Klein‡ into the swelling of the arterial coats in acute disease suggest a very plausible explanation of the thrombosis to which in all probability their occurrence is due in such cases, and to which they had been attributed long since by Dr. Murchison.

The infarctions of leukæmia are also due to thrombosis, and it is probable that to some such cause as thrombosis or embolism are due the apoplectic extravasations found in the spleen in some of the lower animals in the disease called splenic fever, and which is now known to be associated with, and due to the presence of spores of the *Bacillus Anthracis* in the blood.

* Mycosis Intestinalis Virchow Arch., 52, p. 541.

† Berliner Klin Wochensch, 1874; and Archives der Heilkunde, 1876, p. 208.

‡ Quoted by Birch-Hirschfeld.

§ Zur pathologie des Acuten Mitztumors Virch. Arch., Bd. 66, p. 171.

‖ Untersuchungen über die Embolischen Processe, Berlin, 1872, pp. 18, 19.

* Murchison, Treatise on Continued Fevers, 2nd edit., 1875, pp. 255, 385, 405, 564, 629.

† Archives der Heilkunde, 1876, p. 119. Über eine Eigenthümliche degeneration der Hirncapillaren.

‡ *Op. cit.*

Cases of ulcerative endocarditis and other forms of pyæmia are the most commonly productive of suppurating infarctions, while the simpler form is due to a-septic valvular inflammations, or to the detachment of clot lodged upon intervening parts of the arterial system.

Let me briefly add that the splenic artery is occasionally eroded by the extension of ulceration from the wall of the stomach, and that it may be atheromatous, in association with atheroma in other arteries, and aneurismal.

Venous changes.—It is probable that the veins also undergo changes in acute febrile diseases analogous to those which the arteries exhibit. Billroth* has called attention to these under the head of the "typhous spleen." The veins of the affected viscus are said by him to contain large quantities of polynucleated cells similar to, but more numerous than, those found in the normal veins. Klein† has gone a step farther, and ascribes these cells to a process of budding carried on by the cells of the splenic matrix, that is, by cells which are equivalent to the endothelial lining of the splenic veins.

Lardaceous degeneration affects the walls of the pulp veins when it reaches the more advanced stages.‡ But of chronic conditions the most important, because the most common in connection with the splenic venous system, is the *chronic induration* met with in obstructive heart disease and hepatic cirrhosis. Under such circumstances the spleen is heavier than usual, though it is not often much increased in size; the increase of weight being due in great measure to increased density. The capsule is usually opaque, often flaked with lymph, rough from vegetations, or thickened by milk-white patches. On section the surface is of an uniform dark purple, very firm, yielding no juice when scraped, and no Malpighian corpuscles are visible.

The alterations seen by the microscope (Plate ii., fig. 11), are widely spread and usually great dilatation of the venous sinuses; increase of the fibrous tissue of the trabeculæ; thickening of the walls both of the arteries and veins; and wasting of the arterial sheaths and pulp. The dilated veins may be overlooked with facility in unhardened specimens for two reasons: one that they are filled with blood; the other that the splenic stroma is filmy, easily displaced, and fills in what would be spaces under natural conditions. In hardened specimens much of the blood becomes dislodged, and then this feature is very remarkable. Here then are morbid changes essentially similar to those found in the nutmeg liver under similar circumstances. They consist of atrophy of the proper structures from the pressure of the dilated veins and thickened septa. The spleen of heart disease is, however, not usually described as atrophic; it comes, on the contrary, under the head of hypertrophies with many pathologists, but there can be very little doubt that it is more accurately described as an atrophied one, and that it should take its place among pathological changes with "red atrophy" of the liver. I have not mentioned any interstitial cell-growth as one of the concomitant changes, because although the presence of such may be assumed as highly probable, the actual proof of it is difficult. It may, however, be stated as certain that the trabeculæ and vessels of large size are usually closely studded with small cells, and it is probable that these are due to a so-called interstitial inflammation. There is more or less pigment scattered about in the trabeculæ and splenic cells, and some authors have described an endarteritis of the splenic arteries.

As an occasional and rare condition I have once met with varicose dilatation of the splenic vein. The case was one of cirrhosis and atrophy of the liver, with thrombosis of the portal vein, in a woman aged 48. The spleen weighed 16 ounces, was rather tough and bloodless, and its capsule was thickened from chronic peritonitis. At the splenic end of the stomach the splenic vein divided into a bunch of dilated veins (splenic varicocele). Upon one of these branches was a saccular aneurism the size of a chestnut, the greater part of it full of laminated clot. The main trunk of the splenic vein was dilated, but not sacculated. Phlebolithes have occasionally been found in branches of the splenic vein.

Abscess of the spleen is somewhat rare. This is a fact of great interest when it is remembered that there is no very obvious reason to be deduced from its position, why the spleen should be exempted from the tendency to the formation of pus which exists in other organs; and that it has peculiar and intimate relations with the leucocytes which do not obtain elsewhere. It is doubtful if spontaneous abscess ever occurs in the spleen; when suppuration does occur it is usually in

* Virch. Archiv., 23, p. 466.

† Journal of Mic. Science, n. s., 15, 368.

‡ Billroth, Virch. Arch. 23, p. 483, and Cornil and Ranvier, *op. cit.*, p. 991.

association with abscesses in other regions as part of a general pyæmia, and is then considered to be of embolic origin. The illustration in Plate vi., fig. 3, is from a case of ulcerative endocarditis. In other rarer cases abscess is sometimes due to phlebitis of the portal or splenic vein, and yet again there is a diffused form of suppuration or sphacelus found in fevers, probably dependent upon thrombosis. I have known abscess to occur also as a consequence of traumatic rupture. Splenic abscess is very liable to be associated with local peritonitis, and to lead to localised peritoneal abscess, and in this case the pus may pass into the pleura or colon.

Encysted abscesses are occasionally found in the spleen with a thick capsule, for which no cause can be assigned. Dr. Moxon throws out the suggestion that some of them may have a hydatid origin.* Others may possibly be explained by some bygone infection of pyæmic nature. Under these circumstances they cannot be considered as undoubted cases of idiopathic abscess.

LESIONS OF THE PULP AND LYMPHOID TISSUES will be described more or less together, as it is hardly possible to separate them satisfactorily. They include various conditions, which may first be enumerated and then described seriatim. They are: acute swelling, softening, atrophy, hypertrophy, leukæmic, lymphadenomatous and tubercular changes, pigmentary deposits and cancer.

Acute swelling, previously described as affecting the vessels, alters the pulp also. Here, as in the vascular system, the disease is one which appears to be most frequently associated with septic fever, and some have attempted to show with those forms in which thrombosis and infarction occur.† It is uniformly present in typhoid and relapsing fever, and also, though less certainly, in typhus, scarlatina, all acute forms of septicæmia, syphilis, both congenital and acquired, and other occasional cases. The acute congestion of malarial fever is not included, because nothing is at present known concerning its nature.

The spleen is usually soft, relatively light in colour, and the Malpighian corpuscles are swollen or congested. Under a stream of water the pulp washes away freely. The minute changes which have been noticed are that the pulp-cells become swollen and granular, and often contain red corpuscles in their protoplasm.* MM. Cornil and Ranvier consider these appearances to be due to a parenchymatous inflammation, but they add that it is not a simple inflammation, since its essential feature is a destruction of the red corpuscles "qui sont mangés par les cellules lymphatiques."

By some these changes are considered to occur not in the pulp, but in the endothelial lining of the veins; but this is rather a matter of interpretation than of actual fact, and depends upon the view taken of the nature of the splenic pulp. If the pulp is formed, as Klein thinks, by cell-budding from the vein walls, it would still be a *pulp* change, though also a vascular one. Upon this point the reader must be referred to the original observations already quoted of Billroth, Klein, Cornil and Ranvier, &c.

It is necessary to make additional mention of the extreme softening which is sometimes found in septic fevers, because, although usually associated with the condition above described, it is not invariably, and in many cases the softening is the more essential and peculiar state. So extreme is it in some cases that the mere incision of the capsule destroys all the shape and substance of the organ. The pulp drains away as a thick fluid, or, to adopt Louis' term, it is reduced to "putrilage." Under such circumstances the spleen is liable to spontaneous rupture.† These cases present great difficulties to investigation, and it cannot be said that the microscope has thrown any light upon the change; but it is probable that it may be regarded as a rapid decomposition occurring during the last hours of life.

Atrophy is usually a consequence of old age, and may reach an extreme degree; the capsule is then opaque and corrugated, the surface of the section pale, bloodless, and unduly fibrous in appearance from the disappearance of much of the pulp. Atrophy is also found in various wasting diseases, accompanied by anæmia, and in some cases also of abundant ascites.‡

Hypertrophy of the spleen (Plates vi., figs. 1—2; x., figs. 6—7), is a condition essentially dependent

* Wilks and Moxon, Lectures on Path. Anat., 2nd ed., p. 486.

† Birch-Hirschfeld, *loc. cit.*

* Hoffmann, Untersuchungen über die Path. Anat. Veränd. der Organe beim Abdominal Typhus. Leipsic, 1869.

† Rokitansky Path. Anat., Syd. Soc. Trans., ii., 168.

‡ Jones and Sieveking, 2nd ed., 1875, p. 655.

upon excessive overgrowth of the pulp or arterial sheaths, or of both together. It has been already stated that in these cases the capsule may be thick, the fibrous and muscular elements of the trabeculæ increased, the arterial walls thickened, and the veins dilated; so that we can now, without enlarging further on these, confine ourselves to the changes in the pulp and periarterial parts.

The spleen may be particularized as being in general over firm, and its section rather pale. The latter is minutely mottled by pale, rather large, and not very well-defined Malpighian corpuscles, with a network of fine white lines, the cut ends of trabeculæ and vessels. The main feature under the microscope is the uniform and crowded appearance of the section. Difficult as it is to make much of a healthy spleen, in hypertrophied spleens there is still more doubt; the pulp and sheaths having lost their distinctive limits, and both together being uniformly stuffed with leucocyte-like cells. (Plate x., fig. 7.) It is not easy to say in what this change consists. Is it due to over activity on the part of the arterial sheaths, or to an increase in the pulp? Both views have received support, and the question cannot as yet be said to have received its solution. But the appearances seem to me to be, on the whole, better explained by the first of the two. Even in the advanced cases the aspect of the section is more that which would be produced by an overgrowth of the cytogenous tissue of the arteries than by activity of the pulp, which, when it is distinguishable, still retains the normal more open texture due to the arrangement of its venous sinuses.

We may next turn to other conditions. Instead of a very large and uniformly mottled spleen, we meet not unfrequently with one of moderate size whose section is studded with irregular or arborescent pale red or yellowish-white masses embedded in its substance. Plate vi., fig. 1. The more pronounced cases of this kind have the yellowish-white masses which Dr. Wilks and Dr. Moxon describe as "tolerably firm and opaque, resembling, at first glance, masses of suet." Others are merely indicated by their pale pink colour, or by yellowish blurred patches in the darker ground around them. In some there is but a diffused irregular mottling; some again in which the Malpighian corpuscles are merely swollen. (Plate vi., fig. 2.) Now all these cases, when examined microscopically, show the nature of their disease very plainly. The arteries in longitudinal section have elongated and branching masses of cells around them, obviously overgrowths of the periarterial sheaths. In transverse section these show as circular or ovoid masses, and between them is seen the pulp tissue atrophied, often much pigmented, and its sinuses dilated. Plate ix., fig. 22. There is no evidence of any overgrowth of the pulp, and the grades between this and what we regard as the more advanced condition, viz., the uniformly enlarged spleen of leucocythæmia, are sufficiently connected to warrant the belief in the identity of the process in the two cases.*

I have previously referred to the ambiguity of the term hypertrophy of the spleen; how it is made synonymous with *enlargement* by many writers, and thus includes the chronic forms of congestion and the enlargement resulting from interstitial thickenings. Even in the more restricted sense adopted here, applying it only to pulp and periarterial changes it is still too comprehensive for simplicity, and includes several diseases which have distinct clinical symptoms. We must say, therefore, according to present knowledge, that there are certain fundamental alterations in the spleen, limited in their number, which combine in varying proportions to produce the distinctive changes which are the recognised accompaniments of certain symptoms. Thus in one class of cases the lymphoid tissue and trabecular system or stroma increase in about equal proportions, when we have as a result the large tough spleen found after prolonged exposure to malarial poisoning, in exceptional cases of cirrhosis; occasionally in rickets.† In

* This description is made to correspond with the phraseology of the present time, but I may perhaps be allowed to express a doubt as to its accuracy, and to say that I regard the distinction between pulp and lymphatic tissues as somewhat artificial. I would do away with it and adopt the term splenic cells, including under this head both pulp and lymphatic tissues. And just as in every other tissue of the body, the intensity of morbid activity extends itself in the neighbourhood of the briskest blood supply,—that is to say, is periarterial,—so here the most marked *pulp* changes are *periarterial*. To put it in an intelligible way, the periarterial cells possess advantages by reason of their position which enable them to command success in the struggle for existence whenever it becomes a question of rivalry between them and those of the pulp.

† I do not here refer to the moderate enlargement found in rachitis, and which I have described before as an early fibroid change, but to those occasional cases of which I have seen five, where in young children with moderate rachitis the spleen has occupied a large part of the abdominal cavity.

these there is no leukocythæmia. In other cases the splenic cells, particularly those arranged round the arteries, increase in quantity less or more; less to the extent of producing localised nodules or tracts, with but moderate enlargement; more, to produce great enlargement of the whole organ with uniformity of colour upon section, in which case there is leukocythæmia. It may occur to some that there is still a third group in which tough yellow nodules are present, forming the appearances which have been designated the hard-bake spleen, but these are of the same periarterial nature, though they have undergone a further fibroid change, an observation made by Dr. Greenfield,* and which may perhaps go some way towards explaining the fact that in this class of cases there is no leukocythæmia.

The experience of Guy's Hospital has been almost without exception that leukocythæmia is associated with the greatly enlarged and uniformly-coloured spleen, not with the more moderate sized and bespotted one, though many pathologists say that the appearances vary in different cases. Rindfleisch† describes and figures, as a leukocythæmic spleen, one which I should certainly have regarded as the spleen of Hodgkin's disease or lymphatic leukæmia.

The leukocythæmic spleen frequently contains one or more yellow wedge-shaped infarctions running from the surface into the substance. The occurrence of these is not difficult to explain if it be remembered that in sections of the viscera, and indeed in the tissues in all parts of the body, when leukocythæmia is present, the spleen not excepted, the vessels are dilated, and in many cases plugged with colourless corpuscles. Under such circumstances thrombosis is only too likely to occur, and in this way not only the splenic infarctions, but the retinal hæmorrhages and the purpuric extravasations which occur upon various parts of the surface have been explained. There is, moreover, an additional risk of thrombosis in the spleen from the excessive activity of cell-growth along the vessels, and which may with ease cause obstruction in some part of their course.

Of the exciting cause of leukocythæmia, and therefore of the morbid changes in the spleen in that disease, little is certainly known, but it is a matter of frequent observation—and this may be of importance—that in no inconsiderable number of cases its subjects have previously suffered from ague or have lived in districts where ague is endemic.* Hence comes an argument that ague, leading to enlargement of the spleen, is in some cases the indirect cause of the leukocythæmia. Upon this hypothesis the spleen is the immediate cause of the prominent symptoms, and that it is so is held by the majority of pathologists at the present time. Some, however, hold that the primary fault is in the blood—a failure of the transition from the embryonal form of corpuscle into the mature red corpuscle; upon this view the spleen is supposed to enlarge in consequence of this arrest of corpuscular metamorphosis. The term leukocythæmia, or white-celled blood, is not applied to a mere temporary increase of leukocytes, —to this the term leukocytosis is confined,— but to a persistent increase of the colourless corpuscles and diminution of the coloured. The blood separates upon coagulation into two parts, each of them characteristic; a large greenish-yellow pus-like clot, and a small one of brick or pale red, the pallor of the tint being due to the fact that red and white corpuscles are intimately mixed even in the darker parts, giving to the whole a stippled aspect when closely examined.

Leukocythæmia is associated in some cases, not always, with an anæmic appearance, and is usually characterised by the occurrence of hæmorrhages and purpura towards its close. It is often accompanied by pyrexia, and runs a chronic course; it may last for four, five, or six years. The concomitant morbid conditions are not many. The vessels in all parts of the body are full of colourless corpuscles, and in many places the corpuscles are found outside the vessels, extravasated in the tissues. From this cause the liver and kidneys are liable to considerable enlargement, and the medulla of the bones assumes a peculiar colour. (Neumann. Mösler). It is a question whether there is more than extravasation, whether, that is to say, there is any actual growth of tumour in any of the affected tissues, except as an occasional occurrence. There may be hæmorrhages or infarctions in the viscera, and the muscular tissue of the heart may undergo fatty degeneration. The lymphatic glands are not enlarged to any noticeable extent, though there are occasional exceptions to this rule.

The *hard-bake* spleen of Hodgkin's disease (adénie, lymphatic leukæmia, lymphadenosis), on the other hand, though not itself undergoing much

* Path. Soc. Trans. vol. 29, 1878, pp. 293—4, and Plate 13, fig. 1.

† Path. Histol. Svd. Soc., vol. i. p. 216.

* Gower's Splenic Leukocythæmia. Reynolds' Syst. Med., vol. v., p. 225.

increase in size, *is* associated with very great enlargement of all the lymphatic glands, and this is no mere simple hypertrophy, but an aggressive growth of their own tissue (Plate x., fig. 8), which infiltrates the neighbouring structures and is also found in the liver, kidneys, bones, connective tissue of all kinds, glands, and skin. The new growth is peculiar in being very prone to caseous and fibroid changes. This disease is, with occasional exceptions, not coupled with leukocythæmia, but is accompanied by fever, and is more rapid in its course. There is, moreover, in some cases a very remarkable and sudden spontaneous diminution in size of some of the leukæmic tumours, though without any corresponding amelioration of the other symptoms. The subjects of Hodgkin's disease are very anæmic, and death results from exhaustion, hæmorrhage, diarrhœa, or some intercurrent inflammation.*

Tubercle (Plate vii., figs. 7 and 8, Plate x., figs. 9 and 10), occurs in the spleen almost invariably as part of a general tuberculosis, and is far more common in children than in adults. It is present in the form of (1) grey grains, which are difficult of detection from their likeness to the Malpighian bodies; and (2) larger millet or hemp-seed sized tumours, which are usually yellow. Plate vii., figs. 7 and 8. These small masses occasionally grow to larger size, when they irresistibly suggest by their appearance that they have a similar constitution to that of the yellow nodules just described as characteristic of Hodgkin's disease. As a fact there has been much discussion concerning their actual seat. Virchow and Billroth† consider that they form in the connective tissue of the spleen, and but seldom in the Malpighian corpuscles. The connective tissue between the veins is thickened, says Billroth; it is the seat of new elements, and the nuclei of the endothelium of the veins proliferate. Foerster is stated, by Cornil and Ranvier, to have met with tubercle in the larger trabeculæ, and also in the Malpighian corpuscles. It appears to me that they usually develop from the splenic cells, though not always in the same way. In some cases they certainly grow round small arteries (Plate x., fig. 10), and take the place of the Malpighian follicle; in others they start at the outer margin of the follicle, and spread from thence into the pulp; in others, again, they appear to start in many small centres in the pulp itself by proliferation of the splenic cells. It is very difficult to push investigation far enough to determine in what elements—lymphatic, vascular, or connective—the earliest beginnings of tubercle originate; nor is there, perhaps, much necessity to do so, for there is no certainty that it always commences in the same tissue. There is some evidence to the contrary. Researches into the nature of tubercle in the lung and serous membranes would seem to show that it forms in the walls of the capillaries, in the adventitia of the finer arteries, within the lumen of and outside the lymph vessels, and in the course of the veins. Should this opinion prove correct it may serve to explain the discordant opinions that have been expressed regarding the seat of tubercle in the spleen. In any case tubercle in the spleen, like tubercle elsewhere, shows the same propensity to early caseation (Plate x., fig. 9), and to form those central masses which have been denominated giant cells, and which have been supposed by some to indicate the tubercular nature of the affection.*

Cancer of the spleen commands but a passing notice, since all pathologists agree that the primary affection is so rare that doubt exists whether any unquestionable case is on record.† It is also rare, though far less so, as a secondary occurrence. When it occurs, rounded masses are present in the substance of the organ, or an infiltration which spreads from the hilus inwards. It is said to be more common with cancer of the stomach than with tumours elsewhere, unless such growths be exceedingly diffused.

Pigmentary excess.—Some slight excess of pigment is present in many of the morbid conditions of the spleen; indeed, it may be doubted whether there is any splenic disease which has not at some time or other been observed to be associated

* The limitation of space, alone forbids my entering upon what would indeed have been a pleasurable labour, the history of these diseases bound up as it is with the names of the most gifted of our pathologists—of Bennett, Virchow, Hodgkin, and Wilks. But this I may say, that no summary of our present knowledge, however short, would be complete did it not perpetuate in some way the names of those who, by the brilliancy of their suggestions and the earnestness of their work, have opened these paths of fresh investigation.

† Virchow's Arch., 23, p. 472.

* This opinion is not justified by the facts. The exact mode of origin of these giant cells is still doubtful, but they have been observed to be present in a variety of conditions of the nature of chronic inflammation.

† Of the cases recorded by M. Besnier, in the 'Dictionnaire Encyclopédique des Sciences Medicale,' M.M. Cornil and Ranvier remark that they are too much wanting in histological detail to carry conviction.

with it. The pigment is situated in the splenic cells; sometimes in the veins as irregular fragments; sometimes free in the stroma. Its origin is uncertain: some think it due to previous extravasation of blood; others to some anomaly in the metamorphosis of the red corpuscles by which these are destroyed in larger numbers than can be properly disposed of, or that the facilities for the removal of refuse products, of which pigment must be counted one, are decreased. But in such cases there is no melanæmia.

Melanæmia, or a morbid excess of pigment in the blood, is a symptom reserved for severe and in most cases typical remittent fevers, if we may exclude certain cases of melanotic sarcoma. The melanæmic spleen is very large, indurated from increase of its stroma, and its colour is greyish or bluish-black from an abundance of black or brown pigment which its tissues contain. In exceptional instances the section has a peculiar spotted appearance from the pigment being confined to the Malpighian bodies.* With the aid of the microscope angular subcrystalline and amorphous granules are found in the blood. They are mostly free, but some are enclosed in the colourless corpuscles. The red cells are diminished in quantity, the white may be absolutely, and are at any rate relatively, increased. An excess of pigment may in such cases be present in the liver, and occasionally also in the brain or kidney.†

The spleen contains some pigment in health, and is more frequently and excessively affected in melanæmia than any other organ. This has led up to the hypothesis that the spleen is the viscus primarily at fault. The pigment produced in the spleen finds its way into the portal blood, and is carried to all parts of the body, so much of it, at least, as is not arrested in the capillaries of the liver or lungs.

This theory may be true for some, perhaps for the majority of cases, but it can hardly be made applicable to all forms of melanæmia. Frerichs‡ has recorded examples, collected from older authorities, Lancisi, Stoll, &c., of excessive deposit of pigment in other organs than the spleen. They are exceptional, it is true, and perhaps cannot be allowed to disturb an opinion founded upon a larger body of evidence. But they suffice to show—particularly when they are taken in conjunction with the melanæmia, which is a symptom of some melanotic sarcomata, with the excessive pigmentation of the skin in some uterine diseases, Addison's disease, and other less definite conditions—that although an excessive *discharge* of pigment may satisfactorily explain some cases, there is yet much to learn respecting the *formation* of pigment; and some of the cases mentioned suggest very forcibly that disturbances of function of the abdominal sympathetic play an important part in their initiation.

The pigment of melanæmia is altered hæmatin.

Yet a few other conditions require mention: these are rupture of the spleen; cysts; malformations; and misplacements.

Rupture of the spleen, Plate vi., fig. 5, is usually the result of excessive violence to the lower part of the chest, or to the abdominal cavity. Its extent will naturally vary from a mere fissure in the capsule to the extremest form of laceration. If extensive, death is speedy from hæmorrhage into the peritoneal cavity, but lesser wounds may undergo partial and even total repair. In tropical climates, where enlargement of the spleen is not uncommon, fatal accidents of this nature are frequent. Rupture sometimes leads to the formation of an abscess in the left hypochondrium, when death, though less speedy, is hardly less sure.

But rupture of the spleen has a more interesting aspect than this obvious and mechanical one; it sometimes occurs spontaneously. This is said to arise in states of congestion in cholera, fever,* and the cold stage of ague. I have once seen a spontaneous laceration where the cause was inexplicable. A man, aged fifty-four, had undergone the operation of colotomy. He was doing well when, on the seventh day after the operation, he suddenly complained of intense abdominal pain, and within three or four hours from that time he died in a state of collapse. The peritoneal cavity contained a large quantity of fluid and clotted blood, and there was a rent in the anterior border of the spleen, round which most of the clot was collected. It has been suggested that sudden movements of the body when the spleen is softened, sudden swelling in the case of ague, may explain such an occurrence. To these it may be added, as a mere speculation, however, that irregular action of the muscular tissue of the spleen, particularly

* Jones and Sieveking's Path. Anat., edited by Payne, 1875, p. 654.

† Bright, Reports of Medical Cases. Frerichs, Klinik der Leberkrankheiten, Bd. i., p. 248, *et seq.*

‡ Klinik der Leberkrankheiten, Bd. i., 326.

* Murchison, *op. cit.*, pp. 385, 405, 629.

if strongly developed, may possibly play some part in occasional cases.

Cysts, simple, dermoid, and hydatid, have been observed. They are all rare. *Malformation* is not uncommon, for the most part to no greater extent than mere fissuring, or the addition of outlying balls of splenic tissue called spleniculi. Occasionally the lobulation is excessive, and I have once seen a large mass in the left hypochondrium which could only be explained on the supposition that it was an enlarged indurated and lardaceous spleniculus. The case was under the care of Dr. Moxon at Guy's Hospital, and the nature of the tumour had been subjected to much discussion during the life of the patient. The inspection was made by Dr. Hilton Fagge.

Lastly, the spleen is occasionally placed abnormally; it may be found in the thorax in diaphragmatic hernia, congenital or traumatic; or it may be found in an umbilical hernia. Movable spleens have been noticed in several instances.

Of the morbid affections of the *nerves and lymphatics* of the spleen we know nothing. It must not, however, be concluded that they are of small importance. On the contrary, the experiments of Tarchanoff and Swaen,* of Drosdoff, and others,† show how large a field there is in this direction for further investigation. The first-named experimenters showed that when the splenic nerves were cut the colourless corpuscles no longer appeared in excess in the blood of the splenic vein; the latter, how completely diminution and enlargement of the organ are subordinate to the control of the abdominal sympathetic. If this be so, and there can be little doubt of it, even without the aid of experiment, we may yet have to go back to some central nerve disturbance to complete the pathology of such diseases as leukæmia and lymphadenosis.

The figures which illustrate the morbid histology of the spleen, Plate ix., figs. 18—22, Plate x., figs. 1—13, are taken from various sources. Figs. 18, 19, 20, 21, Plate ix., are reproductions from Dr. Klein's paper, already quoted. Fig. 22, Plate ix., was kindly made for me by Miss Alice Boole. Fig. 8, Plate x., is reproduced from the Transactions of the Pathological Society of London; and figs. 9, 12, and 13, Plate x., are by Mr. Pearson. For the delineation of the remainder I am alone responsible.

* Archives de Physiologie, 1875.

† Central-blatt für die Med. Wissen., 1876.

A RÉSUMÉ

OF OUR PRESENT KNOWLEDGE OF

DISEASES OF THE SUPRA RENAL CAPSULES.

By JAMES F. GOODHART, M.D.

The Supra renal bodies, always of interest from our ignorance of their function, have of late years, owing to the discovery of Addison, assumed a position of practical importance. Their somewhat grotesque shape and tawny colour are well known. They are situated, each upon the anterior and inner part of the summit of the corresponding kidney, the posterior surface resting on the diaphragm; the anterior covered on the right side by the liver, on the left by the pancreas and spleen. The right capsule, consistently with the position of the right kidney, lies a little lower than the left. Both are placed very close to the spinal column and in the immediate neighbourhood of the central abdominal sympathetic with which they have numerous connections by large communicating branches. They vary in size in different individuals, measuring about an inch and a quarter in width and from an inch and a quarter to an inch and three-quarters in height. Their thickness is from two to three lines, and the weight of each, in the adult, is from one to two drachms. They show, if cut at right *angles to* their surface, a series of layers: an outer buff, an intermediate dark brown, and a central thicker substance of white or grey. These *anatomical facts are by no means unimportant* in relation to diseases of the supra renal capsule. Ignorance of them has led to many mistakes, both by attributing to disease appearances which have been within the range of health, and, though this is less frequent, by overlooking as healthy the product of disease.

A fibro-elastic capsule surrounds the supra renal bodies and sends septa into their substance which subdivide them into cavities containing cells. In this manner an alveolar tissue is formed, enclosing spaces lined by delicate fibrous walls and varying in shape according to their position. Thus a vertical section of the organ shows a layer of rounded spaces under the capsule; farther inwards, elongated cavities (the cells contained in these have been described as cell columns), which anastomose with each other occasionally; and below these another layer of rounded cell masses. (See fig. 155 in Stricker's Handbook. Syd. Soc. Trans., p. 113.) In all these parts the contents of the spaces appear as a homogeneous granular mass of protoplasm in which rounded nuclei are embedded, and but seldom can any separation between individual cells be observed. All the cells are liable to infiltration with oil-drops of various sizes, and the innermost cells of the deepest cortical layer are of a permanent yellow colour, due to pigment which in the mass gives an olive-green or brown tint to this layer. The medulla is more delicate: it consists of an open-textured network of connective tissue in which lie the larger blood-vessels. The meshes contain rounded groups of delicate polygonal cells. The arterial supply is derived from the aorta, and the phrenic and renal arteries; it forms a plexus upon the surface of the capsule, then penetrates into the substance, and terminates in delicate walled capillaries which ramify upon the walls of the alveoli. The veins, for the most part, discharge into a central vein which leaves the organ at the hilus and joins the inferior cava.

Nerves are richly distributed in the supra renal capsule. They are derived from the semilunar ganglion, the renal plexus and the phrenic and pneumogastric nerves.

Entering the medullary substance they form large decussating cords interspersed with bipolar and multipolar ganglion cells. Their exact mode of termination is unknown. but it has been ascertained that the cortex is in the main supplied by nerve fibres and that ganglionic cells are only occasionally present.

The morbid conditions of the supra renal capsule which require description are: hæmorrhage into the capsule, lardaceous degeneration, chronic inflammation, tuberculosis, sarcoma, and carcinoma. Other diseases are occasionally present, such as atrophy, congenital or senile; cysts, hydatid and serous; vascular or cavernous tumours; and gummata; but these are of such rarity that we may be content with their enumeration.

Hæmorrhage in the capsules has been noticed in many cases. Rokitansky* and Wilks† both state that it is not infrequent. The apoplexy, as it is sometimes called, takes place in the medulla, and the cortex becomes distended into a cyst. The effusion may be symmetrical. It has been found in the newly-born infant as well as in the adult, but there are no constant conditions with which it is known to occur, and none that can be said to predispose to it.‡ It has occasionally been associated with some of the symptoms of Morbus Addisonii, but never with any such that could be considered typical of that affection.§

Lardaceous degeneration occasionally attacks the supra renal bodies, which become enlarged, pale and hard, and their medullary portion translucent.‖ It affects the vessels of the medulla and the fibrous septa; is only present with a similar change in other viscera; and no special symptoms are associated with it.

Inflammation.—Suppuration has been found occasionally in one or both supra renal bodies. It has not been followed by any special symptoms,¶ and, unless it be in conjunction with the caseous changes of Morbus Addisonii, it is dependent upon some other disease in the neighbourhood—of the pancreas, or spine. Except such cases as these, and perhaps two recorded by Virchow,* in which the capsules were swollen and studded with extravasations of blood, acute inflammation is unknown. Interstitial inflammation, or the increase of connective tissue elements between the columns of cells, is much more common; but as this is generally associated with, and is one of the changes proper to, Addison's disease, the consideration of it may, for the moment, be deferred.

Caseous disease of the supra renal capsules.—(Tubercular—Strumous—or Addison's disease.) I prefer the heading given, although "tubercular disease" is perhaps the better known, because there is reason to think that Addison's disease is not invariably due to the presence of *tubercle* in the adrenals. The capsules are enlarged, indurated, and generally adherent to the parts around. Their surfaces are nodular or irregular, and often yellow, like concrete pus. (Plate vii., fig. 5.) Upon section the healthy appearance is lost, and in its place "two kinds of material are seen: one, making up the greater part, is more like hard cheese, being opaque, yellowish-white, and toughish or friable; the other, in lesser quantity, is more in the outer part, is grey and translucent, having a slightly pinkish appearance when exposed to the air."† (Plate vii., fig. 6.) The yellow material frequently shows softened parts containing pus-like fluid, and others in which lime salts are deposited, converting the organ into a cretaceous mass. The grey and the yellow portions have characteristically different microscopical features: the former, which represents the active stage of the disease, is composed of a close arrangement of round nuclei in a hyaline or granular protoplasm, and resembles the granulation tissue common to inflammation of the connective tissue, and to some spreading or infiltrating tumours. This growth spreads thickly in the trabeculæ of the supra renal capsule, and gradually replaces the proper elements, which atrophy as it advances. (Plate x., fig. 14.) The yellow portion contains much less cell growth, and is composed mainly of granular structureless fatty detritus, calcareous grains, and tough bands of hyaline fibroid tissue. (Plate x., fig. 15.) The two substances, grey and yellow, thus represent two stages in the life history of a cellular growth in the capsules; the grey the active or growing period; the yellow the residuum when the growth has ceased, the

* Path. Anat. Syd. Soc. Trans., vol. ii., p. 245.

† Trans. Path. Soc. Lond., vol. xiv., p. 256.

‡ Unless a typhoid condition is to be excepted. See Virchow Krankhaften Gesch., 1864, vol. ii., p. 696.

§ I have only recently made an inspection of the body of a man who, although suffering from emphysema, died suddenly and unaccountably. Both supra renal capsules were more than twice their normal size, and so infiltrated with blood that their healthy structure was quite lost and the neighbouring branches and ganglia of the sympathetic were swollen and congested.

‖ Payne's ed. of Jones and Sieveking's Path. Anat., p. 663.

¶ Cornil and Ranvier, Manual d'histologie Path., p. 1002.

* Krank. Gesch., Bd. 2, p. 696.

† Wilks and Moxon, *op. cit.*, p. 494.

new material degenerated, and cicatrisation is more or less completed. With regard to the nature of the growth, it is generally held to be tuberculous, and upon these grounds: first, that the grey material which occupies the outer zone is quite like the grey and rather vascular shell of yellow tubercle in the brain, and also like the grey infiltration so often present in tubercular lungs; secondly, the grey passes rapidly into yellow material or becomes caseous, a well-known characteristic of tubercle; thirdly, the mere fact that it is yellow and pultaceous is sufficient to attest its tuberculous nature to many.

Rindfleisch* gives the following description of the minute anatomy of the disease:† "It begins with an eruption of grey nodules, larger than a millet seed, in the medullary layer of the organ. We cannot localize them more precisely, whether in the sheaths of the vessels, in those of the nerves, or in the lymphatics. The nodules coalesce to form larger aggregates, which may ultimately attain the size of a pigeon's egg and more; these speedily become cheesy. An infiltration of the connective tissue of the septa with small cells, which I regard as inflammatory, takes a great part in this process." To these various facts it may be added that miliary tubercle has been found in the supra renal capsules in association with miliary tubercle in other organs, and that a large number of cases of Addison's disease are, in like manner, co-existent with tubercle elsewhere. On the other hand, it is to be remembered that in the supra renal capsules we are dealing with organs prone to the accumulation of fatty material in the cells of their cortex, therefore yellowness is of less significance here than elsewhere; next, that all such accumulations of degenerate products are in themselves fertile sources of irritation of their surrounding connective tissues, and thus of an interstitial inflammation, of which, in great part, Addison's disease consists; thirdly, that a by no means inconsiderable number of all the recorded cases of the disease have been unaccompanied by any tubercle in the viscera;‡ and lastly, that caseous inflammation of the supra renal capsules is not uncommon in connection with diseases of the spine, that is to say, with a local affection in the neighbourhood of the capsules from which a chronic inflammation could readily extend to them. Greenhow gives seventeen cases of the sort, and I could add to them four or five more.

The facts that have been collected by various observers seem, therefore, to show that while the larger number of cases of Morbus Addisonii are of a tubercular nature, some may be of the nature of a chronic inflammation, and some perhaps may originate by the extension of the inflammation from surrounding parts.

Accessory morbid changes in the abdominal sympathetic.—Whatever may be the origin of this caseous change, tubercular or non-tubercular, originating in the capsules or extending to them from the extraneous tissues, the resulting inflammation leads in most cases to some thickening of the neighbouring parts, and this is important because the capsules are situated in the thick of the abdominal sympathetic and that system of nerves is only too likely to become involved. The first careful dissection of the nerves in Addison's disease was made by Dr. Habershon,* and the sympathetic ganglia and branches were found embedded in an unusual quantity of dense fibrous tissue. Since then, other observers, English and foreign, have obtained like results,† though cases are also on record in which the nerves are reported to have been quite healthy.

A few other morbid changes have been noticed to be occasionally co-existent with caseous disease of the capsules by Addison and others; these are enlargements of the solitary glands of the intestine, mammillation of the stomach, ‡ and enlargement of the spleen.

The relation which disease of the supra renal capsules bears to the symptoms of Addison's disease.—The symptoms of the disease may best be given in the words of the illustrious physician whose name it bears; they are, "anæmia, general languor and debility, remarkable feebleness of the heart's action, irritability of the

* See also Virchow, Krankhaften Geschwulste, Bd. 2, p. 688.

† *Op. cit.*, vol. i., p. 229.

‡ Of the 230 cases collected by Greenhow (On Addison's disease. The Croonian Lectures for 1875. Longman and Co.), 103 were virtually uncomplicated. Of 159 cases tabulated by Klebs (Handbuch der Path. Anat., 1876, Bd. 1, 597), 55 were non-tubercular, 86 tubercular, and 18 doubtful.

* Guy's Hosp. Rep., Ser. iii., 1864. The preparation is preserved in the Museum of Guy's Hospital. A similar one, beautifully dissected by Mr. W. Pearson, has lately been added to the Hunterian collection at the Royal College of Surgeons.

† Krank. Geschwulst, Bd. 2, p. 701.

‡ This condition has of late been subjected to microscopical investigation by Dr. Sydney Coupland and Mr. Schäfer. *Vide* Greenhow, *op. cit.*, p. 29, and Plate.

stomach, and a peculiar change of colour in the skin." The melasma, already figured in the 'Atlas of Diseases of the Skin,' is due to a deposit of pigment in the deeper layers of the epidermis or rete mucosum; a similar deposit takes place also in the papillæ of the tongue, and in the mucous membrane of the lips and cheek. The disease is often very chronic, sometimes lasting for years, but, so far as is known, is always fatal. The immediate cause of death is sudden syncope, or slow exhaustive asthenia.

Addison at first supposed that all or several alterations in the structure of the supra renal capsules might lead to the characteristic symptoms which he was the first to group together as distinctive of disease in a definite part. He afterwards modified his views, it is believed, and surmised not only that the essential change was less liable to variation than he had supposed, but also that the important factor in the production of the symptoms was the implication of the abdominal sympathetic, not the destruction, more or less, of the supra renal capsules. Dr. Wilks was the first to show, by the publication of cases and otherwise,* that only in one of all the affections to which the capsules are liable, are the particular phenomena present; that the clinical features of Addison's disease are pathognomonic of a yellow cheesy change of their substance. Virchow has, to a certain extent, combated this notion, and declares that, notwithstanding this very frequent association, other diseases of the supra renal bodies are met with which show a similar combination of symptoms. The latest writer on the subject, Dr. Greenhow, already alluded to, has attempted to settle the question by a careful analysis of as many of these *other* cases as were accessible to him; and he shows very conclusively that the nature of the majority of all the received cases of Addison's disease, unaccompanied by the proper morbid changes, is more than doubtful. He is, therefore, quite in agreement with Dr. Wilks that the peculiar changes in the supra renal capsules in Morbus Addisonii are remarkably constant, and so large a number of facts are now upon record that it is difficult to understand how there can any longer be a doubt about the matter.

The question is, however, not quite exhausted when this result is attained. We have still to consider the bearing of an additional fact: that this same cheesy state may destroy a part or the whole of one or both the supra renal capsules without producing any of the characteristic symptoms. Addison had fully appreciated this circumstance also, for it was only too evident that, in his most typical cases, the disease was of no recent date. This led him to surmise that their essential factor could hardly be the destruction of the capsules, nor yet the destruction of them as capsules in any particular way, since every known form of change, caseous and non-caseous, may occur without the production of the bronzed skin or abdominal disturbances, which are requisite for the identification of Morbus Addisonii. Hence it seemed probable that the symptoms were due to the implication of the large nerve trunks which are so intimately connected with the capsules, and this view has been adopted by all subsequent writers who allow that Addison's disease is a reality. It receives its strongest support from the fact that the bronzing, &c., are most pronounced where the capsules are shrivelled and calcareous, and buried in thickened fibrous tissue, — that is to say, in those cases in which the destructive effects of strangling pressure upon the surrounding parts would be most marked; while they are absent when the disease is early, or partial, or rapid in its course.

The advance of opinion has therefore had the effect of modifying the hypothesis originally promulgated; has reduced the significance of destruction of the capsules, and brought into greater prominence the chronicity of the process and the atrophy or destruction of the neighbouring nerve trunks. But if these are the essentials of the change, there is no good reason to doubt that, should any other affection run a similarly protracted course, implicate the same structures, and lead to fibroid thickenings, it would be associated with a similar train of symptoms. No disease is so likely to bring about these requisite conditions as a chronic inflammation; but should a fibrous cancer or some like growth be found to occur, the clinical phenomena of Addison's disease might perhaps be present. This seems to be the position to be assumed at the present day. In the great majority of instances a particular lesion of the capsules is associated with particular symptoms, and it is the opinion both of Dr. Wilks and Dr. Greenhow that no well-authenticated cases are yet on record where the latter have been present without the

* Guy's Hosp. Rep., Series iii., vol. viii., 1862, p. 1.

former. But if chronic inflammation is the only essential requisite, there is no reason to hope that the supra renal capsules enjoy a monopoly in this region for the production of fibroid tissue, and for purposes of insidious destruction of the abdominal sympathetic; and we need not, therefore, be surprised if, as an occasional and rare occurence, some disease of the spine, or pancreas, or other tissue, should lead to the symptoms which Addison so well pourtrayed, and this even perhaps without the destruction of the capsules. An exceptional case will not detract from the reality or importance of Addison's discovery; on the contrary it would, as it seems to me, tend to place it upon a surer, because upon a wider, basis of support.*

Tuberculosis.—It need only be repeated that tubercle is sometimes, not often, found in the adrenals associated with tubercle in other viscera, and that Virchow, Rindfleisch, and others regard it as the primary element of Addison's disease. Apart from this it has no significance and no symptoms.

Adenoma.—There is occasionally present in one or other of the capsules a circumscribed tumour of ochre-yellow colour and soft consistence to which Virchow has applied the term supra renal goitre or struma supra renale. (Plate vii., figs. 2, 3, and 4). Under the microscope (Plate ix., fig. 23), the structure of this is found to be composed of tubes or columns, or masses of cells crowded with fat granules of all sizes. These tumours are in fact composed of an overgrowth of the glandular follicles, the cells of which are overcharged with fatty matter. Except for this increase of fat they are composed of healthy supra renal structure. The large tumours are usually unilateral, but smaller masses may be found in both capsules.

Tumours (Plate vii., fig. 1), are occasionally found in the supra renal capsules. They may be either carcinomatous or sarcomatous—more often the latter.* In virtue of the similarity which exists between the medullary portion of the capsules with its many nerve cells and delicate intercellular connective tissue, and healthy nerve tissue; and between the delicate stroma which exist in some of its tumours and nerve tumours, Virchow has proposed to consider the medullary part of each capsule as nervous tissue, and its tumours as gliomata.†

New growths in the supra renal capsules are far more often secondary than primary, and occur as part of a diffused outbreak in many organs. But occasionally the disease is primary, and is then usually sarcomatous and often melanotic,—that is to say, contains more or less pigment. Dr. Moxon records a case of primary sarcoma of both the supra renal bodies as large as a fœtal head.‡ It is now well known that tumours of the capsules are not usually associated with any special symptoms.

* Since the above was written, Dr. Robert J. Edis has reported in the Boston Medical and Surgical Journal, December 19, 1878, "a case of general cancer including the supra renal capsules, with symptoms of Addison's disease," which illustrates some of the above remarks and supports the observation of Virchow that the symptoms of Addison's disease are occasionally present when the proper morbid changes are absent. . . The patient, a gentleman of 38, was seen by Dr. Heslop, of Birmingham, and several American physicians; and the diagnosis of Addison's disease was made by all: though it must be allowed that the "bronzing" was not remarkably pronounced, and the gastric symptoms were nearly in abeyance.

* Wilks and Moxon, 1875, p. 495.

† Krank. Gesch., vol. ii., p. 150.

‡ *Loc. cit.*

AN

ATLAS OF ILLUSTRATIONS

OF

PATHOLOGY

COMPILED (CHIEFLY FROM ORIGINAL SOURCES)

FOR

THE NEW SYDENHAM SOCIETY.

FASCICULUS III.

DISEASES OF THE LIVER.

(PLATES XI. TO XVI.)

LONDON:
THE NEW SYDENHAM SOCIETY.
1880.

AGENT—H. K. LEWIS, 136, GOWER STREET, W.C.

BOMBAY BRANCH
OF THE
Royal Asiatic Society.
22 CLASS 13 Aug 81

PREFATORY NOTE.

THE present Fasciculus of the 'ATLAS OF PATHOLOGY' illustrates some of the diseases of the Liver, as follows:—

PLATE XI. Lymphadenoma.
" XII. FIG. 1.—Dilatation of the ducts from obstruction.
" " FIG. 2.—Carcinoma of the Liver, with obstruction of the ducts and retention of bile.
" XIII. Syphilitic cicatrices in the Liver.
" XIV. FIG. I.—Acute yellow and red atrophy of the Liver.
" " FIG. 2.—Microscopical appearances of the same.
" XV. FIG. 1.—Lardaceous disease of the Liver.
" " FIG. 2.—Lardaceous disease, showing the iodine reaction.
" XVI. FIG. 1.—Cancer of the Liver.
" " FIG. 2.—The Nutmeg Liver.

The next Fasciculus will complete the coloured drawings of the diseases of the Liver, and will contain the plates of illustrations of the morbid histology, as well as a *Résumé* of our present knowledge of the morbid anatomy, of the organ.

PLATE XI.

LYMPHADENOMA OF THE LIVER. From a drawing by Burgess; in the private collection of Mr. Hutchinson.

E. Burgess del. lith. ad nat.

Wm. Newman & Co. imp.

PLATE XII.

FIG. 1. DILATATION OF THE BILE DUCTS IN THE LIVER from the pressure of a gall-stone in the cystic duct. From a drawing by Hurst; in the museum of Guy's Hospital.

FIG. 2. CANCER OF THE LIVER, with dilatation of the ducts and staining of the hepatic tissue. From a drawing by Hurst; in the museum of Guy's Hospital.

Fig. I.

Fig. II.

PLATE XIII.

Syphilitic Cirrhosis of the Liver. From a drawing by Burgess; in the museum of the London Hospital.

PLATE XIV.

FIG. 1. RED ATROPHY, WITH ACUTE YELLOW ATROPHY OF THE LIVER. From a drawing by Dr. Moxon; in the museum of Guy's Hospital.

FIG. 2. MICROSCOPICAL APPEARANCES OF THE YELLOW SWOLLEN PARTS OF THE LIVER (acute yellow atrophy).

a. Healthy liver cells.

b. The tissue breaking down.

c. Granular relics, with a few hepatic cells remaining in the granular stroma, which is not thickened.

From a drawing by Dr. Moxon; in the museum of Guy's Hospital.

FIG. 3. MICROSCOPICAL APPEARANCES OF RED ATROPHY OF THE LIVER.

d. The more healthy parts, with fibrous tissue between the columns of cells.

d'. Part from which the cells have been pencilled to show the excessively thick stroma.

e. Liver cells reduced to small size, and separated by much fibrous tissue,—the greatly thickened natural stroma.

f. Changes still more advanced, the hepatic cells being mere relics, and the whole converted into fibrous tissue.

Around the portal veins (*g*) a quantity of inflammatory corpuscles crowd the stroma.

From a drawing by Dr. Moxon; in the museum of Guy's Hospital.

Fig. I.

Fig. II.

Fig. III.

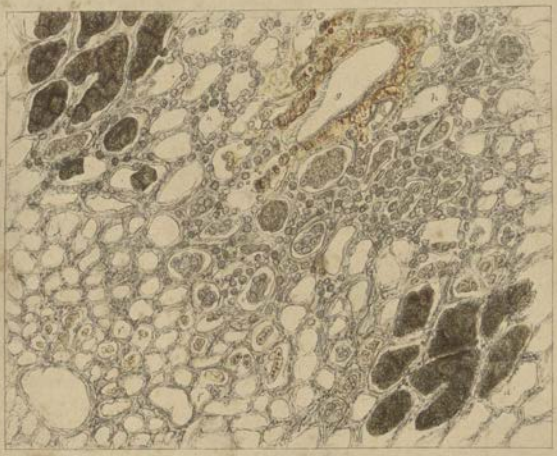

W. Mossman del. E. Burgess & Hill. West, Newman & Co. imp.

PLATE XV.

FIG. 1. LARDACEOUS LIVER. From a drawing by Tuson; in the museum of St. George's Hospital.

FIG. 2. LARDACEOUS LIVER, showing the iodine reaction. From a drawing by Dr. Westmacott; in the museum of St. George's Hospital.

PLATE XVI.

FIG. 1. CANCER OF THE LIVER. From a drawing by Hurst.

FIG. 2. NUTMEG LIVER. Chronic congestion and atrophy of the liver from mitral lisease. From a drawing by Hurst.

Fig 1.

Fig 2.

APPENDIX.

PLATE XI.

Lymphadenoma of the liver. — The figure represents a section through the right lobe of the liver, a part of the under surface being also visible. The liver is enlarged by the presence in it of numerous yellow masses which appear on the surface as elevated tubera, and on the section as of somewhat irregular shape and outline. These are the lymphadenomatous tumours; they are unusually large, and their margins are ill-defined, blending by infiltration with the surrounding gland substance. In several of them transverse sections of large vessels are discernible.

But the figure depicts other morbid appearances. The liver is throughout yellow and mottled; it is nowhere healthy. This is in part due to the presence of vast numbers of smaller tumours of similar nature to the larger ones; and in part to a general infiltration of the hepatic lobules by lymphadenomatous growths. The smaller nodules are in most cases surrounded by an annular congestion of the liver substance, due in all probability to dilatation of the radicles of the hepatic vein and its tributary capillaries, similar to that present in the "nutmeg" liver, but here produced, not by obstruction behind the hepatic vein, but by the presence of the new growths within the liver.

Lymphadenomatous tumours such as these are not common. When the liver is affected it is by small isolated yellow nodules, few in number, situated in the portal canal, or by growths which, running in the course of the portal vessels, assume on section a streaky figure. Such an extreme condition as is represented in the plate is one of rarity, but it may with advantage be compared with the lymphadenomatous kidney, Fasc. I., Plate I., Fig. 5, which presents somewhat similar appearances, and is perhaps more common.

The following are the notes of the case. In some respects it was a very extraordinary one. The man was admitted on account of pan-ophthalmitis of both eyes, and with the history that he had recently recovered from an acute chest ailment. Both eyes were quickly lost. Next he had severe pains in the back, and then jaundice. His temperature fell below normal, and he was very feeble. The nature of the disease was not conjectured until after death, when Dr. Sutton found the changes of lymphadenoma in the liver, spleen, glands, and other parts. The diagnosis was verified by the microscope by Dr. Sutton, and a careful examination of the eyes was made by Mr. Nettleship.

George Butler, æt. 32, admitted under Mr. Hutchinson's care into the London Hospital, January 23, 1876. He stated that his sight had been quite good until a fortnight previously, when both the eyes became bloodshot, "there was some discharge from them, and in two days they were closed up." He had been taking cod-liver oil, and he thought this had brought out a nettle-rash which just preceded the failure of sight. On examination the corneæ were very hazy, as if burnt with lime, and the pupils were blocked with large masses of lymph. There was great chemosis. The discharge was not purulent, and only slight; serous or mucous. He had a very feeble pulse, which was unequal in force. He said that he had had an attack of pleurisy five months previously. He resumed work afterwards till again laid up with inflammation of the lungs, when he was for six weeks in bed. He had not been to work since a month before Christmas. He had some venereal affection seven years previously, but was not very definite in his account of it. He had one child, aged five years.

On February 14th Mr. Hutchinson removed the right eye on account of pain. The patient considered himself relieved by this operation. A few days later he complained of pain in his back. The physical signs showed "a little comparative dulness below left clavicle, with sonorous rhonchus there and behind. The liver seemed a little large, but not tender. The spleen was not enlarged." March 14th. Scarcely any air entered the lower parts of either lung. The pulse was extremely feeble. There was a considerable

109544

amount of jaundice. He had become much emaciated.

On February 22nd the temperature was 100°. It sank on 24th to 99°, and then gradually rose till, on March 1st, it was 102·4°. It then sank again to normal on the 5th; rose to 100·2° by the 9th; on the 10th fell below normal, and remained so to 13th; and then sank to 97° on 14th (day of death).

Post-mortem (by Dr. Sutton.)—Body badly nourished, but not exceedingly wasted. One eyeball had been removed; the other had its cornea opaque. It was taken out and reserved for examination. Nothing was found in the orbits to account for the changes in the eyes. The skull, scalp, and membranes of brain seemed normal. Heart and pericardium normal. Pleura: the right cavity contained a quantity of serous fluid, and the pleura was studded with a number of fine grey bodies, some of which were about the size of tubercles, others larger. There was lymph in the right pleura. The lung, with the exception of some collapse, presented no very noticeable changes. It was free from deposit. A few of the bronchial glands, near the root of the lung, were enlarged. In consistence and colour they resembled parsnips. The other lung presented no very noticeable change. The diaphragm was studded by many masses of a greenish yellow colour, and of tough, firm consistence, some of which were confluent and thickened the muscle and united it firmly to both liver and lung. The liver was larger than normal. On section, about the middle of the right lobe, there was a large firm greyish yellow mass, tough, and extending in various directions through the surrounding hepatic tissue. In other parts, and around this mass, it was studded by a great number of small masses, the colour and consistence of which were very like the larger one, and varied in size from a pin's head to a sixpenny piece, or much larger. There were no nodular masses near the surface. Close to the hepatic duct the glands were enlarged, and resembled in colour and consistence the other enlarged glands. There were some enlarged glands in front of the pancreas, forming a mass as big as a large egg. These glands also were firm, of a greyish yellow colour, and cut somewhat toughly. They did not extend into the pancreas. The spleen was studded by masses of a greyish yellow colour, firm, irregular in shape and in size from that of a pin's head to a large pea. The stomach presented no noticeable change. Many of the lumbar glands were much enlarged, and had the same appearance as the others. The kidneys were normal. One gland in the right axilla was about half an inch long, was firm, and on section was red in great part, but studded with a number of greyish pink masses. The latter seemingly were isolated, early lymphadenomatous changes. On the left side of the neck several glands formed a mass about one inch and a half to two inches long, and these glands also resembled the one removed from the axilla in the fact that they had isolated greyish masses scattered through them. The yellow colour of the glands and other parts was clearly bile staining. The skin generally had a jaundiced appearance, and the serum in the right pleural cavity was markedly bile-stained. It is most probable that the jaundice had been caused by pressure of some glands on the common bile or hepatic duct.

PLATE XII.

FIG. 1. *Dilatation of the bile ducts.*—From a section of a liver in which the bile ducts were dilated from obstruction caused by the pressure of a gall stone lodged in the cystic duct. The surface of the section is represented as studded with cysts of various sizes, containing yellow or greenish yellow contents. At first sight these might be supposed to be abscesses, but the absence of any change in the hepatic tissue round the cyst, the absence of anything like thrombosis in the veins, and the uniformity in the appearance of all the cavities suggest an origin in dilated ducts rather than in phlebitis of the radicles of the portal vein, and the account of the autopsy confirms this view.

From a woman, aged 48, who was admitted, under the care of Dr. Addison, into Guy's Hospital in 1841. She died four days after her admission.

The clinical history of the case has been lost. The notes of the autopsy are as follows:—

The body was much emaciated and tinged of a bright lemon-colour.

The cavity of the chest was small, being encroached upon by the contents of the abdomen and the consequent displacement of the diaphragm. The pleura covering the lower lobe of the left lung was covered with a layer of recent lymph; a similar layer also glued the upper and lower lobes feebly together. The fluid was in very small quantity. There were

some old adhesions upon the right side. Both lungs were a little œdematous at the posterior parts, and the lower part of the lower lobe of each was much compressed, fleshy, and airless.

The heart was small but healthy.

Abdomen.—The liver was very large, and its surface uneven from numerous small rounded elevations of a paler colour than the rest of the organ. These proved to be small cysts. They varied in size, some being one-third of an inch in diameter, and were very numerous. They contained a thick creamy fluid, almost puriform, tinged with bile. The intervening portions of the liver were firm, dark-coloured, and presented a nutmeg appearance.

The gall-bladder was small; its coats were thickened, and its cavity contained a fluid very like that in the cysts. Within the ductus cysticus was a small rounded calculus about the size of a marble, consisting of inspissated bile and cholestearine. It pressed upon the orifice of the hepatic ducts, which were much dilated and their coats thin. The common duct was of natural size, and its opening into the duodenum pervious, admitting a good-sized probe.

The kidneys were small, shrunken, pale, and slightly granular. The other viscera were healthy.

Fig. 2. *Cancer of the liver.*—This drawing, from the Museum of Guy's Hospital, is without history of any kind; but it explains itself. It is entered in the catalogue, "Portions of a liver deeply coloured from retained bile. On the surface are numerous carcinomatous tubercles. The bile ducts throughout the liver are very much distended." Little more need be added to this. The surface of the section, while still retaining its proper lobulated appearance, is stained throughout of a dark olive-green colour from retained bile. Small circular nodules of cancer are seen in parts, and the dilated bile ducts, which are unstained, are prominent features of the picture.

The case is no doubt one of secondary cancer of the liver, associated with, perhaps derived from, some mass of similar nature in the portal fissure or larger bile-ducts.

PLATE XIII.

Syphilitic cirrhosis of the liver.—The disease is characterised in this, as in other similar specimens, by some slight thickening of the capsule, and by adhesions to surrounding parts; by pale grey scars, one being visible on the convex surface of the right lobe; and more particularly by the distortion produced by many deep and abnormal fissures. These are the result of extensive syphilitic deposits in the substance of the liver which have become absorbed, and are now represented by these deep scars.

The right lobe has borne the brunt of the disease, and the left would appear to have undergone some compensatory hypertrophy, a not unusual result of atrophy of any large portion of the dominant lobe. The liver was contracted, and on section there was but little gummatous deposit, but extensive tracts of fibrous tissue.

There is no further record of the case.

From a drawing by Burgess in the Museum of the London Hospital.

PLATE XIV.

Fig. 1. *Acute yellow and red atrophy of the liver.*—The figure represents an antero-posterior section of the liver with the gall-bladder laid open on its inferior surface to the right hand of the plate. Above the gall-bladder the liver substance is firm, dense, and fibrous, its lobulation lost, and its colour a brick-red or coppery. This is the red atrophy. Similar appearances present themselves in other parts of the section, particularly in the course of some of the larger vessels, both portal and hepatic, but the remainder is chiefly characterised by an opaque yellow mottling of the surface and a swollen hazy appearance of the normal lobulation of the liver, most marked in those parts which show best the rhubarb-yellow change. This is the acute yellow atrophy. A portion of the surface and its capsule is represented also, with the yellow change showing through the capsule in part, but much broken up by a green or dull brown.

Figs. 2 and 3 represent the microscopical appearances found in the specimen depicted in fig. 1.

Fig. 2 is from the yellow part, and shows the hepatic cells comparatively healthy in one corner. The remainder of the figure shows a granular yellowish-brown stroma, from which the liver cells have almost entirely disappeared.

Fig. 3 is taken from a part which has undergone red atrophy. It is remarkable for the

excessive amount of fibrous stroma between the liver cells, many of which have been compressed into masses, and others are mere relics. It is unnecessary to go more minutely into these appearances now, as the change will be described in detail with the résumé of morbid histology which will appear in the next fasciculus.

The plate is from originals by Dr. Moxon.

From a woman, aged 34, who was admitted into Guy's Hospital under the care of Dr. Moxon in 1871. She was a married woman with six children, but at the time of her fatal illness was living with another man, and had suckled her last baby to within five days of her admission. Her illness began five weeks before her admission with a cold, ushered in by a rigor and general malaise. She became jaundiced the same evening, and three weeks later she came under the care of Dr. Pye-Smith as an out-patient with the conditions of simple jaundice. The liver was then an inch below the ribs.

When admitted into the hospital she complained of yellowness of her skin; of nausea and pain in her side. She was of dark complexion, of average height, and fully developed. There was nothing of unusual nature in her illness. The liver was enlarged, extending nearly to the umbilicus; its surface was smooth, and its substance, as in simple jaundice, was soft, so that its edge could scarcely be felt. There was some doubtful resistance in the neighbourhood of the gall-bladder. The other viscera were normal. The urine was very dark, containing a large quantity of bile pigment, an excess of mucus, but no albumen. There were no ecchymoses; the cerebral functions were normal; the temperature 98·1, and the pulse 84.

For the next day or two she was sick at times, with pain when she took food, and on the 30th she had another rigor, otherwise she was better.

On October 31st she complained of pain in her abdomen.

Nov. 3.—A hydrochloric acid bath was ordered, and from this time she became plaintive and ill; at first on account of severe pruritus and eczema. The liver was now noticed to be only of normal size.

Nov. 11.—She was somnolent, and thought to be drunk, as two brandy bottles were found under her pillow, one full, the other empty.

Nov. 12.—She was drowsy; putting out her tongue when bidden to do so, but not answering questions. The pupils were dilated, the liver dulness diminished. The excreta passed under her.

Nov. 13.—Much in the same state. Was ordered twenty grains of elaterium powder.

Nov. 14.—In the condition of icterus gravis; deeply comatose, but fidgetty. Breathing stertorous; pupils dilated widely; conjunctivæ sensitive. Pulse very rapid, 140; skin sweating; excreta passed involuntarily. A small quantity of urine was obtained by catheterism. She died the next day.

The inspection was made thirteen hours after death. The body was spare, deeply jaundiced, and marked over with eczematous scales and scratches.

The brain quite healthy; its tissues white, but the serum yellow. Lungs and heart quite normal.

The stomach contained blackish mucus; the duodenum contents of dirty blue-black appearance. No evidence of bile pigment could be obtained by the usual tests. This black material extended as far as the middle of the colon, and was probably altered blood, as some blood flecks were found adhering closely to the coats of the bowel.

The liver had a peculiar appearance; it was wrinkled, flabby, and small. It was nearly covered by the lung above, and failed to reach the margins of the ribs below by two inches. It had a dirty clay-colour, and was uneven from elevations of a yellow hue from the size of a hemp-seed to that of half a pea. These were mostly in the middle of the organ, none in the anterior part, which was dark red and uniform.

A section of the organ showed that numerous clusters of lobules were in a state of yellow atrophy, with its characteristic colour between sienna and cadmium. They were all larger than normal, and between and around the parts so altered, which were scattered with extreme irregularity, yet held chiefly to the middle and hinder parts of the right lobe, was another change, in which the liver was of a deep red, like the colour of blood clot, its lobules being small, inconspicuous, and in part indistinguishable. This condition was present throughout the anterior edge for an inch and a half of its depth. Plate XIV., Fig. 1.

The kidneys were deep-coloured, and greenish and opaque-looking. As usual in yellow atrophy, much fat was present in the epithelium. The bladder was quite empty. The genitalia normal.

Of the two parts, the red and the yellow, the latter was the less diseased of the two. The

greater part of it, however, consisted of formless flocculent relics of the stroma crowded with grains of cell detritus, with an occasional shrivelled cell or two. The destruction of the cells was most advanced near the portal veins, around which there was more or less inflammatory corpuscular product.

The red part was more constructive in its nature. The vascular plexus in the remains of the lobules was thickened by the formation of new fibrous tissue, the cell containing meshes, being in this way much reduced in size, and the cells, which should have been within, either small or represented by grains of pigment. These cells resembled the epithelium of the capillary bile-ducts.

Abstract from the report of the case by Dr. Moxon in the 'Transactions of the Pathological Society of London,' vol. xxiii., 1872, p. 138, *et seq.*

PLATE XV.

FIG. 1. *Lardaceous liver.*—A section of liver is represented which has undergone an extreme amount of the lardaceous change. To the left hand of the figure and round its margin the appearances are those of somewhat advanced lardaceous disease, the artist having succeeded in expressing the tint and the translucency of the bacon-like change. But the central, lighter part shows a still more extreme stage of disease. The morbid material would appear to have been deposited in such quantity as to limit very materially the supply of blood to the part, and to destroy all semblance of the natural structure, except faint indications of its lobulation.

From a man, aged 35, who was in St. George's Hospital under the care of Dr. Fuller. He had suffered from a prolapsed rectum for four years, and for this an operation had been performed; and for the same period he had had a discharging abscess in the scrotum. These were the only apparent sources of discharge. Polyuria and thirst had troubled him for a year, and latterly he had noticed some abdominal enlargement.

He was extremely emaciated, with sunken eyes and prominent cheek-bones, congested venules about the face, and an amyloid aspect of the skin. The liver was much enlarged, smooth, hard, and extending to within an inch of the umbilicus. He was suffering from severe diarrhœa when admitted, and was in a state of collapse; his skin was dry and scaly. The urine was not in abnormal quantity, and contained some scrofulous pus which appeared to have come from the kidneys. An abscess in the scrotum was nearly healed. There was some considerable swelling of the abdomen and abdominal pains, associated with vomiting. He gradually sank.

The body was emaciated. Firm pleural adhesions existed on both sides of the thorax, and the upper lobes of the lungs were œdematous.

The mitral valve was rather thick.

The intestines were matted together by recent lymph, the peritoneum much congested, and upon it, through the whole course of the intestines, was a scattered deposit of tubercle.

The liver weighed 59½ ozs., and was in a state of extreme lardaceous degeneration, so much so that the structure of the right lobe was replaced by the morbid deposit, which presented to the naked eye a white transparent aspect. The white matter gradually became darker and more like liver substance towards the outside of the organ, the deposit being more in the course of the hepatic than the portal vein. The colour test with iodine, as also that in the kidneys and spleen, was most striking.

The kidneys were in an advanced state of lardaceous disease; they weighed 16½ ozs. The cones of the left kidney were almost destroyed by scrofulous deposit, tolerably firm outside, but softer and more resembling pus towards the centre of the mass.

The spleen weighed 24 ozs., and was extremely lardaceous.

A small abscess was found in the scrotum in process of healing; it appeared to have originated in the covering of the left testis, and then to have made its way through the scrotum. The structure of each testis was healthy.

From the notes of the case by Dr. Whipham, recorded in the case-books of St. George's Hospital Museum.

FIG. 2. *Lardaceous liver.*—From a portion of liver in an advanced stage of lardaceous disease. The brown part to the left represents the stain produced by the action of iodine upon the lardaceous material. The greater part of the surface, being unstained by iodine, presents a pale buff or fawn-colour with some slight appearance of translucency, dotted over by a number of small congested capillaries. The whole is veined by faint yellow lines where fat has been deposited in excess.

From a man, aged 45, admitted into St. George's Hospital under the care of Dr. Fuller, in 1867. He was a pensioner, and had served in Bengal 14 years. He had had fever, ague, and dysentery when abroad, about 17 years before death, and had contracted syphilis; but the date of this was uncertain. He had been an inmate of the Hospital on a previous occasion with symptoms of lardaceous degeneration of the liver and kidneys. He had then been ill a month, with pain in his right side, œdema of the legs, and swelling of the abdomen. The urine was clear, pale, and very albuminous. He was very thirsty, and had a very cachectic look. He left the hospital in three months' time much relieved, Dropsy soon returned in his legs, he began to vomit and to suffer from diarrhœa, and he was re-admitted. The urine then became scanty, he lost flesh rapidly, and the dropsy increased. He gradually got worse, was troubled with distressing diarrhœa, and during the last week of life had uncontrollable epistaxis.

The body was much jaundiced. An indurated cicatrix was present on the prepuce, and the glands in the groin and other parts were enlarged. Firm and strong adhesions united the pleural surfaces on each side, the left apex being especially affected. The lungs were congested and œdematous. At the left apex was an old cicatrix, and old quiescent tubercle was present in one of the bronchial glands.

The liver was adherent to the diaphragm by a number of adhesions of firm and strong character. Its capsule was much thickened and of an opaque milky-white appearance, with numerous pits upon its surface. Its section was pale buff or fawn-colour, dotted over with a number of minute points of congestion due to its infiltration with lardaceous material. Iodine gave a characteristic reaction. In places the section showed an absence of the points of congestion, and the colour was of a yellowish tinge, due, as the microscope showed, to the presence of fat in addition to the lardaceous material. In the centre of the right lobe was a deposit the size of a small orange, of a dusky yellow colour and firm consistence, not very distinctly circumscribed, somewhat resembling tubercle in appearance, but much harder and more tough. It was softened in its centre and broken down; gave very little reaction with iodine, and under the microscope was of a fibroid nature. The spleen, kidneys, and intestines were all lardaceous. The tibiæ and the hard and soft palates were examined, and found to be natural.

(Abstract of the notes of the case in the Records of St. George's Hospital, by Dr. Reginald Thompson and Mr. Pick.)

PLATE XVI.

Fig. 1. *Cancer of the liver.* — Section of a liver in an antero-posterior plane, including the gall-bladder—shown green in the figure at the anterior and inferior part. The surface of the organ is seen to be swollen in places by the protrusion of tumours from the substance of the gland, and the section shows these to be circular nodules of all sizes, with a tendency to lobulation, and of soft white fleshy aspect. The intervening structure presents a natural appearance. At the lower part of the section some of the tubera have assumed a yellowish tinge from the imbibition of bile.

From a woman, aged 28, under the care of Dr. Wilks, in Guy's Hospital, in January, 1880. She was a married woman, of healthy parentage, and had enjoyed good health till the time of the commencement of the illness for which she sought admission. Three months before she came she first noticed pain in the back and shoulders, and stomach, and her appetite failed. For a fortnight the abdomen had been increasing in size. She was in a very weakly condition when admitted, with pain in her abdomen, which was much distended with fluid. It was impossible on this account to examine the abdominal viscera, but a hard nodule could be felt an inch below the ensiform cartilage which moved upwards and downwards during respiration. The viscera were acting normally, except the kidney, which was excreting a urine of high specific gravity—1028, scanty in quantity, and full of lithates. She slept badly and emaciated rapidly, complaining much of abdominal pain. She sank gradually from exhaustion seventeen days after her admission.

The body was extremely emaciated. There was no anasarca. No scars, moles, or warts. Nothing upon the surface to give rise to any primary growth. All the bones of the skeleton were searched as far as possible, but nothing morbid found in any.

Lungs.—Both were small. The lymphatics of the pleura over the lower lobes were full of a white matter from the new growth, and on section the lobular septa were found invaded in *many* parts.

The glands in the mediastinum were all involved in the growth. Behind the sternum a chain of white fleshy glands ran upwards, implicating the cervical glands on both sides, and infiltrating the intercostal muscles in the second right space.

The *heart* weighed only 4¾ oz. It was healthy.

Peritoneum.—Much ascites. Many parts of the membrane thickened and irregular upon the surface from a new growth, which had for the most part ill-defined margins, though picked out here and there by a marginal injection of the veins. The omentum formed a dense mass, the new growth infiltrating it extensively. It surrounded the stomach and transverse colon, uniting these parts and the liver together.

The stomach was much thickened; in some parts all the coats were affected, and near the pylorus the peritoneal coat chiefly. At the cardiac end and on the hinder wall the mucous membrane was white and mottled over a large area. On a vertical section it was cancerous. All the glands in the portal fissure were enlarged and tough. The duct and vein were surrounded, and the bile duct was very small and very thick. It was patent. The portal vein was unaffected.

The intestine was healthy.

The liver was full of masses of cancer, which studded it in all directions. These appeared on the surface as numerous raised, smooth, white elevations, and upon section as circular nodules of all sizes. Many of these had formed in the right lobe, converting the greater part of it into one large mass of new growth. The tubera were all well defined in their outline and circular, the liver substance around being in sharp contrast by its dark colour. The consistence of all parts of the growth was soft. A close examination showed, besides the larger masses, a number of minute lines and spots which were evidently centres of early growth. The common duct was thickened and contracted by the disease of the glands in the portal fissure, but it was not obliterated, the gall-bladder and lining membrane of the common duct appearing to be quite healthy.

The supra-renal capsules were both affected. Each contained small nodules of soft growth, without any thickening of the surrounding parts.

The kidneys weighed 8½ oz. They were adherent to a mass of glands which ran upwards from the lumbar region to the portal fissure, and which extended into the hilus of one; but the glandular structure of both was healthy.

The pelvis and genitalia were unaffected.

The new growth, both in the peritoneum and liver, was found to be a characteristic specimen of a cancer, the stroma being alveolar and the cellular elements large and epithelial.

The case presents some obscurity as to the origin of the disease, as there was no one part which presented features which told in favour of the primary disease having originated in it. The mode of distribution of the disease in the liver was no doubt suggestive of material having been carried there by the veins, but the extensive implication of the lymphatic glands makes this to some extent doubtful. It is on the whole most probable that the disease commenced either in the stomach or peritoneum, and spread rapidly.

FIG. 2. *Nutmeg liver.*—A section of liver with a characteristic "nutmeg" mottling. There are light parts and dark parts, the former being an opaque-looking reddish yellow, the latter dark purple. The yellow parts occur in tracts of varying size, which are surrounded by the dark parts, but there is a fine veining of the purple with lighter lines. The surface shows accurately the hepatic lobulation, and the distinctions of colour which are so striking are due to the presence of fat in the hepatic cells of the lobules in the paler tracts, and to extreme congestion of the radicles of the hepatic vein and atrophy of the hepatic cells in the darker.

In any particular specimen of the "nutmeg" liver there may or may not be other alterations of the normal tissue, which will be given in detail in the next fasciculus, where the morbid histology of particular changes will be discussed; but for the present it is enough to bear in mind that the essential factors in producing the appearances depicted are (1) an irregular distribution and excess of the fat in the hepatic cells in some lobules (fatty infiltration), and (2) dilatation of the radicles of the hepatic vein and capillaries, with atrophy of the adjacent hepatic cells more or less universally.

From a man, aged 19. His family history was good, and no rheumatism could be traced to himself or his parents. He had had no illness that he knew of, except measles and gonorrhœa. In August, 1877, while taking part in a field-day at Aldershot, he suddenly felt faint, and was obliged to fall out. He quite recovered from this attack, and next day resumed his work; and from that time till September, 1879, he remained

well. He then began to experience shortness of breath and difficulty in getting up stairs. He was admitted into a hospital at Chatham for this, and finally into Guy's Hospital, under the care of Dr. Habershon. His body was at that time very dropsical, his dyspnoa was great, and he was very ill.

The præcordial dulness was increased, the apex beating in the nipple line in the fifth space, and accompanied by a presystolic thrill. The heart's action was rapid, though regular, and both presystolic and systolic bruits were audible at the apex; and a diastolic aortic bruit along the sternum.

The urine was only 12 ozs. in amount in the 24 hours, sp. gr. 1030, but not albuminous or saccharine.

It became necessary to tap the peritoneum, and by this he was for a time much relieved; but fluid gradually accumulated again, his heart became irregular, his urine albuminous, and he finally succumbed with pericarditis and a gangrenous state of the cellular tissue of his legs, after puncture with Southey's capillary tubes.

The inspection was made twenty-six hours after death.

The body was very bloated from anasarca. The left thigh was much swollen from extensive suppuration of its subcutaneous tissues, the result of the measures taken to relieve the dropsy.

Pleuræ.—Old adhesions were found on both sides, with a little fluid at the left base. Both lungs were indurated, semi-solid, and of a dark spleen-like colour. They contained several patches of pulmonary apoplexy, of recent origin. The bronchial mucous membrane was congested.

Heart.—The pericardium contained 10 ozs. of fluid serum; weight of heart 19½ ozs. Both sides very large and dilated; each auricle contained a quantity of post-mortem clot, and the ventricles also. In the left ventricle, which was much dilated, there was a little decolorized ante-mortem coagulum at the apex. The tricuspid valve was thick and opaque, not narrowed. The mitral valve was much thickened and narrowed, so much so that it only admitted the index-finger easily. The auricular face of its edge was fringed with recent lymph. The auricular wall was hypertrophied. The aortic valves were considerably contracted, so as to form but small flaps; their attachments were dragged down, and their edges fringed with beaded vegetations; and on the endocardium of the septum was a rough white thickening indicative of the pre-existence of regurgitation through the aortic valves.

Liver.—An extreme specimen of the "nutmeg" change. Its surface was dark-coloured, mottled, and granular, from the wasting which parts had undergone. The section showed a more than usually striking likeness to the nutmeg. The dark or congested parts were unusually arborescent and contrasted with the yellow fatty parts; this the more so, that the former were depressed below the surface and the lighter parts prominent. In this way the surface of a section was seen to be irregular and uneven, and so far, somewhat like cirrhosis, many parts of the organ being in a state of atrophy, resulting from the previous congestion.

The spleen was very firm, dark in colour, such as is found in cases of mitral disease. Weight 7½ ozs.

Kidneys.—Weight 13 ozs. A few old depressed scars which may well have been embolisms of former date. The kidneys were indurated and their cortex considerably charged with fatty elements; and it was evident that they had undergone some extent of chronic inflammation.

AN

ATLAS OF ILLUSTRATIONS

OF

PATHOLOGY

COMPILED (CHIEFLY FROM ORIGINAL SOURCES)

FOR

THE NEW SYDENHAM SOCIETY.

FASCICULUS IV.

DISEASES OF THE LIVER,

INCLUDING ONE FIGURE OF SPLEEN.

(PLATES XVII. TO XXII.)

WITH

PATHOLOGICAL SUMMARY BY DR. GOODHART.

LONDON:
THE NEW SYDENHAM SOCIETY.
1882.

AGENT—H. K. LEWIS, 136, GOWER STREET, W.C.

PLATE XVII.

DISEASES OF THE LIVER AND SPLEEN.

(Four Portraits.)

Fig. 1. Cirrhosis of the Liver resembling the Nutmeg Liver.—From a man, aged 53, under Dr. Habershon's care in Guy's Hospital. He had been addicted to spirit and beer-drinking, and suffered from ascites, enlargement of the spleen, and imperfection of the valves of the heart. The liver weighed sixty-two ounces; its capsule was thick and its surface granular, from a general and diffused form of cirrhosis. But its section resembled the "nutmeg" liver, being mottled by a combination of dark and light-coloured parts. The lighter parts were chiefly due to an excess of fibrous tissue; the dark, as in the nutmeg liver, to congestion of the venous capillaries. The omentum was matted into a mass resembling the pancreas, and the peritoneal surface was sanded over with tubercles which were particularly luxuriant over the abdominal aspect of the diaphragm. No trace of tubercle existed elsewhere. From a drawing by W. Hurst.

Fig. 2. Brown Atrophy of the Liver.—Dr. Moxon thus describes this condition:—"The liver is small; its edge perhaps wasted and white-looking. It is flabby, but not so pulpy as in yellow atrophy. There is no appearance of increase of fibrous tissue, the capsule being thin, the substance dark brownish red. On close observation, grey tubercle-like points may be seen, microscopically composed of remains of liver tissue, in which all the veins are occluded." (Plate XXII., fig. 8.) From a drawing by Dr. Moxon.

Fig. 3. Cirrhosis of the Liver.—The figure represents a section of the granular liver in which the fibrous tissue is in large excess. This gives the greenish grey appearance to the whole, the yellow spots being the bile-stained and fatty hepatic cells. The green colour is too pronounced in this figure. From a drawing from nature by Dr. Moxon.

Fig. 4. Lymphadenoma of the Spleen (Hodgkin's Disease).—A woman, aged 24, with phthisical family history, suffered for some time with disease of the ankle, for which the foot was amputated. Recovering from this, the glands in her neck began to enlarge, phthisis developed itself in both lungs, the glands elsewhere became affected, the liver and spleen enlarged, and the urine became albuminous. The cervical, mediastinal, mesenteric, and lumbar glands were all alike, forming large firm yellow masses, with fibrous septa and capsules. The spleen weighed sixteen ounces, was of a dark purple colour, and studded with circular nodules of tough yellow cheesy material having a laminated arrangement. Some of them were undergoing calcareous changes. The intervening splenic pulp was very dark, in colour and consistence like the spleen of chronic mitral disease, and no splenic corpuscles were visible. The uterus and fallopian tubes were extreme instances of cheesy or scrofulous disease of the mucous membrane. The other viscera were lardaceous. Guy's Hospital; from a drawing by W. Hurst.

Fig. I.

LIBRARY
OF THE
BOMBAY
BRANCH
OF THE
ROYAL
ASIATIC
SOCIETY

Fig. II.

Fig. III

Fig. IV

PLATE XVIII.

DISEASES OF THE LIVER.

(Four Portraits.)

Fig. 1. Fatty Liver from Poisoning by Phosphorus.—A woman, aged 28, was admitted into Guy's Hospital, under Dr. Habershon. She had taken some phosphorus by mistake four days before death. Her symptoms were, severe diffused abdominal pain, full hepatic dulness, and low temperature. The liver weighed seventy-nine ounces, was of natural shape, firm and tallowy to the feel, pale opaque light buff-colour, with numerous small ecchymosed spots or streaks. It sank slowly in water, and burnt like the wick of a lamp. The microscope showed little else than fatty lobules. Dr. Moxon states from microscopical examination that the stroma of the liver was not increased in amount. The kidneys weighed fourteen ounces, and were fatty. Guy's Hospital; from a drawing by W. Hurst.

Fig. 2. Cirrhosis of the Liver, showing the extremely lobulated surface and the appearance of the liver as seen on section.—A man, aged 48, suffered from extreme ascites, due to cirrhosis, for which it was necessary to tap him repeatedly, and he died with symptoms of peritonitis. The peritoneum was intensely inflamed. The liver weighed sixty-five ounces, and was a good example of the hobnailed liver. The section showed in some parts an amount of fibrous change which was extreme, even to the formation of a secondary cavernous structure. In other parts there were lobules of swollen, fatty, bile-stained tissue. From a drawing by W. Hurst.

Fig. 3. Tubercular Liver.—From a child, aged 4, admitted into Guy's Hospital, under Dr. Habershon, for convulsions, which terminated fatally within a short time of its admission. It suffered from tubercular meningitis, tubercle of the choroid, extensive tuberculosis of the lungs, associated with solid caseous masses; tuberculosis of the glands, peritoneum, intestine, liver, spleen, supra-renal capsules, and kidney. The liver weighed twenty-two ounces; it was thickly studded with large tubercles, many of which had softened in the centre and were stained yellow with bile. The whole liver was of a peculiar mottled appearance—in part due to this growth of tubercle, in part to an irregular congestion. From a drawing by W. Hurst.

Fig. 4. Cirrhosis of the Liver.—From a man, aged 61, under the care of Dr. Moxon for cirrhosis and slight jaundice. He had been addicted to spirit-drinking. The urine contained a little albumen. The liver weighed forty-three ounces. The capsule was thick, and its surface granular; on section the surface presented a number of bright orange-yellow circular islands of various sizes, enclosed in grey or pinkish seams of fibroid tissue. It presented a good example of common cirrhosis. The gall-bladder was small; the ducts and intestine contained bile. A large vein some five or six millimetres in diameter ran from the portal vein, in the transverse fissure of the liver, along the round ligament to the abdominal wall, and there distributed itself; it had no communication with the inferior cava. An old apoplectic cyst existed in the left optic thalamus, the lungs were œdematous, and the kidneys in a state of subacute parenchymatous inflammation. From a drawing by W. Hurst.

THE BOMBAY BRANCH OF THE ROYAL ASIATIC SOCIETY

PLATE XIX

Cystic Disease of the Liver.—From a man, aged 53, under the care of Dr. Pye Smith in Guy's Hospital. He had been a hard drinker, and died of chronic pneumonia. The liver was of natural size, but puckered and deformed from the presence of depressions on the surface, due to cysts in the subjacent parenchyma. The cysts were very numerous, and varied from microscopic dimensions to cavities of considerable size; they contained thin, clear, slightly albuminous liquid free from bile, and no connection with the ducts could be discovered. The kidneys were sixty-four ounces in weight, and were converted into similar cysts. (See also Plate XXII., figs. 4 and 5.) The case is recorded in the 'Transactions of the Pathological Society of London,' vol. xxxii., p. 112. From a drawing by W. Hurst.

PLATE XX.

FIG. 1. LARDACEOUS DISEASE OF THE LIVER.—In the centre is a section of a portal channel crowded with nuclei; outside it irregular dark blotches are seen, representing sometimes lardaceous material, sometimes the atrophied and fatty parenchyma; still more towards the margin of the figure the section becomes more homogeneous, being almost entirely converted into lardaceous matter, which is intersected by delicate lines of fibrocellular tissue and strings of round nuclei. (1×40).

FIG. 2. FATTY LIVER.—The large circular bodies are fat globules distending the hepatic cells; to the right of the figure and between the altered cells the large hepatic cell nuclei are visible. (250 diam.)

FIG. 3. EARLY CIRRHOSIS.—Part of a portal channel and the adjacent part of a lobule.

aa. Line of the original boundary of the lobule, upon the head side of which is a thick band of highly-nucleated fibrous tissue, of new formation. At *b* another lobule just enters the field; *c* is a duct-like arrangement of cells. On the hilt side of the line the adjacent liver cells are small; many appear only as free nuclei. The margin of the lobule is evidently undergoing some cirrhotic change. The appearances bear the interpretation that the hepatic cells are proliferating and forming fibrous tissue. Many of the liver cells are charged with fat, *dd* being some of these. (250 diam.)

FIGS. 4 & 5. CIRRHOSIS OF THE LIVER (after Hamilton).—To show the various stages of the process of the formation of fibrous tissue. In fig. 4 the proliferation of the hepatic cells is seen in the centre, where many of the cells have a double nucleus, and outside are clusters of similar cells, forming duct-like arrangements in the fibrous tissue. Fig. 5 shows the proliferation of the hepatic cells, and their more direct transformation into spindle-cells and fibres.

FIG. 6. CIRRHOSIS OF THE LIVER.—Interlobular new growth of tissue, with well-formed biliary canaliculi and nucleated tissue outside them. From a child, aged 5. (230 diam.) From a drawing by Dr. Frederick Taylor. See also 'Path Soc. Trans.,' 1880, vol. xxxi., p. 119.

FIG. 7. A VEGETATION FROM THE SURFACE OF THE LIVER.

a. Superficial layer of hepatic cells beneath the capsule.

a—b. Subendothelial or peritoneal connective tissue thickened and containing many round nuclei, capillaries (*b'*), and a small artery (*g*).

cc. Original line of peritoneum, with a layer of cube-like cells with nuclei.

dd. Striated line of condensed fibroid tissue limiting the vegetation.

e. Loose fibrocellular tissue composing the vegetation.

f. A small arterial twig. (250 diam.)

FIG. 8. SPINDLE-CELL SARCOMA OF THE LIVER (220 diam.)—The case is recorded by the late Dr. Murchison in the 'Path. Soc. Trans.,' vol. xxiv., p. 123. From a drawing by Mr. Henry Arnott.

FIG. 9. DISSEMINATED GROWTHS OF FIBROUS NATURE IN THE LIVER.—The figure represents a portion of liver showing a nuclear growth extending along the intercellular network; the liver cells mostly removed by pencilling.

a. Nucleated growth.

bbb. Spaces from which liver cells have been removed.

cc. Liver cells *in situ;* almost unaffected by the new formation.

d. Amorphous granular mass; probably resulting from the transformation of liver cells. (430 diam.)

From a drawing by Dr. Cavafy of a case recorded by Dr. Payne in the 'Path. Soc. Trans.,' Lond., vol. xxi., p. 236. The nature of the case is doubtful. It is headed, "Minute fibrous granulations of peritoneum; disseminated growths throughout the liver; fibrous thickening of walls of portal vein and bile ducts." Dr. Payne remarks upon it—"The structure had an unmistakable resemblance to (1) a peculiar affection of the liver associated with growths in the kidneys, &c., described by Drs. Sanderson and Murchison, vol. xx.; and (2) to the form of growth in the periphery of syphilitic tumours of the liver." (Allusion to this case has been accidentally omitted in the text; it should illustrate the last paragraph on first column of p. 32).

FIG. 10. LARDACEOUS DISEASE OF THE LIVER.—The shaded parts are lardaceous, and are intended to show two characteristics of lardaceous material—(1) its irregularity of distribution, and (2) its want of definiteness of outline. The intervening parts represent the atrophied stroma, with fatty liver cells and free nuclei. (250 diam.)

FIG. 11. CAVERNOUS TUMOUR IN THE LIVER.—The section is taken from the border of the liver (a portion of fig. 13 more highly magnified), from which it appears that the liver cells lose their outline, their nuclei increase, and gradually pass into the fibromuscular trabeculæ of the cavernous tissue. The walls of the blood-spaces possess nuclei, which in some parts appear to be undergoing some process of growth also. From a drawing by Miss Alice Boole. (250 diam.)

FIG. 12. ACUTE YELLOW ATROPHY OF THE LIVER.—A portion of liver in which the outlines of the individual cells are all lost, and very little trace of the hepatic structure is left. A number of free nuclei are scattered about, some of which appear to be derived from the cells, others from vessels. The whole section is cloudy and indistinct in the extreme. (250 diam.)

FIG. 13. CAVERNOUS TUMOUR IN THE LIVER.

a. Healthy liver.

b. Fibrous zone adjacent and running into it, in which are large vessels and dilated spaces containing blood.

cc. Line of commencement of cavernous tissue proper.

ddd. A number of irregular spaces are shown bounded by thick fibrous trabeculæ. These spaces are full of blood, and constitute the bulk of the tumour. From a drawing by Miss Alice Boole.

FIG. 14. EARLY CIRRHOSIS.

a. Transverse section of a small interlobular passage, with its vessels and the adjacent lobules.

aa. Hepatic cells.

bbb. Transverse sections of vessels and ducts, all of them surrounded by an abnormal number of nuclei; the hepatic cells are normal.

Fig. 15. COLUMNAR EPITHELIOMA OF THE LIVER ('Path. Soc. Trans,' vol. xxv., Pl. vi., fig. 1).—From a drawing by Dr. Greenfield.

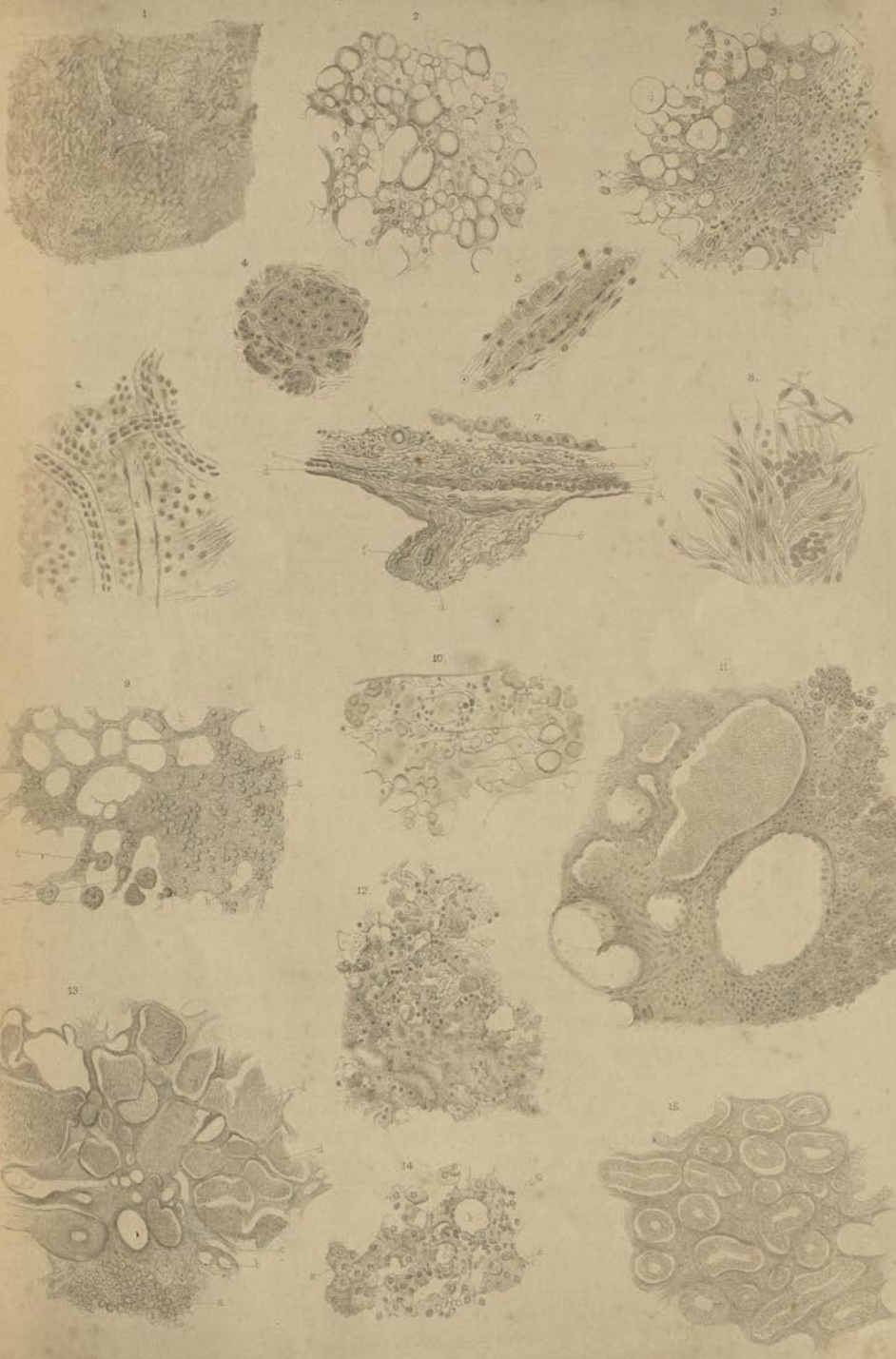

PLATE XXI.

FIG. 1. CIRRHOSIS OF THE LIVER (after Dreschfeld and Young).

a. Bands of fibrous tissue with spindle cells, running from the portal fissure between the liver cells.

bb. Similar bands surrounding small groups of hepatic cells.

cc. Collections of nuclei resembling fine biliary ducts.

FIG. 2. CIRRHOSIS OF THE LIVER, showing a cross-section of ducts and vessels in a portal channel, with the surrounding changes. These appear to be in the connective tissue only.

aaa. Connective tissue containing scattered and aggregated nuclei.

b. Section of portal vein.

cc. Hepatic artery.

dd. Biliary duct.

FIG. 3. MONOLOBULAR CIRRHOSIS (after Dreschfeld and Young).

aa. Fat.

bb. Liver cells.

cc. Liver cells surrounded by fibrous material.

dd. Liver cells proliferating and on their way to form

ece. Biliary ducts.

FIG. 4. THE NUTMEG LIVER (Ramose Atrophy of Moxon).

a. Section of intralobular vein dilated and full of blood.

bbb. Dilated capillaries with atrophied liver cells between them, and thickened hyaline fibroid connective.

cc. Masses representing orange-coloured pigment.

dd. Hepatic cells.

From a drawing by Miss Alice Boole. (215 diam.)

FIG. 5. TUBERCULAR LIVER.

aaa. Margins of the tubercle.

bb. Sections of branches of portal vein.

cc. Healthy liver cells.

dd. Cells arranged after the fashion of biliary capillaries.

From a drawing by Miss Alice Boole. (215 diam.)

FIG. 6. THE NUTMEG LIVER, showing appearances in the portal canals similar to those of the so-called Biliary Cirrhosis.

aaa. Sections of biliary canals.

bbb. Intervening thickly-nucleated tissue.

From a drawing by Miss Alice Boole. (215 diam.)

FIG. 7. MILIARY GUMMATA (see also fig. 12).

aaaa. Early gummata indicated by thick clusters of nuclei.

b. A similar collection of nuclei, but with a margin less well-defined, the nuclei being more diffused through the tissue.

FIG. 8. IDIOPATHIC ANÆMIA.—Atrophy in the distribution of the hepatic artery and intralobular vein. (See also fig. 15).

a. Central part, from which the hepatic cells have all disappeared. A network of hyaline fibres alone remains, the intervening spaces containing blood-corpuscles in many instances.

b. Atrophied cells visible.

c. Outer zone, in which the hepatic cells are fairly healthy. There is much pigment in all parts.

From a drawing by Miss Alice Boole. (40 diam.)

FIGS. 9 & 10. CANCER OF THE BILE DUCTS. (High and low powers.)

a. Lumen of duct.

b. Epithelial coat in a state of proliferation.

c. "Indifferent" nuclear growth surrounding the duct, and not unlike that found in cirrhosis.

From drawings by Miss Alice Boole. (215 and 40 diam.)

FIG. 11. CANCER SPREADING FROM THE BILIARY DUCTS.

aa. Sections of branches of portal vein.

bb. Epithelial growth enclosed in alveoli of fibrous tissue.

c. Hepatic cells smaller than natural, but still recognisable.

From a drawing by Miss Alice Boole. (215 diam.)

FIG. 12. EARLY GUMMATOUS INFILTRATION OF THE LIVER.

a. Small collection of nuclei, apparently a gumma in its very earliest stage.

b. Larger collection of nuclei around some capillary vessels.

From a drawing by Miss Alice Boole.

FIG. 13. "COMMON" CIRRHOSIS ("Multilobular" Cirrhosis).

aa. Section of a portal canal much thickened by fibrous growth. At *b* the fibrous tissue has invaded the parenchyma, and some fatty liver cells are represented in globular outline; *ccc* are "granulations" composed of the hepatic cells encircled by fibrous bands. The liver cells are all fatty, and the fibrous tissue of the new growth has undergone considerable cavernous metamorphosis.

From a drawing by Miss Alice Boole. (40 diam.)

FIG. 14. TUBERCULAR LIVER.

aaa. Tubercles plainly situated in the portal canals, but to the left of the figure invading the lobular structure.

bb. Liver cells comparatively healthy, but the parenchyma is not free from an excess of small round nuclei in many parts.

From a drawing by Miss Alice Boole.

FIG. 15. IDIOPATHIC ANÆMIA (a part of fig. 8 more highly magnified).

aaa. The cavernous structure produced by atrophy of the parenchyma in the arterial territory of the lobule, in which are many roundish pigment masses (of orange-colour in the preparation).

bb. Hepatic cells somewhat massed together, and many containing an excess of pigment.

From a drawing by Miss Alice Boole. (215 diam.)

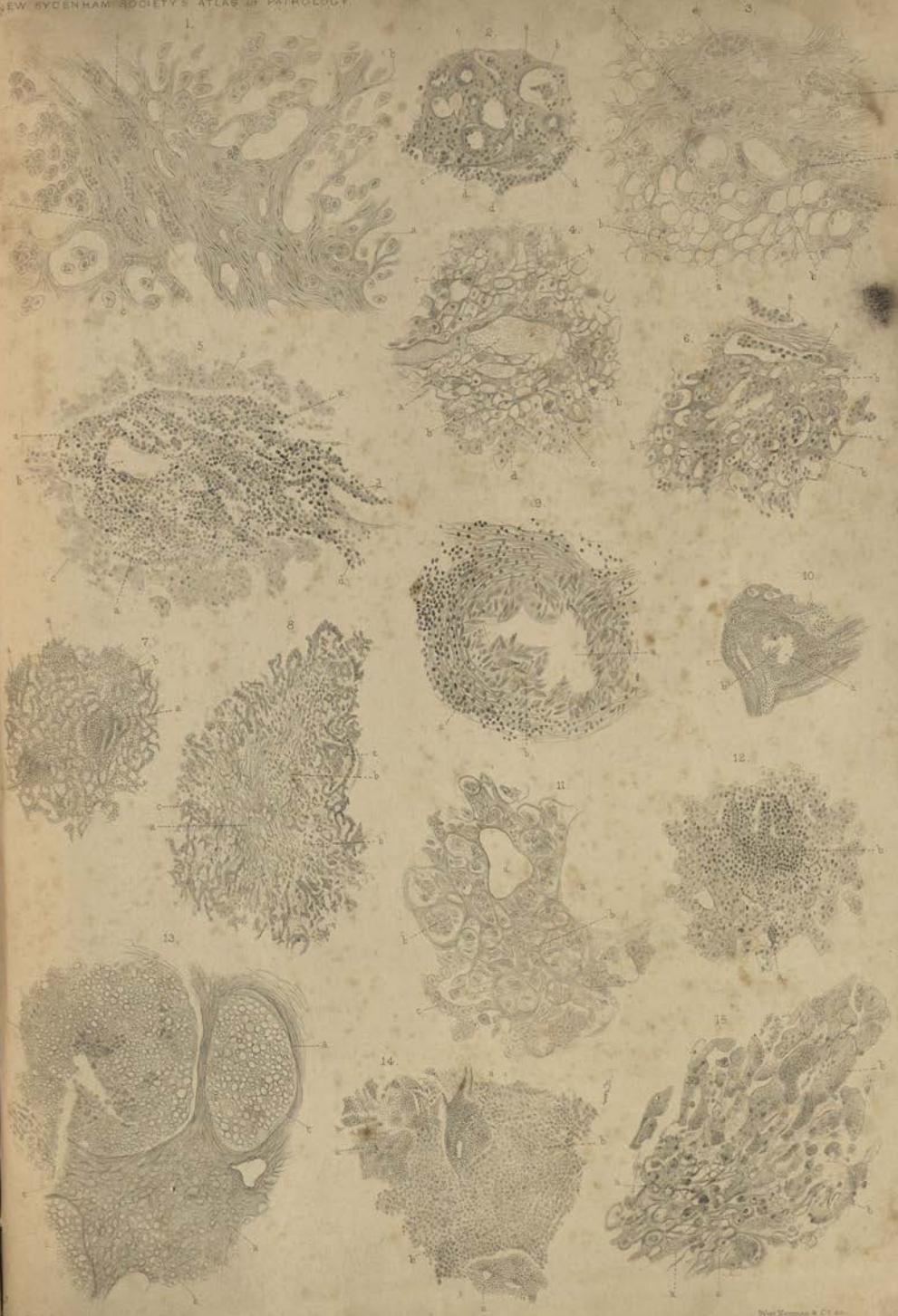
1.
2.
3.
4.
5.
6.
7.
8.
9.
10.
11.
12.
13.
14.
15.

PLATE XXII.

FIG. 1. "PERICELLULAR" CIRRHOSIS.

aaa. Masses of hepatic cells fused together.

bb. A closely-webbed fibroid stroma thickly studded with round nuclei (*cc*) which invaded the parenchyma in all directions.

From a drawing by Miss Alice Boole. (215 diam.)

FIG. 2. CIRRHOSIS OF THE LIVER.

aa. Sections of branches of the portal vein.

b. Thick fibrous tissue in the portal canals.

c. Nuclear growth.

ddd. Sections of biliary canals. The hepatic cells surrounding all are apparently healthy.

From a drawing by Miss Alice Boole. (40 diam.)

FIG. 3. NUTMEG LIVER, showing cirrhotic changes.

a. Section of a biliary canal.

bbb. Hepatic cells small, and compressed by

cc. Surrounding thick fibroid material.

dd. Nucleated tissue.

From a drawing by Miss Alice Boole. (215 diam.)

FIG. 4. CYSTIC LIVER, to show the changes in the portal canals.

a. Wall of large branch of portal vein.

b. Oblique section of a bile duct.

c. Transverse section of a small artery.

dd. Elongated rod-shaped muscle nuclei. To the right of the section are some hepatic cells which show the variation in the size of their nuclei, indicative of proliferation. (215 diam.)

FIG. 5. CYSTIC LIVER.—In appearance very like a fatty liver; but many of the circular spaces are probably small cysts, and some of the hepatic cells are in process of vacuolation. Many of the hepatic cells are compressed by the cysts. (215 diam.)

FIG. 6. EARLY CANCER OF THE LIVER.—The hepatic cells undergoing conversion into the cells of the growth.

aa. Healthy hepatic cells.

bb. Liver cells with enlarged nucleus (first stage of disease).

cc. Liver cells with many nuclei (second stage of disease).

dd. Free nuclei of the new growth. (250 diam.)

FIG. 7. EXTREME TUBERCULAR DISEASE OF LIVER.—At *aa* sections of the portal canals are seen with a growth of tubercle of some thickness around them. The disease has diffused itself in lines more or less throughout the liver (*bbb*).

From a drawing by Miss Alice Boole. (56 diam.)

FIG. 8. BROWN ATROPHY OF THE LIVER (a small part of fig. 2, Pl. XVII.)

A. One of the grey granules.

B. From its immediate neighbourhood.

a. Fibroid tissue, the residue of secreting tissue; in it were brown pigment-grains.

b. Free nuclei.

c. Very small secretory cells.
d. Larger cells, very few in number. The pigment all brown.
e. Network of persistent capillaries.
From a drawing by Dr. Moxon.

FIG. 9. EXTREME TUBERCULAR DISEASE OF THE LIVER.—From the same case as fig. 7, showing the abnormally numerous nuclei distributed through the liver. The drawing does not bring out their number sufficiently. The disease affected the connective tissue all through the liver, and many of the cells were in process of vacuolation. (215 diam.)

Fig. 10. MYXŒDEMATOUS LIVER, with large intercellular accumulations of faintly fibrillated or granular substances, and numerous large nuclei.
aa. Healthy liver cells.
bb. Pigment-grains in the cells and round the nuclei.
cc. Intervening hyaline material.
dd. Swollen nuclei.
From a drawing by Dr. Alfred Sangster, from a case under the care of Dr. Ord, recorded in the 'Transactions of the Clinical Society,' vol. xiii.

FIGS. 11, 12, & 13. "CONTRACTING SCIRRHUS OF THE LIVER SIMULATING CIRRHOSIS."
Fig. 11. Isolated cells from nodules of cancer, large and not at all unlike the gland cells.
Fig. 12. Part of the infiltrating growth. *aa*. Liver cells fused together and encircled by a richly-nucleated fibroid material like that of cirrhosis.
Fig. 13. Shows the cells from a nodule of the growth in position. The liver cells appeared to be multiplying and forming the new growth, and it was sometimes most difficult to distinguish between disarranged liver tissue and the actal growth. From the 'Trans. Path. Soc.,' vol. xxviii., p. 138.

FIGS. 14, 15, & 16. VARIETIES OF CELL VACUOLATION AND PROLIFERATION, illustrating the stages of Cancer in the Liver (after Creighton).

FIG. 17. PRIMARY ADENOMA OF THE LIVER (small part of fig. 19).
aa. The gland tubes (?)
bb. Intervening fibroid tissue.
From a drawing by Miss Alice Boole. (215 diam.)

FIG. 18. LEUKÆMIC LIVER.
a. The new growth.
b. Liver cells.
c. Nucleated growth spreading between the hepatic cells. In other parts the new growth had produced a more closely felted fibroid tissue, and great wasting of the hepatic cells. (215 diam.)

FIG. 19. PRIMARY ADENOMA OF TH LIVER.
aa. Capsule of liver.
bb'cc'. Fibrous capsule of the growth, within which are seen numerous spaces in a fibrous network containing welded masses of cells.
From a drawing by Miss Alice Boole. (40 diam.)

A RÉSUMÉ

OF OUR PRESENT KNOWLEDGE OF THE PATHOLOGY OF

DISEASES OF THE LIVER.

By JAMES F. GOODHART, M.D.

The liver, the organ selected for illustration in the last and the present fasciculus, invites attention at all points. Whether we consider it anatomically, physiologically, or pathologically, it attracts us by the magnitude and importance of the questions which press upon us for solution. Not only so: these questions are of so much intricacy that, notwithstanding all that has been written, there is still a divided opinion upon much in all three branches of investigation. Perhaps there is no organ of which it may be said that the groundworks necessary for the erection of a stable system of pathology are more unsettled than are those of the liver at the present time. Take the normal histology of the liver, and, though we name all the prominent histologists of late years, are we more certain of any one point than we were after Kiernan published his investigations? It may reasonably be doubted. And whereas a perfect system of pathology should, no doubt, be continued upon the lines of the normal structure and functions, and although some important advances in this direction have been made of late years, as will presently be shown, we cannot so systematise hepatic pathology at present. The pathologist must content himself with pursuing an almost independent investigation; nay he may even hope in morbid changes to throw some light upon vexed questions of anatomy and physiology.

It is true that at first sight the liver would seem to hold a favouring hand to systematic nosology, for certain prominent symptoms and alterations of structure characterise its diseases. Jaundice might serve, it might be suggested, for an axis to the nosological tree from the physiological and functional side; cirrhosis upon the ground of morbid histology. But visions of this kind are soon dispelled if we attempt to put them into actual practice. Take up any book devoted to jaundice, and the pathologist is worried from its beginning to its end by finding how unsatisfactory it is in the want of finality and completeness of its arrangement. And it is a fact that, prominent as are some of the features of hepatic disease, there is no one which occupies any position parallel to that of albuminuria for renal diseases. This being so, as well as upon the ground of uniformity, we cannot do better than follow out the plan adopted for the *résumés* of Diseases of the Kidney, Spleen, and Supra-Renal Capsules; and we shall therefore describe, first of all, some of the elementary changes which the main constituents of the liver (the hepatic cells) undergo, and then as far as possible show the arrangement of these various elementary lesions in the numerous diseases of the liver.

As heretofore, our first concern must be with a short sketch of the anatomy and histology of the healthy liver.

Of its rough appearance it will be enough to say that it measures 10 to 12 inches transversely from right to left, 6 or 7 inches from posterior to anterior border, and about 3½ inches through its substance at the thickest (Quain & Sharpey). Its ordinary weight is from 50 to 60 ozs. in the adult, though somewhat less in females than males, and—a not unimportant point pathologically, though one to which but little attention has as yet been directed—it is about equal to 1-36th of the weight of the whole body, a proportion which is altered in children in favour of the liver, which becomes disproportionately heavy. The specific gravity of the liver, according to Krause and others, is 1·05 to 1·06, which is reduced in states of fatty degeneration. It will be unnecessary to call attention to the various lobes of the liver, except in so far as to call to mind that upon the under surface, the vena cava inferior, the portal vein and bile duct are to a certain extent imbedded between the

lobes; and that in cases of enlargement of the latter some pressure may be exercised upon the various channels, and obstruction of the circulation brought about. The vena cava, for instance, may be compressed between the right lobe and the lobulus Spigelii; the portal vein in like manner by any excess or enlargement of the quadrate and Spigelian lobes. Of its position, it may be well to remember that it occupies the right hypochondrium chiefly, being accurately moulded to the vault of the diaphragm; and that it is only separated from the right lung by the diaphragm and the serous coverings of that muscle. Thus there is a liability for diseases to extend from one serous cavity to the other, and between lung and liver; and such extensions are of sufficiently frequent occurrence to be of considerable practical importance. It is covered by or situated behind the six lower ribs on the right side, and consequently if they are compressed, or the level of the diaphragm lowered from any cause, the liver may become altered in shape or change its position of inaccessibility to palpation under the ribs to one of easy access in the upper, or indeed any, part of the abdomen.

The gall bladder situated in its own fissure in the right lobe touches the abdominal parietes immediately behind the tip of the tenth costal cartilage.

Of the blood vessels of the liver it would be unnecessary to make mention, were it not to call attention to the various means of communication which exist between the portal and systemic systems of veins. It is well known that in no inconsiderable number of cases of cirrhosis, probably in more than one-third of all, ascites is absent, and it must needs be therefore that this accessory or collateral circulation is in a considerable number of cases sufficient to replace the normal routes.

The portal vein then, be it remembered, is the combined trunk of the gastric or coronary, the mesenteric, and the splenic veins. The splenic vein would appear to have no outlet, except by means of the portal trunk; but with the coronary and mesenteric it is otherwise. As regards the mesenteric veins, it is generally well known that the inferior mesenteric of the portal system communicates by its superior hæmorrhoidal branches with the inferior hæmorrhoidal of the internal iliac of the systemic system. Thus in obstructive liver disease piles are frequent. But there are other important means of communication between the two systems: the colic and duodenal veins communicate with the left renal vein; some superficial branches of the portal vein inosculate with the phrenic veins, as originally pointed out by Kiernan; and in cases of cirrhosis I have repeatedly found that injection forced into the portal vein flows freely away by means of adhesions to the diaphragm; and at least one case is on record where these veins appeared to be the sole means of communication between the two systems (Rindfleisch, Pathological Anat., New Syd. Soc., vol. ii., p. 111).

The gastric veins in supplying branches to the cardia communicate with the œsophageal veins. The importance of this channel is shown by the fact that cases are on record in which the œsophageal veins have become varicose, and fatal rupture of the veins with hæmatemesis has occurred.

Another very important collateral channel is supplied by means of a small vein running from the portal vein to the umbilicus in the round ligament of the liver, the vena par-umbilicalis. Probably the existence of this vein may be only occasional; but in some cases of cirrhosis it becomes greatly enlarged, and in two cases I have seen it not far short of the normal portal vein. One of these specimens is preserved in the Hunterian Museum. This is the channel which Sappey has described as the umbilical group of his system of accessory portal veins. Starting in small rootlets which are said to have their origin in the epigastric and external iliac veins, it reaches the umbilicus, and passes with the round ligament to the transverse fissure of the liver and opens into the portal vein. By this means, when the portal circulation is obstructed in the liver, the portal blood finds its way to the abdominal wall, and thus into the subcutaneous tributaries of the epigastric and internal mammary. From what I have myself seen, I agree with Schiff that this vein may also carry a considerable quantity of blood to the hepatic branches of the portal vein when the main trunk is obliterated.

By these various means, but chiefly by the existence of the umbilical vein and the anastomoses between dilated mesenteric radicals and the spermatic veins, complete obstruction of the portal vein is occasionally entirely compensated and an important clinical fact receives a satisfactory solution. Dr. Fagge makes the statement that, at Guy's Hospital, one case of cirrhosis

has been found accidentally upon the post-mortem table, *i. e.* gave no symptoms, for every *two* that died from it.

These remarks are all that it seems necessary to make upon the coarse anatomy of the liver, and we turn now to the normal histology. This must be given very shortly, and with the more reason that the members of the New Sydenham Society are already in possession of an exhaustive article on the subject by Hering in Stricker's Handbook.

The simplest conception of the liver is, I think, that which, taking one of its component lobules, compares it to a raspberry upon its stalk. The stalk corresponds to the intralobular hepatic vein; the fruit to the hepatic cells, and round the exterior is a network or bag of small branches of the portal capillaries running with other vessels in Glissons capsule.

The lobules of the liver in man are irregularly polyhedric and usually elongated bodies about a millimetre in diameter, and from one to two millimetres in length. Each is usually described as having a base, lateral surfaces, and an apex; but it does not appear that much is gained by this conception. It is sufficient for all purposes to remember that they are nearly uniform in size, somewhat variable in their external contour owing to the mutual compression of other lobules; their centres, if cut at right angles to the intralobular vein, show a central vein; and round the polygonal circumference of each some branches of the portal vein. The intralobular vein is separated from the interlobular by an interval of about 0·5 of a millimetre. This therefore corresponds to the half of the diameter of the lobule; and the length of the capillaries which run from the centre to the circumference, that is, which connect the portal and hepatic veins, is necessarily the same.

The capillary network of the lobule between the hepatic and portal veins is a very close one; the intralobular vein gives off branches in all directions, which run at right angles, and as they approach the circumference of the lobule they divide dichotomously; they also communicate with each other by transverse branches. The diameter of the capillaries is said to be about 0·01 mm., and, to show how close is the network formed, they are separated by an interval of only 0·015 mm.

Every space left between the vessels of the capillary plexus is filled by hepatic cells, which assume a polyhedric form by mutual compression, and become indented by the capillaries between which they are situated.

The hepatic cells, when isolated, appear as round or sometimes angular bodies, with an average diameter of 0.018 to 0·026 mm. (Kölliker). They consist of a finely granular material, without any investing membrane, and contain in the interior one, or more rarely two, ellipsoidal nuclei. The cell substance is frequently sprinkled with small granules or groups of granules of biliary pigment, and refracting molecules of fat of various sizes. The latter are sometimes replaced by a single large globule, round which the cell is folded as a membrane, the nucleus being generally visible upon some part of the wall. It must of course be remembered that the rounded or natural form of the cell is very seldom seen; on the contrary, the usual appearances presented by it are those of a mass of protoplasm of brownish tint, and of polyhedric or angular contour; but this is the acquired form which, determined by the pressure of other cells, has become fixed by post-mortem or artificial coagulating agencies. The question has been much discussed whether the hepatic cells are possessed of a membranous envelope, and whether there is any cement between the various cells; latest opinions seem on the whole to incline to the opinion that, though the exterior of the cell may be condensed and hardened, there is no special envelope and no cement substance between the cells.

The hepatic cells and the blood conduits having been described, the biliary capillaries now require mention. These are of very small diameter, much smaller than the blood capillaries, and require very high powers for their detection. They are cylindrical canals of 0·001 to 0·002 of a millimetre, and they form a close plexus which runs between the hepatic cells. Their arrangement in the lobule is such that they always run separately, that is, unaccompanied by any blood vessel. They usually run between the planes of contact of two adjacent cells, consequently whenever the planes of two hepatic cells are seen in contact,—that is, in a straight line,—a biliary capillary may be observed either presenting as a minute oval or circular aperture at some point of the line,—usually the centre,—or running parallel to it above or below the surface of the section. They have no membrana propria, but are channelled out of the cell substance. Of more importance, however, than the biliary capillaries, pathologically, are the

biliary ducts, seeing that important changes are described in the latter; the former are so small as to be rarely visible. The principal divisions of the hepatic duct accompany, it will be remembered, those of the hepatic artery and portal vein; it is from them that the finest intralobular channels take their origin. The larger branches of the biliary duct are composed of a fibrous sheath, and inside this a mucous membrane; the latter is lined by a single layer of tall columnar cells, and supports a close capillary plexus; the former is fibro-muscular, and carries a few blood vessels. In the medium-sized ducts the epithelium is still columnar, but lessened in height, and the finest ducts possess only an epithelial layer which consists of polyhedric cells lying free in the interlobular connective tissue. The nuclei of the epithelium are elongated in the axis of the cells, and their shape varies, therefore, as the shape of the cell. Vertically oval in the larger tubes, they are round in the medium-sized, and oval in the direction of the long axis of the small tubes. The larger tubes are further studded with small glands, which are probably extrusions of the lining membrane of the ducts, their epithelium, like that of the ducts, being columnar. The change from the finest epithelial celled ducts into the minute intralobular channels or biliary capillaries would appear to be a sudden one, and is accomplished in this way: the membrana propria ceases at the circumference of the lobule; the epithelium of the ducts rapidly assumes the granular appearance of the hepatic cells, and the narrow lumen is continued onward as a passage of the same size between the hepatic cells (Stricker, New Syd. Soc., vol. ii., p. 22, fig. 123 (1).

The relation of the duct epithelium to the hepatic cells just alluded to is of importance in its bearing upon points which have to be discussed in pathology. In some forms of cirrhosis of the liver it is said that the biliary ducts increase *in number*; and it is responded on the other hand that they do not do so, but that what have been called biliary ducts are in reality the hepatic cells which in multiplying and forming the new fibrous tissue which constitutes the main feature of the disease come to resemble ducts.

It will be seen at once, by a careful study of the epithelium of the terminal biliary ducts and the terminations of these in the hepatic parenchyma, how difficut it must be to decide such a question. But of this more hereafter; it will be sufficient to note here the anatomical condition with the bare indication of its pathological bearing.

Enough has been already said of the circulation, except that the hepatic artery supplies Glissons capsule and its veins by a wide meshed plexus, the capillaries of which anastomose with each other; by its radicles upon the capsule it anastomoses with the mammary, phrenic, and supra-renal arteries; and the venous channels in correspondence with it are the portal. It may be as well also to recapitulate that, while the branches of the hepatic artery anastomose freely with each other, the branches of the portal vein never do so, nor do those of the hepatic vein; and further, the portal and hepatic veins communicate in no other way than through their capillaries.

Lymphatic System.—The larger trunks form two distinct sets, a superficial running on the capsule, and discharging in this direction; and a second or deep-set emerging from Glissons capsule. But in the liver, as in all other organs, it is the custom of the present day to describe an all-pervading perivascular system of lymphatics. These have been described by MacGillavry, Frey, Biesiadecki, and others. They need no special description, since in form and arrangement they correspond with the capillaries, except that they are wider, and contain the capillaries in their interior. Hering, however, does not consider the existence of these spaces proved, and it is certainly no easy matter to make oneself positive of their existence.

Connective tissue.—The capsule of the liver is a membrane for the most part of extreme tenuity, which, where it receives a peritoneal investment, consists of two layers, a superficial serous and a deep fibrous. The connective tissue of Glissons capsule forms an investment to the larger veins, and incomplete septa between the lobules. No proper fasciculi of connective penetrate into the interior of the lobules in the healthy organ, but there is a delicate intralobular connective tissue which forms a reticulum between the capillaries. In many of the branches of the portal canals a considerable number of the rod-shaped nuclei of non-striated muscle may be seen. Non-medullated and a few medullated fibres enter at the portal fissure into the other structures in Glissons capsule, but none are demonstrable beyond the exterior of the lobules.

There remains yet one other point which calls for notice, namely, the development of the liver. Some of the most recent researches in morbid histology seem to show that a knowledge of embryology throws light upon some of the pathological changes met with in the liver. There is some uncertainty about the origin of the liver cells, but it is possible that, while the ducts are in great measure derived from the hypoblast, they are of mesoblastic origin.* From which it would follow that the liver cells are related to the connective tissues, and not, as the ducts, to the epithelial structures, like other glandular cells. If this be so, a probable histological difference is foreshadowed between the parenchymatous diseases and the duct diseases of the organ. Whether this is a view which conforms to what we know of hepatic pathology must be determined hereafter in its proper place.

Morbid Histology.

We may now pass to the consideration of the main part of our subject, taking first of all certain elementary lesions of the liver, of its fibro-cellular tissue, its vessels, and its secreting cells. And since the last named are the essential part of the organ, and their morbid changes are in some respects perhaps least well known, there is reason for following other authors, and for considering the alterations undergone by the hepatic cells as of primary importance, and for making them our point of departure.

The hepatic cells undergo various changes, of which the following are the chief:—

1. Hypertrophy.
2. Fatty infiltration.
3. Atrophy.
4. Fatty degeneration.
5. Granular degeneration.
6. Lardaceous degeneration.
7. Pigmentary degeneration.
8. Proliferation.

Hypertrophy of the liver cells is commonly held to include not only increase in their size (true hypertrophy), but increase in their number (hyperplasia). Probably this is because it is usual to speak of hypertrophy of the *organ*, rather than of hypertrophy of the cells composing it. Rindfleisch considers the utility of distinguishing between the two conditions to be but problematical, from the undoubted fact that variations in the size of the cells, and appearances indicative of increase of their number, may often be observed in healthy livers. But as the science of histology advances, the behaviour of elementary cells becomes a subject of greater importance and increasingly clear; and at the present day it is not a matter of indifference whether we distinguish (as we shall do) or not between hypertrophy and hyperplasia, or proliferation. The two conditions are often found combined, but they are nevertheless distinct; and it is of importance that they should be held to be so, otherwise we are apt to forget that the liver cells possess this power of self-multiplication, and are disinclined to admit its existence as an important feature of pathological processes; whereas indeed it is almost certain that if the liver cells can be shown to increase in number on the physiological side of the line, hyperplasia is a fact that must be reckoned with in morbid conditions also—an important *prima facie* argument the force of which will be evident to all who have studied the recent advances in the morbid histology of the liver.

Hypertrophy, the less important because the less frequent of the two, according to present knowledge, occurs under varied conditions; sometimes as an individual peculiarity in healthy men,* when it does not admit of the designation "morbid"; it is in fact a physiological excess; as such it is not uncommon, and no special significance attaches to it. But it appears to occur with some constancy as part of a morbid process, if hardly more so in its essence than before, in certain states of hepatic congestion, particularly in diabetes. That the liver is large in diabetes is a matter of common observation; but MM. Cornil and Ranvier state that the hepatic cells are more voluminous, and they are said to contain more glycogen than usual. Rindfleisch describes similar appearances, but expresses himself somewhat cautiously that they are *perhaps* owing to an increase in the bulk of the cells. It occurs as a localised change in many cases of cirrhosis, and then no doubt, as Charcot ('Leçons sur les Maladies du Foie,' p. 24) says, it is to be looked upon as a compensatory change. This author also states that hypertrophy of the hepatic cells is found in leukæmia and adénie, or Hodgkin's disease, and both Thierfelder and Klebs make a similar statement (see also Frerichs); but I am not prepared to endorse this

* 'Comparative Embryology,' Balfour, vol, ii., p. 632; and fig. 422, p. 633.

* Birch Hirschfeld, 'Anat. Path.,' p. 949.

of my own knowledge. The question of size is not an easy one to determine, even by careful observation, because the hepatic cell is a unit of no fixed dimensions, and changes its shape with great readiness according to variations in surrounding pressure. But there is no reason to suppose that the hepatic cells are endowed with a peculiar physiological inaptitude for hypertrophy, as a belief in its non-occurrence would necessitate; there are some facts in health and disease, which, if not unequivocal, are still in its favour; and all recent investigations into the growth of the liver cells point strongly to the conclusion—which probably but few pathologists would not willingly endorse—that hypertrophy of the individual cells is a condition which at least requires mention.

Fatty infiltration is a storage of an excess of fat in the hepatic cell, without destruction or degeneration of it or its nucleus. Minute droplets of oil are a normal constituent of the hepatic cell, and under certain circumstances these swell out into several large drops or fall into one, when the cell becomes expanded by a large oil globule (Pl. 20, figs. 2, 3), the nucleus being flattened out upon one part of it. Under the microscope a series of oily-looking globules are seen, which may entirely obscure the hepatic cells; but if the fatty matter be removed by ether, the cell assumes the appearance of the so-called vacuolation; the part previously occupied by oil now becomes a cavity, and on one side of it may be seen the nucleus, with the flattened-out protoplasmic material of the hepatic cell. (Plate 20, fig. 2; 20, fig. 3 *d*.)

It sometimes happens that this definition of fatty infiltration, and its consequent distinction from fatty degeneration, though true in the main, becomes somewhat finely drawn. In poisoning by phosphorus, for example, there are appearances which indicate fatty infiltration at its commencement, but the termination is one of fatty degeneration.

Atrophy.—The hepatic cells are exceedingly prone to atrophy, meaning by this to become smaller. The examination of any series of specimens taken haphazard will indeed furnish convincing proof that their size is regulated very much by the surrounding blood-pressure; if this increase, the cells alter in shape and decrease in size, till they may be hardly recognisable. This is best seen in cases of nutmeg liver (Pl. 21, fig. 4), where the liver cells which should occupy columns of certain breadth become compressed into a mere network of fibres, and sometimes not more than the nucleus of each cell is to be distinguished. This atrophy from absorption, consequent upon pressure, is perhaps the only form of simple atrophy; other forms are so frequently associated with degeneration of one sort or another. Nevertheless some of these border land conditions must be mentioned. And first of all, because least doubtful, is the diminution in size of the cells which follows starvation and wasting diseases (atrophy from diminished function and nutrition); then comes the atrophy of old age, with which, however, there is more or less pigmentary degeneration, a qualitative as well as quantitative form (Plate 22, fig. 8); and there is the atrophy which precedes or accompanies some forms of infiltrating new growth, and which again may easily be mistaken for, but is quite distinct from, the diminution in the size of the hepatic cells which is due to an increase in their number (Pl. 20, figs. 3, 4, 5). The so-called acute atrophy of the liver is so obviously a degeneration of the cells (qualitative atrophy) that it is omitted here.

Fatty degeneration.—In fatty infiltration the hepatic cells contain an excess of a normal constituent, but their structure and functions are but little impaired. In fatty degeneration it is otherwise. Sooner or later the nucleus and its surrounding protoplasm become completely destroyed, and the function of the cell ceases. Such a change as this, although no doubt in the case of isolated cells it is one of the normal processes of decay, sometimes attacks the whole organ, or a large part of it, when it becomes a serious disease. It is best seen in cases of acute yellow atrophy or poisoning by phosphorus (Plate 20, fig. 12), but is a condition which is no doubt somewhat widely spread over the morbid anatomy of diseases of the liver. It notably occurs in cases of acute alcoholic poisoning and in most severe febrile disorders, but also in more chronic affections, idiopathic anæmia amongst others.

Granular degeneration, though distinct from the above, is in all probability closely allied to it. The hepatic cell becomes swollen and cloudy-looking; the nucleus is obscure and sometimes obliterated. It has received various names, such as cloudy swelling, parenchymatous hepatitis, parenchymatous degeneration, and is very common. It has been described and figured by Dr. Klein as one of the results of scarlatina (Trans. Path. Soc. of Lond., vol. xxviii.); by

Liebermeister in pyæmia, tuberculosis, and typhoid fever; by Buhl and others in puerperal fever. But it is found more or less in all acute febrile states, whether they be part of the process of a contagious fever or of an acute inflammation; and Dr. Wickham Legg has extended its domain still further, and concludes from the results of experiment upon the lower animals that an abnormally-high body temperature, apart from any specific cause, may suffice for its production (Path. Soc. Trans., vol. xxiv., p. 266). It is probable that to produce such changes the elevation must be considerable or somewhat prolonged; but the subject is one of great importance because it supplies one of the most convincing arguments in favour of those methods of treatment, as cold baths, which have of late years been advocated and practised for keeping "fever" within moderate limits.

Lardaceous degeneration.—The occurrence of lardaceous disease of the hepatic cells has been much discussed, and can hardly even now be said to be definitely settled. Virchow and many subsequent authorities have always maintained that it is essentially and primarily a disease of the small vessels. Klebs, Foerster, Rindfleisch, &c., contend that the hepatic cells are also affected, and often severely. Of late, however, opinion has swung round, and Wagner's view that the liver cells under no circumstances become lardaceous is very generally adopted now. Like many other such questions of minute structural change it is possible to interpret appearances seen under the microscope in more than one way, and I must confess to being still inclined to think that the hepatic cells become lardaceous. If so, the cell becomes glassy-looking and gradually swells. It next loses its outline and its nucleus, becomes blurred, and impossible to focus, from its high refracting properties. In the extreme conditions the individual cells are not to be recognised, but the surface of the section is studded over with irregular masses of vitreous-looking lardaceous material, which may represent swollen cells, or possibly several which have become fused into one (Pl. 20, figs. 1, 10). If, on the other hand, the cells do not undergo this change, then the description must stand thus: the lardaceous material infiltrates the vascular areas, and the hepatic cells compressed by its continued advance become fatty and atrophy.

Lardaceous disease, when far advanced, is readily recognised by the microscope without the addition of staining fluids; but it is well in all cases to stain the section either with a watery solution of iodine or methyl anilin, either of which the lardaceous material absorbs greedily.

Pigmentary degeneration is for the most part one of the concurrent results of atrophy (Pl. 22, fig 8.). The hepatic cells are small and shrivelled, and contain minute grains of black or orange-tinted material. It is a condition which has a somewhat irregular distribution in the liver. Some lobules may be quite free, others much affected. It is best seen in cases of senile atrophy, or in the red atrophy of Virchow, which is the result of heart disease,—the condition which is better known in England as the nutmeg liver,—and in exceptional cases of cirrhosis, of which mention is made by most writers (Frerichs, Dis. of Liver, N. Syd. Soc., vol. i., p. 317; Cornil and Ranvier, vol. iii., p. 927). This condition must not be confused with pigmentary infiltration, which produces the pigment liver. In such the pigmentary deposit is not in the hepatic cells, but in the vessels and connective tissue.*

Proliferation of the hepatic cells has not hitherto found much mention in Manuals of Pathology. At the same time all who are familiar with morbid histology must have repeatedly come in contact with appearances which have left but little doubt upon the point in the minds of individual observers. There can indeed be no doubt that the hepatic cells increase by subdivision under certain circumstances, and increase largely. For instance, if, as is unquestionably the fact, the left lobe of the liver can grow to a size equal to that of the whole organ, when from one cause or another the right lobe has atrophied, an increase so large puts mere swelling, or even increase of the size of the cells only, out of the question; and the enlargement must be due at any rate in part, and probably in great part, to increase in the number of the hepatic cells. Then there are cases recorded by Hoffmann (Virch. Arch., 39, 193) and Friedreich (*Ibid.*, 33, 48), to which Klebs alludes as tumour-like, nodular forms of hyperplasia. These are cases in point, although for description they may be left to the section which treats of adenoma. Again, all histologists must be familiar with appearances on the outskirts of many of the new growths met with in the liver, which make it very likely indeed that the hepatic cells themselves take part in the process (Plate 22, figs. 11, 12, 13; see also Coupland on Primary Sarcoma of Liver, Trans. Path. Soc.,

* Frerichs, *op. cit.* Birch Hirschfeld, *op cit.*, p. 472.

vol. xxxi., p. 130; Schueppel on Adenoma of the Liver; Zeimssen's, Cycl., vol. ix., p. 352); and Dr. Creighton, as is well known, has attempted to trace the stages of the process in his most admirable Report to the Privy Council. Figs. 14, 15, 16, Plate 22, are copied from Dr. Creighton's Report.* But more important still are the investigations which have extended this doctrine of hepatic cell proliferation to so large a series of cases as cirrhosis. These form a gradually enlarging and now nearly complete series, commencing in some experiments by Holm and other continental observers upon some of the lower animals; continued by Wickham Legg,† and latterly described in detail by MM. Kiener‡ and Kelsch, Dr. Hamilton,§ and Dr. Dreschfeld.|| The changes (Pl. 20, figs. 4, 5; 21, figs. 1, 3) which the liver cells undergo are thus described by Hamilton:—The nucleus becomes swollen to perhaps twice its original size, and it takes staining fluids with undue readiness and greed; at the same time a nucleolus becomes visible, with a prominent intra-nucleolar plexus around it; segmentation next occurs both of the nucleus and its cell or periplast, and two new cells are thus generated. The nucleus in each continues to grow, and the periplast becomes proportionately diminished; the process of division is repeated again and again, and finally the periplast disappears and free nuclei only are left. Each nucleus now enters upon a separate existence; it becomes oval, generates a new periplast from its border, and the whole assumes the shape of a spindle-cell; the fusiform periplast next splits into a number of fibrils, becomes gradually more elongated and attenuated at its extremities, and finally a bundle of white fibrous tissue is formed, the nucleus remaining as the nucleus of the bundle. Others ascribe the formation of biliary canals to the hepatic cells, Brieger (Virch. Arch., vol. lxxv., p. 85), merely considering that they play a passive role by atrophy; Dreschfield (*loc. cit.*) that they proliferate to the same end. It is probable that this doctrine will not stop even here, but that it will be extended to other processes of rapid cell growth which occur in the liver. I have myself seen, more than once, appearances indicative of these active changes in the liver cells in diffused tubercular growth in the organ (see Path. Soc. Trans., vol. xxvii., p. 196), and in other anomalous cases less easily named, particularly in the case of a child admitted, from my out-patients, into the Evelina Hospital under the care of my colleague, Dr. Baxter. She was a girl aged 23 months, and was slightly jaundiced; she rapidly became comatose and died, and the changes in the liver bear the interpretation of a general proliferation of the hepatic cells (Pl. 22, fig. 1). This case will be given in more detail subsequently.

On the other hand, some caution must be exercised in drawing our conclusions upon this point, for there are many difficulties in the way of a correct interpretation of the microscopical appearances. The atrophy of the cell protoplasm which so readily occurs may lead to appearances very similar to those found when the cells are proliferating. The nuclei in either case are surrounded by an unusually small amount of periplast, or by none at all. Then in dealing with such minutiæ and with specimens in which we cannot see the actual process at work, where we are obliged to infer what has been from what is, it is by no means easy, whatever we may think, to prove that certain elements are derived from the liver cells, and not from the nuclei of other parts, such as the blood vessels, connective tissue, or even the bile ducts. One of the best evidences of this is to be found in the fact that the changes in Glissons capsule found in cirrhosis, and which are sufficiently constant to make it certain that a long series of observers have been at work upon similar structural alterations, have at different times been ascribed to over growth of the connective tissue, to new growth of bile ducts, and to proliferation of the hepatic cells.

Connective Tissue, and its canals biliary and vascular.

Till quite recent times thickening and over growth of Glissons capsule have monopolized the attention of pathologists. It was supposed,—or more than supposed,—it was asserted upon the basis of a large number of observations, that under certain conditions of vascular irritation the nuclei of the connective tissue increased in number. An increase of fibrous tissue followed from their development, and it, in its turn, produced

* Reports of the Medical Officer of the Privy Council, 1874.

† On Cirrhosis, St. Bart. Hosp. Rep., 1872.

‡ Archives de Physiologie Normale et Path. vol. xi., p. 355.

§ Journal of Anatomy and Physiology, vol. xiv.

|| Journal of Anatomy and Physiology, vol. xv.

certain definite changes in the hepatic parenchyma. Herein lay the morbid anatomy of cirrhosis. This description has of late received considerable amplification, and what was at one time all ascribed to the blood vessels and the connective tissue is now held by many to be a more complex process, in which other elements are concerned than these. In the first place, M. Cornil, followed by M. Hanot and others, described proliferation of the connective tissue in association with an increase in size and number of the interlobular biliary canals. This change is thought by them to be more particularly indicative of a form of cirrhosis in which the liver is much enlarged, and in which other features exist also which help to indicate a disease which is special and peculiar. M. Charcot by still further description and demonstration has sought to place this change upon a more sound basis of support. And now, therefore, in examining any case of cirrhosis one has to reckon not only with the connective tissue, but also with the biliary canals. And whereas in former years it was sufficient to observe the relations of blood vessels—portal vein particularly as supplying a more adulterated blood—and connective tissue, it is now neccessary, according to some, to distinguish between an increase of connective tissue which is vascular in its relations and an increase which is biliary. One great argument in favour of this view has been derived from experiments made upon some of the lower animals, and in which it has been found that irritation of the bile ducts, such as placing a ligature upon the common duct, leads to changes in the liver of a cirrhotic nature. But the observations upon this point are somewhat contradictory. Litten,* for instance, conducted his experiments antiseptically, and no cirrhosis followed.

Moreover, chronic obstruction of the ducts, either by cancer or gall-stones, is by no means uncommon, but it is exceptional for such conditions to co-exist, with any marked cirrhosis. Dilatation of the biliary passages may be present to an extreme degree,—plugging of the passages by inspissated bile,—nay, even a characteristic infiltration and disintegration of the hepatic parenchyma may occur; but cirrhosis in any of these conditions, as a disease producing certain definite symptoms, though I do not deny its occasional occurrence, is exceptional. In this I am only re-stating what was long ago said by Frerichs—"In the various grades and forms of obstruction to the flow of bile, which have come under my notice, the liver never presented any granular characters." And it is not a little curious to notice that this observation is in response to the observation of Rokitansky, that one form of cirrhosis was due to a morbid development of the capillary bile ducts (Frerichs, 'A Clinical Treatise on the Diseases of the Liver,' New Syd. Soc., vol. ii., p. 32). Thus the cycle of medicine has gone round, and the question of twenty years ago is discussed again. There is no doubt about the facts as seen by the microscope: these are, that in some cases of cirrhosis the increase of connective tissue is mostly around the small branches of the portal vein (common cirrhosis); in others the increase is associated with the presence of abnormally numerous tubular processes of cells or interlobular biliary canals, in accordance with Rokitansky's original statement, and no doubt it is around these tubes or processes that the cell growth is particularly active (biliary cirrhosis). Lastly, in rare, or at any rate in as yet but seldom-recognised, cases, the intercellular stroma of the organ is increased (pericellular cirrhosis). But upon the interpretation of these appearances there is still considerable doubt; and with regard to the increase of the bile ducts, opinion is on the whole inclined not to regard the activity of the duct as a primary change, inducing later or secondary activity in the connective tissue immediately surrounding them, but as due in common with it, to some stimulus which exists —for both changes are found more or less in combination—in all forms of cirrhosis.

Pericellular cirrhosis, where the increase of connective tissue is not confined to the exterior of the lobules, but invades and separates the network of the hepatic cells, is at present but little understood; but it is probably not uncommon. It has been specially described as a feature of congenital syphilis. It is more or less mixed up with other forms of cirrhosis, if the disease be in an active or proliferative stage; and it is present as an extensively-diffused change in some forms of cancer. In cases of this kind, however, the inflammatory or cirrhotic nature of the products may be open to question. In the former cases the disease is usually indicated under the microscope by the presence of a richly-nucleated material between the columns of hepatic cells; in the latter by an

* Charité Annalen, vol. v., p. 153.

excessive quantity of hyaline fibroid bands. This distinction between the cellular and fibrous products of inflammation is, however, requisite for all forms of cirrhosis; for it will be found that, while excessive cell growth and excessive fibre often co-exist, some forms of disease are much more one than the other. The late stages of a very chronic process may show nothing but fibrous tissue, just as a granular kidney may sometimes do; the active stages are the stages of cell proliferation. The fibrous material is in many cases but a relic of the past.

The *degenerations* of the connective tissue of the liver may seem hardly to require mention, yet they are not without interest, and possibly they may yet have a future before them. In saying this, I have in mind the oft-described albuminoid disease of rickets and the changes which have been observed by Dr. Ord in the liver in the disease which he has called myxœdema. This is not the place to express any opinion upon the nature of such generalised diseases, but we can deal with the recorded facts as regards the local changes; and it would appear that under certain circumstances the intercellular stroma of the liver becomes increased in quantity and altered in character; so that—to use Dr. Ord's words of the disease, of which he has made a particular study—the fibrillar element of connective tissue and the mucin-yielding interstitial cement are everywhere found in great excess. Everywhere the connective tissue appears to have undergone a degeneration, a retrograde change, bringing it into close resemblance with the mucin-yielding connective tissue of the umbilical cord. Plate xxii., fig. 10, is copied from a drawing which was kindly lent for the purpose by Dr. Ord, and which he has already published in the 'Transactions of the Clinical Society.'

This description is of course only strictly applicable to the disease myxœdema; but it seems probable, from the accounts that have been given of it, that the albuminoid disease of rickets is due to an excess of some embryonic form of connective tissue, and therefore, leaving the chemical question out of consideration, is possessed of similar histological features. How far such changes are allied on the one hand to lardaceous degeneration, and on the other to the less pronounced hyaline changes in the walls of the small vessels and in the connective tissue which have been observed after severe pyrexia, for instance, and in the so-called arterio-capillary fibrosis of senile degeneration is a question of the greatest interest,—nay, even of the greatest practical import,—and still presses for solution.

Pigmentary degeneration of the liver. — The deposition of pigment in the liver which takes place in and after some forms of malarial fever is described as a degeneration, but the propriety of the term may be questioned. When it occurs the pigment is deposited in black granules in the lymph cells of the blood stream; in the walls of the radicles of the portal veins; in the connective tissue around them; and in the capillary veins; and it sometimes happens that by the copious distribution of pigment in the capillaries, and even in the hepatic veins, that the section of the liver assumes a grey tint. The hepatic cells are stated to be free from pigment in all cases. The lobules are by this means mapped out with great distinctness, all the more marked because there is usually some increase in the quantity of the connective tissue in the portal canals. In other words, more or less cirrhosis is apt to be associated with pigmentary changes.

A somewhat similar state of things as regards the presence of pigment in the blood has been observed with some of the melanotic sarcomata, but in their case the local deposition of pigment in the liver is confined to the cells of the new growth.

The *lymphatic spaces* in the hepatic connective tissue can hardly be said to have any special affections. Thierfelder * has described their distension by fibrinous material in cases of heart disease; and Charcot, from what he has noticed in abscesses and experimental studies on guinea-pigs, describes an aggregation of leucocytes in spaces between the liver cells and their capillaries. In addition to alterations such as these, we have the disseminated nodular growths of adenoid tissue which are characteristic of tubercle, Hodgkin's disease, and some cases of leucocythæmia.

Blood vessels.—Nor need we delay long with the blood vessels of the liver, since they come into sufficient prominence in connection with the diseases in which they take part. We can indeed discuss, if so minded, here, as elsewhere, the part played by the capillary nuclei in the origin of tubercle, and of other new growths. We can discuss the nature of the thickenings of

* Atlas der Pathologischen Anatomie, 3 Lief., Pl. xiv., fig. 2. See also Birch Hirschfeld, *loc. cit.*, p. 930.

the coats of the vessels which take place as old age approaches, and the occasional occurrence of similar changes in premature old age—as regards the vessels—in young people. We might allude again to the hyaline degenerations of the vessels in fever; but all these are questions and facts of general pathology which have no certainly known bearing upon the diseases of the organ, and therefore we pass them by.

The affections which are of importance, and which will presently be described, are—(1) the stasis and dilatation of the branches of the hepatic vein which occur when any prolonged obstruction to the passage of blood through the pulmonary circulation exists; (2) the occurrence of thrombosis in the portal vein or some of its branches, an occasional result of cirrhosis of the liver, but more often due to inflammation around some of the radicles of the portal vein—ulceration of the intestines, for example—when it is liable to lead to abscess; (3) lardaceous disease of the vessels; (4) the occasional presence of cavernous tumours or nævi; (5) the changes in the vessels in advanced cirrhosis, and the production of a quasi-cavernous structure in the branches of Glissons capsule; the occasional calcification of the coats of the portal vein from chronic inflammation; and atheromatous changes in the arteries, as the result of senility; or the rare presence of an aneurism.

The diseases of the biliary passages and gall bladder will receive separate treatment subsequently.

After these preliminary considerations we may now proceed to consider the pathological anatomy of the diseases of the liver. The subject is perhaps most conveniently discussed as (*a*) Diseases of the liver and its capsule, including some of the affections of the portal vein. (*b*) Those diseases which affect more especially the trunk and main branches of the portal vein. (*c*) The diseases of the gall bladder and the bile ducts.

DISEASES OF THE LIVER AND ITS CAPSULE.

Under this first heading come hypertrophy; atrophy; fatty infiltration; lardaceous disease; congestive diseases, particularly the red atrophy of heart disease, and of stasis in the pulmonary capillaries; inflammation, including perihepatitis, cirrhosis, and abscess; syphilitic disease; tubercular disease; pigment deposits; cysts; the various new growths; and parasites.

Hypertrophy.

In treating of diseases of the liver it is no longer possible to keep strictly to the distinction between hypertrophy and hyperplasia, which was attempted when speaking of the hepatic cells. It would still be worth while to do so, were it possible; but, as I have said previously, a physiological excess of growth is part of the process of hypertrophy, and it is hardly possible for hypertrophy of the *liver* in any recognisable form to occur without the combined aid of increase both of size and number of the hepatic cells. Let these therefore be understood as together constituting hypertrophy of the liver. The condition is seen at its best where disease, such as abscess, hydatid cysts, or syphilitic cicatrices, has destroyed a large part of the organ. If the patient should live long enough, the remainder of the liver will undergo an increase equal or nearly so to the destroyed part, and the hypertrophy may truly be termed compensatory. To give one or two such cases out of several: the right lobe of the liver was entirely destroyed by a gummatous and fibroid deposit, the whole lobe not weighing more than two to three ounces. The left lobe weighed forty-six ounces, and thus formed a new liver not far short of the average bulk. All authors allude to this condition. Frerichs writes thus:—"In addition to the deep cicatrices which are frequently developed as the result of syphilitic hepatitis, or from obliteration of the branches of the portal vein, or from any other cause, the hepatic parenchyma is frequently found hypertrophied and greatly swollen, and provided with enlarged cells and lobules, so as to compensate more or less completely for the loss of substance." Wilks and Moxon mention a case where the whole right lobe was destroyed, and the left weighed fifty-six ounces. But such wholesale destruction and compensation as this is by no means the common or the only form in which it exists. Hypertrophy takes place more or less in many cases of lobular atrophy, and may thus appear distributed irregularly throughout the organ, as happens in many cases of cirrhosis; sometimes it may be confined to one or other of the smaller lobes—the lobulus spigelii, for example, which I have found to be enormously enlarged from neighbouring

atrophy of other parts of the liver from the presence of a hydatid cyst.

Other causes of hypertrophy are usually enumerated, but they hold a much less definite position. There is the hypertrophy of diabetes. In many cases of diabetes the liver is no doubt enlarged, but most of the augmentation is probably due to congestive swelling; some of it to increase of glycogen in the hepatic cells. But MM. Cornil and Ranvier, after the examination of several cases, describe a true hypertrophy of the liver cells in diabetes; and it is indeed difficult to dispute this conclusion with such confirmatory evidence, after the careful examination already recorded by Stockvis and Frerichs.* According to these writers, the hepatic cells enlarge—contain numerous nuclei and nucleoli, and small, apparently young, cells are mixed up with them.

Leukæmia is another reputed cause of hepatic hypertrophy, but if we separate from the enlargements of the organ—which are admittedly usual in this disease—the swelling due to overcrowding of the vessels with leucocytes, the extravasations of leucocytes in the tissue, and the growth of the new material which constitutes so important and constant a feature at any rate of the glandular form of the disease, there will not be much ground left for the occurrence of a true hypertrophy.

Finally, Klebs† mentions a hypertrophy (hyperplasia) as a condition found in men who have been topers. This, however, is a rather vague condition, although it opens up a very interesting field of enquiry. In making any large number of inspections the weight of the liver will be found to vary considerably, even in cases where the body-weight is about equal. And it would appear that, taking a series of bodies of about equal weight, some require, or at any rate are furnished with, more liver than others. It is the same for the other viscera: some bodies have sixteen or eighteen ounces of kidney to the average of ten or eleven, and this without any disease. We can only suppose that these variations are due to individual peculiarities in the correlated working of the parts of the machine; that some people make more use of one organ than of another, and that accordingly we meet with hypertrophy here or there. This subject is by no means unimportant, for increased use means increased wear and tear, and increased chances of premature breakdown; but unfortunately our knowledge of the working of the various viscera is not as yet so intimate that we can tell of the existence, far less foretell the onset, of such forms of hypertrophy as these.

The hypertrophied liver is healthy to all appearance externally; on section it is less mottled than usual, the lobules less well defined and often smaller than natural, although more numerous. Under the microscope the cells sometimes correspond, being small and numerous; or they may be large, and contain a large single nucleus or a double nucleus—perhaps several; the nuclei taking dyes more readily, and therefore becoming more deeply coloured than in the more mature cells.

Atrophy.

Four forms require mention:—(1) Simple atrophy; (2) atrophy from pressure; (3) brown or chronic atrophy; (4) acute yellow atrophy. I exclude the term red atrophy because it is confusing—some authors having applied it to a condition found associated with acute yellow atrophy; others to some of the forms of atrophy from pressure (the atrophy of cardiac and pulmonary disorders); and others again to the third form (brown or chronic atrophy).

Simple Atrophy.—The liver is small in all its dimensions, the left lobe and the anterior margin being often more particularly wasted; it is dark brown in colour, its capsule being wrinkled from the wasting of the glandular elements within it, and it is tough both when cut and on pressure. The latter characteristic is also no doubt due to the wasting of the glandular elements, and to the consequently disproportionate residue and greater condensation of the fibrous tissue.

The microscopic changes are shrivelling of the hepatic cells, and excess of brown or orange pigment within them. The portal canals generally appear thick, and there may be a slight excess of nuclei studded about them; but this increase is for the most part a relative, not an absolute one.

The disease is one of the results of old age, or of wasting diseases associated with starvation. Most writers allude to its occurrence as a result of cancer about the œsophagus and stomach.

2. *Atrophy from pressure.*—This is of course simple atrophy equally with, perhaps more so

* *Loc. cit.*, vol. ii., p. 211.

† 'Handbuch der Pathologischen Anatomie,' p. 370.

than, the former. But it includes quite another class of cases, so that it may be well to consider it separately. Moreover, it includes not only one but several distinct conditions, and the microscopic appearances of the liver will naturally vary accordingly.

Thus it is found in association with perihepatitis. The capsule of the liver being thickened by chronic inflammatory processes, contracts upon the glandular elements within it. The liver becomes much distorted in shape, its anterior edge folded over, and the whole organ more cylindrical. In other cases the pressure may be exerted locally by adhesions in various parts of the capsule; by fluid pent up within adhesions between the liver and diaphragm or neighbouring viscera; or these viscera themselves may be enlarged and encroach upon the organ. In this way the liver may be made to assume a variety of shapes: indented by furrows from the ribs above or the gall bladder below; a lappet of its anterior border may be almost separated from the main body by the girdle-pressure of tight lacing; and fossæ of all shapes and sizes may be made by abscesses, cysts, and other abnormalities almost too numerous to mention. Of the microscopic appearances it is only necessary to say that, in proportion to the pressure, the hepatic cells become smaller, and disappear, and that in extreme cases there is no doubt some corresponding obliteration of vessels. Much has been made by Frerichs of this diminution of the vascular area in chronic atrophy of the liver, and to it have been attributed the ascites and other symptoms occasionally present. But we are inclined to agree, with Thierfelder, that, for this and the first-mentioned form at any rate, the disappearance of vessels is no more than the closing-up of those no longer used; and that any symptoms that might be ascribed to this source are better explained by the conditions of the body in which the atrophy has originated.

Another variety of atrophy from pressure is that arising from persistent distension of the vessels from cardiac or pulmonary obstruction. The liver cells, particularly those around the intra-lobular veins, become much atrophied and full of pigment grains; but this state will receive consideration a little farther on, as the nutmeg liver.

In the same way cases of cirrhosis of the liver are, many of them, cases of atrophy of the hepatic cells, either local or general; but this also will be alluded to under "Cirrhosis." Nor does this exhaust the list of diseases in which a similar state of things is found. It is sometimes well marked in idiopathic anæmia, and several other affections; and it must be considered a by no means uncommon occurrence in a variety of distinct and not easily connected conditions.

3. *Brown or Chronic Atrophy.* — Were I to detail only my own experience I should be inclined to follow Rindfleisch and Birch-Hirschfeld, who make no mention of this form, except it be a condition of simple atrophy. But it would appear from the larger experience of others that, besides other senile changes already described, there is another form. It was described originally by Frerichs,* and its existence has more recently been affirmed by Dr. Moxon and Dr. Murchison.† The liver shrinks in all directions—cases are recorded by Frerichs where it weighed 22¼ and 24½ ounces: Dr. Moxon has found it weighing only 28 ounces. The coarse appearances do not differ materially from the liver of simple atrophy, but it is flabby and soft; the colour dark reddish brown. The lobules are either indistinguishable or very small, and Dr. Moxon calls attention to certain small grey tubercle-like points which may be seen upon the surface of the section (Plate xvii., fig. 2). Microscopic examination shows, as in the senile form, shrivelling of the hepatic cells, sometimes even to their complete disappearance. They contain much brown pigment in granules; sometimes oil; Glissons capsule is thick. But the more important change appears to be one affecting the vascular area. The smaller branches of the portal vein are described by Frerichs as terminating in club-shaped extremities where they should subdivide into capillaries. The capillaries are in great measure destroyed or filled with granules of brown pigment. The small grains described by Dr. Moxon are composed of "remains of liver tissue in which all the veins were occluded." Both authors describe an impermeability of the portal vein to injection.

It is important to note that this disease appears to be associated with intermittent fever; that although it for the most part occurs, if we can so speak of a rare disease, at or after middle age, it has been known to be present in young people; and that, unlike the senile or marasmic form, it is associated with enlargement of the intestinal branches of the portal vein, with ascites, a

* Frerichs on Liver, New Syd. Soc., vol. i., p. 250.

† Wilks and Moxon, Patholog. Anat., p. 430. Murchison, Trans. Path. Soc, Lond., vol. xviii., p. 152, *et seq.*

deficiency of bile, and sometimes with enlargement of the spleen. Dr. Moxon notes, in addition, the absence of jaundice and the occasional occurrence of diarrhœa. The symptoms in fact are those of cirrhosis without jaundice.

Acute Yellow Atrophy.

(Fasc. III., Pl. 14; Fasc. IV., Pl. 20, fig. 12.)

Morbid Anatomy.—The liver is much reduced in size. Taking the average weight of the human liver to be fifty to sixty ounces, it may weigh no more than sixteen, twenty, or twenty-four ounces, and a case has been recorded where, in a girl of 17, it weighed only thirteen ounces.* This, however, is the most extreme case of wasting that Dr. Wickham Legg has been able to find on record.† But the liver is not invariably small. Liebermeister has attempted to show that a stage of swelling precedes the atrophy: the evidence in favour of this is not much, though it may well be—considering acute yellow atrophy to be only one of several local manifestations of some general state, as is now the most commonly-accepted view of its nature, and the disease to be generally rapid in its course—that any stage of acute swelling would be soon over and the atrophic one commenced, and in this case the earlier stages would be very liable to be overlooked.‡ But if this view is doubtful, there is more to be said in favour of the statement that the liver, though showing changes characteristic of acute atrophy, may yet be of full or even of abnormal size. Many cases are on record with the liver described as of natural size; and when we consider that the disease may affect only part of the organ; that it may follow upon other diseases, such as cirrhosis; that phosphorus poisoning produces almost identical changes, yet the liver is usually large; and that the disease shows some little variety in its duration; it is not unlikely that the amount of the shrinking is in some degree proportionate to the length of time the disease has existed. The liver is diminished equally in all directions, so that it preserves its natural contour; but it becomes exceedingly soft and its capsule falls into unnatural wrinkles, while the section becomes uneven from the immediate bulging of the more pulpy parts. The dominant colour of the section of the organ is rhubarb-yellow. But the capsule is often mottled and perhaps uneven, from the yellow parts only appearing through it in places, the intervening parts being dark coppery-red or greenish and depressed (Fasc. III., Plate xiv.). Neither is the section universally yellow—dark red is usually blended with it. I make use of the term blended advisedly, as there has been some little difference of opinion concerning the relations of yellow and red parts. Some have described them as sharply defined, others as not so; and, so far as I have seen, the two conditions may be blended. But inasmuch as different phases of the disease are probably represented, the more acute by the yellow, the more chronic by the red,—in some cases there is much of the yellow appearance, and but little of the red; while in others the opposite obtains, and these are the more rare. Moreover, the consistence of the organ will in a measure depend upon the amount of the red material, this being of considerably firmer consistence than the yellow. Thus the yellow parts often bulge from the surface of the section, and the lobulation is lost; while the red parts are depressed, and their lobulation may remain distinct. The liver sometimes contains leucin and tyrosin (see case 2), and the bile ducts and gall bladder are either empty or contain a grey mucus: even should they contain a colourless fluid, but seldom does it give any of the characteristic reactions of bile.

Histology.—(Fasc. III., Pl. xiv., figs. 2, 3; Fasc. IV., Pl. xx., fig. 12). From what has been said it will already have been surmised that there is considerable difference in the minute structure of the two parts, and this we shall now find to be the case.

Yellow parts.—The fresh liver should be taken, its cut surface scraped, and the resulting material examined under a 1-4th or a 1-5th inch objective. The liver cells, if visible, will be few in number; they are swollen, their nuclei indistinct, and the cells full of minute granules. The fluid surrounding them is full of minute oil globules and granules of orange-coloured pigment. In the more advanced cases no liver cells are to be seen, the scraping showing nothing but granular matter, pigment, and shreds of liver tissue. When the tissues are hardened the changes are

* Dr. Clements, 'Brit. Med. Jour.,' 1871, vol. i., p. 367.

† 'Bile, Jaundice, and Bilious Diseases,' p, 501.

‡ A case of acute atrophy of the liver is recorded in the 'Trans. Path. Soc. of Lond.,' vol. xxxi., p. 116, by Dr. Samuel West, which confirms Liebermeister's view. On October 9th the liver was much increased in size, and rapid decrease took place till the child's death, six days later.

even more pronounced. Under a 1-inch objective the structure of the liver is hardly recognisable. The place of the liver cells is occupied by a cloudy granular substance, without any distinguishing features, which clings to and occupies the spaces formed by a flocculent network which represents the stroma and the smaller vessels, biliary ducts, &c. Scattered about the field are small clusters of thickly crowded nuclei, which are for the most part situated in the portal channels and can be traced for some distance in small offshoots of Glissons capsule. Not uncommonly they are accompanied by clustered spaces full of cubical epithelium, which are evidently sections of interlobular biliary canals in abnormal numbers or abnormally crowded and visible. The coats of the intralobular veins are not altogether free from over-nucleation, but this change is for the most part one of the interlobular channels.

With higher powers (Fasc. IV., Pl. xx., fig. 12) the granular indistinctness of the cells is very marked; there may be hardly anything visible which is certainly a hepatic cell, but much that might be taken for swollen cells, small cells or nuclei. In particular, there are masses of granular protoplasm of about the size of the normal hepatic cell, which contain perhaps seven, eight, or ten nuclei, and which admit of interpretation in more than one way. It may be said by some they are hepatic cells in process of proliferation, as Winiwarter and others have contended; it may be said that they are hepatic cells which in the process of atrophy have become thus closely huddled. It is difficult to give a positive opinion. At the same time I have seen no evidence whatever in this disease in support of Winiwarter's opinion that the process is one of connective tissue formation by proliferation of the hepatic cells. The masses I have described seem always to remain somewhat isolated from their surroundings, which are not even in most places connective tissue, but are composed of shrivelled cells or other indistinguishable elements. The nuclei remain distinct, though not so distinct as normal; and they are less distinct also than those of the epithelium to be found in the sections of the biliary canals, in many cases hard by.

The excess of nuclei found in the portal canals is very decided, and extends more or less throughout the whole section. The nuclei here also are possessed of great distinctness of outline and uniformity of size, and appear to be separate from the tissue in which they are situated. For which reason I am inclined to think that they are exudatory, and have escaped from the blood vessels; and that they are not the product of any activity either of the hepatic cells or the connective tissue of the liver.

Thus far, I have confined myself to describing what I have myself seen in four cases, and in none of which was the red material a prominent feature But there is some difference of opinion concerning the presence of inflammatory products in the portal canals. None such have been observed in many of the recorded cases, and opinion inclines to the view that they indicate that those cases in which they are found have run a more prolonged course (Fasc. III., Pl. xiv., fig. 2). Of the four cases, from which I draw my own conclusions, one (in which the cellular elements were more limited) appears to have been a very acute case. Dr. Ralfe brought it before the Pathological Society in 1878-9, but it has not received any permanent record in the 'Transactions.' A short note of it is to be found in the 'British Medical Journal' (1878, vol. ii., p. 877). The patient, a boy, was admitted from a training ship to the Seamen's Hospital with jaundice, convulsions, coma, and suppression of urine. For another I am indebted to Mr. Pepper, of St. Mary's Hospital, who made the inspection, and who very kindly supplied me with some pieces for microscopical examination. The case was under the care of Dr. Handfield Jones, of St. Mary's Hospital. He was a man of 22, who had been drinking freely; he had been jaundiced for twelve days, and suddenly became drowsy and then comatose a few hours before death. The liver weighed thirty-nine ounces; it was small, pale, and mottled; its section was of a dull yellow colour, much more marked in some parts than in others, and here the parenchyma was softer than natural; the outlines of the lobules were indistinct; the surface slightly wrinkled and puckered; the biliary ducts empty; the gall bladder containing a small quantity of colourless viscid mucus. Under the microscope no trace of the natural liver substance could be detected. The section was composed mainly of granular and fatty *débris*, in which were embedded a vast number of globules of leucine of greenish yellow colour. Some fine acicular and rhomboidal crystals of pale yellow colour were visible, probably of the nature of tyrosine; these were mostly isolated, but a few were grouped in a brush-like manner.

The third case was in the Sussex County Hospital, under the care of Dr. Kebbell. Dr. Uhthoff has supplied me with the notes of the case and pieces for examination. The man had enjoyed good health till three months before admission, when he started to walk and work his way from Hull to Brighton. He did badly for food and shelter on his way, and when he reached his destination he ate so voraciously as to bring on sickness. Three weeks later he began to feel ill with headache, sickness, and constipation, and ten days later he became jaundiced. He died a fortnight later. He was admitted to the hospital four days before death; the liver was carefully examined daily, but no decrease in the area of dulness was noted till the day before death; the liver weighed 35½ ounces; it was flabby, and fallen away from the ribs; the section was of an orange colour, but there were a few brown spots and streaks more depressed and atrophied than the yellow portions; some healthy liver still remained in the left lobe.

In a fourth case, under my own care, a little boy, æt. 2½ years, had been ailing for three weeks with jaundice and vomiting. In the fourth week he became drowsy and then comatose, with black vomit. The liver was shown at a recent meeting of the Pathological Society of London, and the case will be published in their 'Transactions.'

The *red material* is distinguished from the yellow microscopically by the greater amount of destruction of the liver cells,—which have in many places entirely disappeared,—and the greater preponderance of thickening of the stroma and cell infiltration (Fasc. III., Pl. xiv., fig. 3). Whereas in the yellow parts there are, if not actual liver cells, nevertheless granular and fatty materials which represent them; in the red part these are in great measure wanting. Shrivelled nuclei are scattered about with a network of capillaries of all kinds and shreddy connective tissue (Fasc. III., Pl. xiv., fig. 3), the whole forming a web, with small interstices in which lie a few nuclei, pigment grains, or a granular detritus from the pre-existing hepatic cells. The portal canals are recognised with facility by the nuclei which they contain, and also by an unusual number of small biliary ducts clothed with a layer of cubical epithelium. For a good representation of this condition the reader may be referred to MM. Cornil and Ranvier's 'Manual of Histology.'* There would appear to be some little difference of opinion as to the exact nature of these tubes. I am disposed to regard them as no more than the normal ducts over crowded by reason of the atrophic processes in the hepatic cells in their neighbourhood. But Dr. Dreschfeld* describes: a shrivelling of the hepatic cells at the periphery of the lobule, till they come to form double rows, appearing like tortuous canals directly continuous with the biliary canals; and spaces containing cells which he believes to be dilated biliary ducts. Waldeyer† and Klebs‡ had previously described what must have been the same conditions, and have even ventured to interpret them as showing a regeneration of the hepatic parenchyma§ either from the biliary canals or from the hepatic cells. I must confess to thinking that Dr. Dreschfeld has done wisely in contenting himself with descriptions. The evidence of regeneration of the hepatic parenchyma is as yet but flimsy. And this is more particularly the case when we remember that very similar appearances are to be found in cirrhosis. It is true that in the latter disease new ducts are said to form, but at least one other interpretation of the appearances must be considered, viz., that if the anatomical description alluded to in the preliminary remarks be correct, and the epithelium of the biliary canals be continuous with the hepatic cells:—then if the hepatic cells do but dwindle in size they will come to resemble the smaller bile ducts; and under circumstances of atrophy of whatever kind in the portal zone, parallel lines of hepatic cells will be likely to appear, bearing the closest resemblance to the smaller hepatic ducts. This, I suspect, is so in many of the cases in which new ducts are found.

It need only be added that Waldeyer, Klebs, Eppinger,‖ and others have recorded cases of acute atrophy in which bacteria in large numbers have been found in the bile ducts; and it has been supposed that the disease may be produced by these bodies. But in the more recent researches by Coats and Dreschfeld no such organisms could be detected, and at present there is no sufficient evidence that they take any such active part as is by some assigned to them.

* P. 890, 891, figs. 305, 306.

* 'Journal of Anat. and Phys.,' vol. xv., p. 422.

† Virch. 'Arch.,' 43, 533.

‡ Klebs, 'Handbuch. d. Path. Anat.,' 421; 419, figs. 32, 33.

§ See also Thierfelder's 'Atlas der Pathologischen Histologie.' 3 Lieferung, Taf. xvi., fig. 7.

‖ For references, see Birch-Hirschfeld, *loc. cit.*, p. 938.

Before, however, concluding this *résumé* of the morbid anatomy of acute atrophy, it is necessary to call attention to the changes which have been found in other organs, and which form no unimportant element in determining the pathology of the affection.

The more salient are ecchymoses in various parts of the body; fatty degeneration of the muscular wall of the heart, and probably of other muscles also; enlargement of the spleen, which appears to occur in about two-thirds of the cases; and various other occasional conditions, such as swelling of the mesenteric glands, and changes in the vessels of the brain. But most important of all is the condition of the kidney: this organ is found in a state of acute catarrh; it is jaundiced and swollen, the section of the cortex being broadened, opaque, and without its natural striation; and under the microscope the tubules are found full of fatty epithelium.

Summary. — Acute atrophy of the liver is characterised in the first instance by cloudy swelling and fatty degeneration of the hepatic cells; by more or less migration of leucocytes; and by other evidences of blood stasis round the vessels of the portal channels, and in the capillaries of the lobules. If the patient should succumb at this time, the liver is liable to be large and to present a more or less uniform yellow appearance. When life is prolonged, red material makes its appearance, and the liver is then characterised by a firmer consistence, more irregularity of surface, and the general aspect of the whole organ is more mottled. This stage is denoted microscopically by more entire destruction of the hepatic cells; by increase of the connective tissue in the portal canals, and indeed through the entire lobule; and by the appearance of biliary canals in excess at the circumference of many.

Avoiding excessive detail, which is not called for here, the foregoing account represents all that is material to the pathology of acute yellow atrophy as at present known, and the data upon which it is discussed. There are indeed other exceptional cases which must not be altogether overlooked, but they will receive mention only in so far as they seem to bear upon special points in the pathology.

Pathology.—The principal facts of the histology of acute atrophy are not in dispute. It is not contested that the hepatic cells undergo an acute fatty degeneration in the yellow parts; nor that in the red atrophy there is an increase of the stroma, of cell infiltration, and still more complete disappearance of the gland cells.

The points open to question are: whether a process of cell proliferation precedes the fatty degeneration; whether the disease is inflammatory or not; whether the yellow and the red changes are distinct from each other, or only stages of one process; and, most recent of all, whether bacteria have anything to do with the production of the disease.

It is no new proposition that the disease is inflammatory, but this has only of late years been re-asserted upon grounds that histologists of the present day consider reasonable. The theory first enunciated by Bright,* and subsequently by Frerichs and others, is, that an acute diffused inflammation of the liver occurs—an acute parenchymatous hepatitis. But, as MM. Cornil and Ranvier point out, such a use of the word hepatitis has little to justify it. It is in fact the substitution of a vague term for the well understood description, "cloudy swelling." Early inflammatory affections of glandular organs are, no doubt, very commonly attended by cloudy swelling of their epithelium or glandular cells, but so are many other conditions of blood-poisoning, fever, &c., in which we should certainly gain nothing by calling them inflammatory.

But by this time observations have sufficiently accumulated to show—1. That yellow atrophy and red atrophy are generally associated in the same organ. 2. That in very acute cases the liver may be yellow throughout. 3. That in the more chronic cases the *red* tissue is likely to be in excess. And if these be the facts of the case there is much ground for the now very general opinion that the red tissue represents the more advanced disease. Klebs considers that the two tissues are distinct, but the fact that they are so generally associated in the same organ, and that those cases which show more of the red material have been of some weeks' duration, is sufficient ground for the opposite opinion now in favour, that they represent two stages of one disease—the red a late, the yellow an early stage. And this statement of the facts carries with it an answer to the much-disputed question—Is the connective tissue increased in these cases? And it is this: acute atrophy is a disease of two stages, a yellow and a red. In the former, or the early stage, the increase of connective tissue, though not absent, is unimportant; in the latter it is generally

* 'Guy's Hospital Reports,' 1836, vol. i., p. 621.

well marked. This, I think, accords with the experience of most observers,* but it does not exclude the occasional occurrence of apparent or actual increase of connective tissue in cases which seem to the naked eye to be pure yellow atrophy. In the first place, rapid changes such as this are only too likely to lead to extravasations of leucocytes, &c., a condition which must be eliminated before we consider the question of proliferation of the connective tissue; and secondly, a certain proportion of cases of yellow atrophy ensue no doubt upon conditions of the vascular system (such as pregnancy) which are well known to favour connective tissue overgrowth.† At any rate it is certain that, taking a number of cases examined by competent observers, in some proliferating connective tissue has been found, in others none.‡ And I see no more reasonable explanation of the fact than that given by Dr. Wickham Legg,—"that the difference between observers may arise from the varying length of time which the disease has lasted."

Winiwarter has been repeatedly quoted as in favour of connective tissue proliferation, even in acute cases; and it is his opinion that the fatty changes are consecutive to it;§ but I am disposed to look upon his case as an exceptional one. It was no doubt very acute, death having occurred in twenty-four hours; and on microscopical examination the hepatic cells were undergoing multiplication and forming connective tissue; but in face of the much more numerous observations which tell in favour of the conclusion stated above, it may be held to illustrate an interesting exception, not the rule. And I would the more insist upon this because I have in my possession slides which, more than any others I have seen, correspond with Winiwarter's description of his case (Fasc. IV., Pl. xxii., fig. 1).

A female child, 23 months old, was brought to the Evelina Hospital for Children as an outpatient on February 24th, 1880. Her parents were healthy, and there was no evidence of syphilis either in them or their children. The child had been languid, peevish, and slightly jaundiced for about a week; the bowels confined, motions light, urine dark. When I saw it, it was brightly yellow all over, the liver large and hard, extending nearly to the umbilicus. Regarding it as a case of catarrhal jaundice,—though remarking at the time it was a disease not common at that time of life,—I gave it some rhubarb mixture, with bicarbonate of potash, and sent it home. It remained much in the same state till February 28th, when it appeared feverish, and vomited repeatedly a yellow fluid. It was admitted under my colleague, Dr. Baxter, the next day. There was nothing to call attention to the child, except the universal jaundice and the enlargement of the liver, which now extended half-way to the umbilicus, its edge being thick and hard. The child was remarkably well-nourished, and not feverish. She brought up bloody fluid three or four times without retching during the night, and died at 10 a.m. the next day, after being convulsed for two hours, the temperature rising to 102°.

Dr. Baxter thus writes of the inspection, thirty-six hours after death:—

Body remarkably plump, with much subcutaneous fat. Skin and internal viscera deeply jaundiced.

Brain, 2 lbs. 10 oz. No abnormality.

Thorax.—Lungs congested at bases. Pharynx, larynx, trachea, healthy.

Heart of normal consistency, its fleshy walls somewhat pale; right ventricle dilated and flaccid; left ventricle contracted. No signs of inflammation; no ecchymoses. Under microscope muscular tissue of ventricular walls extensively fatty, not uniformly so, however; fibres with normal striation lying side by side with others, in which the striæ were completely masked by oil granules.

Abdomen.—Liver large, hard, with rounded edge, 14 ozs.; remarkably mottled, large portions of its substance being of a dirty yellow hue, while other parts were of a livid purple: these passed gradually into each other. No softening of the hepatic tissue anywhere. The liver cells were extensively fatty. Cystic duct obliterated (congenitally ?). Gall bladder full of bile-stained mucus. Hepatic ducts pervious and empty.

Pancreas healthy. *Spleen* rather large and dark, firm, 2¼ ozs.

Kidneys.—Apparently healthy; cortex pale. Under the microscope the convoluted tubes of the cortex were full of oil. Urine drawn from bladder was bile-stained, non-albuminous, depositing vesical epithelium and aggregates of rounded granules of bright yellow colour. No

* Riess, 'Charité Annalen,' 1865, Bd. xii., Heft. ii., p. 122. See also Wickham Legg, *loc. cit.*, p. 510.

† I might cite, as an instance, the puerperal osteophytes of Rokitansky.

‡ Wickham Legg, *l. c.*, p. 510. Dreschfeld, *l. c.*

§ 'Wien Med. Jahrb.,' 1872, p. 256.

leucin or tyrosin found in this or in the hepatic tissue.

Intestine. — Peyers patches peculiar; they were all of a dull purple hue, and distinctly elevated; all in similar condition; no ulceration; no peritonitis. Large intestine healthy.

Summary. — Jaundice, with enlarged liver. Fatty changes in liver, kidneys, and heart. Congestion and swelling of Peyers patches.

The liver, after hardening, showed very unusual, and to me new, appearances under the microscope. The section was crowded with nuclei, which studded a small meshed connective tissue. The hepatic cells were clumped in masses between this new growth (Pl. 22, fig. 1), and were greatly diminished in number; many of them contained fat globules, but their nuclei were for the most part distinct, though they often appeared increased in number; no connection could be traced between them and the nucleated tissues outside them. The lobules were affected throughout with remarkable uniformity from periphery to centre, although in some parts there was some slight excess of growth in the portal area; but the smaller hepatic ducts, which so often constitute a feature of cirrhosis, were conspicuously absent.

Now this case, except it be allied to those of Winiwarter and others, is outside our experience of the ordinary changes in the liver; it certainly presents quite different appearances from any that I have seen in acute yellow atrophy or in poisoning by phosphorus, and I have carefully compared it with the one condition and the other. It might be considered to be either acute diffused proliferation of the hepatic cells or of the capillaries and connective tissue outside them; but such a condition is on the whole more consonant with the changes recognised as cirrhotic than with those which have been repeatedly found with acute atrophy. Dr. Wickham Legg, who kindly examined a specimen of this liver, agrees with me that it is cirrhotic rather than atrophic. If we are to call cases of so exceptional a nature acute atrophy, for the reason that they in common with other cases present the clinical picture of icterus gravis, and because atrophy of the hepatic cells plays some part in the morbid changes, then there is much to be said for the contention of Klebs—that the red and yellow atrophy should be considered as distinct diseases. Already pathologists occupy the anomalous position of having to include yellow and red changes under the common term yellow; and under atrophy, livers that are large as well as those that are small: we shall not improve matters by further extending the limits of this particular disease to more varied microscopical changes than those already described, until there is more ground for so doing than exists at present. For my own part, I am disposed to think that the changes in acute atrophy are sufficiently characteristic to make it likely that the exceptional cases are not of that nature, whatever the symptoms may be.

In saying this I am fully alive to the difficulties which beset those who would always draw a sharp line between acute atrophy and cirrhosis. The one may be subacute or chronic, the other diffused and acute; and each under such circumstances will tend towards taking on the features of the other. Acute processes, whatever their nature, will always be associated with more or less atrophy of the secreting cells; chronic processes, on the other hand, will hardly fail to show those interstitial changes which, for the sake of brevity, we may call cirrhotic. But atrophy and cirrhosis are nevertheless distinct. From this it will appear that I think the evidence is but little, that acute atrophy is in the first instance a rapid proliferation of the connective tissue (Winiwarter), or of the hepatic cells (Levitski and Brodowski) *—in other words, that it is an acute cirrhosis; and, if so, then the second ground upon which was based its inflammatory origin comes to nothing, and we fall back upon the conclusion—the only one apparently that is open to us—that the disease is at the onset what it has always been thought to be by many, viz., an acute fatty degeneration. But there is still this further question to be considered—What is the nature of this fatty change if it be not inflammatory? Many hypotheses have been advanced for its solution. It has been said that the changes are due to some sudden disturbance of the nutrition of the hepatic cells; that nervous influence, or the arrest of it, has been at fault; that the disease is due to obstruction of the bile ducts; and so on. These opinions are all fully considered in Dr. Wickham Legg's exhaustive work,† and cannot be taken up now. It will be enough to say that the opinion most generally accepted at the present day is this:—Acute atrophy is due to some condition (probably a blood poison) introduced from without. What

* Vir. Arch., 70, p. 121.

† *Loc. cit.*, p. 518.

this poison may be, we as yet know not. Bacteria have been found in the various biliary passages in some cases, but the observations are too isolated to be of value, and, as I have already stated, there are negative facts to counterbalance them. Nevertheless the argument in favour of a blood poison rests upon firm ground: other organs, notably the kidney, and heart and voluntary muscles, suffer in the same way as the liver, though not perhaps to similar extent; diseases certainly due to external influences, such as typhus fever, typhoid fever, and septicæmia are associated with like changes in the viscera; and a form of icterus gravis with somewhat similar visceral lesions is directly produced by the introduction into the economy of excessive doses of phosphorus, alcohol, and other foreign substances, such as arsenic and antimony. Etiological considerations do but strengthen this opinion, for they also, many of them, go to show that external conditions, either septic or miasmatic, keep oftentimes close company with it.

As regards the nature of the jaundice, many have been disposed to hold that it is hæmatogenous; but of late it has been shown that in all parenchymatous degenerations of the liver the smaller bile ducts are liable to become blocked by their epithelial contents; and it is held by many that an obstruction is thereby produced equivalent to the production of jaundice.

Acute yellow atrophy occurs, as a secondary occurrence, as an occasional termination of cases of cirrhosis and of prolonged obstruction of the ducts.*

The microscope is in most cases necessary, not for its detection, but to establish its presence with certainty; because in cirrhosis particularly there is a tendency to the formation of lobular accumulations of bile-stained fat which may closely resemble the soft yellow fatty degeneration of acute yellow atrophy.†

Phosphorus poisoning.

Phosphorus, like acute atrophy, produces a parenchymatous degeneration of the hepatic cells. The liver is usually large, of a uniform lemon-yellow or brightly-jaundiced tint (Pl. xviii., fig. 1); it is firm in consistence, and greasy like lard on section. It has all the macroscopic characteristics, which acute yellow atrophy has not, of an extreme fatty infiltration of the liver. Under the microscope the hepatic cells are cloudy and ill-defined in their outlines, full of granules and drops of oil; or in the most advanced parts have entirely disappeared. So far, the minute changes resemble those of acute atrophy. But in the one case which serves me for description,* and for which I am indebted to the kindness of Dr. Capon, the nuclei of the cells appear to have resisted the morbid changes more than the body of the cell and than is usually the case in acute atrophy. The minute bile ducts become plugged with mucus and epithelium, and sometimes contain retained bile†; and the small vessels and capillaries are said to undergo fatty changes. The connective tissue of Glissons capsule is said to be increased, and changes resembling early cirrhosis to be produced in consequence. But I shall confine myself to the statement that the portal canals—large, medium-sized, and small—are everywhere crowded with abnormal cells or nuclei. These I believe to be mostly due to emigration of corpuscles from the blood vessels, because of their uniformity of size; the absence of definite connection with the portal connective tissue; and some would certainly add, from the entire absence of anything like activity of growth on the part of the hepatic cells at the circumference of the lobules. These are the main points to be noted in the liver. In the other organs there is a fatty change in the glands of the stomach and intestine, kidneys, muscular structure of heart, &c., similar to that which occurs in acute atrophy.

Most foreign writers at the present day consider that phosphorus produces a form of acute yellow atrophy. Winiwarter has indeed attempted to distinguish between the two diseases on the ground that in the one he finds evidence of interstitial inflammation (acute atrophy), in the other (phosphorus poisoning) none. But this distinction is untenable, first, because Wegner‡ has been able to produce, by experimenting with phosphorus on animals (dogs,

* Frerichs, *op. cit.*, vol. i., p. 237. Murchison, 'Trans. Path. Soc., vol. 22, p. 159.

† For a *résumé* of cases of this kind, both in cirrhosis and chronic obstruction of the ducts, see Thierfelder. Ziemssen's 'Cyclop.,' vol. ix., p. 245, 6.

* A more detailed report of the microscopical appearances in this case will be found in an Appendix, and the case is published in the 'Lancet' of March 18th, 1882, under heading, "A recent case of Suicide," by H. J. Capon, M.D.

† Thierfelder, *op cit.*, Taf. xv., figs. 5, 5 *a*.

‡ Virch., 'Arch., Bd. 55. p. 18, Plate iii., fig, 1.

rabbits, &c.), the several stages of cirrhosis, and even a "granular" liver (see fig. 1 of his three plates, where an extreme degree of cirrhosis in a rabbit appears to have been produced by four months' treatment); secondly, because in specimens already quoted,—and from what others have recorded, the case is no exceptional one,—there are appearances which some would doubtless interpret as an indication of an interstitial inflammation. But I am not disposed to give an unqualified adhesion to the view that the liver of acute yellow atrophy and the diseased liver produced by phosphorus poisoning are alike. Many conditions produce parenchymatous degenerations of the tissues, some acute, some chronic; and all such must necessarily more or less resemble each other, seeing that the possible changes—so far as we know them in such organs as the liver—are limited. But there are nevertheless important distinctions in the majority of cases, which must count for something; these are—(1) that the liver of phosphorus poisoning is a large one, that of acute atrophy usually small; (2) that the one is firm, the other flabby; (3) that the one is uniform in section and colour, like a jaundiced fatty liver, and greasy in addition; the other is irregular, lobulated, mottled. And these distinctions are true for the great majority of cases, because the great majority of those who poison themselves with phosphorus die within a week or two of the introduction of the poison into the system. But supposing that in an exceptional case the process is more chronic: then, remembering the results that have been obtained by Wegner upon animals, remembering also that all chronic degenerative processes carry in their train secondary inflammatory changes, it is not unlikely that the appearances may be modified and the liver become small, irregular, or mottled, such as that of acute atrophy. Dr. Wickham Legg, after remarking that the disease of the liver in poisoning by phosphorus may take two forms,—one in which the cells only are attacked, the other in which the cells degenerate and the connective tissue increases, and that the difference is probably only a question of time,—goes on to say,* "The effects of phosphorus closely resemble those of alcohol; an acute poisoning by alcohol causes a granular or fatty infiltration of the liver; a chronic poisoning a cirrhosis." I believe this parallel to be a just one. Yet it is but seldom that any difficulty can be felt in distinguishing between the liver of the one condition and the other. As far as the ultimate lesion of the hepatic cells is concerned, the effects of all poisons acting upon them are similar, but the *tout ensemble* of the diseased viscus is usually distinct for each. And as regards the histological details, although I apprehend no English observer is in a position to speak authoritatively upon what must necessarily be a limited experience, yet I would venture to insist upon what is, I think, an important distinction between the two diseases: that whereas in acute yellow atrophy microscopical sections of the affected parts of the liver have passed beyond recognition, so that if put before one who knew nothing of their antecedents, he could not say whence they came, in phosphorus poisoning the obliteration of the natural structure is by no means so extensive. In Dr. Capon's case, already alluded to, where death ensued in eight days,* the normal anatomical arrangement is everywhere perfectly distinct. The hepatic cells are very cloudy and ill-defined in outline, full of small granules, and even drops of oil; but they still occupy their places in columns, and are properly related to the intra- and inter-lobular veins; and even when—as happens by no means unfrequently—the cells have disappeared entirely, the lobulated arrangement is still preserved, although only the skeleton of its former self. This is not so in any one of four cases of acute atrophy of which I possess slides. Therefore the histological appearances in a measure correspond with those which are apparent to the eye, viz., the one is rather a fatty infiltration, the other a fatty degeneration. With regard, however, to the question of interstitial inflammation, although I do not myself attach that meaning to it, one of the cases of acute atrophy closely resembles the case of phosphorus poisoning in the free presence of numbers of cell elements in the portal canals. But in both cases these partake, I should say, more of the nature of what have of late years been described as miliary abscesses.

I would also add that similar changes are probably not uncommon, and are provoked by varied causes. I am in possession of a slide prepared by my colleague, Mr. W. H. A. Jacobson, Demonstrator of Morbid Histology at Guy's Hospital, taken from a child who died

* *Op. cit.*, p. 573.

* 'Lancet.'

from a burn, and whose liver was large and fatty. The outlines of the liver cells are intact, and the nuclei are perfect; but many of the cells are reticulated throughout by fat globules, and the sections of the portal canals show a similar abnormal nucleation to that in the cases just referred to.

I shall not further deal with the liver of acute alcohol poisoning, or with those rarer cases of mineral poisoning (arsenical and antimonial), with yellow fever and the like. It may be taken that they are all parenchymatous degenerations more or less corresponding with the two more accurately investigated conditions with which we have dealt in detail.

The Fatty Liver.

(Pl. xviii., fig. 1; xx., figs. 2, 3; xxi., fig. 13).

Fat being a normal constituent of the healthy liver, there are many degrees of "the fatty liver," but they are not usually designated as morbid until certain changes of shape and consistence are produced. The fatty liver is large, of a pale buff-colour, soft in consistence, easily lacerable, and with the naturally sharp anterior border rounded by distension of the glandular elements within the capsule. More minutely, the lobulation is distinct, and often there is some mottling, the outer parts of the lobules—in which the fat tends to be deposited in excess—being pale; the central parts red, from the absence of fat and the presence of blood (peripheral fat infiltration). In extreme cases the fat is spread through the entire lobule, and the colour is then uniformly buff (total fat infiltration). It may be remarked, in passing, that the contrast so often seen between the outer and inner parts of the lobules, while it presents resemblances to, indeed is a slight grade of, the change soon to be described as the nutmeg liver, is an evidence that fat in excess produces anœmia of the organ, and from it we may conclude that the fatty liver will be sluggish in function. It is further to be noted that as an occasional circumstance the pattern of the lobulation is rearranged, and, instead of a foliated buff pattern with central red parts, a dark red ground becomes dotted over with small yellow spots, which are due to fatty changes in the hepatic cells round the central vein (central fat infiltration).* This condition would appear by common consent to be present most often during pregnancy and lactation—for the special purpose, according to MM. Cornil and Ranvier,* of supplying the fat readily to the blood; but more probably, as is suggested by Klebs, because the drain upon the fat supplies is then excessive, and the portal areas are rapidly cleared of their surplus stores. This condition, then, is one in which the fat happens to be caught at its vanishing point, and before the portal areas have had time to replenish themselves. By the presence of fat in excess in the liver the specific gravity of the organ is altered, and it floats in water; and often, if a small portion be held in the flame of a spirit-lamp till the water which it contains is driven off, it will burn. But the best test of the presence of fat is the microscope. According to the amount present, so the hepatic cells at the circumference only, or more or less all through the lobule become filled with globules of oil of various sizes, or distended by one large globule, the nucleus being displaced to the side and the periplast forming an albuminous envelope or cyst. The microscopic features of such a liver are not unlike a piece of adipose connective tissue.

The fatty liver is found under varied circumstances—it is particularly frequent with phthisis, with many emaciating diseases, and in those who have been long bedridden. It is also not uncommonly associated with cirrhosis, and in people who, dying from other causes, have been "living well." But as a cause of death, or even of harm, it has not attracted much attention among pathologists; for although it often becomes a question in the post-mortem room how far it may have conduced to this end, yet a certain quantity of fat being necessary to the full function of the liver, and there being good evidence that even large excesses are capable of rapid resorption, it has not been considered to be a morbid state of much importance. But if late observations are to be trusted, the pathology of the subject may yet enter upon new phases. Under certain conditions not yet by any means fully ascertained, but particularly in diabetes† and after injuries to the organ, the blood appears to become overcharged with fatty matter, and the smaller branches of the pulmonary artery, renal and other vessels to become plugged by it. It is of course quite conceivable that oily

* Klebs, *op. cit.*, p. 382.

* 'Manual d'Histologie,' 928, fig. 312.

† Lipæmia and Fat Embolism in the fatal Dyspnæa and Coma of Diabetes, Sanders and Hamilton, 'Ed. Med. Journal,' vol. xxv., p. 47.

material contained in an organ might by severe pressure be forced into its veins; and, if fat embolism is as much a reality as it claims to be, by passing into the right heart and the pulmonary capillaries it might produce results detrimental to the proper aëration of the blood; but it is not so easy to understand why, in such a disease as diabetes, where the liver is by no means remarkable for an abnormal quantity of fat, such a crisis should suddenly occur. Drs. Sanders and Hamilton,* however, do not suggest that the fat plugs come from the liver: they merely record the association of diabetes with fat embolism, whatever its meaning.

Pathology.—By way of summary, it may be said that a certain amount of fat forms one of the constituent elements of the healthy liver. When this passes beyond some limit, which it is quite impossible to define, the excess of fat becomes a disease, although it does not produce any definite symptoms of its existence by any recognisable perversion of the function of the organ. Moreover, although in the majority of cases fatty infiltration is sufficiently distinct from fatty degeneration, these two are not to be separated from each other by any fast line; but under some circumstances, of which phosphorus poisoning forms one of the best examples, simple infiltration is associated with degeneration.

Lardaceous Disease.
(Pl. xv., figs. 1, 2; xx., figs. 1, 10).

The lardaceous liver is large, increased equally in all directions, its surface smooth, its edge sharp. It is somewhat doughy, and pits on firm pressure. The section is bloodless, peculiarly dry, and dull, tending rather to adhere to the knife; and in these respects is aptly compared to raw bacon—which in tint, in behaviour when cut, and when pressure is made upon it, it very much resembles.

The more minute appearances vary—according as the disease is more or less general and is associated or not with fatty infiltration. Lardaceous disease pure and simple converts the liver into a semitransparent greyish substance, not unlike boiled sago or starch. This, spread all through the liver, as is the case when the disease is extreme, produces characteristic reddish grey appearances. But the character is due to tint and transparency combined; and this combination is very difficult, if not impossible, to depict in a drawing. The red parts of Pl. xv., fig. 1, are intended to represent it. But the lardaceous material is often mixed with fat, and then the appearances alter. Most commonly the surface becomes speckled, the grey or red ground just described being streaked and dotted over with irregular angled lines of an opaque yellow granular substance—which, in anticipation of its histology, we may say is due to fatty infiltration of the non-lardaceous hepatic cells.* More rarely, the distribution of the fat is more diffused, and the reddish grey material then changes to a yellowish grey, still retaining, however, something of its former transparency (Pl. xv., fig. 2). Lardaceous disease, though generally diffused through the entire viscus, is not necessarily so; it sometimes attacks quite localised areas; and it has occasionally happened that patches of this kind have suffered some further fatty or calcareous metamorphosis, and have come to resemble infarctions or the gummata of syphilis.†

Lardaceous disease of the liver is very common: it is present in 50 per cent. of all cases of the disease; but the liver is not so frequently attacked as the kidney or the spleen, which suffer in the proportion of 70 and 66 per cent. respectively.

The slighter degrees of lardaceous disease cannot be distinguished without the use of reagents. These are, first and best, because always at hand and most quick in development, the iodine test: a watery solution of iodine containing a little iodide of potassium is poured upon the surface—the affected parts quickly become a deep mahogany-brown. 2ndly, a thin section may be cut and soaked in a 1 per cent. solution of methyl anilin violet, and then mounted in glycerine acidulated with acetic acid—the affected parts soak up the colour greedily and assume a reddish violet tint, which makes a pretty object and readily demonstrates

* This is a question which must remain for some time *sub judice*. The exact import of fat embolism from any source cannot be said as yet to be placed beyond doubt, as a morbid process; and with regard to diabetes, I have examined the lungs of two cases of diabetic coma without finding any fat embolism; and my colleague, Dr. Frederick Taylor, has been similarly unsuccessful.—"On the Fatal Termination of Diabetes" ('Guy's Hospital Reports,' 1880-81, p. 155).

* Dr. Ralfe, 'Path. Trans.,' vol. xxx., p. 356, considers that this fat has peculiar properties which constitute it part of the disease, and not a consecutive degeneration.

† Wilks and Moxon, *op. cit.*, p. 436. Fagge, 'Trans. Path. Soc.,' vol. 27, p. 329. Rindfleisch, *op. cit.*, vol. 2, p. 87.

the morbid changes. This test was first proposed by M. Cornil, and has more recently been advocated by Dr. Greenfield.*

Histology.—Here, as elsewhere, the disease is in the first place one of the small branches of the hepatic artery, and in its earliest stages is found to attack these exclusively. If a section of the liver be examined at this time—taking a transverse section of a lobule and dividing it into three imaginary zones, an internal or hepatic vein zone, an external or portal vein zone, and an intermediate or hepatic artery zone—the disease will be found to be confined to the last-named area. Not that one can usually see definite zones of this kind: it is more true to say that the lardaceous material exhibits an irregularity of distribution which is somewhat puzzling; but one thing is clear, viz., that the inter- and intra-lobular veins are for the most avoided. For the later stages a simple description of the microscopic appearances will suffice. I have nothing to add to what has already been said concerning the part played by the hepatic cells in the disease (p. 7). But as regards other structures, the coats of the minute arteries become swollen and blurred, and the capillaries also lose their distinctness of outline and become blended with material of similar appearance outside them. Thus, subject to the qualification already made, the entire middle zone becomes a confused deeply-stained mass; streaky, from some parts taking the colour more deeply, but not separable into distinct elements. Coincidently the hepatic cells in the portal zone are frequently found full of oil globules: those in the hepatic vein zone are atrophied or unaltered. The disease extends by the appearance in still unaltered parts of the lobule of masses of lardaceous matter; whether swollen vessels, capillaries, affected cells, or free lardacin, is really not a matter of much importance. Neighbouring masses gradually coalesce, the hepatic cells disappear, and nothing remains in the affected area save the lardaceous material and a delicate somewhat sparsely nucleated reticulum of connective tissue which intersects it in all directions. Further, it is not uncommon to find changes of a cirrhotic nature in the portal fissures. The reticulum of connective tissue just described must not be understood to be anything of this nature; it appears to be rather the original connective tissue of the organ which lasts longest, and thus is still visible when the glandular elements and the capillary vessels of the lobules have disappeared. But in examining hardened specimens it is not uncommon to find a closely-studded cell growth in the connective tissue of the portal canals, and even spaces full of epithelial cells, the nature and occurrence of which in cirrhosis have given rise to so much discussion of late. A cirrhotic process this may be called, but I may add that the hepatic cells have in all these cases seemed to me to be quite passive—a point to which I shall have to make further allusion in discussing the changes which take place in cirrhosis. Changes of this nature are by no means universal in lardaceous disease, but perhaps their presence is controlled by the extent of the lardaceous change. There is no doubt that this, if excessive, limits the supply of blood to the the liver very seriously,* and under such circumstances cell growth of all kinds would probably be checked. Whereas with a more partial distribution more latitude would be possible in this respect. The existence of any change of a cirrhotic nature is in any case of importance, because a correspondence is thus established with lardaceous disease as it is known to occur in the kidney, where interstitial inflammation is very commonly indeed ascociated with it. But I am not quite clear that in either case, syphilis—so common a cause of the degeneration—may not have something to do also in determining the presence or absence of inflammatory conditions. No doubt, as I have said before, all parenchymatous diseases of chronic nature tend towards chronic inflammatory processes; but in this case syphilitic influences must first be eliminated before we can hope to assign to lardaceous disease its true position as an originator of cirrhotic changes.

In making this statement with regard to the association of interstitial inflammation and lardaceous disease in the liver, it may seem that I hold a contrary opinion to some. I do indeed think that the frequency of cirrhotic changes in lardaceous livers is perhaps rather underrated, but there can be no doubt that the kidney is far more often and more severely affected in this way. I believe, with Dr. Fagge, that this difference is to be found in part in the different arrangements of the blood-supply to the organs; but it would

* "Discussion on Lardaceous Disease," 'Path. Trans.,' vol. xxx.

* Dr. Fagge has adduced this fact to explain the occurrence of the retrograde metamorphoses of lardaceous disease already alluded to. *Loc. cit.*, p. 329.

be strange if the secondary inflammatory changes which occur so often in the one should be entirely wanting in the other. The spleen is an organ of so peculiar a constitution and habit, as its well known resistance to any suppurative process proves, that it may be regarded as exceptional in this respect. It will not be out of place to remark here, as closely connected with the subject, that Dr. Dickinson, whose work at lardaceous degeneration is known to all, makes the interesting statement, which may be easily confirmed, that the liver recovers faster than the spleen, and the spleen than the kidney: an observation which is in conformity with the fact just stated—that the kidney is more affected by secondary inflammatory changes ('Path. Soc. Trans.,' vol. xxx., p. 546).

Lardaceous disease of the liver is found most frequently in association with prolonged suppuration; and with syphilis, either with or without suppuration. Dr. Charlewood Turner has brought forward some facts to show that tumours of various kinds are also associated with it; but this is not in accordance with the experience of most pathologists, if we except those cases in which either syphilis or suppuration has been present also.

DISEASES DUE TO CIRCULATORY DISTURBANCE.

The next group comprises cases which are chiefly dependent upon conditions of disturbed circulation other than those of pylephlebitis and portal thrombosis: œdema active and passive; congestion; and anæmia—states of passive congestion being far more important than the others.

Œdema.—Very little is known about this condition; it is mentioned by Birch-Hirschfeld as occurring in some cases of aortic disease, but I know no other author who considers it worthy of notice. I am unable to say definitely, with Birch-Hirschfeld, under what circumstances œdema is to be found; but I call attention to it because it is probably not uncommon, and it presents features which would make distinctions other than chemical ones difficult, between it and some of the changes that occur in the myxœdematous liver or in the albuminoid disease of rickets. The liver is large, elastic, and of an india-rubber-like consistence. The albuminoid liver of rickets, described first by Sir W. Jenner and subsequently more fully by Dr. Dickinson,* is paler than the normal liver. The œdematous liver is, I think, usually dark. Under the microscope the interstices of the organ are swollen and gelatinous, so that the fibrous tissue appears increased and the columns of cells are abnormally separated. These appearances are exactly represented in Dr. Sangster's drawing of a myxœdematous liver, figured by permission of Dr. Ord (Plate xxii., fig. 10). A good representation of the thickening which is to be found in the portal canals under a low power is given by Dr. Dickinson in the communication above referred to.

Hyperæmia, on the other hand, although from the standpoint of morbid anatomy it is less demonstrable than œdema, is fully described by many writers. It is supposed to occur, and probably does so, whenever a too-stimulant and excessive diet is indulged in—when any specific fever or severe pyrexia of any kind is present. Under certain climatic conditions and a great variety of other circumstances the liver rapidly swells from excessive blood-supply. It is naturally only a passing disturbance, but in many of the conditions enumerated is premonitory to the more serious disturbances of cloudy swelling and fatty degeneration of the hepatic cells, the morbid appearances of which have been already sufficiently described.

The Nutmeg Liver.

(Pl. xvi., fig. 2; pl. xxi., figs. 4 & 6).

We come next to a condition which in one or other of its several degrees has received a variety of names—passive congestion; mechanical hyperæmia (Green); red atrophy (Virchow and Rindfleisch); brown atrophy; cyanotic induration and atrophy (Klebs); the nutmeg liver. It is the only form of congestion which has much to characterise it as such after death. The last-mentioned name is to be preferred, because although the appearances are not always exactly the same, owing to the natural and considerable variation both in the extent and duration of the congestion which produces it, yet, as a central figure, all cases may be grouped around it.

The nutmeg liver and all its class are due to some impediment to the passage of blood from the hepatic veins, and therefore from the liver; consequently it is most frequently present in cases in which the pulmonary circulation is seriously hampered either by chronic bronchitis or disease of the mitral valve. In limiting ourselves to these, the common causes, it will not be forgotten that others may occasionally be present,

* 'Trans. of the Roy. Med. Chirg. Soc.,' vol. 52, p. 361.

such as cancerous or suppurative thrombi in the hepatic vein, or chronic inflammation about the capsule of the liver and the main branches of the hepatic vein (Frerichs, *op. cit.*, vol. ii., p. 432). Nor is it unimportant to bear in mind that the nutmeg appearance, being due to an excess of what in slighter measure are physiological conditions, will be found to be present in some degree under a great variety of circumstances (see, for instance, Pl. xvii., fig. 1, where it was associated with rather advanced cirrhosis).

General appearances.—In the early stages the liver is large and smooth, and indurated. Its section is on the whole dark reddish brown or claret-coloured, but close inspection determines the presence of islands of claret-colour surrounded by tracts of a brick-red. Plate xvii., fig. 1, although of unusual origin, well represents the extreme of this stage—that is to say, where the appearances of simple congestion are passing into the condition known as the nutmeg liver. In the later stages the liver is less markedly increased in size, but it is more irregular on its surface. The capsule shows opacities and small flocculent vegetations (Pl. xx., fig. 7), and the dark red becomes mottled with yellow. The irregularities of surface are not usually such as are seen in cirrhosis. The appearance is not that of a granular liver, nor indeed of any regular segmentation either into large or small lobules. The aspect is one of distortion rather than lobulation—a large area being slightly depressed in one part, an abnormal bulging visible at another; the condition being more comparable in its external appearance to the kidney in many cases of ascending nephritis—that is to say, of disease extending from the urinary passages to the glandular parts of the organ. The section is a mottled one (Pl. xvi., fig. 2)—opaque reddish yellow mingling with dark claret-coloured parts. Some authors describe the yellow as surrounding the red. Cornil and Ranvier, for instance, write thus*:—"If the section passes through the divisions of the sub-lobular vein, a foliated figure is seen—red branches surrounded by grey zones. If the section is made across the vein, regular circles are obtained with red centre and grey periphery." This is quite correct. Klebs, on the other hand, makes allusion to lighter parts *within* the *red*. The differences are merely questions of degree—the red parts being due to stasis and dilatation of the capillaries, beginning at the hepatic vein; the yellow to fatty infiltration of the hepatic cells in the portal area; the longer the duration of the case the more the dilatation and stasis in the capillaries, and the less the prominence of the fatty infiltration. So that it may happen that the red colour predominates and encircles the yellow, or, as Dr. Moxon writes of "ramose atrophy,"* a cavernous tissue may be produced by the extreme dilatation, which may destroy the nutmeg appearance altogether. It had not done so in the specimen which serves for illustration, but it had produced the irregularity of surface described by Dr. Moxon, which is due to the shrinking of the cavernous tissue; and it also showed another characteristic not uncommon—that the changes are unequally distributed through the organ. In some places, the fat having accumulated to excess, a bulging lobulated yellow part is seen; at other parts the dark depressed cavernous areas predominate.

Occasionally extravasations of blood of such considerable size occur in the substance of the liver as to have received the name of hepatic apoplexy. Such extravasations of blood are by no means common, and would appear to be more often due to severe diseases of the blood—such as scurvy, or yellow fever; or to vascular growths or diseases of the coats of the vessels (Frerichs, *op. cit.*, vol. i., p. 383. Thierfelder, 'Zeimssen's Cycl.,' vol. ix., p. 83).

Histology (Plate xxi., figs. 4, 6).—In the uncomplicated forms this is a simple matter. The blood in the liver is prevented from passing out of the hepatic veins, and certain changes naturally follow. These are:—dilatation of the intralobular veins; dilatation of the capillary veins which contribute to them; distension of these by blood (Pl. xxi., fig. 4 *a*, *bbb*); atrophy of the hepatic cells in the corresponding part of the lobule (hepatic vein zone, *bbb*); deposit of pigment in the cells and connective tissue (*cc*) (hence the term brown atrophy); and gradual accumulation of fat in the hepatic cells of the portal zone. All other changes are due to the prolongation of the congestion, and may therefore be said to be secondary. Of these we may first of all note, as most common, a hyaline thickening (swelling or œdema) of the intralobular branches of the hepatic veins; and probably of similar nature is an œdematous-looking swelling of the stroma intervening between the hepatic cells. In health, any definite stroma is hard to detect:

* *Op. cit.*, p. 883.

* Wilks and Moxon, p. 432.

but in this and other conditions also it becomes thickened and well marked. Cornil and Ranvier make use of the term sclerosis; and Klebs it is, I think, who suggests with much probability that the appearances are due to the coalescence and obliteration of the minute lymphatics, and probably of other channels as well. This change is quite different from a cirrhotic one. Some authors have contended for a process of cell proliferation round the hepatic veins in the centre of the lobule—a cirrhosis of hepatic vein origin corresponding to that of portal origin. I have never seen anything of the kind worth the name. Sometimes, indeed, in the coat of the thickened central vein the nuclei in the walls may appear rather numerous. The hepatic cells, owing probably to the irregular pressure to which they are subjected, become very small in some parts, and thus some sections appear to be over nucleated. But I agree with MM. Cornil and Ranvier,* that anything deserving of the name cirrhosis starting in the region of the intralobular veins must be rare indeed. Extreme and prolonged obstruction to the hepatic veins does not threaten this. As a matter of fact, the dilatation of the capillaries gradually extends backwards to the portal zone, and in so doing leads to atrophy of the hepatic cells in that region, just as it has already done to those in the hepatic zone; it may then produce an œdematous state of Glissons capsule, and oftentimes a certain amount of nuclear growth visible as islands between the hepatic lobules; and it may no doubt, though not very commonly, lead on to a *portal* cirrhosis of considerable extent. I am in possession of slides which demonstrate this (Plate xxi., fig. 6); but naturally such an extreme change is uncommon because the cardiac and pulmonary troubles which cause it will in the majority of cases lead to death in other ways, and at an earlier date than would allow of its production.

Anæmia.

(Pl. xxi., figs. 8, 15).

Klebs, in his Handbook,† makes mention of a second form of atrophy—due not to hindrance of the blood passing from, but to arrest of blood going to, the liver. It is not often met with. Isolated patches of atrophy may occur in association with localised cirrhotic changes spreading from the coats of the branches of an atheromatous hepatic artery. It is conceivable that, under exceptional circumstances, obstruction to the main trunk of the hepatic artery—aneurismal or otherwise—might lead to disease, although hitherto in the few cases of the kind scattered over medical literature it does not appear to have done so; or as occasionally happens in the analogous case of the lung with its double circulation by means of the pulmonary and bronchial arteries, sudden obstruction to the portal vein might engender some necrobiotic change: but here again the experience gained up to the present time does not warrant us in saying that the possible actually occurs. For in the many such cases recorded the liver has appeared quite healthy, and in the few it has presented a lobulated appearance; and the minute changes were not those of an acute atrophy, but of cirrhosis.* But I have once met with peculiar conditions in a case of idiopathic anæmia (Pl. xxi., Figs. 8, 15) which deserve to be recorded—not because they are exceptional, though this they certainly are, but because they conform to Klebs's description of the alternative conditions which may produce his second form of vascular atrophy, viz., decrease and impoverishment of the blood. Moreover, Dr. Sydney Coupland, in his Gulstonian Lectures,† alludes to a case (Case 5), in which he observed remarkable conditions which were in all probability of similar nature; and he has kindly examined my slides, and believes them to exhibit the same appearances. The change is one of atrophy and fatty degeneration of the hepatic cells, but the atrophy distinctly avoids the portal zones,—where the cells are in all cases in good condition,—and attacks the arterial zone and the hepatic zone. In these parts the cells have for the most part disappeared, leaving a thickened hyaline trabecular stroma, with numerous masses of pigment entangled in its meshes.‡ More minute examination enables one to determine that the smaller, and therefore probably the earlier, patches, are most of them situated about midway between portal and hepatic veins, or rather nearer to the latter; that these parts are, quite as much as the more advanced ones, well supplied by large pigmented cells; and that the liver cells round the central vein are fatty. I think one might even say that the deposition of pigment precedes the atrophy, so many of

* *Op. cit.*, p. 885.

† *Op. cit.*, p. 424.

* Frerichs, *op. cit.*, p. 396.

† 'Lancet,' vol. i., 1881, p. 690.

‡ Pl. xxi., figs. 8, 15.

the hepatic cells contain an excess of pigment while yet apparently in an otherwise healthy condition. Lastly, the spaces in the network of thickened stroma prove to be in most cases dilated capillaries full of blood.

This condition must not be considered a common one: it has occurred to me once only in four cases. Dr. Coupland has seen it once. On the whole it would seem most probable that it is one of the secondary degenerations which affect the heart, vessels, and gland cells in this disease; but the preference for the arterial zone of the lobules is of great interest, because it affords evidence of an alteration of structure which it may be presumed is directly dependant upon the existing anæmia.

DISEASES OF INFLAMMATORY NATURE.

This group comprises—Capsulitis or Perihepatitis; Abscess; and Cirrhosis; including that form of interstitial hepatitis which is of syphilitic origin.

Perihepatitis

may exist as firm fibrocellular adhesions between the liver and surrounding parts, particularly the diaphragm; as flocculent vegetations growing from the peritoneal coat; as diffused opacities on various parts of the surface; or as a general condition of the superficies.

Adhesions between the liver and diaphragm are found under all sorts of circumstances, and have no special indication in hepatic pathology. They are often associated, for instance, with evidences of old and severe pleurisy. But perhaps they are more liable to be present in the fissured pseudo-lobulated liver of old syphilis (Pl. xiii.) than in other diseases. Many cases of cirrhosis are also associated with diaphragmatic adhesions. The flocculent vegetations have already been alluded to as part of the appearances found in chronic congestion. The capsule in these cases is usually rather opaque, from a general increase of its thickness, and the surface is more or less shaggy, from the presence of the vegetations. They are subperitoneal growths of fibrous tissue (Pl. 20, fig. 7), and are said by Dr. Moxon to be analogous to the Pacchionian bodies found along the longitudinal sinus in the brain, and like them to be non-vascular. There is no doubt that this view of their nature is essentially correct. Whether they contain vessels or not is an unimportant matter; but I am of opinion that they much more often contain vessels than has been thought, and in this I am in agreement with MM. Cornil and Ranvier*; a vessel is seen in the figure given. They are mostly found in cases of chronic pulmonary congestion and heart disease, but are also present in some cases of cirrhosis.

In the localised and diffused thickenings the changes only differ in degree, not in kind. The thickening is peculiar, being bluish or milky-white in colour, and having studded over it numerous small depressions which are circular in shape, have a sharply-defined edge, and look much like ulcers. They are evidently not of that nature, however, from the fact that all are perfectly uniform in appearance, and that their edges, though well defined, are always quite smooth. Dr. Moxon* states that these are gaps which the new tissue has torn in itself during contraction, and I have occasionally seen appearances which confirm this opinion; but whether it is always so or not I cannot say.

This condition is found in its most typical form as part of a chronic peritonitis, and the liver is liable to undergo characteristic distortion. In chronic pleurisy and hydrothorax the lung is well known to lose its natural shape, and to assume more or less of a spherical form. If the thickened pleura be removed and the lung inflated, the alteration is found to be due to the doubling over of the thin edges of the lung, and to partial collapse; and this is produced by the gradual contraction of the pleural jacket. Precisely the same process goes on in the diffused form of perihepatitis: the thin edges of the liver become doubled over, and the organ tends to assume a cylindrical or globular form. The liver in this way becomes much compressed; its circulation is obstructed, perhaps more so than in any other disease of the liver; it becomes anæmic; and the hepatic cells undergo atrophy. Primary perihepatitis is not usually associated with cirrhotic changes. The substance of the organ when the interior is examined is soft and natural. But it occasionally happens that it is associated with a cirrhosis of peculiar distribution, the liver being fissured and scarred in various directions; and this has been attributed by some to a secondary extension of the inflammatory growth from the capsule to the substance of the organ; and it may be so. On the other hand, I should

* *Op. cit.*, p. 916.

* *Op. cit.*, p. 449.

be disposed to say that in such cases the capsulitis is not *general*, but is characterised by localised thickenings; and such localised conditions are very suggestive of bygone syphilis. But syphilis is known to produce changes in the liver also, such as are here ascribed to in-growth from the capsule, and to my mind it is their better interpreter. There is, however, a secondary perihepatitis, due to cirrhosis. It is not uncommon to find in the latter that islands of cell growth establish themselves in the liver substance immediately beneath the capsule; and the surface is then liable not only to become thickened, but also puckered into deep sinuous foldings from the contracting disease beneath.

The chief causes of perihepatitis are the chronic peritonitis of Bright's disease, chronic alcoholism, and syphilis.

Hepatic Abscess.
(Pl. xxiv., fig. 1).

I pass by any other form of acute inflammation because—excepting conditions such as acute yellow atrophy, the questionable nature of which has already been discussed—no other form is known than suppurative hepatitis.* Under certain circumstances, such as a tropical climate or miasmatic influences, acute swelling takes place; and this, the pre-suppurative stage of tropical abscess,—if there be such a condition distinct from the abscess of dysentery and pylephlebitis,—can hardly be other than an acute inflammation.† Threatening abscesses not seldom stop short of the suppurative stage, but we have no knowledge of the histological changes which characterise such swellings of the liver; we can only apply the general doctrines of inflammation to the particular case, or do as others have done before, viz., describe as an acute parenchymatous hepatitis such changes as are to be found in acute yellow atrophy and allied diseases.

The only acute inflammation of which we have certain knowledge is the suppurative one. Hepatic abscess may be single or multiple, and is more prone to occur in the right lobe. Solitary abscesses may attain an enormous size; multiple abscesses are usually small (Plate xxiv., fig. 1), but if—as sometimes happens—they are richly distributed through the liver, one large cavity may be formed by the coalescence of several of smaller size. Their contents are usually thick, greenish, non-offensive pus, but the colour of the pus is liable to variation, according as bile is present in it or not. Their walls also show considerable variety of appearance: they are usually lined by a granular layer of semi-coagulated pus, and composed of slightly indurated hepatic tissue, or—in the case of the smaller abscesses—of the thickened coats of some small vein. But coinciding with the well-known fact that abscesses of the liver may be very acute or very chronic, there may be a shreddy gangrenous cavity without definite wall or tough fibrous tissue of great thickness, and even in parts containing calcareous matter. The solitary abscess is more often possessed of thick walls than are multiple abscesses, which is equivalent to saying that it is more often of old standing.

Abscess of the liver owns a plurality of causes. Injuries of the liver may lead to it; dilatation and inflammation of the bile ducts also. The multiple abscesses occur so invariably in association with dysentery or suppuration in some part of the portal system, or else as a part of a general pyæmia, that they are on all hands considered to be of embolic origin. These forms admit of no dispute. But is there or is there not another variety—the tropical abscess—in which the liver suppurates as the result of an acute hepatitis? There is no space to enter into the history of this question, or even to name the many distinguished men who have entered the arena of its discussion. It must suffice to say that on the whole the arguments in favour of the existence of an acute suppurative hepatitis, independent of any contamination from other sources of inflammation, preponderate. There is indeed some ground for thinking that acute purulent hepatitis is for hot climates what cirrhosis is for the temperate zone, viz., one of the modes of expression of alcoholic excess. Roughly as it expresses the nature of the process, and insufficient as a complete statement of the facts of the case as it is, perhaps we should not be very wide of the mark in saying that "the cold house" favours the slow and hardy growth which we call cirrhosis, the "hot house" the luxuriant processes of abscess. But the question of the existence of an idiopathic

* Thierfelder, 'Atlas,' Pl. xv., figs. 1 to 2*a*. Fig. 1, Pyæmic abscess (? arterial); fig. 2, Pylephebitis.

† For some very good plates of the histological appearances of hepatic abscess, an article in the 'Archives de Physiologie Normale et Path.,' vol. ii., p. 655, by M. Laveran, may be consulted.

suppurative hepatitis cannot be definitely settled yet. Murchison and Fayrer, to name only two of the greatest modern authorities on tropical diseases, believe in its existence, and it is well nigh presumption to suggest disagreement with an opinion which is backed by so ripe an experience; but Budd and many others in this country are at least sceptical, and indeed the facts upon which the existence of tropical abscess mainly depend —viz., the absence of discoverable ulcer, the absence of any previous symptoms of dysentery in many of the cases, the infrequency of hepatic abscess in the dysentery of Europe—are only too readily explained away, as Dr. Dickinson has quite lately pointed out.* The histology of the subject has not as yet been carefully worked out, and until this is done we shall not be in a position to settle the vexed question of its true cause. Thus the pathologist of the present day can hardly avoid *doubt*, for on the one hand he is swayed by the mastery of the doctrines of cell migration, cell growth, and "cellular pathology," which bear strong testimony, to say no more, to idiopathic suppuration; and on the other, he is compelled to forecast the probability, to which the most recent investigations into the process of suppuration undoubtedly point—that the teaching of the future will be that *all* forms of suppuration are associated with the presence of microscopic germs. If this should ultimately be, the question of the dependence of hepatic abscess upon ulceration must become of subsidiary importance, determined by the settlement of a still larger one. For if the presence of germs be needful for the very existence of pus, it must needs be—from the many forms of suppuration which take place without wounds—that they find their entrance into the body by pores so minute and processes so subtle as to require no *ulcer* for their introduction.

Here we must dismiss the subject of tropical abscess. For the minute details of abscess of the liver we are indebted entirely to the information derived from the metastatic form.

Metastatic or pyæmic abscesses in the liver are of various kinds, or rather originate in several regions. Inflammation in any part of the area from which the portal vein draws its supplies is liable to cause embolism of the smaller branches of the portal vein in the liver, and thus to produce multiple abscesses in the distribution of that vein in Glissons capsule (suppurative pylephlebitis). On the other hand, foci of inflammation in the liver—such as suppuration around new growths, in connection with hydatid cysts, &c.—are liable to lead to thrombosis in branches of the hepatic vein, and to produce secondary abscesses in that area;* and a general pyæmia, when it infects the liver, probably does so by the route of the hepatic artery. It is even further possible that some of the abscesses considered to be located in one or other of these regions may be more directly connected with the lymphatic channels. Such cases have been described by Klebs† and others as suppurative periphlebitis.

It may be added that injuries of the head have for long been said to have a preponderating influence in determining abscess of the liver, and Klebs‡ very ingeniously suggests that the liver is particularly obnoxious to suppuration in the bones—1st, because the venous arrangements in the osseous system are particularly favourable to the entrance of foreign matter; and, 2ndly, because the hepatic circulation is favourable to sluggishness, and to detention of the particles thus taken up. On the other hand, from some recent facts collected by C. Baerensprung from the records of the Pathological Institute of Berlin (Ziemssen's 'Cycl.,' vol ix., p. 106), it is doubtful whether injuries of the head are more liable than those of other parts to produce hepatic abscesses. (See also Jones and Sieveking, ed. by Payne, p. 620).

Histology.—The minute changes appear to be very similar for all forms of hepatic abscess which have been submitted to examination. The most apparent are—distention of the vessels of the affected parts with blood or leucocytes; infiltration of the coats of the vessels and of the tissues around with like elements; pallor or discoloration of the hepatic cells, and subsequently their atrophy and disappearance in a mass of granular detritus. These changes have been well described by Koster from the results of experiment. As the hepatic cells disappear, so pus appears, and ultimately the whole focus becomes a confused mass of pus corpuscles. It has been contended by Holm that the inflammatory cells are the product of the hepatic cells, and Von Hüttenbrenner and Wickham Legg§ have repeated and confirmed

* 'Path. Soc. Trans.,' vol. 32, 1881, p. 130.

* For a case of abscess in the distribution of the hepatic veins, see MM. Cornil and Ranvier, *op. cit.*, p. 901.

† *Op. cit.*, p. 426.

‡ *Op. cit.*, p. 433.

§ 'St. Bart. Hosp. Rep., 1872, vol. viii., Art. 8, p. 82.

his observations; but it is now generally believed* that the liver cells undergo no process of proliferation, and that they remain completely passive. Laveran, one of the latest writers on the subject, looks upon the softening as a necrobiotic process, and not a miliary hepatitis. If we regard this question from all points, it is difficult to believe that this is always the case; or that Holm and those who agree with him are so entirely wide of the mark in their view. From what has been of late repeatedly asserted by various observers to take place in cirrhosis, it seems not unlikely that, in some cases of suppuration, Holm's view may ultimately prove to be, at any rate in part, correct.† So much for the later stages of abscess; the initiatory ones are now generally interpreted after Virchow as embolic. In former years the mere presence of the plug in the vessel was supposed to account for such interference with the circulation as would cause necrosis and abscess; but the observations which have been made subsequently with respect to the relation of bacteria to suppuration have extended this doctrine, and it is now taught that the plug is of special composition, the capillary blood vessels being filled with micrococci; and that the cells become disintegrated and pus forms as a result of the combined forces of diminished blood-supply and the disturbance set up by the aggressive growth of these small organisms. Abscesses spread by the extension of these same processes, and are of course liable to extend to bile ducts, and set up catarrhal or even more severe inflammatory processes, and thus to occasion the jaundice which is not uncommonly present.

Multiple abscesses may also arise from suppuration in some part of the biliary tract; or suppuration outside may find an entry into the ducts, and thence be propagated to other parts of the liver.

Cirrhosis.

(Pl. xvii., figs. 2 and 4; xviii., figs. 2 and 4; xx., figs. 3, 4, 5, 6, and 14; xxi., figs. 1, 2, 3, and 13; xxii., figs. 1 and 2).

Cirrhosis is rightly said to be the most important disease to which the liver is liable in this country. This is so, both having regard to its frequency—which appears to be about one in twenty-five inspections—and its aggressive nature. It also has points of no mean pathological interest.

The general appearances of the cirrhotic liver vary much. Sometimes the organ is enlarged, the surface being slightly dimpled or irregular, and the colour brightly jaundiced. This is the cirrhose hypertrophique avec ictere of which there has been so much talk of late. Sometimes it is distorted by deep fissures, which cut it up into unnatural lobes (Pl. ix.); sometimes it is "hobnailed," showing more uniform elevations upon the surface, which call to mind the semi-spherical-headed nails after which it is named (Pl. xvii., fig. 2); sometimes it is much more minutely subdivided, when the surface looks almost as if it were sprinkled with sand—then it is called the granular liver. These external forms correspond with the appearances of the section: the hypertrophic cirrhosis shows a yellow unnaturally lobulated surface; the lobed liver shows straggling scars of thick fibrous tissue cutting up the organ, the large masses between them being sometimes jaundiced, sometimes like the nutmeg liver (Pl. xvii., fig. 1), sometimes more finely lobulated by secondary bands of fibre encircling smaller portions. The hobnailed organ shows circular masses of liver substance, often jaundiced and bulging on the section (Pl. xviii., fig. 4); and the granular liver is more or less grey all over, from the extent and diffusion of the new fibrous tissue (Pl. xvii., fig. 3).

Besides these, the more marked forms of cirrhosis, we must be careful not to overlook the earlier stages and slighter forms of the disease which are liable to escape notice, as simple induration or as induration coupled with fatty infiltration. Indurated fatty livers not uncommonly reveal, upon microscopic examination, cirrhotic changes of the most instructive kind. Furthermore, localised lesions of similar kind are to be met with under a variety of conditions, well described by MM. Cornil and Ranvier (p. 909) as cirrhoses partielles; such are the fibrous thickenings met with around tumours, hydatid cysts, in connection with thrombi in the veins, atheroma of arteries, &c.

It was thought at one time that the external form of the liver indicated the mode of production of the disease; the large yellow liver was the beer drinker's liver; the more segmented, that is to say, the granular or hobnailed organ, the spirit drinker's. No numerical statement has been brought forward to sustain this opinion,

* Birch-Hirschfeld, *op. cit.*, p. 935.

† See on this point, "Affections Paludéennes du Foie," par MM. Kiener et A. Kelsch, 'Arch. de Phys. Norm. et Path.,' 1879, vol. ii., p. 355.

but it is probably to some extent true. The large livers are very generally charged with fat, and are, as Dr. Moxon states, usually found in the corpulent bodies of beer-drinkers. The more granular and contracted are due to dram-drinking. Further, the distorted liver with unnatural lobes is very often syphilitic, and is probably to be explained by the pre-existence of masses of foreign material of the nature of gummata in the substance of the organ, which by their contraction lead to deep scars and fissures.

More recently, some have attempted to differentiate still further, and as a result we have, in addition to alcoholic cirrhosis, a hypertrophic or biliary and a syphilitic cirrhosis, between which there are said to be definite histological distinctions. So far as the macroscopic characters are concerned, the varying appearances of cirrhosis are accounted for by the arrangement and extent of diffusion of the new tissue, and by the presence or absence of such frequently associated conditions as fatty infiltration and local blood stasis. No doubt, too, these conditions are largely influenced by differences in the exciting cause or in the workings of the cause upon the individual organism. The disease matures rapidly in some, in some it advances fitfully, in some it is exceedingly slow. And probably many things which are well nigh impossible to estimate, help to determine whether the liver shall be large or small, smooth, hob-nailed, or granular. But as a matter of fact no recent investigations have succeeded in shaking the old foundations—that cirrhosis of all forms is, in this country at any rate, alcoholic. A few rare cases, if we except the cicatricial form, are due to syphilis, particularly when congenital; a few are due to portal thrombosis; and in some parts of the Continent—Italy, for one—malarial influences seem to be powerful;* but as a disease admitting of clinical recognition, other forms of cirrhosis are beyond the sphere of practical pathology.

Some indeed think otherwise, and have lately given expression to their opinion at the Pathological Society of London in a discussion upon a case of cirrhosis of very unusual character, reported by Dr. Pye Smith. Dr. Creighton supported the doctrine of the conversion of tubercle into fibroid material, here as in other organs; and Dr. Payne is of opinion that fibroid changes occur other than those I have mentioned, which will one day require to be grouped and named. The latter is a reasonable and, I think, probable view; but, without any prejudice to the future, we are unable yet to say when these conditions will be found, or in what circumstances they originate. They come upon us as striking exceptions, and as such they must for the present remain.

I am loth even to enumerate obstruction to the bile ducts among the causes of cirrhosis, because, notwithstanding so much has been written of late in its favour, the existence of a so-called biliary cirrhosis is contradicted by the common experience of the dead-house.* Few affections are more common than gall-stones, but I have never yet met with a case where there was any reason to believe that it had produced cirrhosis. I am not concerned to deny the occasional presence of some slight nuclear excess in the portal canals in such cases—a constructive cirrhosis, if we please to call it so; but any liver that could be characterised as cirrhosed I repeat I have never seen from simple obstruction of the ducts. Moreover, the cases that have been collected by others—eight or ten at the most—are so few in comparison with the frequency of obstruction of the bile ducts, that they are quite exceptional, and a very careful enquiry into the question of alcoholism would have to be made before they could be accepted as cases in proof of a special form of cirrhosis. Further, some of these have been associated with new growths, and there are good reasons for eliminating all such. I am prepared to admit that cancerous tumours about the pancreas and common duct are associated with changes similar to those met with in cirrhosis, and occasionally with an indisputably cirrhosed liver; but I think such cases admit of a better explanation than that they are caused by the obstruction, and they will be dealt with as part of the evidence that cirrhosis is, oftentimes, an *infective* inflammation.

* 'Affections Paludéennes du Foie,' par MM. Kiener et Kelsch, *loc. cit.*

* One of the best examples of what may sometimes happen from simple obstruction of the ducts is to be found recorded by the late Prof. Maurice Raynaud; but the case is so exceptional, and moreover differs in such fundamental points—as, for instance, the integrity of the lobular arrangement—from the so-called hypertrophic cirrhosis, that it strengthens my argument. "Note sur un cas d'enorme dilatation des voies biliaires avec periangiocholite chronique et hypertrophie des glandes pericanaliculaires," 'Arch. de Phys. Norm. et Path.,' 1879.

The grounds upon which the existence of a biliary cirrhosis rests are—1st, the *primâ facie* probability that irritation applied to the ducts would, as elsewhere, start some process of cell proliferation outside them. But epithelial worry is more liable to lead to some atypical development of epithelial cells, such as Friedländer has described*—to a process more allied to that of cancer growth—than to the chronic contracting fibroid changes of cirrhosis. 2ndly, the experiment of ligaturing the common duct in animals has been shown by Wickham Legg,† and Charcot and Gombault,‡ to be followed by such changes in the tissues as in later stages are known to produce cirrhosis in man. But, as I have previously stated, these experiments have been controlled by others, by Litten,§ which goes to show that the *obstruction* is of less importance than irritation of the fibrous tissue surrounding the ducts, a qualification which practically reduces biliary and portal cirrhosis to a common cause. Though it is but right to add that Dr. Hilton Fagge,‖ speaking of Dr. Wickham Legg's experiments, says, "My observations lead me to believe that a similar change occurs very frequently in cases of obstructive jaundice in man, although not to the same degree."

Histology.—The general arrangement of the new material as seen under the microscope is well expressed by the terms adopted by Charcot, and now in very general use—multilobular, monolobular, and intercellular cirrhosis.¶ In multilobular cirrhosis the disease surrounds a series of lobules, and corresponds to the hob-nailed and granular liver in the foregoing description of the general appearances; the monolobular corresponds to the more diffused and smooth forms of cirrhosis; and of the intercellular variety one cannot say more than that it is occasionally found by accident in the dead-house, but that it does not present any characteristic external appearances. It is said to be associated with syphilis in the new-born, and has been described by Gubler, Baerensprung, and Parrot.*

Minute structure of the cirrhotic material.—In accordance with the view that cirrhosis is a simple inflammation of Glissons capsule, the earlier descriptions of the histological changes were correspondingly simple. To say that an excess of nuclei or fibrous tissue existed in the portal canals exhausted a subject then, which is less easily disposed of now. The main departure from this primitive description has been in the prominence which is now given to the existence of an excess of biliary canals, or an arrangement of elements which closely simulates them,† in the portal fissures, in addition to the nucleated connective tissue which has always been described. These have been attributed in some quarters to a proliferation of the terminal ducts; in others to an attempt on the part of the liver to regenerate its lost tissue—by a process of budding from the original ducts; by some they are considered to be formed out of atrophied liver cells; and quite lately Dr. Hamilton, of Edinburgh, has endeavoured to show that they are not ducts at all, but rows of proliferating liver cells in progress of forming connective tissue. In so doing they come to simulate ducts, as they lie in the meshes of the fibrous tissue of Glissons capsule. French observers, to whom we have already alluded, finding that they only occur in certain cases,—that these present, as they think, peculiar clinical symptoms, and that similar morbid appearances can be produced in animals by ligaturing the common bile duct,—have accepted the duct origin of these cells, and have put forward the hypothesis that this state of activity on the part of the ducts is due to obstruction from various causes. Hence they have given to the disease a special name, "biliary cirrhosis." For Charcot, then, monolobular, biliary, and hypertrophic cirrhosis, all represent the same morbid condition. But since the publication of M. Charcot's 'Leçons,' and the attention which has in consequence been given to the subject, it has been ascertained that,

* 'Über Epithelwucherung und Krebs.'

† "On the Changes in the Liver which follow Ligature of the Bile Ducts," 'St. Bart. Hosp. Rep.,' ix., p. 161.

‡ "Note sur les Altérations du foie consecutive à la ligature du canal cholédoque," 'Archives de Phys.,' viii., 272 and 452.

§ 'Charité Annalen,' vol. v., p. 153.

‖ "Observations on some points connected with Diseases of the Liver or of the Peritoneum," 'Guy's Hosp. Rep.,' ser. iii., vol. xx., p. 170.

¶ The adoption of these terms must not be taken to mean that the three varieties are absolutely distinct, for as a matter of fact the multilobular and monolobular forms are very generally more or less associated; and it is not uncommon to find all three in one part or another of the same viscus.

* 'Leçons sur les Maladies du Foie,' Charcot, *op. cit.*, p. 230.

† "Note sur la neoformation de canalicules Biliaires dans l'Hepatite," par MM. Kelsch et Kiener, 'Arch. de Phys.,' vol. viii., p. 770.

whatever may be the nature of these apparent ducts,—a question which must be discussed directly,—they are present in a much larger number of cases than was at first supposed.* They are found in cases of acute yellow atrophy;† they are found in many cases of nutmeg liver (Pl. xxi., fig. 6), in some cases of tubercular liver (Pl. xxi., fig. 5 *d d*), in cancer, and in so many cases of cirrhosis as entirely to deprive them of the significance which originally was supposed to attach to them.

It is quite true, as Charcot and others have insisted, that in some, perhaps in many, of the small hobnailed livers—the multilobular or common cirrhosis—these ducts are not to be seen (Pl. xxi., fig. 13) in many parts; but the probable explanation of this is, that the disease is in such cases represented by fibrous or scar tissue. Biliary ducts in excess are only found where the cirrhosis is in a state of active progress, and when its products are in great part cellular; it is not to be expected that they should survive when all else around them has passed into a cicatricial state.

But it is by no means certain that these cell processes are of the nature of ducts. Observations have of late years been so frequently repeated in favour of proliferation of the hepatic cells that it is hard to believe that such a process is imaginary, and, if it has an existence, a *primâ facie* ground must be admitted for the probability of the position taken up first of all by Wickham Legg, then by Kiener and Kelsch,‡ and Dr. Hamilton. Dr. Hamilton's argument is shortly this:§ the hepatic parenchyma probably owns, with the connective tissues, a mesoblastic origin, and its tendency to fatty infiltration is in favour of this. If so, then proliferation and conversion into connective tissue would be its natural reaction to stimulation of any kind; and in examining cases of cirrhosis he finds all stages of transition between hepatic cells and fibrous tissue. The nuclei of the hepatic cells enlarge, divide, and subdivide (Pl. xx., figs. 4, 5); the periplast disappears, and young cells are set free in the connective tissue. These, in the gradual process of fibre formation, and by the pressure of the contracting fibrous tissue around, become arranged in rows; and should two rows—as commonly happens—lie closely together, they look very like epithelium lining a tube.

This view is in accord with results obtained by experiment, and, as Hamilton points out, has been maintained by other observers than himself. But nevertheless it has one or two weak points. In the first place, it fails to give any explanation of the *double* rows of cells which, as is acknowledged, are prone to occur. One could understand that the contracting fibrous tissue might force the cells into rows, but that it should arrange them so constantly in double rows seems strange for so accidental a relation. And secondly, it seems to me that, though the appearances described are perfectly accurate for some cases, they are so only for a small number; and I allude now only to those which from the cellular nature of the product may be considered to be in a state of progress. Thirdly, the process described by Dr. Hamilton is curiously partial; by that I mean to say that, although many parts of the liver may be affected, some hepatic cells will be actually proliferating, while others just beside them show no action whatever. It might have been thought that in the affected areas the hepatic cells would very generally show some signs of participation.* As regards the changes in the hepatic cells, Dr. Dreschfeld has observed very similar appearances, and he states that he has had no difficulty in tracing the tubes in question from them. He, however, differs from Hamilton in that he regards them as biliary canals, and not as merely accidental arrangements of the hepatic cells; nor has he been able to satisfy himself as to the ultimate conversion of the hepatic cells into fibrous tissue.

I am not inclined to agree entirely with either of these observers; for while, on the one hand, I think with Hamilton that the hepatic cells pass in some cases into connective tissue, I do not hold that these tubular processes are a stage in that conversion, but, with Dreschfeld, that they are really biliary ducts. On the other hand, it appears to me doubtful whether there is any direct conversion of hepatic cells into hepatic ducts by any process of proliferation on the part of the cells.

* Saundby, 'Trans. Path. Soc.,' vol. xxx., p. 301 *et seq.*

† Cornil and Ranvier, *op. cit.*, 890, 891, figs. 305, 306.

‡ "Sur les Affections Paludéennes du Foie," 'Arch. de Phys. Normale et Path.,' vol. ii., p. 355.

§ 'Journal of Anat. and Physiol.,' vol. xiv., p. 185.

* I must not, however, make much of an objection of this kind, when nothing is known of the stimulus, much less of the range of its action. Moreover, exactly the same kind of localisation has been noticed by Schüppel in primary cancer of the liver, which he considers to be a development in like manner from the hepatic cells.

What appears to me to occur is represented in the accompanying woodcut from drawings made by the camera, from a case of cirrhosis. In each of these masses of hepatic cells a collection of small nuclei is seen on its confines (*a a a*). It does not appear that they are the offspring of the

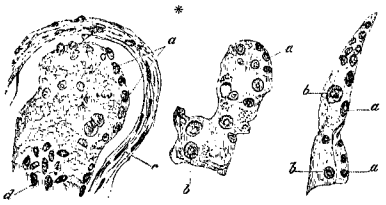

nuclei of the hepatic cells, which are plainly discernible in the neighbourhood (*b b*). Rather do they seem to be the finer ramifications of the biliary ducts, rendered unduly prominent, perhaps, by the multiplication of their epithelium.†

Thus I venture to doubt if there be any actual formation of *new* ducts. Some slight modification of Brieger's view,‡ that the presence of ducts is associated with atrophy of the hepatic cells, is more probably correct. Some of the so-called *new* ducts are probably directly due to such atrophy—an event not unlikely to happen, even if we accept the usual statement of the natural relations which the epithelium of the smaller ducts bears to the hepatic cells, and doubly so if the amplification of that view suggested in the footnote be correct. But atrophy is not the only process by means of which the appearances in question are produced. It is quite certain that in some cases the relation of the minute ducts to the hepatic cells becomes abnormally apparent. As I have said, the masses and columns of hepatic cells become bordered on some margins by a closely-set row of nuclei elongated in the axis of the margin they line. They are not usually demonstrably proliferating, but it is probable that they are so from the number of nuclei present and from their prominence in the section. Moreover, transverse sections of what are nearly certainly similar tubes are seen in all directions, with their canals choked by the excess of epithelium. I have nowhere seen anything which could be certainly said to be new tubes in process of formation, and I believe the facts are best interpreted by supposing that in this respect cirrhosis consists partly of atrophy of the hepatic cells and partly of a conversion of biliary capillaries into biliary ducts by the proliferation of the capillary nuclei. I had arrived at this opinion quite independently from the examination of many specimens, but I see that MM. Cornil and Ranvier take much the same view, attributing the increase of biliary ducts not only to the abnormal prominence of those already in existence, but to the conversion of the biliary capillaries into ducts by the extension onwards of the duct epithelium.

This view is, more than others, in accord with the well-known fact that the ducts are often well seen in cases of acute yellow atrophy. Reasons have been advanced for distrusting the opinion that acute atrophy is a rapid process of cell proliferation. But a fatty degeneration of the cells, such as it is believed to be, while it is unlikely to be associated with proliferation of the ducts, is well known to cause their catarrh; and this, with the atrophy of the parenchyma, supplies abundant reason for their undue prominence. On the other hand, I am inclined to attach more importance to nuclear proliferation of Glissons capsule than perhaps recent observers have been inclined to do. Hamilton, for instance, while not claiming for the hepatic cells a monopoly for the formation of the fibrous tissue, believes that they are chiefly concerned in its production. I cannot accept that view: on the contrary, it seems to me that the earliest departure is a simple excess of nuclei in the portal canals. This may easily be determined by examining, not those organs which are obviously diseased, but

---

* Explanation of Woodcut.—*a a a*. Nuclei arranged along the side of a mass of hepatic cells. *b b*. Nuclei of hepatic cells. *c*. Fragment of Glissons capsule. *d*. Nuclei ? due to the proliferation of the nuclei of the hepatic cell.

† I know not how far it may be thought safe to take morbid states as exponents of natural conditions, but, with this reservation, I am disposed to think that one point in the minute anatomy of the liver would bear redescription. From what may be seen in some morbid specimens, the epithelium of the minute ducts can hardly be said to be replaced by, pass into, or be carried on as, gland cells. It becomes applied to (*a*) and incorporated with those faces of the cells which are grooved by the biliary capillaries, though in this position and in health it is both more sparsely and more irregularly distributed than in the larger ducts. But if this is the real relation of the terminal ducts to the hepatic cells, then, supposing that atrophy of the cells were in progress, an involution of parts of the gland would be presented, by which the elaborated structure would reappear in more primitive form as a system of simple tubes.

‡ "Beiträge zur Lehre von der Fibrösen Hepatitis," 'Virch. Arch.,' Bd. 75, Heft. 1, p. 85.

those of bodies past middle life which would pass as healthy or at most as indurated. In them we see the beginnings of cirrhosis, and they are confined entirely to Glissons capsule. As the result of a number of examinations of this sort of early cirrhotic conditions in lardaceous disease, for example; of pronounced cirrhosis of all kinds,—bearing ever in mind, too, the various appearances that have been described by, and have received the sanction of, the most competent workers almost from time immemorial,—I think we must now take some such modified and extended view of cirrhosis as this: the disease takes origin—as has always been taught—in the connective tissue of Glissons capsule. So it may continue, and thus may lead to a slow thickening of this capsule, to a simple atrophy of the liver cells, and a multilobular cirrhosis. And in this process of atrophy the liver cells may come to represent biliary ducts of new formation, and the minute biliary *ducts* may be brought into undue prominence by the shrinking of the hepatic cells. Such changes are not to be looked upon as necessarily indicating some active process of growth, for at times they are quite independent of it. But cell proliferation may be of all grades of activity, and in proportion to this activity so are its infective properties. Thus, when cell growth is in active progress in the connective tissue of Glissons capsule, and this is not seldom, few or many of the neighbouring hepatic cells coming within range of this infective influence participate in the revolution. The amount of new tissue found in cirrhosis, the evidence of active growth there, the number of biliary ducts in the portal canals, the amount of proliferation within these ducts, the evidences of proliferation of the hepatic cells, vary so greatly in different cases that it is impossible to avoid the conclusion that cirrhosis as a pathological process embraces phases of cell growth but little removed from hypertrophy at one extreme, and closely approximating to malignancy or tumour growth at the other. And in order to justify this introduction of the doctrine of "infection" to a somewhat new domain, I will first adduce a group of cases—examples of which are not very uncommon—where cirrhosis of the liver is associated with tubercles on the adjacent peritoneum, and perhaps on the pleura also. It has been suggested—quite reversing, as I think, the natural order of things—that the cirrhosis is the result of a bygone tubercular deposit, comparable to the fibroid change in the lungs in chronic tubercular phthisis. But the evidence of this is very little, for tubercle is conspicuously absent not only in the other viscera of such cases, but even within the liver itself; whereas we know from examples in plenty that serous surfaces are liable to be affected by a granular form of growth,—we presume by some process of infection,—from adjacent sources of inflammation. The more probable explanation of cases such as these is, that what in the first place is a simple inflammation of the liver becomes ultimately something more than this, and infects the neighbouring parts.

Nor do I think that the descriptions of "the cirrhotic liver of phthisis," described by Saundby and Brieger,* can be considered as destructive of this hypothesis. I am not familiar with any such associated changes in any sufficient number of instances to prove the connexion; but I can understand that in phthisis the liver cells, with their surcharge of fat, might provoke histological changes which must be called cirrhotic, just as the congestive conditions of pulmonary obstruction may do. But as I have already stated, no cirrhosis capable of clinical recognition is found with phthisis in any considerable number of instances.

2ndly, Charcot's hypertrophic cirrhosis is an enormous overgrowth of new tissue in which all the elementary parts of the organ are concerned, and I should regard it as only one stage removed from cancer. In support of this view it may be pointed out that, out of all proportion to the cases associated with simple obstruction of the duct by calculus, are those in which the obstructing element has been actually a cancerous tumour. What more likely, from what we know of the habit of infecting tumours, than that the lymphatic tissue outside—that is to say, Glissons capsule in the special case—should become infected, and the process propagated so? These cases supply no evidence in favour of a biliary cirrhosis, due to *obstruction* of the bile ducts; the presence of an infecting tumour works the mischief, not the bare existence of obstruction to the duct.

3rdly. A further argument may be derived from the existence of a group of cases to which special attention has been called by Dr. Hilton Fagge,† under the name of contracting cancer, simulating cirrhosis. Three cases are put on record, and allusion is made to two others—one

* *Loc. cit.*, p. 94.

† 'Trans. Path. Soc. Lond.,' xxviii., 1877, p. 137.

by Frerichs,* and the other by Murchison.† Both Frerichs and Dr. Murchison looked upon the two conditions as independent of each other; but Dr. Fagge is inclined to think that the cirrhosis is a part of the cancerous growth—a view apparently supported both by Schüppel, and Perls, who suggests the name cirrhosis hepatis carcinomatosa for the affection. Dr. Fagge adds, however, that there still remains the further question, whether excessive indulgence in alcoholic stimulants may not sometimes cause such a disease, instead of an ordinary cirrhosis; and I think that is a suggestion which a study of cirrhosis will induce many to accept. It seems to me that in this group of cases is the one link wanting to complete the picture of the transition from hypertrophy to tumour, or from quiet inflammation to the more active forms of infection, which, as a matter of fact, is embraced by the term cirrhosis. Whether the cancer is the immediate outcome of the stimulus, or a more gradual development through a cirrhotic stage, is a question of intensity, not of difference in the nature of the process.

This presentment of cirrhosis would do away with all special forms, and affiliate it to inflammatory and other cell-growth as found in the body in general. We have in the liver, for instance, parallel stages to those seen in irritative hypertrophy, warts, and epithelioma of the skin, or in ichthyosis and cancer of the tongue. Very little investigation sufficed to show that many cases of atrophic cirrhosis present all the histological changes supposed to be characteristic of the hypertrophic form, so that no difference founded on the presence or absence of biliary ducts can be sustained, and there is no sharp pathological distinction of any kind between one case of cirrhosis and another. Had it not been that some of these cases were associated with tumours at the head of the pancreas and about the common duct, diseases of a particularly infective nature, I think it probable that biliary cirrhosis as a *result* of obstruction would hardly have seen the light.

But although biliary cirrhosis has no existence, or is so seldom found that it does not deserve a special name; although hypertrophic cirrhosis has not the significance which Charcot would attach to it; nevertheless the clinical features assigned to it, in the light of what has gone before, are still possessed of a meaning—and it is this: the subject of cirrhose hypertrophique avec ictère is affected by a disease which is no simple inflammation, but one which in extent and activity approximates in nature to a tumour, and which is therefore liable to rapidity of development. The only serious argument against this view—but a fatal one could it be substantiated—is, that hypertrophic is an early stage of common cirrhosis, the enlargement and cellular growth giving place to the contraction and fibrous tissue at a later period. This has been asserted by some, but there is no evidence that I know of by which to support the statement. Thierfelder* has discussed this question, and argues against any such conversion; but much of his argument unfortunately depends upon the assumption that the duration of the hypertrophic form is generally longer than ordinary. This may well be doubted. He does not seem to have taken sufficiently into consideration that the atrophic forms of cirrhosis are probably years before they cause severe symptoms; while the hypertrophic form, both from the enlargement of the organ and the accompanying jaundice, would be likely to direct early attention to the disease.

So much for the changes in Glissons capsule and the biliary canals. The hepatic cells have incidentally also received considerable mention, but of them it must be added that they are liable to become charged with fat in cirrhosis (Pl. xxi., figs. 3, 13), or with bile-pigment. They may also contain blood-pigment in excess, and thus present some of the appearances of the nutmeg liver; and cases are described in which they contained black pigment in quantity; but in such cases there seems to be some doubt whether the change had not more to do with some pre-existing malarial taint than with the condition of common cirrhosis. It may also be repeated that the hepatic cells, while undergoing atrophy in some lobules, become hypertrophic in others (Klebs, *loc. cit.*).

The circulation in the portal veins and in the collateral channels has already been described (p. 2), and I have only now to call attention to the increase in size and number of the branches of the hepatic artery, and to the formation, as an occasional occurrence, of a spongy cavernous tissue in connection with the interlobular veins. I have seen the latter condition more than once,

* *Op. cit.*, vol. ii., p. 314. Obs. xlii.

† 'Trans. Path. Soc. Lond.,' xiv., p. 100.

* Ziemsseu's 'Cyclop.,' vol. ix., p. 220.

and MM. Cornil and Ranvier describe a similar one. It is attributable to an extreme condition of obstruction to the passage of the blood through the liver, and it forms an artificial reservoir for the blood till it can find its way off by the various collateral channels. It is even possible that such a state of things might supply the means of a compensatory portal circulation by which some sort of crude performance of some of the functions of the liver might be carried on by the aid of the other vessels in the same strands.

Cirrhosis of the liver is usually accompanied by a firm, dark-coloured, more or less weighty spleen, and by a congested stomach and intestine. In the stomach there may be superficial erosions, or even minute perforating ulcers,* and the whole gastro-intestinal tract is liable to catarrh, being covered with thick tenacious mucus. The presence of œsophageal and rectal piles has been already mentioned.

Syphilitic Hepatitis.
(Pl. xiii., xxi., figs. 7, 12; xxiii.)†

Syphilis affects the liver at all ages and in various ways. It is liable to produce perihepatitis, lardaceous disease, gummata, and diffused forms of cirrhosis. We have here only to do with the two last-mentioned. Between them Virchow and Frerichs make certain distinctions; but a diffused cirrhosis pure and simple is not common in syphilis, and it is probable that—as Klebs teaches‡—the two conditions are one in origin, representing either degrees of cell growth or divergent results of some common product. Attacking, as it does, the interstitial connective tissue, and tending to produce cicatrices by the infiltration of the parenchyma somewhat widely, syphilis has no doubt been assumed to produce a cirrhosis which is indistinguishable from that form of the disease attributable to the abuse of alcohol. But as a matter of experience but few unequivocal cases can be produced to show that it does so, except, perhaps, in childhood. There is some reason for supposing that the distribution of the change may vary with the age of the patient. In new-born children, supposing cirrhosis to be present, it will probably be of the diffused form; in adults, as is well known, the gummatous kind is far more common.

Congenital Syphilitic Hepatitis.—It is by no means an uncommon thing to find the liver and spleen enlarged in syphilitic infants, and we further know that enlargements of the liver in such children diminish rapidly under mercurial treatment. Many such livers have now been obtained and submitted to microscopical examination by Gubler,* V. Baerensprung,† Wagner, and others.‡

Their macroscopic features are not very characteristic. The liver is usually large and heavy, smooth, anæmic; sometimes altered in colour to grey; sometimes mottled, from the blending of grey, anæmic, and fatty parts. The lobulation is indistinct, and thin sections somewhat resemble lardaceous material.§

Cicatrices are only occasionally found,‖ and gummata¶ are still more rare.

Under the microscope a diffused nuclear growth occupies the portal canals and runs in between the rows, and even between the individual cells. The behaviour of the hepatic cells in these cases has seemed to me to be a purely passive one. In the five cases I have examined the alterations were pericellular: in one of them mostly in the arterial zone of the lobule; and in all seeming to originate by irregular dilatations of the capillaries and the subsequent appearance of nuclei in their course. The dilated capillaries were associated with atrophy of the cell columns, not with proliferation. Again, the morbid product may show itself as small collections of cells (Pl. xxi., figs. 7, 12) which much resemble miliary tubercles, but wanting the cheesy tendencies of tubercles; they are consequently less liable to become stained with bile. It is supposed that this condition may lead on to a diffused form of cirrhosis, and to a small granular liver; but this is doubtful. It is known that the miliary or pericellular cirrhosis exists; it is also known that in occasional cases a granular cirrhotic liver like that of adults is found in quite young children; the difficulty lies in the identification of the one as the late stage of the other, and there are many who think that the granular liver of childhood has the same meaning as in adult life—that its subject has become habituated to the consumption of alcohol. Certainly some

* Murchison, 'Trans. Path. Soc. Lond.,' vol. xxi., p. 162.

† See also A. Thierfelder, 'Atlas,' pl. 16, figs. 2, 2*a*; pl. 17, figs. 3, 3*a*, 4.

‡ *Op. cit.*, p. 440.

* 'Gaz. Med. de Paris,' 1852, p. 262.

† Wagner, 'Arch. d. Heilkunde,' Bd. v., p. 121.

‡ 'Die Hereditare Syphilis.'

§ Thierfelder, *loc. cit.*, p. 225.

‖ Barlow, 'Trans. Path. Soc. Lond.,' vol. xxvii., p. 202.

¶ Coupland, 'Trans. Path. Soc. Lond.,' vol. xxvii., p. 303.

such cases are to be attributed to this cause, and the margin left for a syphilitic cirrhosis of this form is not a wide one. Now this is curious, because the pericellular form of interstitial inflammation, being more diffused than any other, would be more likely, one would suppose, to produce a minutely contracted liver. That so little evidence of an affirmative nature exists therefore requires explanation. Perhaps it is because the diffuse form is also associated with much atrophy of the hepatic cells, and greater fatality attaches to all such cases. The alternative would seem at this time of life to be between recognition and cure by the administration of mercurials—and death. The case already alluded to by Dr. Barlow, in which the gummata are described as *receding*, and in which the appearances were anything but characteristic at the time of death, although they had been so during life, seems to support this view.* It seems to show the probability that, had the child lived a little longer, there would have been no evidence at all of any change in the liver.

Another form of disease in congenital syphilis has been described by Schüppel and Birch-Hirschfeld as Peripylephebitis Syphilitica. A gummatous formation starting from the connective tissue of the larger portal channels may reach more than a centimetre in thickness, and compressing the biliary and venous channels cause an intense jaundice.

Syphilitic hepatitis in the adult produces an organ often large, sometimes jaundiced; and subdivided into unnatural lobes by bands of fibrous tissue (Pl. xiii.). Thus it can be distinguished through the abdominal walls during life by its size and lobulation. On section the fissures on the surface should correspond with gummata in the interior, or their cicatrices. The destruction caused by gummata and their cicatrices is sometimes so great as to involve a large part of the liver substance, and is usually accompanied by a compensatory hypertrophy of the remainder. Gummata are (Pl. xxiii.) more or less circular tough yellow masses, very firm and elastic, yet not unfrequently softening down, and with a grey circumferential zone of fibrous tissue which gradually passes into less indurated and then into the healthy texture. Under the microscope they show a caseous and often structureless centre. Externally there is a close network of fibrous tissue enclosing numerous uniform round nuclei, and the tissue is richly supplied with small blood vessels and capillaries. By the active formation of fibrous tissue these become pressed upon and obliterated, and so the mass continues to degenerate centrally, as it grows from its margin. But it is not to be supposed that gummata are always yellow. The colour is obviously due to degeneracy; and though probably ensuing early, is nevertheless occasionally absent, and tracts of more or less circumscribed grey induration are met with, which prove to be in great part actively growing or cellular. Nor is it so very uncommon, notwithstanding the distinction usually drawn between the miliary gummata of congenital syphilis and the condition just described, to find that there is a great similarity between them. I have seen four cases at least in which a diffused interstitial change has been discovered in the liver of adult syphilitic patients dying from various causes, so that I suspect after all there is not so much essential difference between the disease at one time of life and at another; the apparent difference must be due to the modification under which the disease works at the different periods. The greater prevalence of miliary gummata—that is to say, of the more diffused forms of the disease in infancy—may be due, as I have suggested, to the greater fatality from the disease at that time; or from the more active processes of cell growth, if they should happen to have been uncontrolled by treatment, and so on.

With regard to the minute histological changes, very little difference can be detected between the one and the other. The larger gummata, being obviously formations of some little date, present a more organised structure. Their central parts are composed of a fibroid tissue, where not caseous; and their peripheral zones of a highly vascular granulation tissue, which sometimes contains giant cells. But of the more diffused forms, whether for adult or child, both appear to be interstitial and capillary—not due to changes in the hepatic cells; both seem occasionally to prefer the arterial zones of the lobules; but in neither has any special change been detected in the arterial coats, such as has been found in the arteries of the brain. The fact that the hepatic cells are passive in syphilitic hepatitis must, I think, receive some consideration, as bearing upon their behaviour in alcoholic cirrhosis. There is no doubt that the ultimate result of syphilitic hepatitis is an increase of the fibrous element of Glissons capsule, as in the more

* 'Path. Soc. Trans.,' vol. xxvii., p. 202.

common diseases; yet the hepatic cells do not appear to take part in the process. Here, then, is another condition besides the earlier stages of common cirrhosis, in which the connective tissue is formed from elements in the portal canals, and not from the hepatic cells. From it we may gather additional support for the argument that, when the hepatic cells do take part, there must be some stimulus in excess of that supplied in common cirrhosis; what that additional stimulus may be, and whether it is supplied by postulating a theory of infection, is of course a further question which must be determined upon its own merits.

Gummata, as has been indirectly mentioned, undergo certain retrogressive changes, which may lead—(1) to their resorption and conversion into cicatricial material; (2) to softening, either into a yellowish gummy fluid or, more rarely, into pus; (3) to calcareous changes.

The Pigmented Liver.

English pathologists have no practical experience of this disease, but it would appear to be not uncommon in some parts of the Continent and in the Tropics. As a result of exposure to malarial poisons, the blood becomes full of granules of black pigment. These are at first free, and are supposed to represent an equivalent of disintegrated blood corpuscles. Soon, however, they are taken up by the white corpuscles, and with them pass from the circulation into the surrounding connective tissue. This passage is facilitated by sluggishness of the circulation, and the liver, spleen, and central nervous system appear to supply the most favourable conditions for emigration. The connective tissue of the portal canals in such cases becomes crowded with grains of black pigment, and in extreme examples the walls of the vessels and the connective tissue outside them throughout the entire lobule are bedecked in like manner. The macroscopic appearances correspond with the degree of pigmentation. Sometimes the surface is mottled grey and yellow, sometimes it assumes a uniform blackish grey tint. Further, the presence of pigment is supposed to exert an irritant effect on the extra vascular connective tissue, and to provoke its overgrowth or inflammation. At any rate this appears to be certain—that a granular form of cirrhosis of the liver is not uncommon in malarial climates, and it is supposed by those best entitled to an opinion to be the direct outcome of the pigmentary excess in the blood.

Kelsch has found in these cases that there is an excess of bile in the biliary passages and gall bladder.*

NEW GROWTHS.

These are of all sorts: simple and malignant, primary and secondary, fibrous, fatty, cavernous or vascular, glandular, and sarcomatous. But some of these are of little importance.

Fibrous tumours, for example, are small and rare. I have met with one case in which a tumour of this kind beneath the capsule reached the size of a small pea. They are usually much smaller, and of no pathological importance.

Fatty tumours are mentioned by Birch-Hirschfeld; they are still more rare.

Angeiomata or Cavernous tumours (Pl. xx., figs. 11 and 13) are not very uncommon; they are dark claret-coloured tumours, usually a quarter of an inch or so in diameter, but occasionally reaching a much larger size. I have once met with one an inch or thereabouts in its largest diameter. They are often just beneath the capsule, and solitary; but may be multiple, and studded through the substance of the gland. They have a sharply defined angular outline, a slightly depressed section, and if the blood, which they contain in quantity, be washed away by a stream of water a finely reticulated structure is disclosed—the counterpart of the structure of the spleen or of the erectile tissue of the penis. The nature of these tumours has been the subject of some discussion. Most German writers, following Virchow, consider them as primarily due to dilatation of the capillaries with associated atrophy of the liver cells. Rindfleisch, on the other hand, appears to consider them as due to a local or partial cirrhosis, and a subsequent cavernous metamorphosis. Were it not that Virchow has traced them from their earliest formation in the capillaries of the lobule, I should be inclined to agree with this view; for there is no doubt that the liver in their neighbourhood is indurated, and the portal canals are thickened by fibroid tissue; moreover, in advanced cirrhosis a cavernous tissue not very dissimilar is occasionally to be found in Glissons capsule. However, they have not much patho-

* 'Archiv. de Physiol. Normal et Path.,' Ser. ii., vol. iii., p. 690.

logical importance, and it must suffice therefore to describe them.

They are composed of tough fibroid and muscular tissue, which is richly supplied with round and large oval nuclei, and thin walled blood vessels, and is intersected in all parts by spaces communicating with each other, lined by a spindle-shaped epithelium. Sometimes more prominent cells suggest the presence of a columnar lining, but these are the oval nuclei of the stroma rendered prominent by an obliquity of the section (Pl. xx., fig. 13). The spaces can be distended by injections from the portal vein or the hepatic artery.

A recent article by M. Journiac in the 'Archives de Physiologie Normale et Pathologique'* professes to differ both from Virchow, who regards the tumour as a new formation, and from Rindfleisch, who regards them as perilobular fibromas; and follows Cornil in regarding them as due to a proliferation of the perivascular embryonic tissue, which allows the vascular flow to dilate the vessels—veins and capillaries particularly—at the same time it thickens their walls.

They occasionally solidify, from coagulation of the blood in their interior, and thus possibly—as suggested by Birch-Hirschfeld—a cystic tumour may subsequently be formed. Dr. Moxon has twice found them associated with cancer, and I once; but they appeared to be independent growths, and not themselves cancerous.

Of *Lymphangeioma Cavernosum* of the liver† (cylindroma of some authors) I have no knowledge. But, bearing its origin in mind, we may well doubt if it deserves this name. It is a secondary tumour, which is derived from some similar growth in the bones of the face or glandular apparatus in the submaxillary region. I should therefore take the view that it is of a cartilaginous or mucous nature, and that the lymphatic arrangement is apparent rather than real.

Of other new growths I shall speak first of all in common, because they are all, or almost all, infective—in common parlance, "malignant." It has been the custom to distinguish between those which are primary and those which are secondary; but the observations from many sources which have been made of late years seem to show that, so far as the liver itself is concerned, there is not much variety in the process of growth. It appears to be a general law for all hepatic tumours that the liver cells themselves take an active part in their formation. We find, for instance, Greenfield,* in describing a primary columnar epithelioma of the liver (Pl. xx., fig. 15), noting the existence of hepatic cells with swollen nuclei, and some in process of fission. Schueppel makes the statement—for primary cancers—that the cells are to be considered the offspring, partly of the secretory glandular cells, and partly of the epithelial cells of the smaller bile ducts; and he concludes, "In the cases which I have examined, the hepatic cells themselves almost exclusively led to the formation of cancer."† Dr. Moxon writes, "As a rule, the cancer cells are developed by direct transformation of the hepatic cells." Rindfleisch teaches similar doctrine. And lastly, I may cite Creighton—for secondary tumours—as one who holds, from independent observation, a like opinion. Thus, whether we take those growths which originate in the liver or those which are transplanted there; whether we take epithelial, sarcomatous, adenomatous, or even lymphomatous growths, the same rule holds good—they each and all increase by a process of recruiting amongst the cells of the parenchyma of the organ. According to the last-named observer, the stages of the process are vacuolation of the hepatic cells, then endogenous cell formation, and ultimately tumour formation. The appearances seen in the hepatic cells are depicted in Plate xxii., figs. 14, 15, 16, which are copied from Dr. Creighton's article.‡ But without necessarily accepting all the details of the process, although they are very carefully worked out, the fundamental fact is the activity of the hepatic cells; and this is corroborated by observers of all schools. And this is in accordance with other evidence of no little strength. I have shown that the existence of hyperplasia of the liver cells, as expressed in various forms of compensatory hypertrophy, is beyond dispute; the facts of cirrhosis go to show that not only hyperplasia, but in some cases specialised forms of the process, even to the production of connective tissue, occur; and that

* 1879, vol. ii., p. 58.

† Klebs, *op. cit.*, p. 471.

* 'Path. Trans.,' 1875, p. 166.

† Ziemssen, *loc. cit.*, p. 328. Schueppel does not admit of any such changes in the hepatic cells in secondary cancer.

‡ "On the Ætiology of Cancer," 'Report of the Medical Officer of the Privy Council, &c.,' New ser., 1874, p. 95.

this condition presents itself in different grades in different cases, an observation which is in harmony with the view now generally recognised by pathologists—that the hyperplasia of inflammations and that seen in the various forms of neoplasm cannot be separated from each other by any definite line. It is even possible to question whether the minute ducts (as distinct from the bile capillaries) can be considered as histologically distinct from the liver cells (see pp. 4, 35). Moreover, were they so, it is a law which is prodigal of examples, that cells starting with different morphological bias tend to be regulated in their form and action by the company in which they find themselves. Therefore, while the descriptions of the morbid processes in the liver which have been enunciated of late years contain much to startle, and even to repel one who is bent on maintaining clear definitions and a regular morphological continuity of succession,—gland cell from gland cell, duct cell from duct cell, connective tissue corpuscle from its own,—the morbid histology of the liver does not teach this; on the contrary, it makes clear that in the various new growths the process is a complex one; and I should certainly be disposed to endorse the statements to which I have called attention, both by Schueppel and Creighton, and which are to the effect that the cells of the growth are derived in part from the gland cells and in part from the cells which form the walls of the smaller ducts. Nay, we can even go further and say that there is enough evidence at hand to allow us to teach that from the hepatic cells alone tumours may arise which have both sarcomatous and carcinomatous characteristics.*

This view, which I believe to be true for many of the infective or malignant tumours of the liver, does not exclude the occurrence of growths which are uniform in constitution. Not at all. Adopting the infective theory of the origin of growths, which assumes—and the assumption is in harmony with what we know of cell processes in other conditions of the animal economy, and in other branches of organic life—the existence of some spermatic influence, the sperm is active to reproduce itself, or active in impressing the power of reproduction only upon the germ—the likeness of the immediate germ rather than the mediate sperm being propagated. And so we might presuppose—what actually is the case—that some growths in the liver by what we may perhaps interpret as vigorous sperm action and excessive cell proliferation within themselves, proclaim their original in minutest detail; others again declare themselves only by fertilising the elements among which they find themselves, and grow up unlike the sperm, but like the germ. Lastly, it must be remembered that there is plenty of evidence to show that the fertilising agent possesses limited powers of diffusion, a fact which explains an observation of Schueppel upon what has prevented, and does still prevent, the reception by many of any such doctrine as here laid down—that only small rows of the hepatic cells are subjected to the cancerous transformations, the greater part undergoing atrophy from the pressure of the growing cancer.

I fear it may be said that much of this is but vague generalisation which is incapable of proof. But I would venture to insist that none of it is beyond reasonable induction; its purpose—and it seems to me to accomplish it—is to harmonise the many and often at first sight conflicting observations which have been made of late years upon the various neoplasms met with in the liver; and it further, by taking up ground of general pathology, renders unnecessary a good deal of tedious detail in the description of the special classes of tumour to which we must now shortly address ourselves.

General appearances.—In this respect all forms of malignant growth may be included under a common description, for it is not possible from the macroscopical appearances to foretell with any apparent certainty the histological structure. The most that can be said is that diffused infiltrating growths are generally carcinomatous; the nodular may be of any kind.

In the diffused and infiltrating forms the liver is generally much enlarged; its peritoneal aspect smooth; its section is often deeply jaundiced, and the surface of the section is mottled or nutmeg-like. Some parts may be minutely veined with colloidal or glue-like ramifications, which intersect the more opaque parts of the less altered liver substance. Schueppel speaks of the diffused form as one of extreme rarity, but it is hardly so. It is much less common than nodular masses; but as a sequel to carcinoma about the pylorus and stomach it is not so exceedingly rare. As a variety of this diffused carcinoma must be mentioned, the disease described by Fagge as primary contracting

* For a very interesting case which raises this question, the reader may be referred to a case recorded by Dr. Sydney Coupland in the 'Trans. Path. Soc. Lond.,' vol. xxxi., p. 180.

scirrhus, simulating cirrhosis, and by Perls as carcinomatous cirrhosis. The liver is to all appearances a granular cirrhotic one, except that the fibrous septa are unusually wide, and the *granules* therefore more pronounced.

The nodular forms of tumour present great variety. Some are very firm and cartilage-like, both in their resistance to the knife and in their grey translucent appearance. They have less well-defined margins than the softer forms, are often umbilicated, and they are liable to exhibit yellow specks of caseous degeneration or a large central caseous mass. Growths of this kind are of all sizes, from an inch or even much more in diameter down to the minutest grey tubercles. They are by no means necessarily of very rapid growth, and may therefore be associated either with a large liver or one not much over the average weight. They tend to associate themselves with enlarged glands in the portal fissure, and are consequently *liable to be* found with a deeply jaundiced liver of yellow or olive-green tint (Pl. xii., fig. 2). Primary growths in the breast, stomach, gall bladder, or colon, all at times give origin to a disease such as this.

The softer forms show as globular protrusions on the surface, the liver is often much enlarged, and on a section the masses in its substance are sharply circumscribed, creamy-looking, soft and bulging, and are most of them of considerable size (Pl. xvi., fig. 1). They, too, are often found to have undergone some caseous degeneration in their central part, or they are torn up by hæmorrhagic effusions, from the rupture of some of their numerous capillary zessels. The fungous hæmatodes—a term of days gone by—found its best expression in this group, and from it come the cancerous polypi which not unfrequently grow into the veins of the organ. The presence or absence of jaundice in such cases will depend upon the existence, or not, of any pressure upon the ducts.

The pigmented cancer (melanotic sarcoma) is very rare. Although the specimens are not uncommon upon the shelves of a museum, I do not remember to have met with a single case in the nine years I have been associated with my colleague, Dr. Hilton Fagge, in the post-mortem room of Guy's Hospital; and but one case has come before the Pathological Society of London in that period. They are usually growths of similar shape and consistence to, but perhaps vary more in size than, those of the preceding group; but the nodules are more or less black or brown, from the deposit of pigment in their cells. They are generally very vascular. Occasionally the growth is a diffused one, when the blending of pigmented with unpigmented cells and those of the still healthy liver produce a grey speckled condition, which has been denominated "granite cancer."

Adenoma and Primary Cancer.
(Pl. xx., fig. 15; xxiii., figs. 17, 19).

Adenoma is of two kinds—one an encapsuled growth, formed after the type of the liver cells; the other, conforming in appearance to tubular glands, may not improbably originate in the biliary ducts. Either may be a solitary tumour; but more often multiple nodules are scattered through the liver, and secondary deposits may be found elsewhere, as in Dr. Greenfield's case (Pl. xx., fig. 15).* Clinically, therefore, they are liable to present themselves—the tubular variety particularly so—as cancers.

The first form (Pl. xxiii., figs. 17, 19) corresponds to what has been described by Friedreich† and others as nodular hyperplasia. The nodules composing it are surrounded by a capsule of connective tissue, and are composed of cells like the hepatic cells, but often larger and containing fat or several nuclei. Between the cells, which are arranged somewhat irregularly, are small "indifferent" cells or nuclei. Eberth's‡ observations upon a dog affected thus, point to a commencement of the disease in the lobules by hypertrophy and hyperplasia, a process which gradually extends to the entire lobule and then to neighbouring ones.

Several cases of this kind have been described as local tumours. The drawings were made from such an one; of others I may mention that by Dr. Mahomed§ as one of the most authentic.‖ Others are multiple, as just described; and others, besides a multiple formation in the liver, have affected spleen, lungs, glands, &c. Lancereaux has even attempted to distinguish clinically this group of cases from other forms of cancer; but this, even to so adept a hand, is evidently a difficult task.¶

* 'Path. Soc. Trans.,' vol. xxv., 1874.

† Virch., 'Arch.,' xxxiii., pp. 48, 553.

‡ Virch., 'Arch.,' xliii., p. 1.

§ 'Trans. Path. Soc.,' 1877, vol. xxviii., p. 144.

‖ See also Hoffman, Virch. 'Arch.,' xxxix., p. 193. Grosses Adenom. der Liver.

¶ 'Gazette Medicale de Paris,' 1868.

The chief interest of this variety of adenoma naturally lies in its relation to primary cancer of the liver; and, indeed, from what has already been said upon the *rôle* played by the hepatic cells in most of the neoplasms of the liver, there can be no practical difference between the *multiple infecting forms and cancer*. But one may nevertheless question the propriety of the objection which some make on this ground to retaining the term adenoma for the localised tumours, such as Pl. xxiii., figs, 17, 19, and that recorded by Dr. Mahomed. We do not deprecate the use of the term papilloma, because there is no fixed boundary between it and epithelioma; neither need we here dispense with a term which is applicable to the local tumour because it has very close relations with a primary cancer of the hepatic cells.

Tubular Adenoma (Pl. xx., fig. 15), like the simpler form, is usually multiple. The description given by Rindfleisch of the growth and origin of the tubules is to the effect that they commence as roundly oval cylinders of cells which form within the lobule and out of the trabeculæ of the hepatic cells. Schueppel states more precisely that they are produced by enlargement and fission of the hepatic cells, and by the resulting elements arranging themselves circularly around biliary capillaries. Birch-Hirschfeld, on the other hand, inclines to a view which I for the most part should be inclined to adopt—that the tubular forms of adenoma are the offspring of a budding process in some of the smaller biliary ducts. MM. Kelsch and Kiener,* on the other hand, consider that the tubular form is, equally with the other variety, formed out of the hepatic cells; and they trace its formation through various stages—sometimes by general swelling of one or more lobules, sometimes by the appearance of isolated miliary nodules in the centre of the lobules. The hepatic cells are seen to be in a condition of nutritive over-activity, swollen, containing several nuclei, and proliferating by fission. The tubules thus formed bend and double upon each other something after the manner of the cerebral convolutions. They also describe how growths of this kind are wanting in vascularity, how they tend to undergo colloid and caseous changes, and also the occurrence of a concomitant cirrhosis. It must be admitted that the question of origin is no easy one to settle, when all along the line of the pathology of the liver the chief ground of contention has been whether certain appearances are due to minute ducts or proliferating hepatic cells; and victory as yet remains conclusively with neither side. The figures given in illustration of an *hepatic cell adenoma* (Pl. xxiii., *figs.* 17, 19), are an apt illustration of the difficulty, for the supporters of a biliary duct origin, might well claim the appearances as agreeing exactly with those of the biliary ducts in any section of healthy liver.

But to return—in one way or another masses are found entirely composed of convoluted tubes lined by cubical epithelium, and in most cases separated from the hepatic parenchyma by a fibrous capsule. The tubules are bound together by a vascular stroma, which derives its blood-supply probably from different sources, sometimes the portal vein, sometimes the hepatic artery. MM. Cornil and Ranvier include all these cases under the head of cylindrical epithelioma. But this generalisation is too sweeping. There is no doubt that secondary tumours of the liver are often of that nature, as is to be expected when we consider that the most common cancers of the portal system are from the sigmoid flexure and rectum; but primary tumours, both solitary and multiple, are now sufficiently numerous to establish the existence of adenoma as a local disease; and I have no doubt in my own mind that Birch-Hirschfeld is in the main correct when he says that both forms of adenoma (the hepatic cell and tubular) pass without any sharply-defined boundary into corresponding forms of cancer—on the one hand by an atypical development of the gland cells, on the other by a similar process in the epithelium of the biliary ducts; subject always to the qualifications I have before expressed—that in the process of tumour-formation the two parts of the gland do not always, nor can they be expected to, keep themselves quite distinct.

Primary Cancer.—But little need be added to what has already been said. So far as its carcinomatous nature is concerned, primary cancer is composed, like other soft cancers, of a light framework of fibrous tissue and vessels supplied by the hepatic artery, the two together forming alveoli which are full of cells which look like small liver cells. And such indeed they may often be said to be. At least transitional types of cells can often be traced between the liver cells which are healthy and those which form part of

* "Contribution a l'Histoire de l'Adenome du Foie," 'Arch. de Phys.,' viii., p. 622.

the alveoli of the growth. We must remember, however, that a large part of the process, so far as the hepatic cells are concerned, is one of simple atrophy. The spermatic influence being limited to certain centres; as these increase, the surrounding parts atrophy. Occasionally there is a coincident filling of the meshes of the interstitial tissue by small round cells, and the appearances thus produced are essentially similar to those seen in many cases of advancing cirrhosis. Nor is it always easy to determine what the relation of the two processes may be. On the one hand, we know that many actively growing and infiltrating growths enlarge by the production at their periphery of a small round-celled or indifferent growth, which is quite like the product of many purely inflammatory processes; we know, too, that some cancers—take those of the breast and sigmoid flexure, for example—are prone to produce much fibroid tissue, and as a consequence pucker or scar the diseased parts very considerably; and from this it may certainly be contended that the parenchymatous and interstitial changes are all parts of the same cancerous process, which in its most extreme form is represented by the contracting scirrhus to which I have already more than once alluded. On the other hand, upon grounds also already stated, the cancer may be the outcome of the chronic inflammation. Schueppel takes the former view, and perhaps it is the one which is the more orthodox.

Of other modes of origin of primary cancer it will be enough to say that growths are sometimes found in the common or cystic duct after the prolonged worry of gall-stones,* or in association with cancer at the head of the pancreas, and that under such circumstances the epithelium of the smaller ducts may participate in the excitement, and develop nodules in various parts of the liver (Pl. xxi., figs. 9, 10). It has further been suggested that some of the primary cancers of the liver may have an endothelial origin, and a melanotic endothelioma has been described by one observer.†

Secondary tumours of the liver are much more common than those originating *de novo*. A large number spread from the contiguous parts, probably by extension along the lymphatic tissues of the portal fissure; others, also numerous, are attributed to embolism. The variety met with in the macroscopic appearances is equalled, if not exceeded, in the microscopical details, and it is impossible to give a very detailed account of these. I shall say of them in general that what is true for primary cancers, with regard to the blending of a cancerous with a cirrhotic process, is even more applicable to secondary tumours, and the amount of fibrous tissue met with in some is so excessive as to lead to no little difficulty in forming an opinion of their nature. In others, again, large tracts of richly-nucleated tissue are found occupying the portal areas, and simulating the hypertrophic cirrhosis, of which we have already dealt in detail. Others, again, are mostly cellular, and of these some are epithelial, some sarcomatous, some mixed; some appear to form chiefly by growth within themselves, some chiefly by a transformation of the hepatic cells external to them; some start in the connective tissue, some in the nuclear elements of the capillaries, some in the epithelium of the ducts. There is indeed no one of the component structures of the organ which may not now and again take the chief part in the formation of the disease; there is no one, apparently, which may not combine with others, and the result is often—indeed generally—a complex structure which baffles dogmatic teaching. Tumours are in their results diseases of the organ, not of its ducts alone, or its parenchyma alone. By a rough rule the fibroid forms are generally cancers, the softer forms either cancers or sarcomata. The pigmented are usually sarcomata, and composed for the most part of round and spindle cells, which, besides being generally stained of a dark colour, are full of brown or black granules. Such tumours are largely composed of new-formed capillaries, which can be injected from the hepatic artery. There is indeed a certain amount of evidence that tumours of this nature start in some proliferative mania of the endothelium of capillary vessels.

Osteo-sarcomata, myo-sarcomata, chondromata, and gliomata have all been found in the liver, but a mention of their occurrence is a sufficient attention to such rare phenonema.

Lymphatic Tumours.

Under this head four conditions will be described:—1. The liver of leucocythæmia. 2. The liver of adenię, or lymphatic leukæmia. 3. The

* A chromo-lithograph of this condition will appear in the next Fasciculus, Plate xxiv., fig. 2.

† Block, 'Arch. d. Heilkunde,' xvi.

tubercular liver. 4. The liver of certain specific fevers, or the typhous liver.

1. The liver of leucocythæmia is large,—often very large,—its surface not abnormal, but its section showing often a pallor and hypertrophy of the lobules. Microscopic examination (Pl. xxii., fig. 18) shows extreme dilatation of the capillary vessels, crowding of their canals by leucocytes, and in the stroma and in all parts of the field clusters of similar corpuscles are congregated, and the liver cells are much atrophied. Some authors have asserted that the change next to be described as that characteristic of lymphatic leukæmia is also found in leucocythæmia, and I do not doubt that occasionally it is so; occasionally, too, the two conditions are combined. But the morbid appearances under the microscope in leucocythæmia are usually such, and such only, as I have described.

2. The liver of adenie, or lymphatic leukæmia (Hodgkin's Disease), is also much enlarged, smooth, and pale; but its section is studded with small grey points, which crowd the portal channels, and encroach upon the lobules; or the surface is minutely streaked with a more diffused grey material, which we may anticipate is a still more extreme degree of growth (Pl. xxii., figs. 7, 9). In rare cases the new growths may form yellow masses of considerable size, and thus produce such strangely abnormal appearances, as are depicted in Plate xi. The microscope shows in this case that a felted lymphoid tissue is infiltrating the liver in all directions: starting in the portal canals, it does not long confine itself to them, but converts the lobules into similar material; and, in so doing, raises the question we have had so much to discuss already—whether the hepatic cells do not take part in the disease. However, in one way or another a diffused growth, composed of a delicate network of connective tissue stuffed with leucocytes, pervades the liver in all directions, and before it the liver cells atrophy, or in some way disappear. It is a characteristic of this disease that, although the growth is quite like that of the next or tubercular form, it hardly ever undergoes caseation—although Plate xi. appears to be an instance of such a very rare occurrence.

3. Tubercle (Pl. xviii., fig. 3; xxi., figs. 5, 14; xxii., figs. 7, 9) is a morbid growth which is very common in the liver. It is best seen upon the surface by the naked eye as small grey grains showing through the capsule. These grains are more difficult to distinguish upon the section, unless large or numerous, because sections of the finer portal canals may be mistaken for them. Miliary tubercle to this extent occurs in many, if not in most, cases of general tuberculosis, and, as Rindfleisch remarks, is not of any practical moment. But tuberculosis of the liver is by no means confined to scattered tubercle. In many cases, particularly in children, there is a very extensive eruption of miliary tubercle (Pl. xxi., fig. 14; xxii., figs. 7, 9), the portal canals being crowded, and even the interior of the lobules studded. Nay, even more than this, it is by no means uncommon to find an extensive infiltration of the portal canals and lobular structure, when the disease, in the amount and nature of the growth, cannot be distinguished from the infiltrating pseudo-leukæmic form, except by the fact that the former does not tend so much as the latter to become caseous; and that, as noted by Murchison and Fagge,* it may be associated with febrile jaundice.

The histology of the tubercular liver does not require much comment; tubercle is the same here as elsewhere in the possession of giant cells and granulation tissue, and in its tendency to central caseation. It differs, I should say, but in this there is some difference of opinion—in that there is less tendency to the production of fibroid tissue than with tubercle in some other parts. It is the same here as elsewhere in the questions it raises as to its origin. Here, as elsewhere, there is the same difficulty in determining whether it starts in pre-existing adenoid tissue, in the nuclei of blood vessels, or some other source. In the more common cases, where the disease confines itself to scattered grains, the growth is found in the portal canals (Pl. xxi., figs. 5, 14); but in the more diffused forms of miliary growth, in which very early nodules may be found within the lobules, the appearances are very suggestive of a nuclear proliferation of some of the small capillaries, in the distribution of the hepatic artery. The hepatic cells for the most part suffer atrophy, and the extreme infiltrating varieties must produce serious consequences on this account, as the amount of destruction of the hepatic cells is very extensive. In some cases of this kind I have seen appearances which suggested that—here, too, as in so many other forms of hepatic disease—the hepatic cells are liable to participate in the hyperplasia (Pl. xxii., fig. 9).

* 'Guy's Hosp. Rep., xxv., p. 162.

Tubercle very seldom forms masses of any size in the liver, but it occasionally does so in children; and in this case the organ may be studded with caseous nodules (Pl. xviii., fig. 3), perhaps 1-8th to 1-4th of an inch in diameter, with central ragged bile-stained cavities. More rarely cheesy masses may be met with of half an inch diameter or more. These masses have been supposed to be due to a development of tubercle around the bile ducts, chiefly from the fact that they so generally contain bile. But the evidence is hardly sufficient to support the view that there is a special tubercular affection of the biliary passages. It is probable that these softening cavities are caseating tubercles of extraordinary dimensions, situated as usual in the portal canals, and that in softening some of the finer bile ducts suffer destruction and discharge their contents into the cavity produced.

4. The Typhous Liver. In the course of certain specific fevers—enteric, scarlatina, measles, small-pox, &c.—small tubercle-like grains and sometimes more diffuse infiltrations* are prone to occur in the portal canals, and in the intra-acinous connective tissue. The earliest distinguishable stage is the collection of granulation cells with large nucleus between some of the hepatic cells or in the portal canals, and as with tubercle, which they exactly resemble, so with these, it is difficult if not impossible to say whether they are products of the capillaries or of the lymph channels outside them; and it will be evident from the description that they are not easily distinguishable from the earlier stages of miliary abscess, which perhaps with further investigations into the pathology of micrococci they may ultimately prove to be. At present they are looked upon as lymphomata, from their likeness to tubercle.

Cysts.

Solitary cysts containing serous fluid are not uncommon in the liver, and although their origin may no doubt be from various sources, they are most commonly to be attributed to dilatation of one of the biliary ducts. These are well known to lose all trace of biliary contents after a certain period of retention, and to be occupied by a thin mucous or serous fluid. Cysts of this kind are not often of much practical importance, but they may originate near, or make their way to, the surface by atrophy of the superjacent hepatic tissue; and they then very occasionally attain a large size, and may come to simulate hydatid cysts, or even other abdominal tumours. A remarkable case of this kind is recorded by Dr. Cousins in the 'British Medical Journal,' 1874, vol. ii., p. 700, and the specimen itself is preserved in the Hunterian Museum of the College of Surgeons, N.N. 2758, O.N. 1399A. But the affection which is of most interest is a true cystic disease of the liver (Pl. xix., and Pl. xxii., figs. 4 and 5). Instances of this kind have been described by Rokitansky, Wilks, Bristowe, and others; and they have been shown to be associated with a similar disease of the kidneys. Both liver and kidneys are studded throughout with cysts of all sizes, from the minutest microscopic cavities up to those of one or two inches in diameter. They have thin fibrous walls, which are perfectly smooth, and they contain a simple serous fluid. They have been submitted to careful microscopic examination chiefly by English observers,—Bristowe, Beale, and Pye Smith ('Trans. Path. Soc. Lond.,' vols. vii., x., xxxii.),—and in all cases the conclusion has been arrived at that the cysts are formed by a process of vacuolation in the hepatic cells (Pl. xxii., fig. 5). I had an opportunity of examining Dr. Pye Smith's case,—the latest recorded, and from which Plate xix. and the figures on Plate xxii. are taken,—and came to a similar conclusion; but, as Dr. Pye Smith remarks in his report of the case in the 'Transactions of the Pathological Society of London,' there is a certain amount of cirrhotic change in the portal canals, and I think an unusual quantity of non-striated muscle also (Pl. xxii., fig. 4); and some might be disposed to take the view that the cysts originate in dilatation of the minute bile ducts. It has never been possible to inject the cysts by way of the hepatic ducts, but I doubt if any weight can be attached to a fact of this kind, which can hardly have been confirmed by any sufficient number of experiments; and, had it been so, cystic dilatations of the finer ducts would not necessarily allow of their penetration by injection. And no doubt the duct origin affords the easiest explanation of the cardinal fact—that the kidneys and liver suffer together. Both in the kidney and in the liver there is an excess not only of fibrous tissue, but also of muscular tissue—in the portal canals in the one,

* Very good figures of these are given in A. Thierfelder's 'Atlas,' Pl. xvii., figs. 1, 1 *a*.

in the intertubular stroma in the other. The cysts in the kidney in these cases are certainly tubal cysts. Therefore there is a certain amount of *primâ facie* evidence in favour of a duct origin for those in the liver. Nevertheless this is not the view taken by either Beale, Bristowe, or Pye Smith, and I think, with others, that the microscopical appearances suggest that the cysts originate in a process of vacuolation in the hepatic cells. Dr. Pye Smith considers the associated renal cysts to be an altogether independent condition; but I do not feel able to accept that conclusion, for the reason that, when there is cystic disease of the liver, the kidneys are so commonly found cystic too, as to constitute an insuperable objection to any mere accidental association. And as I reject the dilatation theory for the one organ, so does microscopical examination suggest that it may possibly be necessary to reject it for the other. The cysts in the kidney are probably not the result of simple dilatation. There is evidence to show that cyst formation is in progress from the tubal epithelium. If so, one is strongly tempted to surmise that both in the liver and the kidney the process is one of those aberrations of function threatening, but stopping short of, some new growth, such as is seen in some of the multilocular cysts of the ovaries and cysts in other glandular organs. The results being arrived at by different steps according to the custom of each—in the one case by vacuolation, in the other by changes in the walls of the tubes.

One other form of cystic disease requires mention, a very remarkable specimen of which is preserved in the Hunterian Museum of the Royal College of Surgeons, Old No. 1396 A., New No. 2747. The disease is associated in this case with cirrhosis, but the change is in great part a diffused cystic disease, giving the section more the appearance of cavernous tissue. Dr. Moxon appears to have met with a similar condition, and he and I appear equally to have been in doubt whether the appearance might not have been produced by post-mortem decomposition, which, in hot weather and with a rapid formation of putrefactive gases, produces a disruption of the hepatic tissue, and converts it into a number of minute cysts.

Hydatid Disease.

Hydatid disease is more common in the liver than in any other organ, and in its right lobe than elsewhere. This is attributed to the fact that the larvæ escape from the intestinal canal, into which they are taken with the food, by penetrating some of the radicals of the portal vein, and by means of which they are carried to the liver. It is commonly found as a single cyst, which may be of any size, embedded in a fibrocellular capsule formed out of the wasted indurated or inflamed hepatic tissue. The cyst-wall proper is composed of an elastic, transparent, gelatinous membrane, which consists of two parts—an outer thick and composed of delicate parallel laminæ of structureless material, the inner thin and cellular. The contents vary. The cyst may be living, but barren, when it is filled with a limpid colourless fluid of low sp. gr. 1010; or it may be sanded over with the small scolices budding from its walls; or contain numerous attached or separate daughter cysts,—some fertile, some barren,—and full of fluid like the mother cyst; or it may be dead, and full of purulent fluid provoked by the irritation of its presence in the liver, or by the tapping of the ducts and escape of bile into the cyst in the course of its growth; or the fluid may have been all absorbed, and a solid gelatinous mass alone remain, formed of the laminated and convoluted remains of the collapsed and contracted cysts. Sometimes it is converted into a cheesy or chalky residual mass by degenerative changes, with orange-coloured bile pigment here and there, showing that the parasite has been long dead.

The appearances of the scolices are sufficiently well known as hardly to need description. The rostellum or snout surrounded by its double ring of hooklets, and, below these, four suctorial eminences or depressions, as the case may be.

The peculiar indestructibility of the chitinous hooklets of the echinococcus should be remembered for diagnostic purposes, as they may be found entire or in fragments in many calcareous or caseous masses, the nature of which would otherwise be doubtful. It is further all-important to remember that the fluid in a hydatid cyst contains salt, and, according to Lücke, grape-sugar—but not albumen.

Other forms of hydatids are described, but they are much more rare. One is the echinococcus exogenus, in which the daughter cysts bud outwards instead of inwards, and thus form pedunculated masses like the hydatinniform degeneration of the placenta; another, the echinococcus

multilocularis, which was originally considered to be colloid cancer of the liver, from the fact that it possesses an alveolar structure, many of the spaces or cysts communicating with one another.

Hydatids undergo, probably not infrequently, spontaneous cure; and this is brought about sometimes by the unyielding nature of their envelope, which prevents the expansion of the cyst and checks their growth; sometimes by the formation of fatty *débris* in excess within the cyst; sometimes by suppuration external to the cyst; sometimes by the penetration of the cyst by bile from some of the ducts which have become laid open in the course of the growth of the parasite.

As regards the host, hydatid disease is chiefly concerned in producing suppuration in the liver, or in hampering other organs by its size, or by ulcerating into them. The cyst may make its way thus into the lung, pericardium, pleura, peritoneum, bowel, or vena cava. Rupture into the peritoneum or opening into the pericardium and vena cava are consequences most pregnant with evil for the patient; and another serious but fortunately rare complication is the opening of one of the main ducts, and the escape of some of the smaller cysts into it. "Great pain, jaundice, and death are the almost constant results."* One case is, however, on record where cure was effected by this means.†

It would further appear that the symptoms differ with differences in the form of the parasite —the multilobular variety being prone to be associated with icterus and with swelling of the spleen.

For other parasites, since they are either very rare or of little importance, a passing mention may suffice. The cysticercus cellulosæ is occasionally found; the distoma in its various forms, and pentastoma likewise. The latter is usually found close to the surface as a small yellow crescentic mite enclosed in a thickish grey connective tissue capsule, the whole not larger than a pin's head.

The occasional presence of thread-worms or the ascaris lumbricoides in the biliary passages may also be noted; and finally, small oval bodies, said to belong to the gregarinidæ and denominated psorosperms, have once or twice been found.

* Wilks and Moxon, *op. cit.*, p. 460.

† Birch-Hirschfeld, *op. cit.*, p. 962.

Malformations.

Malformations and anomalies in the position of the liver are usually included in summaries of diseases of the liver, but they are hardly within the scope of the present *résumé*. It will therefore be sufficient to mention that the viscus may be transposed from the right side to the left when the other viscera are likewise misplaced; and that it may be altered in shape in various ways by the loss of some of its lobes or the addition of others. Transposition is the most important malformation (excluding absence of the ducts), as its recognition may sometimes help to determine the nature of an associated and perhaps otherwise obscure disease of the heart.

Injuries.

Rupture of the liver is very common, and may be met with in all degrees. It is usually due to direct violence to the abdominal wall, and occurs as one or more cracks or fissures through the capsule from side to side on either upper or under surface. Ruptures are usually fatal, either by themselves, from the hæmorrhage to which they give rise, or in combination with serious injuries of other viscera. But slight fissures may heal.

Such serious injuries as lacerations through the whole thickness of the right lobe, or tearing away of its attachments and through the inferior vena cava, sometimes occur. It is needless to say that such lesions are certainly fatal, but it is occasionally a matter of wonder how life can be prolonged—as it sometimes is—for some hours after such an accident.

DISEASES OF THE PORTAL VEIN.

We have next to deal—and very shortly—with the second part of our subject, viz., the diseases which more especially affect the trunk of the portal vein or its main branches. Of chief importance are—simple thrombosis; adhesive pylephlebitis; suppurative pylephlebitis; compression from new growths outside it; and tumours, usually called in common "cancer." Of less importance are—atheromatous and calcareous changes in the walls of the vein; dilatation; and the presence of parasites, or even an occasional gall-stone in the vein. Of these I shall be content with this bare mention.

Simple thrombosis is, usually speaking, a late result of cirrhosis of the liver or of some disease,

such as perihepatitis, which obstructs the passage of the portal blood; but it occasionally occurs spontaneously, it has been said, in weakly persons; but it is impossible to suggest a cause in all cases. Sometimes it appears as if clots having formed in some of the radicles of the vein become dislodged, and occlude the main trunk by embolism; sometimes starting in some of the mesenteric radicles or in its main tributaries from spleen or stomach, from inflammatory or other causes, the clot gradually extends till it reaches the main trunk.

The appearances of the vein will naturally vary, according to the time during which the coagulation has been going on. Sometimes the trunk is distended and completely occluded by a clot of large size, and more or less firmly adherent to the wall of the vein; sometimes only its hinder wall is covered with a flattened adherent decolorising clot; and sometimes, again, the vein is not only completely occluded, but the clot within it has undergone more or less organisation, or some degenerative changes in its more central parts; in cases of very old date the portal vein may be lost in a cord of uniform fibrous tissue. Adhesive pylephlebitis is sometimes described as a condition distinct from this. It is quite possible that in syphilis—congenital and other—some periphlebitic or even phlebitic changes may occur independently of any primary clotting, but this and the late stage of thrombosis can hardly be distinguished for any useful purpose. A common result is brought about by varied causes. Although it is as well to bear in mind that the complete organisation of a thrombus—or perhaps to avoid disputable ground, the complete conversion of the portal vein into a fibrous cord by means of a thrombus—is not a common occurrence, as death usually comes about from one cause or another before the changes mentioned have become thus complete.

Results to the Liver.—These appear to be various. Obstruction of the trunk of the portal vein, with a previously healthy condition of the liver, is probably in most cases speedily fatal, and no effects are visible in the liver. When it occurs—as is most common—at a late stage of cirrhosis, although it may not be then so speedily fatal, again for obvious reasons no special effects are visible. But when it occurs spontaneously,—meaning by that, when it is unaccompanied by cirrhosis,—and the patient survives, some difference of opinion appears to exist as to the probable consequences. Murchison states that it leads to atrophy of the liver. Cases are on record* where it appears to have induced cirrhosis of the liver. Frerichs has described and figured a peculiar lobulation of the liver from atrophy of the hepatic parenchyma, corresponding to obliterated branches of the portal vein;† and there is a certain amount of experimental evidence from ligature of the portal vein in the lower animals, which seems to support the conclusion that cirrhosis is a probable consequence of the plugging. But it appears to me that this conclusion must be accepted with considerable caution. In the first place, the experimental evidence is of very doubtful value: a ligature placed round the vein in the loose connective tissue natural to the part is a very different thing to a clot within the vein, and much more likely to induce cirrhosis than at any rate some forms of clot. 2ndly, it is hardly a valid argument to say that, because thrombosis of some of the branches of the portal vein within the liver induces the atrophy and lobulation accredited to it, therefore obstruction of the main trunk will do likewise. The conclusion arrived at would be anything but sound, if in like manner it were argued that, because plugging of a small branch of the pulmonary artery produces pulmonary infarction, therefore complete obstruction of the main trunk would produce visible and similar effects throughout the whole organ. Complete obstruction of the main trunk of the vein so completely disarranges the circulation, as compared with the minor change, that it is only possible to forecast the future by the light of the past; and it may be questioned whether there is any sufficient evidence to favour such an opinion as that in any case of portal obstruction cirrhosis will probably follow. Five only of such cases appear to be on record, showing the rarity of the occurrence; yet thrombosis of the portal vein is not uncommon.

My own experience of portal thrombosis, all told, comprises thirteen cases, and, as hitherto unutilised, it may be as well to add it to the already not very extensive literature of an interesting subject. In five of these the thrombus was of old date—four of them being cases of organised thrombus. Dealing with these first, one appeared to have originated in an ulceration of the cœcal appendix, and to have led to a suppurative pylephlebitis, from which the patient

* According to Dr. S. West, at least five such are extant. 'Trans. Path. Soc. Lond.,' vol. xxix., p. 112.

† 'New Syd. Soc.,' vol. ii., p. 396.

had ultimately recovered;* the liver in this case being scarred with local fibroid patches in the seats of former inflammatory foci or abscesses, but not showing any generalised cirrhosis. A second was associated with intestinal ulcers: the liver was tough, and some of the portal canals were thickened, but there was no appreciable cirrhosis by microscopic examination. The third case was a woman, æt. 42, under Dr. Wilk's care, suffering from phthisis, aortic disease, and ascites; the inspection was made by Dr. Barrs, and the case is of interest as being a typical example of the lobulated atrophy described by Frerichs. The liver was only twenty-eight ounces in weight; its surface extremely irregular, due to the presence of numerous distinctly pedunculated lobules, especially about the left lobe. The capsule was studded with scars and depressions. On section of the liver, the tissue was quite healthy in appearance, but it was traversed in all directions by dense fibrous bands and masses of almost cartilaginous density.

The liver altogether presented more the appearance of advanced syphilitic disease than that of an ordinary cirrhosis, but there does not appear to have been any other evidence of syphilis either in the liver or elsewhere. The portal vein for some distance into the mesentery and also throughout the liver, was entirely blocked by an old fibrinous clot. In the fourth case the liver was undoubtedly cirrhosed. The patient was a woman, aged 48, under Dr. Frederick Taylor's care; she was said not to have indulged in liquors, and her illness began with pleurisy. The portal vein was entirely plugged by adherent decolorising clot. It is possible that here we have a case of cirrhosis induced by the thrombosis; though I am disposed to think that, although the clot was of considerable date, it was hardly of age sufficient to explain so advanced a change in the liver, and consequently should regard the case as an example of the commoner condition—thrombosis consequent upon cirrhosis, The last of the five was a man who some months before his death had suffered from a severe illness associated with abdominal pain. The portal vein was completely obliterated by very old organised clot, and the liver, except showing adhesions on the surface, was free from any disease whatever. In four other cases the obstruction was caused by disease outside the vein—three times from cancer of the stomach, once from an ulcer of the duodenum. In all these the thrombus was in all probability eight or ten weeks old, but the liver showed no cirrhotic changes.

In the four remaining cases the clot was recent—being associated with emphysema of the lungs, and a "nutmeg" state of liver once; once with gangrene of the leg and systemic thrombosis; upon which it may be remarked that other cases are on record in which thrombosis of the inferior vena cava and portal vein have been associated, as if the portal circulation suffered from interference with the freedom of circulation through the lower part of the inferior cava. The other cases were examples of ulceration of the cœcal appendix, and suppurative pylephlebitis, with thrombosis.

From these facts, then, it would appear that the question of relationship between portal thrombosis and cirrhosis must still be considered a very open one; and it may not unreasonably be surmised that while most cases, where the two conditions were combined, which could not be properly explained by a pre-existing cirrhosis, have been placed on record, those cases in which the thrombosis has existed with a normal or at most somewhat small liver, being less striking and less uncommon, have not been recorded.

The symptoms of portal thrombosis, when any at all exist, are ascites to an immoderate extent, and sometimes hæmorrhage from the stomach and intestine; and corresponding with the latter symptom we occasionally find in cases of this kind that there is extreme congestion of some part of the small intestine or colon, sometimes œdema; sometimes even a severe form of enteritis.* The spleen is also generally enlarged.

Suppurative pylephlebitis is almost invariably due to some ulceration or suppuration in the abdomen,—in the area, that is, from which the portal vein draws its supplies. This may be in the cœcum or its appendix, as is most common; or from ulcers in any other part of the intestine; from ulceration about the stomach or round the gall bladder or the bile ducts; sometimes from abscess in or about the spleen, and so on. The inflammation, whenever it spreads to the wall of some radicle of the portal vein, produces a local phlebitis and thrombosis, which gradually spreads upwards towards the main trunk; or

* 'Trans. Path. Soc.,' vol. xxxii., p. 137.

* For an illustration of this, see "A case of Acute Thrombosis of the Superior Mesenteric and Portal Veins, attended with rapidly Fatal Collapse," by Dr. Hilton Fagge. 'Trans. Path. Soc. Lond.' 1876, vol. xxvii., p. 124.

more commonly the clot softens in the centre, becomes purulent, and is carried away in fragments to the minute branches in the liver, producing the multiple abscesses that have already been described.

Suppurative pylephlebitis may occur at any age, and has been found in newly-born infants spreading from the umbilicus backwards to the main trunk of the portal vein.

But little need be said of other affections of the portal vein; it is well known that the walls of veins in general are very prone to become infiltrated by new growths of all kinds, and that the lumen of a vein is often narrowed by the projection inwards of cancerous polypi. The portal vein is no exception to this rule; and it is quite common, if only careful search be made, to find that infiltrating tumours in any part of the abdomen may thus involve its branches, and produce as the result secondary tumours in the liver.

Primary cancers of the portal vein have been described, in which the vein has been filled with a new growth, and no other part of the body affected; but of this condition we have no knowledge, and the difficulties in the way of *excluding* for certain all possible primary sources must always leave a doubt about the real nature of such cases.

The diseases of the gall bladder and bile ducts will follow with the next Fasciculus.

APPENDIX.

THE LIVER OF PHOSPHORUS POISONING.

This case has already been published by Dr, Capon in the 'Lancet,' vol. i., 1882; but the following microscopical description is a little more full, and it could not be conveniently embodied in the text:—

Death occurred on the ninth day.

Liver.—Under a low power the structure of the liver was still readily recognisable, and in this the specimen differed from slides of three cases of acute yellow atrophy that I have in my possession. The hepatic cells were present in many parts in large numbers, and had their natural trabecular arrangement. The columns were abnormally separated by dilated blood or lymph spaces, and the individual cells were cloudy and ill-defined.

The portal channels were everywhere characterised by a crowd of small nuclei, which stained with logwood readily. The epithelium of the smaller ducts was cloudy, and blocked the tubes in many cases.

Under 1-5th in. the hepatic cells were exceedingly ill-defined in outline, and full of granules, and even of drops of oil; but in many parts, even where the cells themselves were hazy, the nucleus was still fairly visible. It appeared that—in opposition to what others have described—the nuclei of the cells had in great measure resisted the degenerative process. The changes in the cells were uniform for each lobule, but some lobules were more affected than others; indeed in some parts the hepatic cells had entirely disappeared, leaving only a trabecular network behind of blood vessels and lymphatics; but even here the lobular arrangement was not interfered with, and the portal channels and bile ducts were distinguished with ease. The blood-spaces between the cells were empty, and the liver appeared very bloodless.

The portal canals were uniformly studded with small round nuclei or cells, which were in part—and it might be said in great part—due to increase of the connective tissue or to a cirrhotic process; but it is more probable that they were due to migration from the blood vessels, because they were so uniform in size, and the hepatic cells and connective tissue in their neighbourhood were undergoing no change in the way of growth whatever. No fatty change in the vessels could be detected, but some of the smaller biliary ducts contained cloudy albuminous material, and their nucleation was distinct. No retained biliary pigment was visible.

The *heart* was remarkable for the extreme disappearance of the striation, the muscular fasciculi showing pale hyaline bands, with the nuclei of the sarcolemma well-defined, but no trace of striation and no fat; but the latter may have disappeared in preparation.

AN

ATLAS OF ILLUSTRATIONS

OF

PATHOLOGY

COMPILED (CHIEFLY FROM ORIGINAL SOURCES)

FOR

THE NEW SYDENHAM SOCIETY.

FASCICULUS V.

DISEASES OF THE LIVER

(CHIEFLY OF THE GALL BLADDER AND LARGER BILE DUCTS.)

(PLATES XXIII. TO XXVI.)

WITH

PATHOLOGICAL SUMMARY BY DR. GOODHART.

LONDON:
THE NEW SYDENHAM SOCIETY.
1883.

AGENT—H. K. LEWIS, 136, GOWER STREET, W.C.

A RÉSUMÉ

OF OUR PRESENT KNOWLEDGE OF THE PATHOLOGY OF THE

DISEASES OF THE LIVER

(GALL BLADDER AND LARGER BILE DUCTS).

By JAMES F. GOODHART, M.D.

In the Fourth Fasciculus a résumé of the present condition of the pathology of hepatic diseases was given, so far as two of its subdivisions are concerned, *viz.*, those diseases which affect the parenchyma of the liver, and those of the trunk and main branches of the portal vein.

The diseases of the *gall bladder and of the larger bile ducts* were reserved for the present time. I say of the larger bile ducts because it will be remembered that the morbid changes which have been observed in the smaller ducts and biliary capillaries are so intimately associated with changes in the hepatic cells that it is impossible to describe those of the one without treating somewhat fully of those of the other. And indeed, apart from such as have already been discussed, there are no burning questions which necessitate any lengthy description of the diseases we now have to consider; and what follows is rather a short summary of the facts of morbid anatomy than a résumé of any recent advances in pathology.

Acute Inflammation and Membranous Inflammation. — These are both very rare forms of disease. I have met with the former in association with gall stones. Dr. Moxon speaks of it as having been present also in cases of acute yellow atrophy; and membranous inflammation is stated to have been found in the continued fevers (Rokitansky), cholera, pyæmia, and other conditions. The gall bladder is also liable to acute inflammation in various parts of its surface, to acute membranous inflammation (a figure of such a case is given in Lebert's Anat. Pathologique, pl. 124), and to acute ulceration, the latter sometimes leading to spontaneous perforation of the bladder and acute peritonitis. Frerichs alludes also to cases of acute ulceration of the ducts, recorded by Andral and Dance; Murchison to a similar state of gall bladder in typhoid fever, as recorded by Andral, Jenner, and Trousseau.

Suppuration of the gall bladder appears to have been found under conditions similar to those which have produced membranous inflammation. And it would appear to be especially frequent in typhoid fever. Frerichs mentions such cases, and Murchison alludes to some recorded by Andral, Louis, Budd, and Rokitansky, as well as others in his own practice. Similar ones are to be found in the records of Guy's Hospital. The more common cause is the presence of a gall stone.

Suppuration of the ducts is in like manner most often caused by the inflammation set up by gall stones. Occasionally, however, it arises by the escape of hydatids into them or from the presence of a round worm. The pus may be retained in the ducts or in cysts formed by the dilated ducts; or make its way into the hepatic parenchyma, and thus produce ragged or reticulated abscesses. Some think that a simple catarrhal jaundice may become converted into a suppurative inflammation of the ducts, but unequivocal cases of this kind are very scarce, and there are no sufficient facts upon which to form an opinion.

Catarrhal Inflammation.—Is said to be common, but it gives little indication of its existence to the morbid anatomist. There may be some redness and swelling, or œdema of the common

duct, and an excess of mucus in the channel; but I do not remember ever to have satisfied myself of more than an occasional excess of mucus. The condition is one of importance, however, because it is made to do duty as an explanation of a large number of cases of jaundice. Given jaundice in young people without any symptoms of colic, and terminating spontaneously in a short time, and it is called catarrhal jaundice; and the mind's eye is carried to the duct, and pictures some swelling at its orifice in the duodenum, or mucus lying in its canal. I must say that, having regard to the force which is exerted in some way or other—be it by the accumulation of bile behind, or by the coats of the ducts—in the expulsion of gall stones, it seems at first sight improbable that mucus or simple swelling of the mucous membrane should cause a sufficiently prolonged obstruction to lead to a jaundice of four or five weeks' duration, even allowing the bile to be secreted under such low pressure that a very slight obstruction is sufficient to cause temporary jaundice. However, it is very generally believed by the best observers that catarrh of the ducts is a fertile source of jaundice, and further, the doctrine of catarrhal jaundice is ever enlarging its boundaries, and now-a-days is applied even to the smallest ducts, a catarrh of which is held by some to be sufficient explanation of such conditions as the jaundice of fever, pyæmia, pneumonia, and so on. The liver of catarrhal jaundice is a large one, and the gall bladder and ducts may be dilated.

Chronic catarrhal inflammation is the result of obstruction by gall stones. As such in its uncomplicated form it may be associated with more or less dilatation of the larger ducts, and their distension by thin mucus; or the smaller ducts may either be obstructed by mucus or dilated into cysts (Plate XII., fig. 1). If the cysts are of any size they may contain colourless mucus; if there is a simple dilatation of the ducts they often contain an inspissated orange-coloured mucus.

The more extreme conditions of suppuration in the ducts, and stenosis or even obliteration of the larger ducts, are the result of a severe local inflammation and generally of ulceration, due to the immediate presence of a gall stone.

Dilatation of the biliary passages is due to obstruction, and generally to obstruction of the common duct. It may be of many kinds; sometimes, but rarely, it is a simple stricture,—that is to say, stricture for which no cause can be assigned. Sometimes—this also rarely—it is produced by a gummatous inflammation, with the contraction and displacement of the structures in the portal canals to which it gives rise. More often it is due to new growths, which start in the walls of the ducts, or spread to them from the gall bladder, the stomach or head of the pancreas, Plate XXV.*; or to the impaction of a gall stone in the duct. Parasites, too, whether the echinococcus, or the liver-fluke, or the round worm, must be remembered as occasional causes of obstruction, and therefore of dilatation of the ducts.

With regard to syphilis, it must be added that an obliteration of the ducts in the portal tissue has occasionally been found in newly-born infants, which has been attributed to a syphilitic inflammation. Other cases of congenital occlusion of the ducts appear to be due to malformation, and have been described by Cheyne and Underwood so long ago as 1805,† and by various writers since, as showing an inveterate tendency to transmission by occurring in several children of the same family. It is however possible that such children may have all been exposed to some particular taint, such as that of syphilis for example, and thus the recurrence of similar disease in succeeding infants. There is no doubt, however, that malformation must claim many of the cases of congenital occlusion of the ducts, and the conditions produced vary. Dr. Wickham Legg thus describes the changes likely to be found: In some gall bladder and gall ducts are altogether absent. The gall bladder may be present, but the ducts changed into strings of connective tissue; or the gall bladder may be rudimentary. In another case, with a gall bladder and a cystic duct, there may be no hepatic duct; in another the ductus choledochus may be wanting, or dilated into a blind cyst, the duodenal aperture being absent.

While upon the matter of congenital occlusion, let me say that such conditions do not always prove so speedily fatal as might be supposed would be the case. One infant lived seven months, others six and five months; and some of those which have lasted longest have been associated with cirrhosis. From this fact has been drawn one of the arguments in favour of the occurrence of a biliary cirrhosis. What I would say upon this point is that some

* Two good woodcuts representing this condition are to be found in Frerichs, New. Syd. Soc., vol. i., pp. 140—143, figs. 22, 23. See also Lancereaux, Atlas d'Anatomie Path., Plate X., fig. 3.

† Wickham Legg, 'The Bile Jaundice and Bilious Diseases,' p. 632.

cases—Dr. Nunneley's, for example, which lived nearly seven months—are not associated with cirrhosis, and until we can dissociate simple congenital stenosis—that is, simple obstruction—from stenosis due to syphilis, and perhaps other inflammatory conditions also, which any one would admit are liable to produce cirrhosis, the case is not a very strong one in this direction.

Dilatation of the bile ducts and gall bladder sometimes exists without any evident reason. Dilatation of the smaller ducts in the liver may arise from various causes, such as the local pressure of new growths, the contractions of cirrhosis or of gummata.

The impaction of a gall stone in the common duct, which, as the commonest form of obstruction, may be taken to illustrate the results of occlusion or stenosis, leads to the following morbid changes: to stasis of bile behind the stone and to dilatation of the ducts. The stasis tells at first upon the main ducts, which become full of bile, and gradually dilate. As time goes on the biliary contents become replaced in the larger ducts by a thin, hardly coloured mucus. An analysis of fluid of this kind is given by Frerichs, in which bile pigment and the biliary acids were absent. The liver, at first normal in appearance, except that on section bile pours from the dilated ducts, undergoes enlargement and becomes of a more or less olive-green colour (Plate XII., fig. 2), the parenchyma being apparently soaked in altered bile; subsequently certain of the lobules may undergo a process of yellow softening, and both to the naked eye and to the microscope may present the characteristic changes of acute yellow atrophy. Dr. Moxon alludes to the fact that such cases are liable to die by coma, and thus emphasises the likeness they bear to acute yellow atrophy. No opinion, however, should be given without a microscopic examination of the softened parts, for I have several times met with cases of this kind suggesting yellow atrophy, but which on microscopic examination turned out to be only bile-stained liver cells in a state of fatty infiltration. Schueppel discredits the idea of any such atrophy occurring, but I have seen it once or twice. The olive-green liver shows but little under the microscope; the cells are compressed and small, and contain an accumulation of bile pigment, and there is more or less dilatation of the biliary capillaries.

As regards the larger ducts, it sometimes happens that they undergo a cystic dilatation, in which case the section of the liver is studded with numerous thin-walled cavities, which have no apparent connection with the hepatic parenchyma (Plate XII., fig. 1), and the latter is practically healthy. This condition is rare. It is more common to find a general dilatation of the main hepatic and common ducts, and towards its opening into the duodenum a stone impacted, or some irregularity of surface, or narrowing of calibre indicative of the former presence of a stone. Occasionally the duodenal orifice of the common duct is widely dilated from the recent passage of a stone. The amount of dilatation is sometimes enormous, the common and hepatic ducts being as large as or larger than the small intestine. *The ultimate condition of the liver in cases of chronic* obstruction has been the subject of much controversy of recent years. It has been asserted, as I have stated elsewhere (Fasc. IV., p. 9), that a peculiar form of cirrhosis is brought about by this means; but there is very little evidence of this. Frerich's statement that it "becomes reduced in size, and assumes a flabby and shrivelled character" (*op. cit.*, vol. ii., p. 472), is strictly correct. The liver may be somewhat indurated, as all viscera subject to compression are, but the amount of cirrhosis is insignificant.

In some cases the common duct and others are thickened by chronic inflammation, or narrowed by stricture, the result of ulceration. It is not at all uncommon to find, on making inspections, that the common duct is narrowed or scarred, or dilated, it is to be presumed from some cause of this kind.

Another result of impacted gall stone is suppuration of the ducts, which may appear as a generalised suppurative inflammation, or as local abscesses here and there. These abscesses are not always produced by direct extension along the ducts; the disease in the ducts may extend to the connective tissue around, and lead to a secondary pylephlebitis, the abscesses in that case being portal and not biliary. This result is particularly common perhaps in severe inflammation and ulceration of the gall bladder.

Upon the gall bladder the effects of calculi are somewhat different. As regards the concretion, it may be solitary or there may be many (Plate XXV.); the stone may be one large one, or there may be many small ones. In the one case the shape may be oval or pyriform; in the other the stones are polygonal from the number of facets upon their exterior. Again, the gall bladder may be closely contracted around the

stone or stones, or full of fluid,* the calculi being scarcely palpable from outside. Again, the relation of the mucous membrane to the stone varies: sometimes the calculi are contained in sacculi, sometimes there is a sort of adhesion between the two, the mucous membrane being closely applied to the stone, and only to be removed by peeling it away. The state of the mucous membrane varies much: it may be healthy; more usually it shows either irregular vascularity at certain parts, ulceration perhaps at others, or a more or less widely-spread villous condition. Sometimes there is pus between the mucous membrane and stone; sometimes a creamy-looking mucus; sometimes glairy mucus only; sometimes ropy bile. The condition of the mucous membrane at the neck of the gall bladder is often of peculiar interest. I have several times seen either ulceration or warty or cancerous growths corresponding exactly to an impacted gall stone. And here, as at the sigmoid flexure, or the pylorus, or on the lower lip, may be found evidence that new growths are liable to originate at seats of persistent local worry. Plate XXIV., fig. 2, is a good illustration of an acute inflammation of the mucous membrane of the gall bladder, and also of a warty growth or papilloma around an impacted gall stone, the latter having escaped. Plate XXV. also illustrates the results of gall stones and obstruction. The cystic duct was obstructed by a calculus, and has become enormously dilated, as well as, which is unusual, very much hypertrophied. As late results of obstruction of any kind, but most generally from gall stones,—as obstruction of other sorts is usually due to cancer, and therefore not long in running its course,—the gall bladder may be dilated, and contain thin mucus; it, like the ducts, very seldom contains bile when the obstruction has been prolonged. It may be closely contracted, or contracted and its walls thickened, or even calcified, and no cavity of any kind left.

The inflammation within extends to the tissues outside the gall bladder, and causes adhesions to the surrounding parts, and in this way fistulæ are formed, the ulceration extending through the gall bladder to the adjacent parts; it may be into the duodenum or colon, perhaps directly into the peritoneum, or by an abscess into the abdominal wall.

Gall Stones.—Are usually composed of colouring matter combined with lime in their centre, and cholestearine in layers externally. The carbonate and phosphate of lime enter into the composition of most gall stones, and the former may be present in large quantities. The nucleus is composed of pigment, carbonate of lime, and mucus as a cement. Rarely blood or a fragment of some parasite is found as a nucleus. They vary in colour; very minute and granular concretions are dark olive-green, being mostly composed of pigment; the larger ones are a speckled brown. They are soft and light, but do not float in water unless they are first dried. They vary also very much in size and number; if small, they may amount to thousands. They were very numerous in the case which formed the subject of Plate XXV., and in this plate the facets which form under such circumstances of mutual position or attrition are well shown. Gall stones are not uncommonly single, when they may be very large. An interesting question has been raised as to the size of calculi which pass along the ducts into the intestine. Schueppel believes that no calculus larger than a centimetre in diameter can pass the narrowed orifice into the intestine, and consequently that all larger stones have found their way thither by the formation of a fistula. It is probable that this view is, in the main, correct. The very large size of some gall stones which have been found in the intestine, and the absence in some of these cases of any symptoms of hepatic colic, and the not uncommon occurrence of biliary fistulæ, all make for this view. Nevertheless we must not be too dogmatic on such a point, when we remember the almost unlimited amount of distension some passages will undergo under gradual hydraulic pressure.

But it is well to remember that large stones are liable to perforate the fundus of the gall bladder and ulcerate into the duodenum; that in their passage they may do a good deal of harm, such as producing ulceration of the portal vein, or causing a peritoneal abscess or acute peritonitis; and that there are several cases on record where the size of the stone has led to intestinal obstruction, or to acute gangrene of the coats of the bowel at the point at which the calculus has lodged.

How do gall stones get into and pass along the ducts is another not uninteresting question. It used to be supposed that it was entirely a matter of muscular action; now, however, it is said that there is but little muscular fibre either in the cystic or common ducts, and that the passage

* Cruveilhier, Anat. Path., tom. 2, pl. 4, liv. 29.

onwards of calculi is effected by the vis a tergo of accumulated bile, combined with certain auxiliary forces derived from the muscular movements of vomiting and straining with the abdominal walls.

Gall stones are usually inhabitants of the gall bladder or the cystic or common duct; they are rarely found in the hepatic ducts.*

Biliary fistulæ are almost always due to gall stones, and are most common between the gall bladder and duodenum, the gall bladder and skin, or the gall bladder or the main bile ducts and the stomach† or colon; all others are very rare. They have been found connecting the bile ducts and the urinary bladder, and the ducts and the lung. In the latter case Dr. Dreschfeld has reported an instance of a gall stone in a cavity connected with some suppurating ducts beneath the centrum tendineum which had ulcerated through the diaphragm into the lung. The more common cause of a bronchial biliary fistula is the extension of a hydatid cyst from the liver to the lung.

Parasites are occasionally found in the biliary ducts. Hydatids and the ascaris lumbricoides are least rare; the two forms of liver-fluke (the distoma hepaticum and d. lanceolatum) are very so. All are liable to occasion serious disease, such as dilatation and suppuration; and the passage of the echinococcus cysts along the ducts has sometimes been attended with much pain.

New growths are not by any means uncommon in the gall bladder. They are more rare, but are occasionally met with in the bile ducts. In the gall bladder they may be papillomatous, as in Plate XXIV., fig. 2, or carcinomatous, as in Plate XXV., and of cancers, scirrhus, medullary, colloid, and villous, have all been found. Cancer of the ducts occurs as an ulcer or infiltration of the coats, most usually about the termination of the common duct in the duodenum; but I have seen it as an early epithelial growth in the smaller ducts of the liver (Plate XXI., figs. 9 and 10), when it was associated with a nuclear growth in the portal canal, which could not be distinguished from cirrhosis. The nature of the growth may vary, sometimes resembling columnar epithelioma, at others being carcinomatous (Plate XXI., fig. 11).

The seat of primary cancer in the gall bladder and bile ducts has been much discussed: is it epithelial or submucous?—but it is not a question of great importance. There is strong probability that local irritation plays a great part in the production of the disease, and, looking at the changes with which local irritation is associated on other epithelial surfaces and in gland tubes, &c., it is probable that the early changes may in one case be epithelial, in another sub-epithelial or submucous.

Secondary cancer, extending to the ducts from the stomach or pancreas and parts around (Plate XXVI.) is not uncommon. Two cases of fibroma of the gall bladder have been described and figured by Albers,* and with these may be mentioned a case recorded by Wilks and Moxon;† a child of four years, whose common duct was dilated to form a cyst as large as the child's head, and in its wall were crowds of pendulous growths of myxomatous structure in which were embedded numbers of non-striated muscular fibres.

Hypertrophy and dilatation of the mucous glands of the ducts have been observed in a remarkable case alluded to in the last fasciculus, as published by the late Professor Maurice Raynaud;‡ and it is worth while to note it again, if only to impress upon our minds the fact that there are such things as glands connected with the ducts, and that cancer of the ducts is supposed by some to originate in them.

Tubercle.—A tubercular affection of the bile ducts has been described in which the liver substance is studded with caseous nodules of various sizes, many of them with central softened bile-coloured contents. The existence of such a disease is beyond question; it is more common in children than in adults, and of its tubercular nature there is no doubt; but whether it is a parallel affection of the bile duct to that of the urinary bladder, ureters, and kidney is at present open to question. It may only be that when tuberculosis of the liver is more than usually diffused the tubercles in the portal canal become confluent and softened, and thus communicate with the ducts. The condition was described by Frerichs, and considered to be a tubercular infiltration of

* For a striking figure of this rare condition, Lebert's Anat. Path. may be consulted, pl. 125, fig. 6.

† Wilks and Moxon record the case of a man, long the subject of jaundice and hepatic colic, where the gall stone was ultimately ejected by vomiting (Path. Anat., p. 465).

* Atlas d. Path. Anat.

† Path. Anat., p. 465.

‡ Fasc. IV., p. 32; Arch. de Phys. Norm. et Path., 1879.

the mucous membrane. I have lately met with a case which at first seemed to be one of this kind. With general tuberculosis of the viscera the liver was studded with yellow nodules, in the centre of each of which was some orange-coloured inspissated bile, exactly like a softening tubercle, into which the bile had made its way; but a closer examination showed me that in every instance the bile issued not from a ragged- but from a smooth-walled cavity, and clearly the disease was not one of the mucous membrane, but of the connective tissue surrounding it.

Calcareous and fatty degeneration (Xanthelasma) are occasionally found in the ducts of chronic obstructive jaundice associated with dilatation.

Hæmorrhage into the ducts is occasionally found as the result of ulcers, and other less known conditions.

Malformations. — The gall bladder may be absent, and, as already said, congenital stenosis and occlusion of the ducts may be of this nature.

PLATE XXIII.

SYPHILITIC AND LARDACEOUS DISEASE OF THE LIVER.—From a married woman, aged 21, under the care of Dr. Habershon in Guy's Hospital. No history of syphilis could be obtained, but she had been addicted to drink, and had had one miscarriage. She had been ill for three months, and was admitted to the hospital for ascites and albuminuria. The liver weighed a hundred and thirteen ounces. Its surface was much defaced by old adhesions and puckerings, and in particular a thick cartilaginous scar extended across the centre of the right lobe. This was found to be continuous, with a large sulphur-yellow mass in the substance of the lobe, which is shown in the plate. This mass is composed of many smaller ones, and between and around these the pinkish grey colour represents the liver substance in a state of diffuse fibrosis. The posterior part of the lobe is deeply congested, and also lardaceous, as may be seen from the iodine staining at the upper part; and here also is shown the contrast between the lardaceous parts and other greyish areas which occupy much of the remainder of the surface, and which all of them are more or less circular and bounded by a zone of congested capillaries: one of these, in particular, is seen to the left-hand of the plate, below the capsule. Under the microscope these were found to be composed of a thick, felted, but caseating, fibro-cellular material, by no means free from lardaceous change; and in many parts active growth was found in the form of tracts of small round nuclei in a vascular fibrous network. From a drawing by Hurst.

W. Hurst ad nat. del.

PLATE XXIV.

FIG. 1. ABSCESSES IN THE LIVER.—From a woman, aged 33, under the care of Mr. Bryant in Guy's Hospital. She was under treatment for epithelioma of the rectum, for which colotomy had been performed a month before her death. The autopsy showed that ulceration had extended beneath the growth to the submucous cellular tissue, and to the veins in the neighbourhood. The liver is seen to be studded with small cavities, with yellow contents. They contained thick, non-offensive pus, and one or two were in close connection with branches of the portal vein. There were no special hepatic symptoms. For a fortnight before her death the suppurative fever was pronounced, the temperature sometimes reaching 105°. From a drawing by Hurst.

FIG. 2. PAPILLOMA OF THE GALL-BLADDER.—The gall-bladder and cystic duct are laid open, and at the neck of the former is seen a cluster of bulbous-ended papillæ. The mucous membrane of the gall-bladder is brilliantly injected. From a woman, aged 59, who died of diabetic phthisis. The liver weighed forty-five ounces; it was dark-coloured; its lobulation well-marked; but without evidence of any change of cirrhotic nature. Its ducts looked quite normal. They contained plenty of bile, and gave no indication of any gall-stone having passed along them. The gall-bladder contained two large calculi, with facets upon them, and two odd-shaped fragments, which appeared to have belonged to some other calculus. They did not correspond in the slightest degree to any part of the two calculi now present, but looked like fragments of a calculus which had undergone spontaneous fracture. At the neck of the gall-bladder the mucous membrane had formed a patch of thick bulbous-ended papillæ, white and fleshy looking. From a drawing by Hurst.

Fig I

Fig II

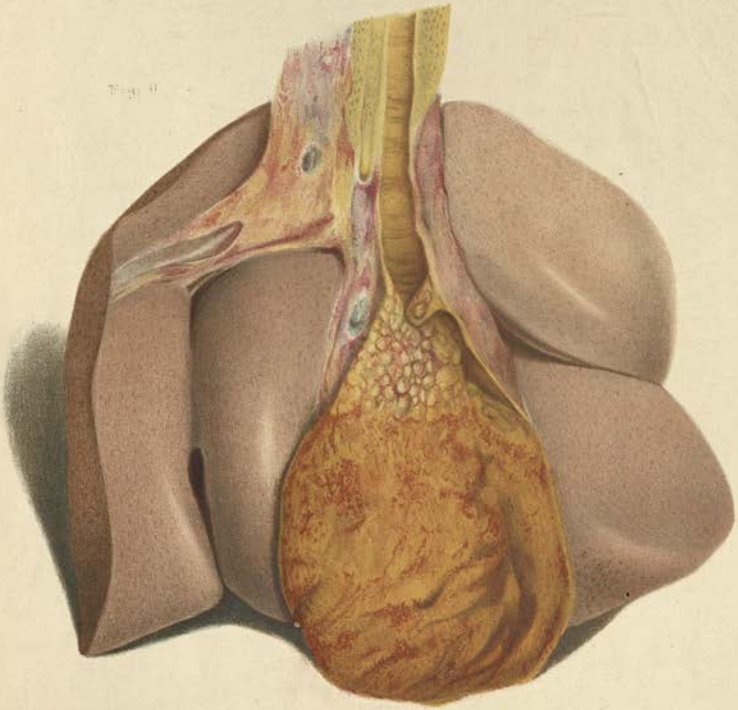

PLATE XXV.

CANCER OF GALL-BLADDER AND LIVER. GALL-STONES, WITH OBSTRUCTION AND DILATATION OF THE CYSTIC DUCT.—To the upper part of the plate is a part of the liver, with large nodules of new growth in it. Below and to the left is the gall-bladder, occupied in great part by a mass of new growth, now seen in section, and from its yellow tint undergoing extensive caseous degeneration. To the right is an enormously dilated cystic duct, and lying in it are a number of cuboid gall-stones. From a woman, aged 74, under Dr. Pavy, in Guy's Hospital. She had been ill for six months, and was admitted for jaundice, with an enlarged nodulated liver. The liver weighed eighty-eight ounces, and was very irregular, owing to the presence of numerous masses of malignant growth. The walls of the gall-bladder were much thickened by new growth. The cavity was about natural, but the walls being much thickened caused it to protrude as a tumour below the edge of the ribs. The cystic duct was hypertrophied and dilated to about the size of the transverse colon. It contained two hundred and forty gall-stones, and its entrance into the common duct was occluded, not only by thick mucous, but evidently till the time of examination by a gall-stone. From a drawing by Hurst.

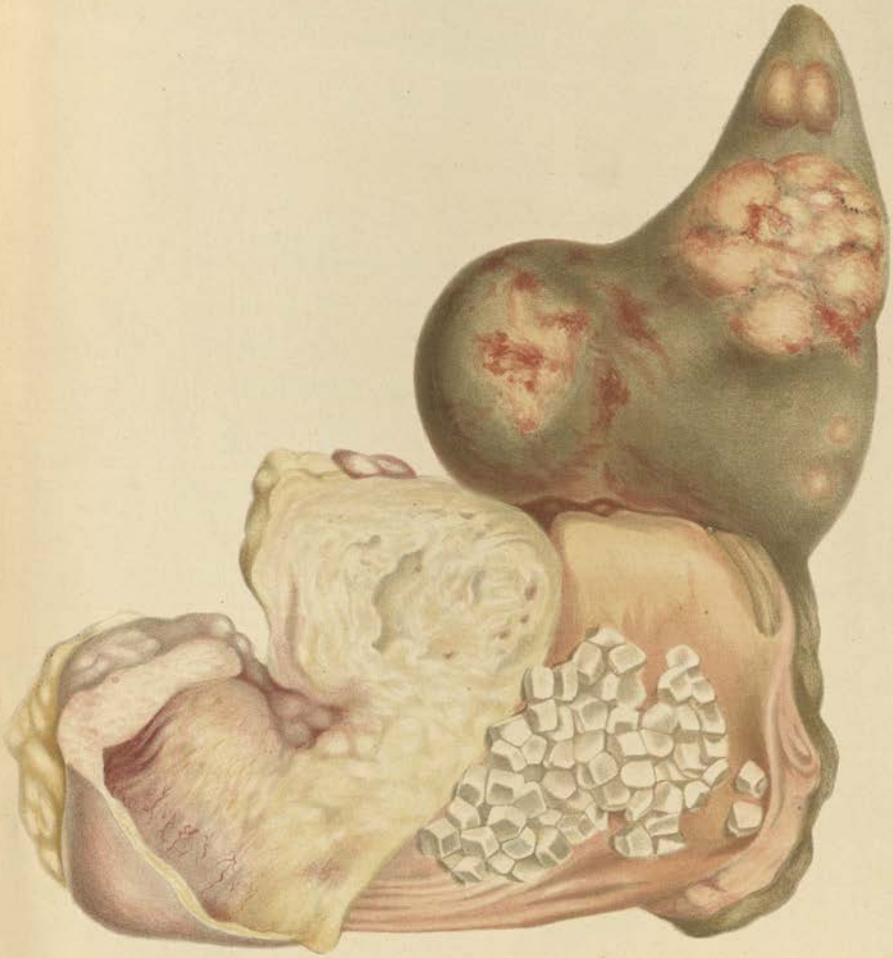

W. Hurst ad. nat. delin.

West, Newman & Co. chromo. lith.

PLATE XXVI.

CANCER OF THE STOMACH EXTENDING TO THE CYSTIC DUCT.—The under surface of the liver, with a part of the stomach and duodenum laid open. The gall-bladder is also laid open. Its neck and the cystic duct are surrounded by a growth, the common duct being unimplicated. The pyloric segment of the stomach is laid open to show thickening of its walls by colloid cancer. From a man, aged 46, under Dr. Pye Smith, in Guy's Hospital. He suffered from obstinate vomiting, and died of exhaustion. The pyloric third of the stomach formed a contracted tube, with walls much thickened by a grey gelatinous growth. In the neighbourhood of the pylorus the lesser omentum was thickened and puckered, and beneath it was a small nodule of cancer, which surrounded and infiltrated the neck of the gall-bladder. The liver contained miliary grains of secondary growth, but these are not seen in the plate. From a drawing by Hurst.

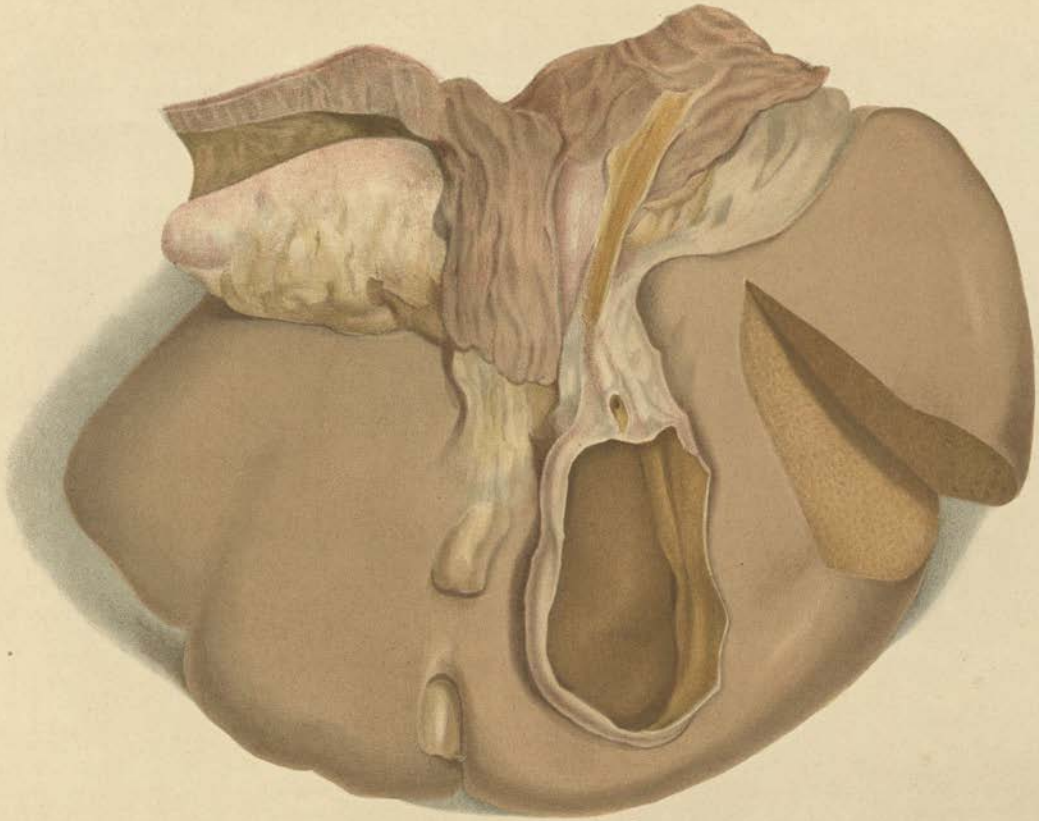

AN

ATLAS OF ILLUSTRATIONS

OF

PATHOLOGY

COMPILED (CHIEFLY FROM ORIGINAL SOURCES)

FOR

THE NEW SYDENHAM SOCIETY.

FASCICULUS VI.

HYDATID DISEASE OF LIVER.

(PLATE XXVII.)

URINARY CALCULI.

(PLATES XXVIII. TO XXXI.)

WITH DESCRIPTIVE LETTERPRESS, COMPILED BY JONATHAN HUTCHINSON, F.R.S.

(PLATES XXVII. TO XXXI.)

LONDON:
THE NEW SYDENHAM SOCIETY.
1888.

AGENT—H. K. LEWIS, 136, GOWER STREET, W.C.

PLATE XXVII.

PART OF A LIVER CONTAINING SEVERAL HYDATID CYSTS. To the right of the figure is a large cyst, from which protrude two flaccid daughter-cysts, with smaller cysts budding from their surfaces. Below and within the cavity of the parent cysts are globular cysts of various size. To the left is another cyst, laid open to show that it is filled with foliated membrane, the hydatid being dead. Above are other unopened cysts.

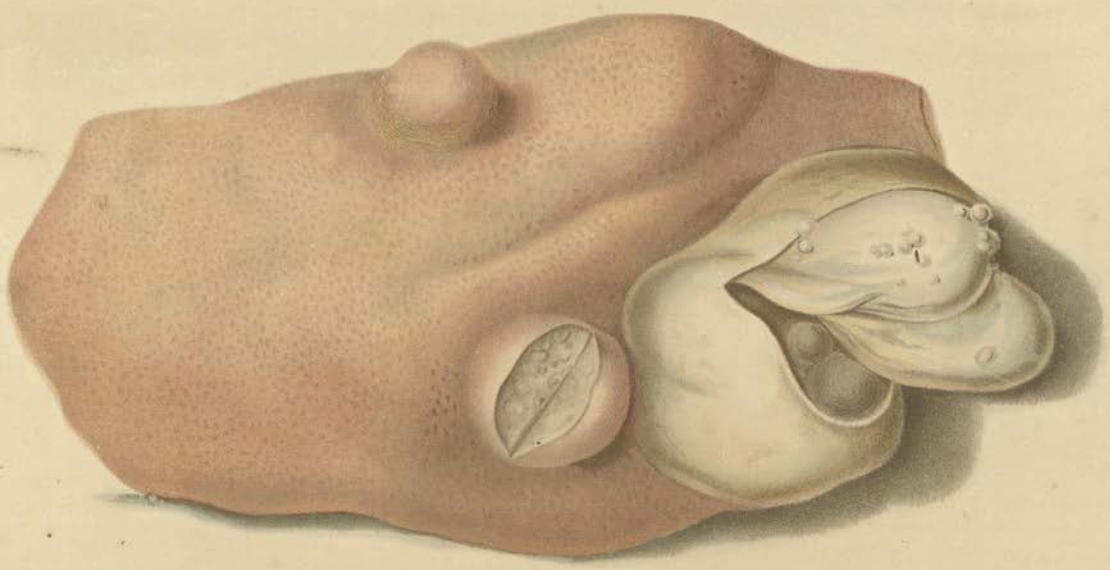

W. Hurst ad nat. del.

West, Newman & Co.ª chromo. Lith.

PLATE XXVIII.

(The descriptions of these Plates of Calculi are in most instances abridged from those given in the College of Surgeons' Catalogue.)

FIG. 1. Section of an ordinary large uric acid calculus, with a little oxalate of lime.

FIG. 2. Shows the polished, tuberculated, or granular, exterior which uric acid calculi sometimes present. [This stone was extracted by Cheselden, April 20th, 1737; it weighed 6½ oz., and in its greatest circumference measured 9 inches. It is on record that the operation was completed in half-a-minute.]

FIG. 3. Section of an uric acid calculus, largely made up of coarse crystals disposed in a radiating manner. It exhibits a granular semi-crystalline and non-laminated structure; its surface is rough and tubercular, and in the centre is seen a pinkish red colouring matter resembling the purpurate of ammonia.

FIG. 4. A calculus composed of uric acid and urate of ammonia, having a porous and non-laminated structure. It contains a little phosphate of lime.

FIG. 5. The nucleus and yellow layer are composed of small crystals of uric acid, the intervening part of this and the urate of ammonia, &c. This calculus (Hunterian) was extracted from a man, aged 70, at St. George's Hospital. The nucleus consists of nearly pure uric acid; upon this is deposited uric acid mixed with oxalate of lime, phosphate of lime, and urate of ammonia, which is surrounded by a layer of nearly pure uric acid, upon which is finally deposited a thin coating of the earthy phosphates.

FIG. 6. An uric acid calculus, having the same structure as that shown in fig. 3. A variety of the uric acid calculus which does not possess the lamellar structure, but consists for the most part of coarse granules or semi-crystalline deposit disposed in a radiating manner round the centre. It contained, as well as uric acid, a little oxalate and phosphate of lime, and its exterior was finely tuberculated.

FIG. 7. Shows the abrupt transition from uric acid to phosphates, the fusible compound not being in this instance preceded by the deposit of urate of ammonia.

FIG. 8. A calculus chiefly composed of uric acid, coated with a thin layer of oxalate of lime, which gives it the external appearance of a mulberry calculus (Mr. Lynn, 1827). The coloured part of the calculus consisted chiefly of urate of ammonia, with a considerable quantity of oxalate of lime on the exterior of the fusible phosphates.

Fig. II



Fig. III

Fig. IV

Fig. V

Fig. VI

Fig. VII

Fig. VII

PLATE XXIX.

FIG. 1. Section of an uric acid calculus from the kidney. "Taken out of Mr. Buxton's kidney, he having complained of it for 30 years." From Dr. Grew's collection.

FIG. 2. External view of the same.

FIG. 3. Section of a large calculus made up of three distinct uric acid stones, united by earthy phosphates.

FIG. 4. Section of a singular but not very uncommon form of calculus, the centre consisting of uric acid, the pinkish gray part of urate of ammonia and uric acid, the white layer at the sides of phosphate of lime.

FIGS. 5 & 6. Exterior and section of a cystic oxide calculus. The confusedly crystalline structure is well seen in fig. 6, which represents a section and the minutely tubercular appearance of its exterior in fig. 5. This calculus was removed after death from the bladder of a man, aged 21, a native of Northampton. He was too ill from disease of kidneys, &c., to admit of the operation, and died three weeks after his admission to Hospital. His bladder was much contracted and thickened, and where the stone lay it was ulcerated, the ureters were distended to the size of small intestine, and both kidneys, in addition to being distended, contained numerous small abscesses.

FIG. 7. A calculus almost entirely made up of uric acid and urate of ammonia deposited on a piece of steel, apparently the end of a stilet. The deposit of any other salt than the phosphates on a foreign body is most unusual. [Presented by Sir William Blizard.]

FIG. 8. The nucleus and exterior consist of uric acid and urate of ammonia, the intermediate layer of oxalate of lime.

FIG. 9. A calculus chiefly made up of oxalate of lime, having a nucleus of impure urate of ammonia, and a white layer chiefly consisting of phosphate of lime.

FIGS. 10 & 11. Section and exterior of a small uric acid calculus, thinly coated with urate of ammonia.

FIG. 12. Shows the crystalline centre and laminated structure of a very characteristic specimen of the pisiform, uric acid concretion. It was passed by the urethra.

Fig. I.

Fig. II.

Fig. XII.

Fig. IV.

Fig. III.

Fig. VI.

Fig. V.

Fig. VII.

Fig. XI.

Fig. X.

Fig. VIII.

Fig. IX.

After Paris Aldous. West, Newman & Co. sc. lith.

PLATE XXX.

FIG. 1. A gray layer of urate of ammonia is seen occurring between the deposits of uric acid. There were three stones, all of considerable size. [Removed from Mr. Paul by Mr. Ranby. Sloane collection.]

FIG. 2. The yellow nucleus is uric acid; it is surrounded by a gray layer of urate of ammonia; then follow alternating layers of urate of ammonia and the fusible phosphates; on the outside is an irregular deposit of triple phosphate.

FIG. 3. Represents the ordinary appearances of the urate of ammonia calculus.

FIG. 4. Section of a calculus consisting of urate of ammonia with urate of lime. [Hunterian. Removed from a girl, aged 7, by Sir Everard Home.]

FIG. 5. The section of a calculus, consisting of urate of ammonia surrounded by phosphates; "the marbled appearance is not common, and is produced by the mixture of urate of ammonia and by the difference in the relative proportion of the earthy salts, the whiter parts containing more phosphate of lime."

FIG. 6. The nucleus consists of urate of ammonia with oxalate of lime; around this is white oxalate of lime mixed with some phosphate of lime; the whole is coated with pure oxalate of lime, upon which is a partial deposit of uric acid.

FIG. 7. Shows the abrupt and well-defined transition from urate of ammonia to oxalate of lime; the exterior is thinly coated with a layer of phosphate and oxalate of lime.

FIG. 8. The ordinary phosphate of lime calculi found in the cells of the prostate gland.

FIG. 9. The ordinary "hemp-seed" calculi, consisting of oxalate of lime and urate of ammonia; the two larger sections are seen magnified, to show their crystallized centre and laminated exterior.

FIGS. 10, 11, & 12. Earthy phosphate calculi, taken from a cyst in the prostate gland; the deep notches in 10 and 12 corresponded, and formed a channel for the urine to pass through. One of these calculi protruded about 1-10th of an inch into the cavity of the bladder through an ulcerated opening situated anterior to the natural opening of the urethra.

1.

3.

2.

4.

5.

6.

7.

8.

9.

10.

11.

12.

PLATE XXXI.

FIG. 1. A calculus, of which the inner tuberculated part and the outer layer are nearly pure oxalate of lime, the intervening white part fusible phosphates.

FIG. 2. The nucleus consists of urate of ammonia; it is surrounded by, first, oxalate of lime; secondly, by uric acid, urate of ammonia, and the earthy phosphates. "The surface of the oxalate of lime deposit appears to have been covered with coagulated blood, as the uric acid part is not in contact with every part of it."

FIG. 3. Calculus, showing a thin layer of uric acid deposited on a mass of oxalate of lime; it is remarkable that the former in such cases generally has this peculiar yellow colour.

FIGS. 4 & 5. Represent the white crystalline variety of the oxalate of the lime calculus. The exterior, fig. 5, is seen studded with octohedral crystals on the surface.

FIGS. 6, 7, 8, 9, & 10. Carbonate of lime calculi.

FIG. 11. Represents the central portion, and one of the fragments of a large uric acid calculus, which had separated spontaneously in the bladder into numerous pieces. [From the Museum of St. Bartholomew's Hospital.]

FIG. 12. The centre consists of urate of ammonia surrounded by oxalate of lime, divided into two by a thin layer of phosphates; then follows a thicker layer of earthy phosphates, succeeded by one of oxalate. It is an exception to the general rule of phosphates not being succeeded by any other deposit. (See also fig. 1.)

FIG. 13. The external surface of a calculus which has undergone partial solution in the bladder.

FIG. 14. A section of the same. In this drawing are shown the abrupt termination of the outer uric acid layers, together with the thickness of the layer of the fusible compound, which has been deposited over the whole of its exterior. This calculus was removed by operation successfully by Mr. Liston; it was supposed that the partial absorption of its surface might have been aided by alkaline remedies, but it does not appear that there had been any systematic treatment with that object in view (see p. 92 of the College Catalogue). The irregularities in the surface of the stone had not been caused by any surgical treatment.

After Lens Aldous.

West, Newman & Co. chromo. lith.

ON

URINARY CALCULI:

THE LESSONS WHICH THEY TEACH AND THE PROBLEMS THEY SUGGEST.

COMPILED BY

JONATHAN HUTCHINSON, F.R.S., LL.D.

THE illustrations which are given in these Plates have all been copied, by special permission of the Council of the College of Surgeons, from those published in its catalogue. The freest possible use has also been made of the descriptions which accompany them, and of the information afforded by the introductory remarks. As in many instances the phraseology has been changed and abbreviation attempted, it has not been found possible to introduce quotation marks so often as would otherwise have been desirable. I must therefore be content with this general acknowledgment of indebtedness.

Urinary and other calculi offer exceptional attractions both to the collector of specimens and to the pathological artist. Every operating surgeon has his private series, and most of our museums contain them in great abundance. Recent improvements in surgery have, however, probably put an end to the possibility of obtaining these concretions in the future, and in the course of another century the extrinsic interest of antiquity will be added to our collections of calculi, whilst new museums may find it difficult to obtain series of specimens. The ease and safety with which all stones of less than unusual size are now crushed and got rid of will make it less and less common for patients to delay treatment until extraction, without crushing, is the only resource.

The classification of calculi, which by some authors has been carried out in much detail, may for clinical purposes be greatly simplified. The attempt to divide those of the lithic acid group into subdivisions according to the element which constitutes the nucleus, although of a certain amount of interest in reference to the mode of formation of the nucleus, does not at the present stage of our knowledge serve much useful purpose. We now know that uric acid, urates, or oxalate of lime may any one of them constitute the nucleus, and that after once this has been formed the subsequent accretions may be of any one or of all, in turns or together, according to the varying states of the patient's urine. We place, then, in one large family all stones in which these closely-allied salts are found, without attempting to register too minutely the precise order of their relation one to another. The laws under which this relationship determines the order of the different layers are of great interest, but they may now be discussed without encumbering ourselves by too much of statistical detail of the kind referred to. The uric oxide calculus, so rare as to be little more than a chemical curiosity, takes its place in the same large group, and so must also, though with a longer interval, that composed of cystine.

Thus then we may conveniently, for clinical purposes, place in one large group all stones which contain uric acid or oxalate of lime, or their allies, in any part of their substance, and it is clear that in this group we comprise almost the whole of what are known as primary calculi.

Another group must be constituted of those stones which consist of phosphates, and in respect to these some questions yet unsettled will have to be entertained. We may admit at once that the majority of phosphatic concretions are what have been called "secondary," that is, consequent upon some diseased condition of the organs in which they are formed. Probably a very large number of the stones classed in our museums as "phosphatic" are "secondary" in a yet stronger sense, in that they have nuclei of some other salt. It remains, however, an open question whether some of the harder forms of phosphatic concretion have not a fair claim to be regarded as primary, and if so, the phosphatic group should be divided into two. It will

naturally encounter a further subdivision as regards the kind of phosphate, whether bone-earth, triple, or their mixture the fusible salt; but, as just explained in respect to the representatives of the lithic acid family, no great clinical inconvenience will result from placing them all together in the first instance.

Our last group will contain the cases in which calculous concretions have formed round bodies which have been introduced from without, and these, excepting that they afford us instructive illustration of some of the laws of urinary deposition, have but little interest for the medical investigator. They stand wholly apart from the other groups, and teach us little or nothing as regards diathetic states. The problems which they offer us are comparatively simple, since they are always preceded by the occurrence of cystitis. With them we may also place certain pseudo-calculi, such as the urostealith (around soap), fibrinous calculi, and blood concretions.

Salts which enter into the composition of Calculi.—Amongst the ingredients which may enter in the composition of urinary calculi, the following must be mentioned as the principal. Most of these salts may occur either in the amorphous or crystaline form, and often in various combinations, or admixture with each other.

Uric Acid.—One of the commonest of urinary deposits. It occurs at all ages, as the well-known red-sand, in grains easily visible to the naked eye, and which have been aptly compared to cayenne pepper. Lithiasis, or the presence of free uric acid as an easily recognisable deposit, is far more common than the occurrence of calculus, and may exist for years, especially in young persons, without any formation of either gravel or stone. It is often seen in large quantities in the pelvis of the kidney, and it may form a concretion either in the kidney or the bladder. It is very often accompanied by a varying deposit of lithates. It may vary much in depth of colour, but is always of some tint of yellow or brown.

An almost pure uric acid is the calculus of adults. In elderly men no other primary calculus is in the least common. In young persons oxalate of lime is frequent, and, although uric acid is not at all rare, it but seldom maintains its individuality, being almost always either alternated, or mixed, with other salts. A large, dense, heavy stone, consisting of uric acid throughout, may be taken to have been almost certainly removed from a patient of at least middle age.

The quantity of uric acid sand passed by some patients is very large indeed. It may be continuous over long periods, or may occur in sudden and possibly in periodic attacks. Precisely similar statements are, I think, true of those who pass phosphatic sand, and it would appear that both are dependent upon conditions of assimilation which are susceptible of rapid and sudden changes. The following statement by Dr. Henry is important, although we cannot help suspecting a misprint in the first part of it, and that for "ounces" we ought to read scruples:—

"Two instances have fallen within my knowledge, in which persons have voided quantities of uric acid with the urine, far exceeding anything that I can find upon record. In the first, which was mentioned to me by Professor Memo, of Edinburgh, every pint of the urine voided by a man about forty years of age, who laboured under symptoms of gravel, deposited about two ounces of a brick-coloured sediment, which I found on examination to be chiefly uric acid, with a very small relative proportion of the earthy phosphates. In another instance, a lady of middle age, who was subject to gravel, was in the habit, when warned of its approach by the usual symptoms, of having recourse to a medicine, the composition of which is kept secret, but which appears to me to be nothing more than spirit of turpentine coloured by a little petroleum, with the addition of a portion of tincture of opium. The uniform effect of this medicine was the discharge of a sandy substance in such quantity, that more than four ounces were sometimes voided within the space of two or three days. It was composed chiefly of uric acid, with a small proportion of urea and of the earthy phosphates. I have since known another instance in which the same medicine has produced a similar effect, though not to an equal extent."

The Uric Oxide Calculus.—The uric oxide or xanthic oxide calculus is simply a variety of the uric acid, from which it differs in containing merely a few more equivalents of oxygen. It is of interest rather to the chemist than to the physician, for it is produced probably under precisely the same conditions as those which

* 'Henry on Urinary Calculi,' Medico-Chirur. Trans., vol. ix. p. 137.

favour the formation of the more common type. Yet, although so close an ally, it appears for the most part to preserve its individuality, and the two salts do not usually mix. Very few instances of its occurrence are as yet on record.

Dr. Marcet, who first described this compound, had in his possession a calculus which weighed only eight grains. It was of a reddish cinnamon-colour, its surface was smooth, its texture hard, compact, and laminated. Of the history of this stone nothing is known, and no portion of it survived the chemical analysis.

Another calculus of the same constituents was examined by M. Langier, and recorded in the 'Archives Générales,' vol. xxi. In this case also the stone was very small.

The third example was examined by Liebig and Wöhler, who confirmed Dr. Marcet's discovery, and carefully determined the elementary composition of the substance. In this instance the stone was as large as a small hen's egg, and from centre to surface of the same constitution.

I have abstracted the above statements from the College Catalogue, and must refer the reader to it (or to any good treatise on the subject) for details as to the mode of analysis.

Urates.—The urate of ammonia is the most common, but the urates of soda, potash, lime, and magnesia also occur. The urates constitute the well-known brick-dust or lateritious deposit so frequently seen after unusual exertion attended by perspiration, after any febrile attack, or in connection with indigestion or unsuitable food. "Muddy urine" is the popular expression for that which contains lithates, and many persons know well by what articles of food,—beer, wine, &c.,—their water may be made muddy. The urates are soluble in warm fluid, and in large quantities of water when cold, and they are very rarely to be seen at the time the urine is voided. Hence the explanation of the infrequency with which they constitute calculi. Although, according to most authorities, not usually forming the nucleus, they are deposited with tolerable readiness when once a nucleus is formed. They frequently alternate with uric acid, or occur in admixture with it. They may also be mixed with the phosphates. The greater the degree of concentration of the urine the more likely it is to deposit urates; thus they are apt to occur after long fasting. As a rule the urates are deposited as an amorphous salt, and it is very common to find the different bases mixed together.

The urate of ammonia calculus is usually met with in children, and never attains a large size. Respecting them Mr. Taylor writes:—"I must fully concur with Dr. Prout that all those calculi which present when broken an amorphous and earthy-looking fracture consist essentially of urate of ammonia." Urate of ammonia is frequently met with in the fusible calculus.

When the urates occur in a crystalline condition it is under somewhat different circumstances. Sir William Roberts has drawn our attention to the important clinical fact that the crystalline urates are deposited within the urinary passages, and may thus easily constitute the nucleus for a calculus. He suggests that the great comparative frequency of vesical calculi in children may not improbably be due to the fact that the crystalline urate of soda very frequently occurs in the febrile attacks to which they are subject. This salt forms what are called "hedgehog crystals," from which sharp spines project, and when complaint is made in children that the passing of the urine gives pain, this is the salt which should be sought for. The admixture of the urate of ammonia with the phosphates in calculi is to be explained by the fact that this salt is liable to be precipitated when the urine becomes strongly ammoniacal, if there be at the same time a tendency to excess of uric acid.

Oxalate of Lime.—The oxalate of lime usually occurs as a colourless deposit, which may easily escape attention. If the urine be placed in a glass, numerous fine lines are produced, giving it the appearance of having been scratched; and, on careful inspection, these lines are seen to be caused by minute white crystals. The oxalate is insoluble in water and in the vegetable acids, but may be dissolved by the mineral acids. It occurs very frequently in conjunction with uric acid and the urates. The influence of food, and especially of certain kinds of vegetable foods, such as fruits, rhubarb, &c., in throwing down oxalate of lime, is well known. Conditions as regards derangement of digestive power similar to those which produce uric acid, may, under slight alterations of diet, produce the oxalates. Dr. Owen Rees even held the opinion that the oxalate of lime never exists free in the blood, but is produced from uric acid after separation from the latter.

That the oxalate of lime calculus is not always of dark colour is illustrated by figs. 4 and 5 in Plate XXXI. In these instances, which certainly at first sight would not be taken for oxalate of lime at all, the salt is in a crystalline condition,

and the texture of the stone is loose. Although not of dark colour, they do not afford good examples of "the *white* oxalate." Of this a fair instance is afforded in fig. 6 of Plate IX. of the College Catalogue (not copied). In this the surface of the cut stone is smooth and hard, and looks like a slightly pink porcelain. It is stated by several authors that in the Norwich Museum are specimens of a yet whiter tint, but I have failed to find them. When oxalate of lime is deficient in colour it is almost always from the stone having been formed in the kidney. Its usual colour is derived probably from the urine.

It is a remarkable fact that oxalate of lime calculi, although both heavy and rough, are often attended by but slight symptoms of irritation. Mr. Poland, in Holmes' Surgery, has figured a stone of this kind of considerable size which he had removed from the bladder of a boy of twelve, who had shown no symptoms until two weeks before the operation. I once myself removed from the bladder of a boy a stone of this kind, which was unusually heavy and rough, but in whom the symptoms had been almost absent. Put to the test of jumping from a chair, he did so with alacrity, and made not the slightest complaint.

Cystine or Cystic Acid.—This is a crystalline body, which has only as yet been detected with certainty in the urine of man, the pig, and the dog. Nothing is known as to the special conditions of health which produce it, and it is seldom recognised in the urine, excepting when the symptoms of a calculus reveal its presence. When once attention has been drawn to its existence it is, as a rule, found to be constantly present in greater or less quantity. Periods of intermission may, however, occur. The urine which contains it is generally slightly turbid, of a yellow colour, and with a peculiar "sweet-briar" odour. The composition of the urine in other respects is usually normal, as it is indeed in most other calculous states. It is the calculus-forming material itself which is alone in excess. Cystine is remarkable for containing sulphur. The peculiarity that by long exposure the yellow tint is changed to green is observed both in the urine which contains cystine and in section of the calculus itself.

Xanthine or Xanthic Oxide.—This is a very rare urinary deposit, closely allied to uric acid. It occurs as a granular deposit, which is soluble by heat, but with considerable variations. It is not impossible that mistakes have occurred in more than one of the records as to its occurrence as a deposit, but there is no doubt that it has been encountered as a calculus six or eight times. It has been met with in Germany, England, and India. The subject of the Indian case was a Mussulman child, and the fact is of importance as illustrating the sameness of urinary concretions in different races. Wherever uric acid calculi are common, there we must expect now and then to meet with one of xanthine.

Carbonate of Lime.—This salt is the common deposit in the alkaline urine of the herbivora, and forms their calculi. It is not unfrequently precipitated in human urine in an amorphous condition, together with the phosphates, when ammoniacal decomposition has occurred. As a primary deposit, whether in the form of sand, gravel, or calculus, it is extremely rare. In a few cases patients have voided numerous small calculi composed of carbonate of lime, or such have been found in the bladder or kidney; but in such cases the suspicion is always to be entertained that some local obstruction exists, and that the salt has been deposited in connection with a cyst in the prostate, bladder or kidney rather than directly from the urine. Sir W. Roberts admits the carbonate of lime calculus to the rank of one of the primary ones occurring in the human subject, though of extreme rarity. In one of the cases which he quotes, however,—that recorded by Mr. Wagstaffe,—it has since been proved that there was a mistake in analysis. It is certainly curious that a deposit which is common in the herbivorous domestic animals, and which in them produces large primary calculi, should in the human subject be all but unknown. The Hindoo is as nearly as possible a vegetarian, but his calculus is like that of a flesh-feeding Englishman, almost always of the uric acid group, never carbonate of lime.*

The Phosphates are usually met with mixed, but it is very important that their several varieties should be considered separately.

Phosphate of lime, basic or amorphous phosphate of lime, bone-earth, is invariably precipitated in alkaline urine. If the alkali which

* Concerning the carbonate of lime, Dr. Ord writes: —"Many circumstances point to the conclusion that where carbonates are formed and enter into the composition of calculi from the urinary organs, such calculi have been formed out of the course of the urine, in diverticular passages where other fluids than urine would predominate."

precipitates it is a fixed alkali, it may be the sole deposit, but as ammonia is by far the more common cause of its appearance, it is usually accompanied by the triple phosphate. Heat throws down this salt when in excess, as is well known to all accustomed to use heat as a test for albumen. It is soluble in acids. "Its occurrence depends simply in the existence of an alkaline reaction, and the presence of lime and phosphoric acid in the urine" (Roberts). It is the normal deposit of urine alkaline after a meal, or of that made alkaline by medicinal treatment. It may be present when the urine is voided, in sufficient quantity to cause turbidity, and, if so, the deposit does not increase on cooling. When cystitis occurs bone-earth is secreted by the mucous membrane of the bladder (Brodie and Prout). Bone-earth rarely constitutes the nucleus of a stone, for it appears, in consequence of its non-crystalline condition, to concrete with difficulty. It is, however, very common in combination with the ammoniaco-magnesian salt.

There is a crystallised form of phosphate of lime to which attention was first directed as a urinary deposit by Dr. Hassall, and which was subsequently investigated by Sir W. Roberts. It is a primary deposit, and is met with in association with oxalate of lime, and even with uric acid; usually in those who are seriously out of health. This salt might easily constitute the nucleus of a stone, but it is rare.

The triple phosphate—magnesian or ammoniaco-magnesian phosphate—is a crystalline salt insoluble in water, and of a white colour. It often constitutes what is known as "white sand." It is usually met with in association with phosphate of lime constituting the fusible calculus. It may, however, occur alone, may form the nucleus of a renal calculus, and produce its chief bulk (see page 8). Its usual cause, or, according to some authorities, its invariable cause, is the ammoniacal decomposition of the urine. There is reason to believe, however, that it may occur without decomposition, or any appreciable inflammation of the urinary passages. Sir W. Roberts places it unreservedly in the group of secondary concretions, but the evidence as to its right to a place amongst the primary ones is at least as strong as is that of the carbonate of lime. It has been found in the kidney constituting a large stone in cases in which there was no history of preceding disease. The more nearly pure the salt the greater the probability that it is due to constitutional rather than local causes. Sir W. Roberts himself records (p. 100) a very instructive case in which it appeared in the urine under circumstances closely fitting with Prout's description of the "phosphatic diathesis."

PHOSPHATIC CALCULI AND THE "PHOSPHATIC DIATHESIS."—The old term "phosphatic diathesis" is now almost wholly disused, and very properly so if it were to be employed, as formerly, to include all conditions in which phosphatic depositions occur. We now know that in a very large majority of cases the phosphates are simply the result of decomposition of the urine and of inflammation of the bladder, and do not in any way denote such peculiarity of the patient's health as might deserve the name of a diathesis. This statement, however, concerns the mixed phosphates, and more especially the triple or ammoniaco-magnesian salt, which is always one ingredient in the mixed (or "fusible") concretion. When, however, a calculus contains none of the triple salt, but consists of bone-earth only (phosphate of lime), its significance is altered, and some further consideration must be given to the question as to whether the state of the patient's health may not have something to do with the formation. The same suspicion may also be entertained in certain rare cases in which the triple phosphate is present in a state of purity. The concluding sentence of Sir W. Roberts' summary on this subject, "the phosphatic diathesis of Prout is simply ammoniacal urine," is, I cannot but think, too strongly put. There certainly are cases in which phosphates are freely deposited which have nothing to do with ammoniacal decomposition of the urine.

In connection with this question it is of great interest to enquire whether there are calculi which consist wholly of bone-earth (phosphate of lime),* or of a pure and unmixed triple phosphate, and, if there are such, to ask under what conditions they are formed. In the Introduction to the College Catalogue it is stated that the ratio which calculi consisting entirely of the phosphates bears to the whole number is

* Mr. Taylor (1838) objects that the term "bone-earth" is not closely applicable to phosphate of lime as met with in calculi, since in the latter the portion of acid is much larger than in the lime of bones. The proportion of acid, he points out, varies a good deal in different specimens of calculus.

as 1 to 13½,* but in a previous sentence it has been said "there is no instance in which the phosphates form the nucleus of a calculus"; so that it is clear that we must take the expression "consisting entirely of the phosphates" with some limitation. We must remember also that by "phosphates" is here meant the mixed salts, for at page 103 we find that "calculi consisting entirely of phosphate of lime,† having an undoubted renal origin, are of extremely rare occurrence. There is no specimen of this description in the Collection, nor does it in any instance form the nucleus of a calculus." This strong negative fact is, however, possibly not so conclusive as it may at first sight seem, for since it is admitted that as a "principal constituent of urinary concretions it is very common," it may be simply that it has great difficulty in forming a nucleus, even when superabundant in the urine and quite capable of forming a concretion when once a nucleus is afforded to it. We must bear in mind that phosphate of lime is not only an ingredient in healthy urine, but that it is possibly formed by secretion from the mucous membrane both of kidney and bladder (and some other mucous surfaces). We have therefore to be on our guard lest we mistake the phosphate of lime due to cystitis for that resulting from its excess in the urine. That there are persons who habitually pass this salt in great excess, through long periods, cannot be doubted, and that too without any disease of bladder or kidney, and often with apparently fairly good health. The question is whether in such patients, for whom, perhaps, the term "phosphatic diathesis," in the sense originally intended by Prout, may safely be still employed, we ever encounter the formation of primary calculi, or of calculi formed so almost exclusively of this salt that we must consider the constitutional state to have taken a share in the result such as it does in the formation of uric acid stones. The evidence given by the College Collection is, as just stated, to the effect that phosphate of lime never at once constitutes the nucleus and the entirety of a stone.*

Dr. Wollaston described, in the 'Philosophical Transactions' for 1797, a concretion of this kind, which had been given to him by Dr. Baillie, but unfortunately no particulars are recorded as to the patient from whom it was obtained. It is said to have been of a pale brown externally, and so smooth as to appear polished, whilst its section showed regular laminæ, which adhered but slightly.

Mr. Thomas Smith, in 1870, presented to the Pathological Society, on behalf of Dr. James Wise, of Decca, Bengal, thirty-one tetrahedral stones, which together weighed nearly five ounces. They had been removed by lithotrity from a Hindoo peasant, aged thirty-five, who recovered well and soon resumed his work. By the analysis of Dr. Mathieson, one of the stones was determined to be phosphate of lime. Sir Henry Thompson has recorded a case in which he removed, by crushing, a large stone which is said to have consisted solely of phosphate of lime. The patient was aged about thirty-five, and had suffered from disease of the bones of the spine in early life. Four years previously he had voided two small calculi said to be phosphatic.

In fig. 2 of Plate XXX. we have an instance of what is called in the Catalogue a "confirmed phosphatic diathesis." A large stone is seen, which is of laminated structure and compact substance, excepting a thick encrusting layer. This outer layer is of the ordinary loose mortar-like substance of the mixed phosphates so constantly met with on the exterior of all stones which have caused cystitis. It is, however, totally different in texture and aspect from the bulk of the stone, although both are white. The difference between the true calculus and its

* Sir Henry Thompson, our chief English lithotritist, in a report in the 53rd volume of the Medico-Chirurgical Society's Transactions, recorded 184 consecutive cases treated by crushing. As regards the kind of calculus, it was believed to have been uric acid or urates in 122 cases, mixed in 16, phosphatic in 40, oxalate of lime in 4, cystic oxide in 1, and pure phosphate of lime in 1. The rarity of the oxalate of lime is probably explained by the fact that all the patients were adults. It is possible that of those called phosphatic not many were wholly or primarily such.

† Dr. Ralfe exhibited, at the Pathological Society in 1880, some calculi from the kidney which consisted of phosphate of lime, with excess of organic matter, and mere traces of uric acid. The patient was a foreign seaman, who had died after severe symptoms of renal irritation, &c., following a blow. The case is proof that phosphatic calculi may form in the kidney. The injury occurred only just before the fatal illness, and had nothing to do with the formation of the stone.

* "Phosphate of lime has in two instances been observed by Dr. Prout to be deposited from the urine as an impalpable powder in very large quantities, and of considerable purity, when no disease of the bladder was present."—College Catalogue. I have myself seen several such cases, but in no instance did a patient ever bring me phosphatic gravel which could be supposed to be primary. Probably the amorphous phosphates form concretions with great difficulty.

encrustation is almost as great as between a uric-acid stone and its coating of phosphates. Yet in this instance both the calculus and its crust rank as phosphates. The nucleus of the stone is a small irregular lump of uric acid, and alternating with layers of amorphous mixed phosphates are narrow lines of yellow lithates. Here, as in some other instances, the suspicion seems plausible that the stone was the result not of cystitis and urinary decomposition, but rather of a urine kept alkaline, or nearly so, for a long period by artificial means. At length cystitis did supervene, and then there came the encrusting mortar-like layer of crystalline triple phosphate. The existence of the uric acid nucleus makes it certain that the patient had not in the first instance "a phosphatic diathesis." That such a condition existed through a very long period is made probable by the large size of the concretion, its firmness, and its lamination, and that it was induced artificially seems only a reasonable conclusion. Unfortunately it is a British Museum (or Sloane) specimen, and consequently there is no forthcoming history of the patient from whom it was obtained. It may possibly be from one of the many who, after the disclosure of Mrs. Joanna Stevens' "discovery,"* swallowed alkalies in enormous quantities for long periods in the hope of dissolving their stones. It is clear from the alternation of the urates with the phosphates that some difficulty occurred in the maintenance of the alkalinity of the urine.

I have searched not a few museums and museum catalogues carefully for examples of the phosphate of lime calculus without other nucleus or admixture. I have been able to find, however, exceedingly few instances, and it is to be regretted that in none of them are the case-histories sufficiently complete to allow of our obtaining from them much clinical knowledge as to diathesis. In some of them, however, there does not appear any reason to believe that the formation of the stone was preceded by cystitis.

In the College of Surgeons' Museum, No. H. 6 (a Hunterian specimen), is the half of a calculus composed almost wholly of phosphate of lime, but with a little of the triple salt. H. 43 is a similar one, "from a man aged 63 in St. George's Hospital."

Although the alternation of layers of other salts is not common after once the deposit of phosphates has commenced (Marcet's law), yet it is to be observed that the admixture of urates with the earthy phosphates occurs not very infrequently. This is of interest, as proving that the states of health permitting of the deposit of these two salts are not in all cases widely separated, or, in the older phraseology, that the two diatheses may even coexist. Thus H. 35 is a calculus in fragments, which weighed six drachms, and consists of earthy phosphates, with a large quantity of urate of ammonia. In H. 47 mixed calculi, containing both phosphates and urates, were finally coated by a thin layer of urate, the patient being an old man of 74. H. 32 is remarkable on more than one account, for the patient was a negro (a race almost absolutely exempt from stone), and the calculi had a crystalline triple phosphate nucleus, with a mixture of fusible salt, urates, and uric acid externally. There were twenty-one in number.* The patient was a negro boy of four years old living in Demerara. There can be little doubt, having regard to the nucleus and to the statement that they were removed from the urethra, that these calculi were not primary, but had formed in connection with some disease of the organs attended by impediment to exit of urine. In H. 18 we have another instance in which the fusible compound is mixed with urate of ammonia; and the same statement is true of H. 19, H. 20, and H. 21. It is clear, then, that we must not allow the creed that the formation of phosphatic deposits once begun supersedes and prevents ever after the deposition of uric acid or urates, to obtain without a free allowance for exceptions.

I have already alluded to the fact that when calculi are composed wholly of phosphates they are almost invariably found in association with disease of the urinary organs. Some of the best examples occur in connection with paraplegia, others with stricture or enlarged prostate, or with organic disease of the bladder. The College Catalogue contains a list of forty-eight specimens of calculi of this formation.

* In the year 1750 Mrs. Stevens received from the Government five thousand pounds for a secret remedy which was vaunted as efficient in the solution of stones. It consisted chiefly of lime obtained from the shells of eggs. Its disclosure led, we are told, to an extended employment of alkalies for this purpose.

* "An old negro woman in Demerara made an incision into the urethra of a negro boy four years of age, and extracted these calculi, and made a perfect cure of her patient, James Hendy."—Hunterian.

In most instances it is expressly stated that the stone consisted of the fusible phosphates, and, as no information is given as to any nucleus, it is to be presumed that none can be discerned. In a large majority of these forty-eight specimens no history whatever of the patient's case is appended, none having been recorded by the donor, and we can therefore make no use of them in reference to the point under discussion. In a few, however, the history is forthcoming, and remarkably illustrates the general statement that phosphatic concretions are usually secondary to inflammatory mischief induced by some mechanical cause.

One of the best of these, and with the most complete history, is that numbered 2. In this instance the stone had attained the enormous size of sixteen inches round its greatest circumference and fourteen in its smallest. It weighed forty-four ounces troy. It consists of the mixed phosphates. An attempt to remove was made by Mr. Cline a short time before the patient's death, but it was found to be so hard that it could not be broken up, and its bulk made it impossible to think of extraction. The history of the case was that the sufferer (Sir Walter Ogilvie, Bart.) had twenty-eight years before his death suffered an attack of paraplegia in connection with a blow upon the spine, which was probably attended by fracture. For two months his lower limbs were paralysed, and the catheter was needed. After that a slow recovery followed up to a certain point, but was never complete. The stone was first recognised by sounding by Mr. Benjamin Bell, of Edinburgh, twenty years after the accident, and it had then already attained a very large size. Probably it had been in process of formation from the date of the paraplegia. The sufferings of the patient were in the end extreme, for he could only make water by placing himself almost on his head, and painful spasms compelled him to do this several times in the hour. The calculus could be felt above the pubes, and it entirely prevented the entrance of a sound into the bladder. At the autopsy it was found to be moulded by the pelvic bones. The ureters were very greatly dilated, so as to constitute "a supplementary bladder," and the kidneys were "altered considerably in their texture, and their pelves much enlarged." Although the notes of this remarkable case are otherwise full, we have no information as to what the state of the urine had been during the formation of the stone. The long duration of life and the slight amount of inflammatory disease in the kidneys, and even in the bladder, would suggest that other sources of the phosphatic salts than chronic cystitis may have existed. No doubt the urine was constantly alkaline, but it seems scarcely possible that it could have been attended through so long a period by severe cystitis. It is moreover recorded that the patient was accustomed to ride about on a gentle horse. The case, however, affords a good illustration of the enormous size to which in the course of time a phosphatic stone, if left alone, may develop.

A yet more instructive example of the gradual accretion of phosphatic deposit, without any obvious signs of inflammation or even of urinary decomposition (presumably, for the notes are brief), is afforded by No. 1 in Group G., described at page 111 of the Catalogue, and figured in Plate X. In this instance the stone weighed seven ounces and a half, and consisted almost wholly of phosphate of magnesia and ammonia, the quantity of phosphate of lime being very small. It is described in a

memorandum from Hunter's pen as "taken from the pelvis of the right kidney of Mrs. ——, a natural daughter of Sir Richard Steele. She was never known to have a nephritic symptom till just before her death, when she was taken with a violent pain in her right side near the back, the seat of the right kidney, which appears

to have thrown her into a fever, of which she died; and upon opening the body was found this stone filling up an enlarged pelvis, and the substance of the kidney itself become so thin as only to appear like a coat or membrane covering the stone, which gave the idea to the surgeon that the substance of the kidney was grown into a stone." The stone to which this narrative refers is in shape and size much like a kidney. The inner and middle part is of much looser texture than the rest, the latter being compact and laminated. The exterior is smooth. There is no trace of any nucleus of other urinary salt. The composition of this calculus was ascertained to be nearly pure phosphate of magnesia and ammonia,—triple phosphate,—which in the loose textured part was obscurely crystallised.

Dr. Hale White has described, in the 'Pathological Transactions,' a case which is almost an exact parallel to the above. The stone was taken from the kidney of a dissecting-room subject. It consisted of pure triple phosphate externally, and a mixture of the triple salt and phosphate of lime in the central and middle parts. It weighed 1560 grains. (1835).

A remarkable example of triple phosphate calculi, developing to a very large size in the kidney, has been recorded by Dr. Gee.* Both kidneys were involved, one containing a calculus weighing 36¼ ounces, the other one of nearly 10 ounces. In addition to these large ones, there were more than a thousand smaller ones, and much calculous dust. The larger stone had been felt through the abdominal wall during life. The patient was thirty-eight years of age, and had suffered much from inherited gout. He had been liable to pain in the loin from childhood. The stones consisted of nearly pure phosphate of magnesia and ammonia; but in the largest there was a complex nucleus, which contained chiefly oxalate of lime, with traces of triple phosphate, carbonate of lime, and uric acid. The analysis was by Dr. Russell.

This case, in which it will be observed that both kidneys were affected, lends, with the preceding ones, a not inconsiderable support to the belief that the triple phosphate may be secreted in excess and form a primary deposit.

Cases of this kind, so far as the facts go, would appear to indicate that even triple phosphate calculi may originate in the kidney itself, and grow with but little evidence of inflammation, or of urinary decomposition. It is astonishing how easy it would appear to be, when once the nucleus has been constituted, for the urine to continue to supply material for successive layers. It is a characteristic of almost all the larger phosphatic calculi that they show proof of having been moulded in the cavity in which they have grown. In some instances this results from their mere bulk filling the viscus, but in others it is from the projection of some part of the stone into some adjacent hollow, and its growth by continued accretion in that special direction. There is in the Norwich Museum a magnificent specimen of a branching phosphatic stone developed in the kidney. It is smooth, but otherwise resembles a huge mass of coral.

The discovery of a large triple phosphate stone in the pelvis of the kidney, and without any evidences of inflammatory disease, brings us back to the question as to whether these phosphates are ever secreted in such excess as to be capable of forming concretions. I have already mentioned Prout's statement that he had twice seen the phosphate of lime deposited in large quantities without any evidence of cystitis, and stated that my own experience entirely corroborates his. It is a question needing further investigation as to the precise chemical constitution of the phosphates, which go ordinarily by the name of "white sand." Usually "white sand" is probably triple phosphate, only in exceptional cases the phosphate of lime. Triple phosphate is, however, a variable salt, and may contain in some cases much less of the ammonia base than in others.

Before leaving the subject of phosphatic urine, we must ask the reader's attention to the extreme facility with which in certain states the urine may become ammoniacal. From the presence of ammonia to the production of phosphatic deposits there is but a step. In connection with this subject some facts given by Dr. Stokes are of interest. That distinguished physician has recorded, in his lectures,* the observation, which he believed to be original, that carbonate of ammonia may be present in the urine quite independently of decomposition or of cystitis. In his first case this happened in a young man who was extremely ill from typhus fever. The ammonia was in sufficient quantity to cause brisk effervescence of the urine, and it continued to be evident for four or

* Medico-Chirur. Trans., vol. lvii. p. 80.

* See New Sydenham Society's edition, vol. ii., p. 311.

five days, disappearing as improvement set in. In order to ascertain whether it resulted from decomposition from retention, the bladder was emptied by a catheter, but the urine taken away two hours afterwards was equally loaded with ammonia. After all, probably this case does not prove more than that when the ferment is present the decomposition of urea may take place with great rapidity. In a second case Dr. Stokes found the urine "loaded with ammonia, and without a trace of urea." In this instance the patient was a strong athletic man, who, after exposure to cold, became seriously ill with pain in the abdomen, tympanitis, and fever. The urine was perfectly limpid when voided, and had not the slightest smell of putrescence. It was alkaline, and effervesced with acids. If the patient completely emptied his bladder and then again in half-an-hour voided a small quantity of water, the latter contained ammonia in the same proportion as before. In this case again, although it may be admitted that the facts are very peculiar, we can scarcely follow the distinguished observer in his inference that ammonia was excreted as such by the kidneys and replaced urea. The very severe pain which the man is described as having suffered may have been due to some one-sided uretral or kidney obstruction, and from this a ferment may have been supplied. As in the former case, all that is really proven is the extreme rapidity with which the whole of the urea in the urine may disappear and be replaced by an ammonia salt. It is to be added, however, that the autopsy showed "the bladder perfectly healthy," and the kidneys only "rather enlarged and turgid with blood."

Those who deny that there is any proof that the phosphates are ever secreted in excess in connection with long persisting derangements of the general health (the phosphatic diathesis), have to meet the following facts: Undoubtedly there are cases in which for years together, but with variations in quantity, white sand appears abundantly in the urine, there being no indication whatever of disease of bladder or kidney. This white sand consists of mixed phosphates, and is attended by an alkaline reaction of the urine. Next there are in all collections of calculi specimens which consist of white amorphous phosphates, in some cases with a small nucleus of some other substance, but in others with indications that the nucleus also is of the same salt. There are also numerous specimens showing thick layers of dense phosphates intervening between layers of uric acid or of oxalate of lime. The character of phosphatic deposits as *thus* met with differs from *that* of the mortar-like encrustations met with as a consequence of cystitis from the presence of an irritating stone, in being much more dense and compact. Not very unfrequently in phosphatic calculi, or layers met with under such circumstances, there is some admixture of urates with the earthy salts. The clinical history of the cases in which white sand appears in the urine is quite consonant with the admixture or alternation referred to. Those who pass white sand often appear to be in good health, or are liable only to dyspepsia, much as are those who pass uric acid, and in some the deposit can be produced almost at will by indulgence in certain wines or articles of food just as that of uric acid can in others. There is therefore nothing to excite surprise that the two salts apparently so opposite in their significance should occasionally alternate, being in turn the results of modifications in assimilation not wholly unconnected. Dr. Prout laid possibly too much stress on nervous exhaustion as an accompaniment of his phosphatic diathesis, and hence misled subsequent investigators, who have easily proved that excessive wear of the nervous system is by no means always attended by increase of the excretion of the phosphates. The fact is that the white sand cases are by no means always attended by debility; whilst, as is well known, uric-acid dyspepsia is in its turn occasionally attended by marked debility, and may be produced by overwork and anxiety.*

Cystine Calculi.—The cystic oxide or cystine calculus, although very rare, is of extreme clinical interest. It not unfrequently affords

* Mr. Taylor, an excellent chemist, writes cautiously, "The phosphates *seldom* form the primary deposit." Dr. Henry, writing in 1818, makes the following definite statement:—"In four instances only out of 187, the calculus has been composed throughout of the earthy phosphates; and in these I have not been able to discover a nucleus of any other substance. I consider the fact therefore as sufficiently established that in some instances, though comparatively very few, a tendency to secrete the earthy phosphates in excess is a cause of the formation of stone, first probably in the kidneys, and subsequently in the bladder. This tendency, indeed, as is well known, sometimes manifests itself by the discharge of urinary gravel, consisting of the triple phosphate, either alone or in conjunction with phosphate of lime."

us an instance of a urinary disease which prevails as a "family malady." I use the term "family" in its restricted and clinical, not its popular, sense, and as applicable to a disease which, whilst not proved to be hereditary, is apt to occur in several brothers or sisters. Ichthyosis, Kaposi's disease, and retinitis pigmentosa are, with many other structural defects, such as coloboma iridis, our best examples of family diseases. There are, however, many others of less conspicuous character, and amongst these the tendency to pass urine containing cystine or cystic oxide ranges itself. Cystine possesses some of the characters of an organic base, and is soluble both in acids and alkalies. Urine which contains it is of greenish yellow colour, and of a disagreeable smell. It is usually covered by a thin oily film, which consists of cystine mixed with triple phosphate.

The characters of the cystine calculus are well shown in fig. 6, Plate XXIX. It is of a somewhat loose crystalline structure, its crystals radiating from centre to circumference. Its surface somewhat resembles coarse sugar or honey, and it has the peculiarity that on exposure to light it loses its original colour and becomes greenish. Its chief chemical peculiarity is that it contains a large amount of sulphur (19 or even 26 per cent.). Cystic oxide calculi are remarkable for their purity, thus making it probable that the state of health, or of visceral peculiarity of function, in which they have their origin, is not in any close alliance with the other urinary diatheses.

The College collection contains three specimens of cystine calculi. One, which is the object of our illustration, was taken, after death, from the bladder of a man, aged 21, who had come to St. Bartholomew's Hospital from Northampton, and in whom it had probably been present for a long time. His bladder and kidneys were in a very advanced condition of disease.

In a second case (D. 2) several cystic oxide calculi, the largest the size of a pea, had been voided by an Irish gentleman, aged 40.

The third specimen, D. 3, is part of large calculus removed by Mr. Luke in the London Hospital from a brewer's labourer of adult age. He had the ordinary symptoms of stone, but suffered no great inconvenience. The stone was extracted with difficulty, and the man died six days later. He had voided calculi fifteen years before his admission, and his urine was habitually turbid from the presence of cystine.

It is unfortunate that in none of the above cases was any enquiry made as to the existence of the disease in brothers or sisters.

Dr. Marcet has recorded the case of two brothers in whose kidneys cystine calculi were found. Lenoir and Civiale each operated on two brothers for the same, and Toel relates the history of two sisters who both of them voided cystine (quoted by Roberts, page 281).

Roberts also mentions that Mr. Southam had shown him the fragments of a cystine calculus which he had removed by crushing from the bladder of a girl aged 4.

In the Manchester Infirmary is an exception to the general law that cystine calculi contain no other ingredient, for the stone consists of a uric acid nucleus, a body of pure cystine, and an external layer of mixed cystine and uric acid; whilst finally there is a phosphatic encrustation. Cystic calculi appear to be usually formed in youth, and to be very apt to cause irritation and disease of the bladder.

St. Thomas's Hospital Museum contains two specimens of cystine calculi. Respecting one (D. 2) no details whatever are given. The other (D. 2) is of special interest, because the cystine alternates, and is mixed with the oxalate of lime. The nucleus is of cystine, and there are also "green rings" of the same.

Guy's Museum contains several specimens of cystine calculi, and amongst them the original one described by Dr. Marcet, who found it by accident in the collection. In none of these is there any statement as to family prevalence. In most the tendency appears to have begun in early life, and to have persisted for long. One of them was removed by Mr. Key from a young gentleman, aged 12, whose urine also contained cystine. We have here an exception (proving the rule) that the children of the upper classes never come under care for stone in the bladder.

In St. George's Hospital Museum is a cystine calculus removed by Mr. Cæsar Hawkins from a Cornish boy, aged 6, who had suffered for four years. The central part only consisted of cystine. More externally are layers of urate of ammonia and oxalate of lime.

Mr. Taylor, in 1838, described two cystic oxide stones in the St. Bartholomew's Collection, one of which he believed "the largest and most perfect in the kingdom." It was supposed to have been taken from the bladder of a young man after death, in whom during life there had

been no symptoms of any affection of the urinary organs. Unfortunately no record of the case exists. The stone weighed 740 grains; the other, of which the museum possess only the half, weighed 155 grains.

Mr. Christopher Heath has published the case of a man, aged 28, from whose bladder he removed a number of cystine calculi. Other concretions were subsequently formed, and death from cystitis, &c., occurred two years after the lithotomy. A small quantity of cystine had been invariably present in the urine.

Dr. Ord exhibited, at the Pathological Society in 1879, a cystine calculus, probably the largest on record, which weighed 1050 grains. It had been successfully removed by lateral lithotomy from the bladder of a young man under the care of Mr. Reginald Harrison, the Liverpool Infirmary.*

Mr. Shattock showed, at the Pathological Society in 1880, for Mr. Steele, of Hemel Hempstead, a calculus in which cystine, with a minute admixture of oxalate of lime, composed the nucleus and chief bulk. There was, however, a thin layer of dark-coloured oxalate of lime, over which again cystine occurred. It had been removed from a healthy lad of 19, who since the age of 4 had repeatedly voided calculi. A great-grandfather had died of stone, and a sister had obscure renal symptoms. Two years after the lithotomy there was no recurrence, and, as in the preceding case, no cystine could be found in the urine.

In the Medical Museum, Bombay, is a cystine calculus removed from a boy of four (a Parsee). Cystine was also detected in the urine.

I do not find that any observers have paid special attention to the nuclei of cystine stones. It has been assumed that it is usually cystine. In the one of which we give a sketch, and in several others referred to, it appears to be not so.

On Alternation of Layers.—In explanation of the alternation of layers of different salts, there can be little doubt that we ought to call to our aid in many instances the influence of drugs, and of abrupt alterations of dietetic habits in obedience to medical advice. A large majority of our stone patients have at one period or other been under medical care: it may have been for the dyspepsia which attends lithiasis, or it may have been for symptoms directly referable to the kidneys or bladder. When we see in the section of a calculus an abrupt demarcation between a layer of lithic acid and one of oxalate of lime—it may even be between earthy phosphates and one of these—we may suppose with plausibility that they denote either change in season and diet, or in medical treatment. It is not likely that without some such influence the patient's diathesis or state of health would so suddenly alter. Uric acid may be taken to represent in the main the colder season and the heavier diet; the layer of oxalate upon it may often denote the summer season with its rhubarb and fruit at meals; or, without change of season, the oxalate layer may have been caused by the patient's having sought advice for lithiasis, and been ordered to at once give up beer, take less meat, and use fruit freely. In this way lithiasis may easily and suddenly have been made to give place to oxalaria. When phosphatic layers are seen in alternating calculi,—and they are not so uncommon as has been supposed,—they may possibly mark the time when the patient, alarmed at the bladder irritation which he suffered, not only changed his diet, but took to the free use of alkalies. When the latter had weakened him and brought out boils, then he gave them up and went back to his better food, with the result that his urates or oxalates were again thrown down. In some instances an abrupt and only temporary change in the deposit may represent some period of acute illness. I give these simply as plausible suggestions. Of the general fact there can be no doubt; we may read, if we can, in the section of a calculus, a record written in stone of the sufferer's changing habits and varying states of health. In this possibility consists one of the chief interests of our topic.

The term "alternating calculus" is applicable to any stone in which layers of different material recur repeatedly. Good examples of alternation, that is with several repetitions of the different salts, are not very common; but alternation to some extent is exhibited very frequently indeed. The salts which alternate are usually lithic acid and lithates with the oxalate of lime, and these salts often afford very conspicuous differences in colour. We may note in passing a deceptive appearance of alternation is sometimes produced by differences in colour in different layers of the same salt.

As a rule the phosphates are not found in the

* In 1882 Mr. Harrison reported that there had been no recurrence, and, what is very singular, that cystine had never been detected in the urine.

substance of alternating calculi. This observation was first made by Dr. Marcet. When the phosphates occur in large quantities they are usually evidence of cystitis and of decomposition of urine, and after this has once occurred the deposition of pure uric acid, or of oxalate of lime, is, for the most part, impossible. Since cystitis caused by a calculus is very rarely cured until the stone is removed, it follows that when once the encrustation of phosphates has begun it will continue to the end. Hence the explanation of Dr. Marcet's law, and not, as it was formerly the custom to say, that the phosphatic diathesis had superseded that of lithiasis.

Respecting alternating calculi, Mr. Taylor observes, "that in no one instance (in the St. Bartholomew's collection) have the phosphates, either pure or in a state of mixture, formed the nucleus." He quotes the highest authority on the subject (Dr. Marcet), to the effect "that a decided deposition of the mixed phosphates is not followed by any other deposition." He then describes a stone which appears to be, he says, an exception, but suggests as highly probable that the deposition of phosphates was caused by the use of alkaline remedies. The stone in question has a nucleus of urate of ammonia, then oxalate of lime, then a white layer three-eighths of an inch in thickness; outside this white layer, which consists of mixed phosphates, is a thin layer of oxalate of lime, and next crystalline uric acid, ending with mixed uric acid and oxalates.

Exceptions to Marcet's law are, however, not very infrequent, and our plates illustrate several examples of them. Thus in Plate XXXI., figs. 1, 3, 11, 12, and 14 all show the appearances of deposits of phosphates which have been subsequently covered in by oxalate of lime or lithic acid. In Plate XIX., fig. 9, is again a beautiful example of the same, but it must be understood that the conditions displayed in these stones is very exceptional. Good examples of alternation of uric acid and its salts with oxalate of lime, and of the encrustation of both by phosphates, are seen in so many of the sections that it is scarcely worth while to specialise them. The phenomena of alternation give support to the conclusion that the states of health which permit the deposit of uric acid and of the urates and oxalate of lime, are very closely allied. In the section of an alternating stone we may, as has been remarked already, in some sense read the record of the life of the patient in whose bladder it was formed; a slight alteration in his health, or very possibly in his diet, had clearly caused a deposit at one time of uric acid, and at another of the oxalate; it may be that this change has chiefly to do with the season of the year, and that during the summer, when vegetables and fruit were plentiful, the oxalate took for a time the place of the uric acid which was the more ordinary deposit. In children the reverse of this may be the case, and in connection with their peculiarities of diet, oxalate of lime may be the usual deposit and uric acid the exceptional one.

Of singular interest in connection with this subject is the calculus which is numbered 12 in Plate XXXI. In this stone variety of alternation is beautifully shown, and amongst the salts which compose its layers is the phosphate of lime, not once only, but twice, in the most definite manner. The stone begins in its centre by urate of ammonia; around this is oxalate of lime, and next nearly pure uric acid; then comes a thin white band of earthy phosphates, then uric acid again, next a much thicker layer of phosphate, and lastly an encrusting layer of oxalate. The limitation between these different layers is as abrupt as possible, and it is certainly most difficult to believe that on two occasions cystitis was present for a short time, and then suddenly ceased and gave place to a state in which the urine was acid in excess. The fact that the phosphate layers do not contain the triple salt is also strongly in opposition to the suggestion of cystitis as its cause. That something of the nature of a diathesis prevailed at the time of deposition of the white layers seems far more probable.* Such diathesis may, it is true, very possibly have been to some extent artificial, that is, it may have been helped or even caused by the remedies which were being used. The phosphatic layers may possibly represent periods during which the patient's urine was kept alkaline by the use of drugs. On the other hand, they may have been due to

* Amongst the extraordinary discrepancies of opinion on these subjects it must be noted that Dr. Owen Rees denies categorically that the use of alkalies has any tendency to favour the deposit of phosphates (page 302). He was perhaps the first to doubt the existence of a phosphatic diathesis. The only alkalinity of the urine which he allows to be capable of causing phosphatic deposit is that caused in the bladder by cystitis. Upon this theory he based the practice of giving alkalies in phosphatic urine in order to make the urine less irritating, and so prevent alkaline secretion from the bladder.

changed conditions in the general health in connection with diet, climate, or season. Fig. 1 of the same plate and fig. 9 in Plate XXIX. show almost the same conditions almost as well, and a repetition of them is admirably exhibited in fig. 10 of Plate IX. of the College Catalogue (not copied here). To a slighter extent they are seen also in fig. 3 of Plate XXXI., where a narrow white line of phosphate surrounding an almost black oxalate stone is in its turn covered, first by oxalates, and next by uric acid.* In seeking an interpretation of such appearances we must never forget the possible influence of vigorous drug treatment. To make the urine alkaline, and to keep it so for a certain time, would probably be quite sufficient to permit the encrustation of a calculus with earthy phosphate, whilst the tendency to deposit of this salt would cease at once when the treatment was changed.†

The museum of St. Thomas's Hospital appears to contain many specimens which afford exceptions to Marcet's law, or at any rate illustrate the simultaneous deposit of uric acid and of fusible phosphates. A majority of the specimens in the fusible group are described as having uric acid mixed with the phosphatic salts. The same statement applies to the concretions around foreign bodies. In this feature the results of analysis differ widely in the St. Thomas's series from those recorded at the College of Surgeons.

MIXED CALCULI.—The term "mixed" has been given to stones in which the different ingredients are mixed indiscriminately together. Observers agree that it is most unusual to find stones which, as a whole, deserve this appellation, and it is not in the least difficult, as a rule, to place a stone in its proper group as consisting of one or other salt, or as alternating. Slight amounts of mixture in certain layers are, however, common, the most frequent being of the urates with uric acid, or with phosphates.

ON THE NUCLEI OF STONES.—Much attention has naturally been given to the ascertainment of the precise character of the nucleus in calculi. The nucleus is clearly of extreme importance in reference to their formation, for a patient may go on for years passing either red or white sand in great profusion, and yet have no stone form. The moment, however, that a nucleus has been produced, then the process of accretion will be established, and the salts will be retained in the bladder, and will add to the bulk of the growing stone.* So far as is at present established, however, the formation of the nucleus is much a matter of accident, and the latter will usually consist of the same salt, or a near ally to it, as that which constitutes the bulk of the stone,—in other words, of that substance which most usually is in excess in the patient's urine. That the addition of animal matter is commonly necessary, and that the process is something more than merely one of either deposition or crystallisation, is highly probable. Dr. Carter, Dr. Ord,† and others have urged that a peculiar colloid material is the ordinary cement.

By Dr. V. Carter an attempt has been made to show that in India at any rate the nucleus is usually oxalate of lime, and his conclusions

* The oxalate of lime often follows the urates, but the urates rarely follow the oxalates.—Dr. Prout, Dr. V. Carter, and others.

† Mr. Bransby Cooper, in the Guy's Reports for 1849, has figured some beautiful examples of alternating calculi. In one of these (fig. 4) as many as fifteen or sixteen different layers may be counted; and figures 3 and 5, the latter from the Norwich Museum, are almost as good. Figures 4 and 5 both show phosphates alternating with lithates and lithic acid.

* Dr. Vandyke Carter has devoted much attention to the microscopic structure of calculi and their nuclei. One of his chief conclusions is that the crystalloids are found in spheroidal forms, or in forms tending to the spheroidal, in a colloid bed. He suggests that "an excess of mucus, perhaps altered in character, in the urinary passages, or the effusion of albumen, fibrine, or blood and the like, ... would furnish a colloid medium, with which urid acid, the urates or oxalates,—themselves, perhaps, in excess,—would combine." Mucus is for Dr. Carter the most important colloid in the formation of calculi. It is now ascertained that very frequently does the commencement of a stone seem to be due to accumulation of normal formation of the globular urates; that not seldom is the oxalate in submorphous form the first material laid down, and that comparatively seldom do crystals of uric acid compose the nucleus of a calculus (Vandyke Carter, page 29). At another part of his Essay, however, Dr. Carter states that "unmixed with oxalates the urates have never been found in calculous matter."

† The experiments of Dr. Ord, based, as he states, on suggestions by Mr. Rainey, bear out the conclusions previously arrived at by Dr. Carter as to the importance of a colloid (mucus) in determining the concretions of uric acid, &c. As he forcibly puts it, the pebbles of the concrete would not hold together without the cement to bind them, and to act on their surface. To make calculi of uric acid without colloids would be as hopeless a task as making ropes of sea-sand." — 'Medico-Chirurgical Transactions,' 1876. We must not, however, forget that the irritation caused by urinary sand of various kinds is probably in most cases itself the cause of the formation of the mucus which acts the part of the cement.

have received some support from others. It is certain, however, that this is by no means constant, but that the oxalate, uric acid, urates, phosphates, mucus, and even blood, may in turn constitute the centre of accretion. We shall probably be not far wrong in believing, as above hinted, that the nucleus is usually formed of the salt most often in excess, and that it is formed during some temporary period of unusual concentration of the urine,—with, it may be, an attack of renal *congestion* and increased mucous secretion.

In Bristol, oxalate of lime as a nucleus is stated to occur in 40 per cent., a yet larger proportion than in Bombay, whilst Mr. Bransby Cooper, in thirteen calculi from the Punjaub, found urates as the nucleus in all but four :—

8	Urate of ammonia.
3	Uric acid.
1	Oxalate of lime.
1	Phosphates and urates.
13	

Dr. Carter confirms Mr. Cooper thus far, that he admits that in most alternating calculi urates precede oxalates.

Dr. Beale long ago experimented upon lithic-acid calculi by dissolving them in potash, and convinced himself that a nucleus of dumb-bell and spherical crystals of oxalate of lime was usually left behind. He found concretions of the same kind in the pelvis of the kidney, and even in the uriniferous tubes themselves, and believes that the salt named supplies the true nucleus in almost all calculi. He figures microscopic concretions of it as voided in the urine, and also as occurring in the kidney-tubes. The careful examination of uric-acid gravel, which is common, would easily decide this point.

Blood as a rule does not irritate the bladder, and its coagula are usually disintegrated and pass away. It is only when a pre-existing state of the urine favours deposition that we find fibrine constituting the nucleus of a calculus.

One of the best examples of the fibrinous or blood-nucleus on record is a case published by Mr. Bransby Cooper in the Guy's Hospital Reports. It is one in which the whole history is complete, and its lesson is emphasised by the fact that there were two calculi, and they were exactly alike. Mr. Cooper removed the two by lithotomy from the bladder of a boy. They were about the size of small greengages, and consisted of layers of uric acid and urates. In the middle of each was a cavity capable of containing two peas. In one the cavity was quite empty, but in the other it contained the remains of fibrine. The history was that two years before the operation the lad (a plasterer) had fallen from a scaffold and contused his loins. After the accident he passed blood, and had great difficulty in micturition. He was soon well from the injury, but symptoms of calculus in the bladder followed.

The only deficiency in this narrative is that we have no statement as to the condition of the boy's urine before the accident, or as to family tendencies in this respect. In all probability he was the subject of lithiasis, or had a strong hereditary tendency to it. Mr. Cooper is careful to direct attention to this probability, but misses the opportunity of recording the fact. He well writes :—"Although in almost every case in which a hard foreign substance forms the nucleus of a calculus, the deposit consists of the earthy phosphates : in some instances a foreign substance may lead to the deposition of uric acid or urate of ammonia. The nature of the matter thrown down from the urine under any circumstances must, however, depend upon the state of the constitution, and upon the condition of the urine itself."

The following is Dr. Golding Bird's summary as to composition of the nucleus in the calculi in the Guy's Hospital Museum at the date of his paper :—

Nucleus consisting of	Uric Acid or Urates	262
,,	Cystic Oxide . .	11
,,	Oxalate of Lime .	45
,,	Phosphates . .	21
		339
	Mixed Calculi .	8
		342

A fallacy which appears to have puzzled Dr. Prout (as it well might) in the above statements concerns the large proportion of cystine nuclei. The author forgets to tell us that the eleven were all from one patient. This information I get from another source. It may be that similar errors underlie other statistical statements on this subject, and explain seeming discrepancies.

In seeking to determine the starting-point of a calculous concretion the operator must take great care that he does not miss the true nucleus. It is very possible that the line of section may not pass exactly through the centre of the stone, and that it may exhibit what we may describe as the kernel rather than the true nucleus. It is very common for a change in

the nature of the salt deposited to occur very promptly after the formation of the initial crystalloid nucleus.* The latter may be very small, and its presence in the centre of a larger and much more obvious kernel may easily be overlooked, or, as just suggested, it may not have been disclosed in the section. It might possibly be convenient, in describing stones, to use the term "kernel" in a looser sense than that of nucleus, and as applicable to the more conspicuous middle concretion, restricting the latter term for the carefully ascertained centre of this. In this use of the words it would probably be found that many published statements have reference to the kernel only, and not the true nucleus.

It may not be out of place to remark that the study of nuclei may be very profitably made upon gravel (happily out of reach of destruction by the lithotritist). In cases of multiple calculi, and of gravel, the operator has an opportunity for the examination of the conditions in many specimens formed under the same circumstances, and the risk of error in his conclusions is much diminished. When the calculus is single, it is obviously more probable that its beginning may have been, so to speak, a matter of accident than when multiple. It is in the multiple cases that we must seek to find illustrations of ordinary laws.

When calculi are hollow, as is now and then observed, the explanation usually given is that a considerable clot of blood has formed the nucleus, which has subsequently been absorbed.

The College Museum contains some extraordinary specimens in which saponaceous matter in large masses forms the centre of the stone, the supposed explanation being that soap had been injected into the bladder. The appended woodcut is a representation of one of these.

Calculi containing Indigo. — Dr. Ord has described a calculus removed from the kidney of a woman who had died from sarcoma which had obstructed the ureter of the opposite side, in which the concretion consisted chiefly of a substance resembling indigo. It is well known that under various conditions a blue colouring-matter like indigo may be met with in the urine. It may occur, for instance, in carbolic-acid poisoning. Dr. Ord thinks that it may be produced whenever there is any unusual or rapid breaking-down of albuminous matter. (See 'Pathological Transactions,' Vol. XXIX.).

On the Influence of Sex in relation to Stone. —The very remarkable difference in the numbers of the two sexes who suffer from stone has been hastily supposed to be satisfactorily explained by the greater length of the male urethra. This may be influential to some slight extent in preventing the escape of gravel, but it is not likely that it is very important. If once a stone has entered the urethra from the bladder it is not very likely to slip back again, and the length of the male urethra, its curves, &c., whilst they would well explain the occurrence of impaction, would scarcely account for retention of gravel in the bladder. It may, I think, be established that not only is it very rare for women or girls to pass gravel or small stones, but that they suffer but seldom from either uretral colic or lithiasis. Careful observations on this point are desirable, but my own experience has been that whilst I have repeatedly had boys brought to me in whom the urine was habitually loaded with uric acid, exceedingly few such cases have ever come under my notice in girls. I

* In using, for statistical purposes, the statements recorded by surgeons as to the composition of calculi and their nuclei, some margin—and, perhaps, not an inconsiderable one—must be made for possible errors. Operators are, I believe, usually content to classify their stones by the naked-eye appearances, without obtaining the aid either of the chemist or microscopist. The fallacies here are very great indeed; nor are they wholly removed even when a chemical examination has been made. Mr. Wagstaffe has published a case which well illustrates this. He showed, at the Pathological Society, some concretions from the kidney which he and others, after using chemical tests, believed to be calcium carbonate. Subsequently, having heard that another analyst had said that they were calcium oxalate, he requested the Chemical Committee of the Society to give its verdict. This was to the effect that one part was calcium oxalate, but that the greater portion was calcium phosphate, with only a trace of the carbonate. Not the least important point in this narrative is that one of the calculi was "of a dark brown colour, very hard, and closely resembled uric acid in appearance." Yet all the observers agreed that no trace of uric acid could be found, however much they differed on other points.

cannot extend this statement to adult women, but I can scarcely call to mind a single example of a definite attack of uretral colic in a female. It cannot, I think, be doubted that quite apart from the supposed greater facilities for escape, the tendency to the formation of calculi is in women at all ages far less than it is in males. To some extent we may credit differences in diet with this, but it must be borne in mind that it is true of young children quite as definitely as of adults. Lithiasis is a malady to which, in virtue of inherited organisation, males are preferentially prone.

In making these remarks we must not forget that it is possible that in the male sex in all ages the bladder is frequently less completely emptied than in the female. In the latter the stream of urine is probably, as a rule, much larger than in males, the time taken in micturition much shorter, and the evacuation of the bladder usually more complete. It is possible that many boys and men never absolutely empty the bladder. If this be so it is obvious that not only is the deposition of the salts favoured, but the escape of gravel, which frequently takes place with the last drops, is hindered.

Amongst the many facts in reference to calculous disorder, which it is extremely difficult to explain, it must be mentioned that all surgeons of experience amongst the richer classes agree that it is most rare to meet with stone in children belonging to them. Amongst the poor and labouring classes boys often suffer, and it appears to be the case in all parts of the world that about two-thirds of the total of stone operations are done in boys. Amongst the wealthier classes lithiasis in boys is common and troublesome, and cases of gout not very uncommon; but for some inexplicable reason vesical calculi form with extreme rarity. They are not absolutely unknown, but their frequency is not at all that which might have been expected.

Boyhood and the early stages of old age are the periods in life in which stone in the bladder is most likely to occur. This appears to be equally the rule in all parts of the world in which calculus is common. When stone occurs in boyhood its early stages are often very insidious; indeed it is by no means improbable that most calculi at this age have their beginning in the earliest period of infancy. The blocking of the renal tubes with salts is a phenomenon not unfrequently seen in dead-born infants, and that nuclei of stones may be thus formed is easily understood. It can, however, by no means be supposed that all calculi in boys originate at this early age, and indeed the occurrence of lithiasis, so conspicuous as to attract attention, is by no means uncommon in boys. Yet attacks of uretral colic are very rare, and so, too, are renal calculi. As age advances the occurrence of symptoms indicating the passage of a stone down the kidney become not infrequent, or it may happen that recurring attacks of pain, with occasional appearance of blood in the urine, indicate that a stone remains fixed in the kidney. Why the adolescent and early manhood periods of life should be, like the female sex, comparatively exempt from stone, it is very difficult to say, but the fact is universally observed that if a young man comes under care for stone his case is probably one which has been long neglected. At such ages the stones often prove to be large.

On the possible explanations of local prevalence of Calculus.—That there is such a peculiarity—we must scarcely call it a disease—as polydipsia (not alcoholic) is well known, and also that the affection is hereditary, and may prevail in families. We have it, I think on the grave authority of Dr. Gee, that an infant of a family in which this tendency was known to exist began to cry for water as soon as it was born, and did not cease until allowed to freely appease its thirst. Now in such persons the formation of calculi would probably be impossible, and it is highly probable that careful observation would show that the tendency to polydipsia of this kind in minor degrees is far from uncommon. Indeed, every mother knows that children differ very much as regards thirst. If peculiarities in this respect could be shown to prevail in races or communities we might possibly have one clue to the explanation of the local prevalence of stone. It is possible also that in districts where the water is agreeable to the taste the general tendency to drink freely of it may be much greater than in districts where it is disagreeable. As an agent in favouring metabolism and elimination, as well as in keeping the products of waste in perfect urinary solution, the free consumption of pure water is doubtless of very great importance. In districts where stone is common this matter should receive careful attention. The prevalence of stone in Syria, Arabia, and Persia, and many mountainous districts in hot countries where the supply of water is probably limited, may

perhaps be explained in this way. Throughout the United States, where calculus is very rare, although a large part of the population may be supposed to have some inherited proclivity to it, the supply of drinking-water is, I believe, everywhere good and liberal, and its customary consumption far greater than in England. Facilities for drinking are systematically provided on a scale of which we as yet know nothing, although amongst ourselves great advances have been made during the last quarter of a century.

Mr. Copeland Hutchison published, in 1818, in the 'Medico-Chirurgical Transactions,' a paper in which he cited much evidence in proof of the infrequency of stone in sailors.* His conclusions have, I believe, been sustained by subsequent experience, and the problem remains, why should it be so? Seafaring persons use salt provisions, and but little of fresh vegetables; they take much exercise and sleep in very close, ill-ventilated quarters. They drink but little beer, and, it must be added, they are liable to great variations in diet, often taking during short periods on shore an excess of those articles of which they have been deprived whilst at sea. That it is the comparative abstinence from fresh vegetable food seems improbable when we remember the frequency of stone in India. That the influence of exposure to air and wind is in some way favourable to completeness of assimilation is perhaps the most probable hypothesis. Sailors are said to be great consumers of salt when on shore, but it may be thought difficult to see why salt meat, or fresh salt with meat, should be preventive of lithic deposits in the urine. Here, however, an important suggestion has to be made.

Dr. Bence Jones, in an important communication to the Medico-Chirurgical Society in November, 1843, showed that the urate of ammonia is made much more soluble in urine by the addition of a moderate quantity of sodium chloride. Bearing in mind Prout's opinion (sustained by Bence Jones) that uric acid probably in the first instance exists in the urine as urate of ammonia, we may have here a very important clue to the explanation of the formation of calculi. It may be that the tendency to calculous formations is much greater in those who take but little salt. Some persons, as a matter of individual taste, take very little salt, and some take it very freely. These tastes are transmitted hereditarily, and may become prevalent in certain families or even races. In some communities and districts the consumption of salt may be much reduced either by custom or by difficulties in obtaining it. On the other hand, under some conditions of life (sailors, for instance), the free consumption of salt may be more or less compulsory.* Another point in reference to the free use of salt is that it increases thirst, and thus leads to the drinking of large quantities of water, the solvent action of which may in its turn further reduce the tendency to calculous formation.†

* Dr. Hutchison calculated that in naval hospitals only one in ten thousand patients was a case of stone, whilst Dr. Marcet had estimated that in the general hospitals of England and the Continent, Norwich excluded, the proportion was one in three or four hundred, and in Norwich itself not less than one in thirty-eight.

* In a short paper by Dr. Max Gruber, of Graz, on the 'Influence of Common Salt on the Reaction of Urine,' the author details the results of some experiments on dogs. The following are his principal conclusions:—

A meal rich in common salt, given to a dog after several days of a nearly salt-free diet, makes the urine intensely alkaline in a few hours. (1) The effect is proportionate to the dose. (2) Even after small doses the effect is noticeable. (3) The urine becomes alkaline after the injection of salt solution into the stomach, or into a vein. (4) The change is only noticeable for the first, or at most the first three days of the salt-diet, after which it regains its normal condition. (5) If a saltless diet be persisted in, the urine no longer becomes alkaline during digestion. (6) Hydrochloric acid is retained in the stomach and sodium carbonate eliminated.

The Essay from which these experiments are quoted is one of a series presented to the venerable Prof. Ludwig on his seventieth birthday by his pupils, and written expressly for that object.—'Beiträge zur Physiologie,' Leipzig, 1887.

† I had written all that occurs in the text above and had become deeply interested in the salt question before I knew that the whole subject had already been worked out. On a visit to Mr. Cadge, in Norwich, in May last, in search after facts as to calculus in Norfolk, I was made acquainted with a paper by Dr. Plowright, of King's Lynn, which I had previously overlooked, and with that gentleman's belief that the use of salt in food is an important factor in respect to the prevalence of stone. I have *since* read Dr. Plowright's very able papers, which contain a summary of much earnest work in search after the truth in this important matter, and I have had conversations with their author. He has investigated the statistics of stone in Norfolk in relation to the amount of chloride of sodium in the drinking water, and also the history of the frequency of stone with reference to the salt tax. I shall not attempt here to re-produce his detailed statistical statements, and no one would, I feel sure, be more ready than himself to admit that numerous possible fallacies are involved in them. Making, however, all allowance for risk of error, it is not easy to escape the impression that the facts do bear strongly in support of the belief that the free use of salt is a very valuable means of preventing urinary concretions. It acts not only as a base for lithic acid, but as a solvent for the colloids which take such an important share in the formation of the nucleus. In justice

There are probably many other questions of detail in reference to diet which it is desirable to keep in mind whilst investigating the causes of gravel and stone. I have already alluded to the possible influence of fruit in causing oxalates, and have also said that some patients experience a deposit of phosphates after taking certain wines. It is possible that other articles of food may have like results.

In his work on urinary diseases, page 286, under the head of phosphatic deposits, Dr. William Carter,* of Liverpool, states that "patients are frequently much concerned at observing a turbidity in the urine when first passed. I have known such urine to have been passed for many weeks together. The turbidity seldom affects that which is passed the first thing in the morning. But the urine at other times of the day is alkaline or neutral, coated often by a greasy film, and throws down a dense deposit of usually amorphous phosphates." He describes the turbidity as greatest at the end of micturition, and says that the malady is usually cured by care in diet and the use of pepsine with nitro-muriatic acid. He cites two cases (page 82) in which this condition of urine was caused by taking oatmeal. In one of these a medical friend was inconvenienced by very frequent micturition. The urine was copious, acid when passed, but rapidly decomposed with abundant deposit of phosphates. Dr. Carter directed his friend to leave off oatmeal porridge; and with great advantage. When it was taken again after an interval the same symptoms followed. In a case in which the free use of oatmeal was prescribed experimentally similar results were produced. He believes that the too free use of "scones" is also liable to suspicion in the same direction.

Many of the Indian uric-acid calculi are very deeply coloured, and some of them of a peculiar tint of red, not often seen in English stones. A collection in the College of Surgeons' Museum, presented by Mr. Holmested, illustrates this remark. One of them is very dense, quite smooth in section, and of a purplish-red colour. Mr. Bransby Cooper mentions, amongst those which he examined, "one of a peculiarly red-tinted uric acid mixed with urate of ammonia." This fact is not without its interest in connection with Dr. Ord's experiments, which seem to show that colouring-matter exercises an important influence in determining the sedimentary urinary form of uric acid.*

As an interesting illustration of how completely one generation sometimes rids itself of the prejudices of a predecessor, we may note that a dietist of the present day is found timidly apologising for allowing lithiasis patients any meat whatever; whilst little more than fifty years ago Dr. Marcet wrote:—"It may be worth while to observe that however useful animal food may be in counteracting the generation of acid, it would probably not be found advisable to restrict calculus patients to the exclusive use of animal food with a view to produce this effect." He adds farther on:—"It might be found detrimental to restrain patients affected with this kind of calculus (lithic acid) from taking a due proportion of vegetable nourishment." In Dr. Marcet's day vegetables were supposed to be the

---

to Dr. Plowright's researches I append his conclusions in his own words. His paper is to be found in the 'Medical Times and Gazette,' Oct. 10, 1885:—

"The conclusions I would derive from the foregoing are:—(1) That there exists in Norfolk a district (Marshland) in which calculus is much less common than in other parts of the country. (2) That in Marshland the natural water-supply contains a large proportion of salt. (3) That calculus was relatively more common during the period of the salt tax than before or after. (4) That the disease is rare amongst sailors who consume much salt. (5) That it is more common amongst the children of the poor from whose dietary salt is almost absent, than amongst those of the middle and upper classes, where this is not the case. (6) That the disease is common in India, where salt is taxed. (7) That the presence of salt greatly increases the solubility of uric acid. (8) That the consumption of salt by increasing thirst ensures a larger amount of fluid passing through the urinary tract, and therefore lessens the probability of calculus. (9) That by keeping the colloids equally diffused, salt tends to prevent the crystalline solids of the urine from agglomerating into calculi. And lastly, that the facts above stated warrant us in recommending a more liberal consumption of salt by those who are in any way threatened with calculous disease, either by hereditary tendency or by premonitory symptoms—especially those at the two extremities of life who reside in calculous districts. Particularly does this apply to infants and young children—the former, of course, through the mother, for we know that sodium chloride is one of those salts which freely passes from the maternal system into the mammary secretion." Dr. Plowright has followed up the subject in more recent papers; see 'British Medical Journal,' Nov. 7, 1885, and a pamphlet on the 'Cause and Distribution of Calculous Disease,' 1886.

* Dr. Carter's cases appear to be examples of what, when in a severe form, is known as phosphatic diabetes, or, more properly, polyuria without sugar and with excess of phosphates (sugar may be found later on in the case). This condition corresponds with Prout's azoturia. Dr. Dickenson was the first to point out that in certain cases of polyuria there was a great excess of the earthy phosphates, and to connect it with tissue-waste. In a paper by Dr. Ralfe two cases are mentioned, both in delicate young men. ('Pathological Transactions,' Vol. XXIX., p. 152).

* 'Medico-Chirurgical Transactions,' 1876.

source of the acidity or "acescent tendency," which resulted in calculus. This view of the matter is worth keeping in mind in reference to the remarkable and unexplained frequency of calculus among the natives of India.

The Distribution of Calculus in reference to Climate, Race, &c.—The distribution and prevalence of calculous disorders, in reference to climate, race, and position in life, offer most attractive subjects for investigation. It might at first sight be supposed to be comparatively easy, since the diagnosis of stone and gravel is not difficult, and examples of their occurrence attract the attention of all concerned, being readily remembered and usually accurately registered. There are, however, as yet certain special difficulties which prevent our feeling sure that the facts as we now possess them are quite trustworthy. Thus, respecting many countries and races, we have only the impressions received by medical travellers who resided for only short periods in the places concerning which they report. Next comes the fact that the statistics of cities, if these be placed in large districts not well supplied with operating surgeons, may, by the attractions of hospitals, represent a seeming prevalence of stone far greater than is really the case as regards the whole population. In other words, we can never accurately estimate the population from which any given institution, with the statistics of which we are dealing, draws its patients, and until we can do this it is impossible, without much risk of error, to state the percentage of those who suffer from stone. It might at first sight be thought that the mortality statistics would help us, but here occurs the overwhelming fallacy that stone is a curable disease, and that wherever it is prevalent there usually skill in its treatment is developed, and the deaths become fewer. There can be little doubt that the mortality from stone in adults has much diminished of late years, and that it will diminish still more in the future; but this will not prove any reduction in its prevalence. It must be noted also, as a possible source of error in our impressions, that in some instances in which statistics have been collected they have been formed on the deaths from stone, and in others upon the cases presenting themselves for operation. If, however, we carefully keep in mind, in our enquiries, these various sources of error, and make due allowance for them, we may venture to trust the general bearing of the facts.

For the purpose of this enquiry we may count all calculi as belonging to the uric acid group, with the single exception of the phosphatic stones. Uric oxide is only a variety of the uric acid, and besides, both it and xanthine are so rare as not in any way to affect statistics. Oxalate of lime may be reckoned as a modification of uric acid, and as depending upon the same diathesis. The two always go together as to frequency, and are, indeed, often mixed in the same concretions. Respecting the phosphates the case is different, for, if we make allowance for a small number which may possibly be primary and result from diathesis, they always imply some disease of the urinary organs, and must be expected to occur wherever such affections as paraplegia, stricture, enlarged prostate, chronic cystitis, and vesical fistulæ are met with. In districts where calculus is reported to be almost unknown it is probable that the exceptions will concern phosphatic concretions. These we must expect to meet with now and then everywhere, and in all races.

Our enquiry, then, concerns the local (or geographical) and race prevalence of the lithic acid diathesis as evidenced by the occurrence of calculus in the bladder. In the first place let it be stated that if we seek for the causes of varying prevalence of this diathesis, we have before us a problem which has not as yet received its solution, and which, indeed, in spite of the great labour already devoted to it, seems almost as far from being understood as ever. We have stone so exceedingly common at the Norwich Hospital that one or more operations are performed every month, whilst at Belfast it is so rare that a student may complete his curriculum without having ever seen a single case.* We have it unknown, or almost so, in the African races,† whilst it is so common in India that it has been asserted that "walls might be built or garden paths covered" with stones obtained from the human bladder. Again, we learn that it is very common in and around Moscow, but exceedingly rare in other parts of Russia, a precisely similar statement being true of the Canton district and the rest of China. Such facts are

* In reference to the frequency or otherwise of stone and lithiasis in Dublin, I may note that Dr. Stokes, in his admirable lectures, which embrace such a wide variety of clinical topics, does not mention either lithic-acid calculus or gravel. He has, however, a good deal to say about gout.

† No. 2214, 33, in the Guy's Hospital collection, is a urate and oxalate stone from a negro boy at the Cape.

exceedingly difficult to explain, excepting on the *prima facie* hypothesis that calculus must depend upon peculiarity in the geological formation of the district and the water-supply which it yields. It seems impossible that diet, climate, or race can have much to do with the question. But this plausible conjecture as to water-supply, although at one time warmly espoused by some investigators, breaks down entirely when it is critically examined. In the first place the chemical ingredients of human calculi—uric acid and its allies—have no special affinity with the constituents which give peculiarity to drinking-water. They are animal compounds, not mineral, and it is difficult to see what hardness in a drinking-water can have to do with their excretion. In the next it is matter of notoriety that of the adults who suffer from stone a majority are precisely of the class who drink least water. Lastly and conclusively, it is impossible to assign any peculiarities to the geological formation or water-supply of the districts where stone abounds which are common to all of them, and which are not shared by others where it is rare.

Before proceeding further with speculations on this question it may be well to state the facts in somewhat more detail, and in the attempt to do this I shall avail myself freely of the excellent chapter on this subject in Hirsch's invaluable 'Handbook of Geographical Pathology.'* To take Asia first, stone is reputed to be common in Asia Minor, Syria, Mesopotamia, and Persia, but its chief seat is India.† Although met with over the whole empire it is commonest of all in the north-western provinces. Dr. Curran, to whose zeal we owe valuable observations, holds that it is more frequent on the whole in the hill-districts than on the plains, and states that in some places it assumes the character of an endemic disease. It is extensively prevalent in Orissa, but more rare in the southern or Madras Presidency.* In Canton there is a special hospital for stone, but, excepting in this district, it is believed to be almost unknown in China. In Australia, Polynesia, and New Zealand lithiasis is almost unknown.

In Africa; Egypt, the Highlands of Abyssinia, Madagascar, Port Elizabeth, and Mauritius are places where it is believed to be fairly common; but in all other parts of this continent it is exceedingly rare.

In Europe, stone is common in France, Italy, England, Scotland, a few isolated districts in Germany, some parts of Spain, Hungary, the Moscow district, certain parts of Turkey, and a few towns and villages in Greece. It is said to be endemic in one village in Malta, whilst rare in most of the Mediterranean islands. Holland has from the earliest times had the reputation of being the special home of lithiasis, but there is reason to believe that its frequency there has recently much declined. In the following districts of Europe calculus is very rare:—Norway, Sweden, Denmark, Iceland, the whole of Russia excepting near Moscow, the greater part of Germany, all Switzerland (almost unknown), and Ireland.†

If we ask in more detail as to the prevalence of stone in England in different counties and districts, we find that the highest mortality is in the eastern counties, and the eastern and northern midlands. In Norfolk it rises to 1 in 42,744, whilst in the north-western counties it is only 1 in 209,681, or about that of Ireland generally. It must, however, always be borne in mind that mortality statistics are not a trustworthy measure of the real prevalence of lithiasis. The majority of cases of the latter attended by stone in the bladder occur in children, and are cured with but very few deaths. The mortality records concern adults chiefly. Thus it will be seen that the mortality from stone is as great in Ireland as it is in the western parts of England, whilst there is reason to believe that the number of stone cases is far less. Making, however, all allowance for this source of error, it is yet

* See New Sydenham Society's translation, by Dr. Creighton, vol. iii., page 460.

† The facts as to calculus in India are worthy of very careful examination on the spot. It had been asserted that it occurred only in Mahommedans, but Dr. Curran assures us that it is equally common amongst the Hindoos. In some districts it is said that oxalate-of-lime stones are more than usually common, but, as a rule, I believe that the calculi of India are lithic acid. I have myself seen a large box-full (possibly a peck) sent home by an Indian operator, and almost all appeared to be of lithic acid. The phosphates as encrustations are certainly rare.

* As a warning against the premature acceptance of the statements of travellers, it may be mentioned that not so very long ago it was held that India enjoyed an exemption from calculus.

† Amongst the poorer classes of the Irish it may be said to be unknown. In the town of Cork there were thirteen operations in eighteen years, and in Dublin only five in each year. The mortality returns for Ireland generally show only one death to 214,740 population. The facts have been carefully examined by Dr. Yellowly.

very difficult to explain the statistics which are offered us from Scotland. Here, in the birthland of Hunter and the cradle of surgeons, we find the mortality from stone double what it is in England. It is difficult to believe that this implies a double ratio of prevalence of lithiasis, and yet it is hard to conceive why amongst the Scotch, who are good patients, and who readily resort to the excellent aid which is abundantly provided for them, the mortality should, without excessive prevalence, rise to so high a point. According to Hirsch (see page 470) the mean death-rate from stone in Scotland is 1 in 51,903, whilst in England it is only 1 in 100,331. Yet Mr. Cadge has calculated that the ratio of stone cases admitted into Scotch hospitals is only half what English hospitals receive.* As to relative local prevalence in different parts of Scotland, Dr. Hirsch could not get many facts, but there appears reason to believe that in the Aberdeenshire district stone is especially common.†

In the Western Hemisphere calculus is, with a few exceptions, decidedly rare. The exceptions are Canada, the city of Boston, and possibly some parts of Brazil. The negro population is not more prone to the disease in America than the same race is in Africa. Stone is said to be almost unknown in negroes. As has been already mentioned, the College Museum contains a number of mixed uric acid and phosphatic stones removed from a negro boy in Alabama, but it is of course possible that he may have had European blood.

In the city of Boston (U.S.) there appears to be evidence of considerable decrease in the disease of late.‡

One of the first questions which occurs to us in seeking to find reasons for the local prevalence or otherwise of lithiasis is whether there is a close bond of connection between it and gout. We should certainly have expected that there would be one, and the belief of English observers assuredly is that the two maladies, though not very often met with in the same person, are closely associated in near relatives. Thus one brother may have gout, and another, passing lithic acid in excess, may escape the results of its retention in the blood, but have a calculus form in his kidney. If, however, we regard the fact that lithic-acid stones are common in India, where gout is unknown, we are obliged to admit that there must be some law regulating its prevalence with which we are not yet acquainted. In England gout is probably far more common in London and some of the south-coast watering-places (Margate, Ramsgate, and Brighton) than it is in Norwich and amongst the agricultural classes of Norfolk; yet stone is far more common at the latter place. Gout is rare in Scotland, but I believe fairly common in Dublin; whilst the reverse holds true as to calculous disorders. The surgeons of Norfolk have exhausted their ingenuity in attempts to find an explanation for the extraordinary prevalence of stone in their county. That they have found it a difficult, or, we might almost say, an insoluble problem, is perhaps proved by the fact that one of the latest hypotheses advanced has been that it is caused by a deficient supply of milk to the children. This may be bad in Norfolk, but it is impossible to believe that in an agricultural county it is really worse than it is in many other districts, and especially in some of our large towns, which are comparatively free from stone.

If we think to find an explanation of our difficulty by reference to peculiarity of race, and adduce the fact that negroes all over the world appear to be free from the tendency to lithiasis, we are again confronted with a host of facts on the other side. The Chinese of Canton and the Russians of Moscow suffer, whilst those of the same race in other parts of their countries escape. The populations of Norfolk and East Yorkshire, where the disease is common, are largely drawn from the Scandinavian countries, where it is almost unknown. The population of Belfast, —the city of Ireland which is most nearly free from stone,—is probably the one in which the Scotch element is largest, and in Scotland stone is abundant.

* Some further investigation of these remarkable figures is clearly needed, and an explanation of their real meaning, such as only those on the spot are competent to afford. I hope that the matter will be taken up by some of the many Scotch surgeons capable of dealing with it.

† Since this was written I have been made acquainted with some important facts collected by Mr. Plowright, which to some extent answer the questions proposed.

‡ A very remarkable diminution in the number of stone cases was observed at the Bristol Infirmary in the beginning of this century. In the decennium 1750 and 1760 no fewer than 83 operations for stone were performed (eight per annum), whereas between 1810 and 1818 there were only 10 (one per annum). The diminution of stone cases in Holland has also been alluded to, and there is reason to think that similar statements may be true of many other districts, perhaps of almost all where stone has been common in former times. See Mr. Hutchison's paper, 469.

Taking a more limited view of the term race, we may admit—and it is almost the one solitary ray of light in the picture—that it seems highly probable that lithiasis is a malady which prevails from generation to generation in the same family. This fact probably to a large extent explains its prevalence in certain towns and locally isolated districts. We may perhaps even venture to use this supposition as explanatory of the facts as to the Moscow district and the several districts in Germany where the disease is, on a somewhat large scale, endemic. Some prepotent ancestor in times long past may have suffered from the tendency, and may have become the progenitor of a large section of the population. There is a feeling of improbability, however, in pushing such a supposition very far, or in asking that it should be believed that a tendency so acquired would, in a district where the conditions were inimical, survive in intensity through many generations. It is further to be remarked that the explanation by heredity, although it may be good for the facts under present observation, does not serve us as regards the past. A man must acquire before he can transmit, and our demand is to know what are the conditions which originate the lithic acid diathesis *de novo*, or which specially favour the further development of it when acquired.

If we may argue from certain matters which are daily under our observation in English practice, we should certainly say that the free use of animal food, of beer and wine, of sugar and fruit, especially of all these together, and in conjunction with deficient exercise, favours the production of free uric acid and its allies. Many persons can, indeed, produce deposits of these salts almost at will. Especially does the addition of certain fruits favour the deposition of oxalate of lime. As regards lithiasis, English practitioners firmly believe that a diet in which animal food is restricted and green vegetables plentiful (not fruits), with abundance of exercise and water-drinking, are measures which almost certainly preclude the occurrence of the deposits in question. It is probable also that those who drink freely of diluents are far less likely to suffer from urinary depositions than those who allow the excretion to become too concentrated. In this last remark we may perhaps have some explanation of the supposed influence of a liberal supply of good water in preventing stone. How far it may go in explaining the prevalence of stone in India, where it occurs in spite of the restricted and for the most part vegetable diet, I do not know, but it is a matter worth enquiry both there and elsewhere where lithiasis is endemic. It seems scarcely worth while to discuss the question of climate, for it is perfectly clear from the statements already made that neither cold nor heat, dampness or dryness, nor any other of the variously complicated influences which are classed together under that term, have anything important to do with the prevalence of stone.

The gradual reduction of the number of stone cases in certain places might possibly, if the facts were carefully investigated, afford valuable information. As long ago as the time of Camper it was believed that the number was diminishing in Holland, and subsequent observers* have believed that the reduction is progressive. In the city of Boston (U.S.) it may plausibly be explained by the suggestion that the conditions of life there are inimical to the diathesis, and that in the first instance the unusual prevalence was due to the immigration of families in whom the malady was hereditary.

The remarkable prevalence of stone in certain parts of India is a fact of such extreme importance for elucidation that I shall deal with it in rather more detail. Many Indian surgeons have published valuable collections of facts respecting it. The following record may, I believe, be selected as giving a good illustration of the whole:—

Surgeon-Major Keelan, of Hyderabad (Sind), in a practical paper on lithotomy in the 'British Medical Journal' of October, 1887, gives us some important facts as to the prevalence of stone in that district. He operated on no fewer than 188 in one year, and has a collection of 1000 stones, which he expects, in the course of five years, to increase to 2000. All the facts as regards the ages most liable, and the relative frequency of the different constituents of the calculi, with which we are familiar in England, seem to be repeated there. 120 of the stones were uric acid, 40 the black oxalate of lime, 5 the white oxalate, and the remainder of other formations; 2 were believed to be xanthic oxide and 3 cystic oxide, but the evidence as regards

* In 1802 Schultens published a thesis, 'De causis imminutæ in Rep. Batava morbi calculosi frequentiæ.' In it full statistics are given of the operations for stone in Amsterdam during the eighteenth century, showing a reduction of one-half between the beginning and the end of it. I am indebted to Professor Tilanus, of Amsterdam, for drawing my attention to this essay.

these is perhaps not conclusive. 105 of the patients were under the age of twenty-five, and 163 were Mussulmans and 25 Hindoos. Out of the 188 there were only 7 females. Mr. Keelan believes that his collection shows that the nucleus is usually of oxalate of lime. He thinks that the drinking-water may perhaps have something to do with the prevalence of stone. All his patients were, he believes, in the habit of drinking the muddy water of the Indus laden "with silt," which, as is the case with the Egyptians and the Nile water, they prefer to water made clear by filtering. It is scarcely fair to Mr. Keelan, though not closely cognate with our topic, to omit saying that of the 188 patients, of all ages, he lost but 8, and it would certainly not be fair to surgical statistics to omit qualifying this by adding that he carefully refused all feeble and very old patients.

Mr. Bransby Cooper, in a paper in the Guy's Hospital Reports, seems to have been the first to recognise the interest of the subject of calculus occurring in India, in reference to peculiarities of food and mode of life. He had thirteen calculi from natives of the Punjaub put into his hands by Mr. Coles. He found uric acid abundant and oxalate of lime rare, and was obliged, after careful investigation of the subject, to record his conviction, that "after all there are causes in operation in the production of stone altogether independent of the nature of the food." Mr. Cooper found the nucleus to consist of urates in almost all the thirteen stones. Dr. Vandyke Carter in 1873 examined the calculi in the Bombay Museum with great care. The principal result was the observation that a larger proportion in India have oxalate of lime as the nucleus than in England, and a smaller one uric acid. Thus in an average of three English museums, uric acid or urates form the nucleus in 71·79 per cent., but in Bombay of only 56·30 per cent. On the other hand oxalate of lime is the nucleus in Bombay in 38·65 per cent., but only of 16·87 per cent. in the English museums. A very large proportion of the Bombay calculi were from natives of Bombay *itself*, some from the Punjaub.

Dr. Playfair, 'Edinburgh Medical Journal,' has noted the infrequency of stone in the Bengal provinces, and contrasts it with the frequency in the north-west. He attributes the difference to the use of rice in Bengal, and of a coarse wheat-flour in the north-west provinces.

Dr. V. Carter notes the comparative rarity of the mixed or fusible deposit in Bombay, a fact which my own examination of Indian calculi in our College collections fully corroborates. He thinks, however, that phosphate of lime stones (not prostatic) are more common in India than in England. "Phosphate of lime," he says, "is commonly associated with the oxalate, whilst cystitis and the mixed phosphates resulting from it are rare."

In Bombay Parsees are believed to be most liable, and Hindoos the least so. Mussulmans are more liable than Hindoos; but Dr. Carter, who struggles against the conclusion, is fain to admit with Mr. Cooper, that between the vegetable-feeding Hindoo and the meat-eating Mussulman, there is not the difference as to calculous disease which might have been expected.

In the Catalogue of the Pathological Museum at Calcutta I find no mention of any collection of calculi, whilst in the museum at Hyderabad, as just mentioned, there is the imposing array of 1000. A paper on lithotomy at Calcutta, however, by Sir Joseph Fayrer, enables us to correct any impression as to extreme rarity of stone in that district. His valuable paper is characterised by the candour of statement which his writings always display. During eleven years he operated in hospital upon fifty cases, these being about half of the total during that period. Many of the patients had come to him in extreme states of illness, and the mortality was 28 per cent. All the boys recovered. The calculi were for the most part uric acid, with or without phosphatic encrustation, but there was "an occasional example of oxalate of lime." Nothing is said as to oxalate nuclei.

Amongst the possible causes of calculus in India the position which males invariably adopt for micturition has been quoted. This position is a squatting one, and it has been supposed that the additional difficulty incurred in completely emptying the bladder may conduce to the formation of stone. It is to be observed, however, that the relative frequency of stone in the two sexes appears to be the same in India as it is with us.

On Urinary Calculi in the Lower Animals.—Urinary calculi are not of common occurrence in our domesticated animals, and are probably still less so in those living in a wild condition. The College Museum contains six from the dog, all phosphatic; seven from the hog, two phosphatic and five carbonate; seventeen from the

horse, all but one carbonate; one from the ass, carbonate; twelve from the ox, all but one carbonate; whilst the sheep affords only a single specimen, and it (exceptionally) of urates. It is well known that the herbivora are liable to carbonate of lime concretions in connection with the state of alkalinity which is the normal state of the urine in them.

A specimen of a carbonate of lime urinary calculus from an ass was shown by Mr. Shattock at one of the Pathological Society's meetings, and with it one of a similar character from a dog. In connection with them Mr. Shattock remarks that carbonate of lime calculi are as frequent in the herbivora as are those of uric acid in man. It is difficult on such a point to collect statistics, but I cannot but believe that this is an exaggeration. It would be of great interest to ascertain whether calculi in the domestic animals are more common in some districts and some countries than in others.

Consistently with what we should expect from the general sameness of diet and absence of drug-treatment in animals, their calculi very rarely show any alternation of layers.

On Calculi of Unusual Size.—Amongst calculi of unusual size must be mentioned one weighing thirty-three ounces, of which a cast is in the Museum of the College of Surgeons, the original being in the library of Trinity College, Cambridge. It is of uric acid, and was removed from a woman after death. The College Museum also possesses the cast of a very large stone successfully removed by Mr. Thomas Smith by suprapubic lithotomy. It weighed twenty ounces and a half, and measured eleven inches and a half by nine and a half. A remarkable feature in this case, but at the same time one which we encounter in almost all cases of calculi of extraordinary size, whether in the kidney or bladder, is that the patient had not had much inconvenience until latterly. He was a soldier, and had been invalided only ten weeks. The stone consisted of oxalates and uric acid, with finally an encrustation of phosphates.

In 1886 Mr. Rivington operated, at the London Hospital by suprapubic lithotomy, for a stone of very large size. Its fragments weighed, after removal, twenty-three ounces and a half.

One of the largest lithic acid stones on record is that which was removed after death, at the age of 81, from the bladder of Sir Thomas Adams. This gentleman had led an active life, and presumably had not failed in health until late, for at the age of 74 he accompanied General Monk to Breda to invite the return of Charles II. The stone weighed 12,000 grains (25 ounces). It is now in the Museum of St. Thomas's Hospital, and by the analysis of Mr. Stewart is stated to consist of uric acid, with a small trace of urate of lime.*

In a case recorded by Mr. Southam, in which, in consequence of the known large size of the stone, he performed a recto-vesical operation, the stone (phosphatic) weighed nearly five ounces, and its diameters were two inches and a quarter by three and a third.

Weights of Renal Calculi.—Civiali states that Pohl found in the kidney of a princess a stone which weighed five pounds! Putting this case aside, Dr. Gee believed his own to be the largest on record, nine ounces being the next (see p. 80, Medico-Chir. Trans., 1874).

Of calculi found in the bladder after death the following are some of the heaviest on record:—

Morand	6 pounds.
Deschamps	51 ounces.
Sir Walter Ogilvie's (phosphates)	44 ,,
The Trinity College specimen (uric acid)	33 ,,
Sir Thomas Adams' case (urid acid)	25 ,,
Mr. Paget's case (Leicester)	27 ,,

The following are some of the largest removed during life:—

Utterhævens' measured in girth 16½ in. by 12¾ in.
Joseph Hunter (Madras), weighed 25 oz.
Dr. Morrison (Northumberland), weighed 1 lb. 6¾ oz.
Sir H. Thompson, 14 oz. (avoirdupois).†

Accretions on Foreign Bodies.—When foreign bodies gain access to the bladder they always sooner or later become coated with deposit. The rapidity with which this is effected, and also to some extent the character of the deposit, will depend upon the state of the urine and bladder at the time. The commonest deposit is the mixed phosphates, and this occurs in connection with cystitis, the effusion from the bladder-walls of phosphate of lime, and the production of triple phosphate by decomposition of urine. If cystitis already exist, the deposit of these salts will take place immediately. A few days may, as is well known, suffice to coat thickly the end of a catheter which has been

* See Pathol. Soc. Trans., 1870, p. 269.

† I have not attempted any exhaustive statement of facts as to calculi of unusual size, but have quoted the above (chiefly from Mr. Rivington's paper) by way of examples. Some risk of error must be allowed for on account of different standards of weight.

retained in the bladder. In a specimen to demonstrate this, which has been preserved in the Museum of St. George's Hospital, the catheter had been kept in only four days. If the bladder be healthy at the time a certain period must elapse, varying in different cases, to permit of cystitis being set up. Although the most frequent, mixed phosphates are not the only salts which form these concretions. In the College Catalogue a specimen is both described and figured in which a pin became the nucleus of a large uric stone, but it is especially stated that this is a most exceptional event. Possibly, however, it is not quite so exceptional as it has been deemed, for I find that in a series of about ten specimens of foreign bodies from the bladder in the St. Thomas's Hospital Museum it is expressly stated in almost all that uric acid formed part of the concretion. In one instance the phosphates appear to have been absent, and it is stated that a needle was coated with oxalate of lime and uric acid. All depends, no doubt, upon what salts are at the time in excess in the urine. If uric acid be sufficiently plentiful to form quickly a protecting encrustation on the foreign body, the bladder may then escape the attack of cystitis, by which under other conditions the phosphates would have been produced.

The appended woodcut shows the remarkable efficiency of the bladder contractions in doubling-



up into a sort of knot a flexible bougie which had been introduced into it. It was removed by lithotomy from the bladder of a man by Sir Everard Home, and was, when recent, encrusted by fusible phosphates.

In the next woodcut is represented a hat-pin, which was removed from the bladder of a woman,

having a nodular mass of phosphates on one end. A much larger mass is seen in the appended figure, concreted around the larger end



of a silver bodkin. This specimen was formerly in the British Museum, and is described and figured in Rymsdyk's 'Museum Britannicum.' The mass consists of mixed phosphates.

The College Museum contains many other specimens of concretions around foreign bodies, but they all illustrate the remarks made above.

CONCLUDING REMARKS.

If we now, in conclusion, attempt an enumeration of the various conditions which may favour the formation of urinary stone, the following are probably the principal :—

(*a.*) First and most important of all, a tendency to the existence in excess in the urine of some constituent which is not easily soluble. This may be either uric acid, urates, oxalate of lime, xanthine, cystine, phosphate of lime, triple phosphate, or carbonate of lime. At first sight it might seem probable that the secretion in excess of one or other of these salts is almost a necessary condition to the formation of the special calculus concerned, but very little consideration is necessary to realise that it may be a question of deficiency of solvent powers in the urine, rather than of absolute excess of the salt to be dissolved. Respecting each one of the substances mentioned, there have been those who have contended that the solvent power of the fluid is by far the most important factor, if not the sole one. There can be no doubt that the truth lies midway. Cystic oxide offers us, perhaps, the most conclusive instance of the excess of a particular ingredient, leading almost of necessity to the formation of a concretion. Whilst it is quite possible that the opinion of Dr. Bird, partially sustained by Dr. Prout, may be correct, that many persons have a small quantity of cystine in the urine, it yet appears to be highly probable that whenever it is present in any degree of abundance, the formation of a concretion is an almost necessary result. What is true of cystine is probably true in less degree of uric acid, oxalate of lime, and the rest.

(*b.*) Next in importance to excess of some calculus-forming ingredient, must be mentioned deficiency of the solvent. Although some of the substances which form stones are when pure but little soluble in water, there is no doubt that they all are more or less so when developed in a nascent condition, and in association with other urinary ingredients. It therefore becomes of the utmost importance that the total quantity of the urine should be adequate. Thus a supply of pure water and a systematic cultivation of the habit of drinking it in liberal quantities, is probably one of the best means of diminishing the frequency of stone in any given community, and in seeking to explain its prevalence or infrequency in any stated locality, primary attention should be paid to this point. The solvent properties of the urine may, however, be increased irrespective of its increase in quantity. Thus a sufficient supply of alkalies, whether taken as such or in the form of green vegetables, is a very important means of promoting the solution of some of the commonest ingredients of calculi. There is also good reason to believe that common table salt possesses great efficiency in this direction. Its consumption diminishes indirectly the deficiency of urine, prevents the formation of colloids, and very much helps the solution of the compounds of uric acid. This is a point which in India, Moscow, Norfolk, and other places is worthy of the most serious attention.

(*c.*) In the third place must be mentioned conditions which favour the formation of nuclei. It is well known that patients may pass uric acid, oxalate of lime, or phosphates in great excess for long periods, yet never get stone, on account of the media not being favourable to cohesion of the particles. Any inflammatory attack may, by supplying mucus, become the determining cause of a concretion in any part of the urinary apparatus. So probably the development of oxalate of lime in the urinary tubules in a patient who is habitually passing uric acid, may serve as a centre of concretion. Certain colouring matters may do the same. Foremost, however, among the causes of the formation of nuclei, must be placed all influences which tend to prevent complete emptying of the bladder. If the urine is left stagnant, aggregation of its salts in concrete masses is greatly favoured; and it can be easily understood that this is especially the case, when the last portion of the urine is habitually retained. The difficulty of emptying the bladder completely in enlarged prostate is probably one of the chief causes of the frequency of stone in men past middle age; whilst the ease and certainty with which the bladder is completely emptied in women is probably one of the chief causes of their comparative exemption.

In mentioning an excess of certain insoluble substances in the urine as being obviously one of the chief causes of concretions in the urine,

it is clear that we take but one little step. The important question remains, how do those substances come to be present in excess? The answer to this question is extremely complex, and branches out in various directions. It would not be profitable to attempt to enumerate more than a few of the chief.

Excesses of certain elements of food or defects in the quality of the food, or defects of the assimilative power of the individual are no doubt of great importance, and they will be found treated of in ample detail in many of the excellent works which deal with this topic. It is, however, far more difficult than some of the authors of these works would appear to have realised, to establish satisfactory laws in respect to them. We may say at once, that there can be no doubt that hereditarily transmitted peculiarity of organisation is very efficient in giving tendency to stone. This peculiarity may be quite independent of everything that can be designated as ill-health. Many patients who pass uric acid or oxalate of lime, or who become the subjects of calculi consisting of these substances, appear to be leading very judicious lives, and to be in the enjoyment of excellent health. This fact is not unfrequently emphasised in cases in which a tendency to calculus prevails in families, and it is especially well shown in the case of the cystine calculus. It may be that the transmission of hereditary peculiarities as regards assimilation will explain a good deal as to the local prevalence of stone, and that it should be considered rather a family prevalence than an endemic one. It has been suggested that in those localities in Germany where stone appears to be restricted within very narrow areas, it is hereditary descent rather than dietetic or telluric conditions which determines its prevalence. We must not, however, push this doctrine too far; it is obvious that all hereditary diseases have been acquired in the first instance, and in a general way the tendency to them dies out unless the influences under which they originated are continually renewed. We must remember also, that in certain districts, inhabited by different races, there appears to be but little difference in the members of each as regards proclivity. Thus in India, Parsees, Mussulmans, and Hindoos, all suffer. Those who have investigated the facts as to the predisposition to calculus in England have almost unanimously believed that inherited tendency to gout is an important factor. Probably they are right to some extent, but how explain in this hypothesis the remarkable prevalence of stone in Norfolk, where gout is not more common than in other parts of England? Or, above all, how explain its frequency in parts of India where gout is unknown? The difficulty of explaining the prevalence of stone in India by reference to any peculiarity in diet has already been adverted to in some detail. And when we remember that it is almost unknown in negroes, the problem becomes almost insoluble. Had it been prevalent throughout the tropics in equal frequency, we might have believed that the too profuse action of the skin, by favouring concentration of the urine, was an important factor. But the exemption of many large tracts and some entire races discredits this suggestion.

The possible influence of the skin on the urine, by producing concentration, has been referred to in the preceding paragraph. Although it is scarcely consistent with facts, to suggest that high temperatures and the profuse sweating induced, are causes of the endemic prevalence of stone; yet it may be reasonably suspected, that when a definite proclivity exists, this influence may be importantly influential. Thus it is very possible in the inhabitant of a temperate climate, with an habitual tendency to the formation of lithic acid in excess, that the occurrence of dry hot weather, and its well-known attendant, concentrated urine, may be the turning-point as regards the formation of a concretion. It has been believed that certain skin-diseases, Eczema and Psoriasis for instance, are not infrequently the accompaniments of a tendency to stone. But it is very possible that the statements on this matter have been made on insufficient data.

In conclusion, we must not allow the consideration of details, such as those which have engaged our attention in the preceding pages, to conceal from our view the main facts. Whatever may be the importance of the precise mode of the formation of nuclei; however true it may be that local conditions of the urinary organs may favour the formation of stone, the fact remains, that a large majority of calculi must be regarded as primary, and as evidence of the existence of diathetic tendency. These tendencies, originating it may be in peculiarities of diet, climate, mode of life, &c., have become in the course of time hereditary, and are now the appanage of certain families and races. They are susceptible of modifications by the life-habits of the individual, but they are, when strongly marked, to a

large extent independent of them. The urinary disorders which result in calculus are, for the most part, simply expressions of peculiarities of assimilation. In diabetes* such a peculiarity finds its conspicuous expression in the presence of sugar with great excess of water; in lithiasis, in the presence of lithic acid, lithates, lithic oxide, oxalate of lime, with no excess of water; in the cystine diathesis, in the presence of cystine. No doubt a number of other diathetic states exist, modifications of some extent of the above, and only less common and less conspicuous than them. That a phosphatic diathesis in this sense of the words must still hold its ground seems highly probable; and since in the herbivora one such is found which expresses itself by the excretion in excess of carbonate of lime, it is highly probable that in rare instances we may recognise the same in man.

It is quite impossible to associate immediately, that is in the individual, these diathetic states with peculiarities in diet, climate, or habits of life, though all these may have remotely their share of influence in predisposing to or aggravating the condition when once formed. Nor, although some of them are closely allied, is it true that any one is identical with the constitutional condition known as gout. We must regard both gout and the various urinary diatheses as resulting from the hereditary transmission through many generations of peculiarities which have gradually assumed more or less of individual type. Whilst clearly admitting these facts as constituting the general basis of our creed, we must, on no account, lose sight of the other collateral ones which concern the modifications of the inherited diathesis in the individual who is its subject.

As regards the prevention of stone in districts where it is prevalent, we may, perhaps, at the risk of repetition, be permitted to insist on two paramount rules of diet: the free use of drinking-water and the free use of table-salt.

Postscript.—Those who desire fuller information on the subjects briefly adverted to in the above Essay, should refer, amongst others, to the following works:—

Marcet on Calculous Disorders. 1819.

Prout on the Nature and Treatment of Diabetes, Calculus, &c. 1825.

Prout on Stomach and Renal Diseases. 1848. Containing an admirable summary of statistical information as to calculus.

Owen Rees on the Blood and Urine in Health and Disease. 1845.

Lionel Beale on the Urine. [Dr. Beale's very able work is, I think, the only one which recognises the possible importance of the salt question. He denounces the cruelty of taxes on salt.]

Ralfe on Morbid Urine. 1882.

Carter (Dr. William) on Renal and Urinary Diseases.

Carter (Dr. Vandyke) on the Microscopic Structure, &c., of Calculi. 1873.

Sir William Roberts on Urinary Diseases.

An excellent summary of most of the above will be found in a recent (1884) work, as yet not translated into English, by Dr. Wilhelm Ebstein, of Gottingen, under the title of 'Die Natur und Belandlung der Harnsteine.'

The Catalogues of the Royal College of Surgeons, from which I have quoted so freely, are full of valuable information, and are liberally illustrated. The reader must be careful not to overlook the fact that in addition to Parts I. and II. there is a supplementary volume.

* It is well known that the diabetes of aged persons is often coincident with lithiasis, and were it not that the abundance of the solvent prevents the salts from showing themselves, concretions would probably be oftener noticed. Diabetes is a malady the frequency of which varies much in different countries, and some of the very imperfect facts which we possess, would appear to indicate that it prevails in the same communities as those liable to stone. Thus our earliest descriptions of it occur in Indian literature; it is said to be unknown amongst the negroes, and it is nearly twice as frequent in England as in Ireland. It is common in Norfolk, where stone is common; it is unknown at St. Petersburg and Copenhagen, and at both these places lithiasis is very rare also. (See Hirsch, vol. ii. p. 646).

AN

ATLAS OF ILLUSTRATIONS

OF

PATHOLOGY

COMPILED (CHIEFLY FROM ORIGINAL SOURCES)

FOR

THE NEW SYDENHAM SOCIETY.

FASCICULUS VII.

URINARY CALCULI AND GALL-STONES. (PLATE XXXII.)

ENLARGEMENT OF THE PROSTATE GLAND. (PLATE XXXIII.)

ENLARGEMENT OF PROSTATE, URINARY CALCULI, &c. (PLATE XXXIV.)

OSTEITIS DEFORMANS (PAGET'S DISEASE). (PLATE XXXV.)

WITH DESCRIPTIVE LETTERPRESS.

(PLATES XXXII. TO XXXV.)

LONDON:
THE NEW SYDENHAM SOCIETY.
1889.
AGENT—H. K. LEWIS, 136, GOWER STREET, W.C.

PLATE XXXII.

URINARY CALCULI AND GALL-STONES.

FIG. 1. A bone bodkin-case, with thread attached to its middle, which was removed from the bladder of a lady about a week after its introduction. It was already somewhat coated with phosphates. The case is recorded by Dr. Lever in the Guy's Hospital Reports, and occurred in the practice of Mr. C. Steele. The urethra was dilated with Weiss' instrument, for five minutes each day, for five days; and then easily admitted a pair of curved forceps. The foreign body was placed in a right direction by the fore finger introduced into the vagina. No incontinence followed the operation.

FIG. 2. A portion of sealing-wax doubled up and encrusted with phosphates. It was removed by lithotomy from the bladder of a man, aged 35, who had introduced it himself. (Mr. McWhinnie's case.)

FIG. 3. A urinary calculus, seen in section, of a very remarkable shape. It is almost exactly cubical on its exterior, but it will be seen in section that a large central portion is ovoid in form. This latter is somewhat porous in structure, while the exterior is very hard, but the whole consisted of oxalate of lime. The specimen is No. 2138 in the Guy's Hospital Museum; and is figured in the "Reports" by the late Dr. Golding-Bird.

FIG. 4. A calculus concretion which had formed on a bit of straw. It was removed after death from the body of a man, aged about 30, who had suffered from severe cystitis. Two careful soundings had failed to detect any concretion, but on a third and a fourth occasion the foreign body was discovered. The man was, however, too ill to permit of any operation, being apparently in the last stage of phthisis. It was ascertained from his wife that he had been in the habit of using straw as a catheter, and that on one occasion the straw had escaped from his fingers and passed into the bladder. The case is recorded by Sir Astley Cooper in the Guy's Hospital Reports, from the practice of Mr. Henry Norris, of South Petherton.

FIGS. 5, 6, 7, 8, 9, 10, 11, 12. A series of gall-stones, which were passed per anum. The case is recorded by Dr. J. W. Moore, of the Meath Hospital, Dublin, from the practice of his relative Mr. Hone Moore, of Anstey, Leicestershire. They were analysed by Mr. Abraham, who reported that they consisted of pure cholesterine. The largest weighed considerably more than half an ounce; it is figured 7 in the drawing, fig. 6 being a portion broken off from it. The particulars of the case are, that a stout woman of sallow complexion, aged 47, had suffered in March, 1884, from violent pains about the region of the gall-bladder. She recovered from the attack, but had slight recurrences at intervals. In July of the same year she had another very severe attack, with much vomiting and obstinate constipation. Various remedies were given to relieve the pain, but at length a dose of compound powder of jalap induced purgation, and brought away the largest of the stones. The small ones followed soon afterwards, and the patient recovered completely. Dr. Moore records at the same time another case (in the pathological section of the Dublin Academy of Medicine),

in which a calculus was voided by an elderly woman, which measured 2¾ inches in its short, and 3½ inches in its long, circumference.

FIG. 13. Shows the size and shape of a calculus which was voided by a woman, aged 53, who subsequently recovered well. The case is published in the sixth volume of the 'Medico-Chirurgical Transactions,' by Mr. F. R. Thomas, F.R.S. He records the case in order to point out "the great uncertainty practitioners occasionally labour under in forming a correct diagnosis in cases of ileus, and also to illustrate the dilatable properties of the ductus choledochus communis, without being productive of any material pain in the parts immediately concerned, or any disturbance to the system at large." The passage of the stone through the intestinal canal was attended by symptoms of obstruction, and, as the patient was the subject of an umbilical hernia, they were supposed to be attendant upon it. The patient and her friends insisted on deferring the operation which was proposed, and two doses of calomel, grs. 10 each, were given. On the fifth day from the commencement of the constipation the calculus was passed, and all the patient's symptoms were at once relieved. It weighed 228 grains, and had a circumference of 3½ inches. It was of light specific gravity, and floated in water. It is stated that the patient was a woman who had uniformly enjoyed excellent health, and who had never shown any symptoms of jaundice. Ten days *after* the expulsion of the calculus she had an attack of pain over the region of the gall-bladder, and at the same time had slight jaundice. It would appear from Mr. Thomas' narrative that this was the first time she had suffered from such symptoms, and it is definitely stated that it was her first attack of jaundice. It may be supposed probable that the symptoms of the passage of the calculus through the gall-duct, and those of obstruction due to its lodgment in the intestines, were merged into one attack. The case is, however, recorded especially to illustrate the absence of the group of symptoms usually supposed to denote the passage of gall-stones from the gall-bladder. Mr. Thomas records the interesting fact that he had often found the ductus choledochus much dilated at post-mortems; and that in two subjects, in neither of whom it was probable that gall-stones had ever existed, he could easily pass his finger from the duodenum into the gall-bladder.

FIG. 14. A large gall-stone, which was voided without any material trouble by an old woman upwards of 80. The interesting point in her case is that she had never in her life had any symptoms of liver disturbance; nor had the passage of the stone from the gall-bladder to the duodenum, or its transit through the intestine, occasioned her any pain. She was suffering from an attack of bronchitis, and was under the care of Mr. Simpson, of Fore Street, at the time the stone was voided. Her great age may, perhaps, to some extent be permitted to explain the absence of painful spasm, and the fact that she was suffering from another illness, may have led to the over-looking of any slight abdominal symptoms which were present.

FIGS. 15, 16, & 17. These specimens are described by Mr. Le Gros Clark in a communication to the Medico-Chirurgical Society, which may be summarized by the statement that a woman of 59, of previous good health, died after an eight weeks' illness with incomplete obstruction of the bowels. The cause of death was perforation of the ileum just above the cæcum. It appeared probable that the calculi had escaped from the gall-bladder eight months previously. The whole of the text of Mr. Le Gros Clark's communication is appended:—"On the 29th of January last I was requested by Dr. King, of Eltham, to visit Mrs. A—, who was suffering from obstinate constipation, with vomiting. She was a

rather stout woman, 58 years of age, and had generally enjoyed fair health. About eight months previously she had a similar attack of constipation, with great pain; and a hard tumour could then be felt in the right hypochondriac region. The existing illness commenced on the 18th of January, eleven days prior to my seeing her: the symptoms were constant bilious vomiting, accompanied by constipation and severe griping pain in the bowels. On the day that I first saw Mrs. A— the vomiting had become stercoraceous. There was at that time no tenderness of abdomen, no distention nor tympanites. The pulse was quiet, the tongue moist, and the countenance placid. Only fluid nutriment could be taken, and that in a small quantity. Warm water was thrown into the bowels as long as it could be retained, and a small quantity of feculent matter returned with it. An active aperient was then given, with opium; and free friction of the abdomen with castor-oil was ordered. Two days subsequently, on July 31st, a scybalous motion was passed, and the stercoraceous vomiting ceased. On February 10th bilious vomiting recommenced, and continued until the 18th. From that date till March 11th there was no vomiting, and the bowels acted daily, the motions being of a healthy character. From the beginning of the illness to this date the abdomen could bear pressure; and any pain was relieved by friction with castor-oil. The pulse ranged from 80 to 90 in the minute; the tongue was coated, but moist; solid food was not taken, except on one occasion. On March 11th bilious vomiting again recurred, attended with severe abdominal pain, principally in the region of the ileo-cæcal valve, where a hard tumour could be felt, and the belly became tympanitic; the pain was then much increased by pressure or friction. The pulse was rapid, and the tongue coated and dry. Death took place on the 17th, four days subsequent to my second and last visit, and at an interval of eight weeks from the commencement of the illness. There was no appearance of jaundice throughout this attack; and Mrs. A— had never suffered from jaundice at any previous time. The post-mortem examination revealed the existence of extensive peritonitis. Two large gall-stones occupied the ileum, close to the ileo-cæcal valve; and an ulcerated opening in the small intestine had permitted the escape of several small biliary calculi into the sac of the peritoneum. The liver was somewhat larger than natural, but otherwise healthy. The gall-ducts were dilated and thickened. 'The gall-bladder did not appear to be altered in character; nor was there any adhesion between it and the duodenum, or anything indicating that the concretions had ulcerated through into the duodenum from the gall-bladder.' I quote the words of Dr. King, to whom I am indebted for the history and most of the particulars of this case, as well as the post-mortem examination which he conducted, but which I did not witness. Each of the large concretions measure about an inch in length and four inches in circumference; and they weigh together nearly an ounce and a quarter. They appear as if moulded to the shape of the ileum. Mr. Wagstaff, who kindly examined both the larger and smaller specimens for me, reports that they consist of cholesterine only with bile pigment; and that the microscope shows no vegetable matter, nor anything added to the concretion in the intestines. Chemically the concretions yielded 95 per cent. of cholesterine, and 5 per cent. of animal matter. I think this case worth recording, on account of the rare size of the concretions, and the singular absence of any proof that they had passed from the gall-bladder to the duodenum by an ulcerated opening through their contiguous surfaces. Yet this is the only conceivable way in which such large bodies would have found their way into the bowel, especially without any attendant symptoms; and the absence of any preceding or accompanying jaundice proves that there could not have been any protracted obstruction to the passage of the bile from the gall-bladder or liver to the duodenum."

PLATE XXXII. (*continued*).

GENERAL REMARKS.

The gall-stones delineated in this Plate have been selected chiefly to illustrate the size of concretions which may escape from the gall-bladder, and pass more or less successfully through the intestinal tract. They are of great importance, in reference to the modern practice of operating by laparotomy and incision of the intestine in such cases. All the cases well illustrate the difficulties of diagnosis; in no one instance had definite jaundice attended the passage of the stone. Two of the cases seemed to show that the use of active aperients is very valuable, as aiding the passage of the stone through the intestine. It is possible that they might have been useful in the latter case also. Their mode of action is probably easily explained, in that they favour fluid distension of the gut above the stone which plugs it. It is easy to see that in this way it may be dilated, and the stone washed onward. It is not certain that, even in the last case, more free use of purgatives in the first instance might not have been beneficial. As it stands, it may certainly seem to be a fact in favour of operation in desperate cases.

II

III

V

VI

VII

VIII

IX

X

XI

XII

XIII

XIV

XV

XVI

XVII

West, Newman & Co. lith.

PLATE XXXIII.

ENLARGEMENT OF THE PROSTATE GLAND.

This Plate (copied from Mr. Stanley's work, with slight alterations) shows the relations assumed by the bladder and rectum in a case of enormous enlargement of the prostate. The bladder has been displaced upwards by artificial distension of the rectum, and the Plate thus well illustrates the recent teaching as to the importance of that measure as preparatory to supra-pubic cystotomy. The displacement is, however, probably greater than would have been possible during life. The prostate is seen as a mass the size of a large orange, and the canal of the urethra through it measures more than 3 inches. Thus the necessity in prostatic enlargement for a long catheter, and one with a large curve is well demonstrated. The thickness of the lower part of the prostate in section is nearly $1\frac{1}{2}$ inch. It will be seen that the prostate bulges into the bladder as an overhanging somewhat lobulated mass, both above and below. Behind and below the lower bulging (third lobe), there is seen a deep pouch, in which a calculus might have been lodged in such a manner as to make it almost impossible to discover it by sounding. The bladder itself was very much hypertrophied. It is to be noted that what is called the third lobe is continuous, without any kind of lobular division, with the base of the prostate. One ureter, and the left vas deferens, and vesicula are shown.

This drawing is of great importance for the surgical student; illustrating *firstly:* The almost impossibility of puncture by the rectum in certain cases of prostatic retention; *secondly:* The peculiarities as regards the use of catheters in these cases; *thirdly:* The all but insuperable difficulties in sounding; and *lastly:* The aid given by distension of the rectum in suprapubic lithotomy. Fig. 1 in the next Plate illustrates similar points.

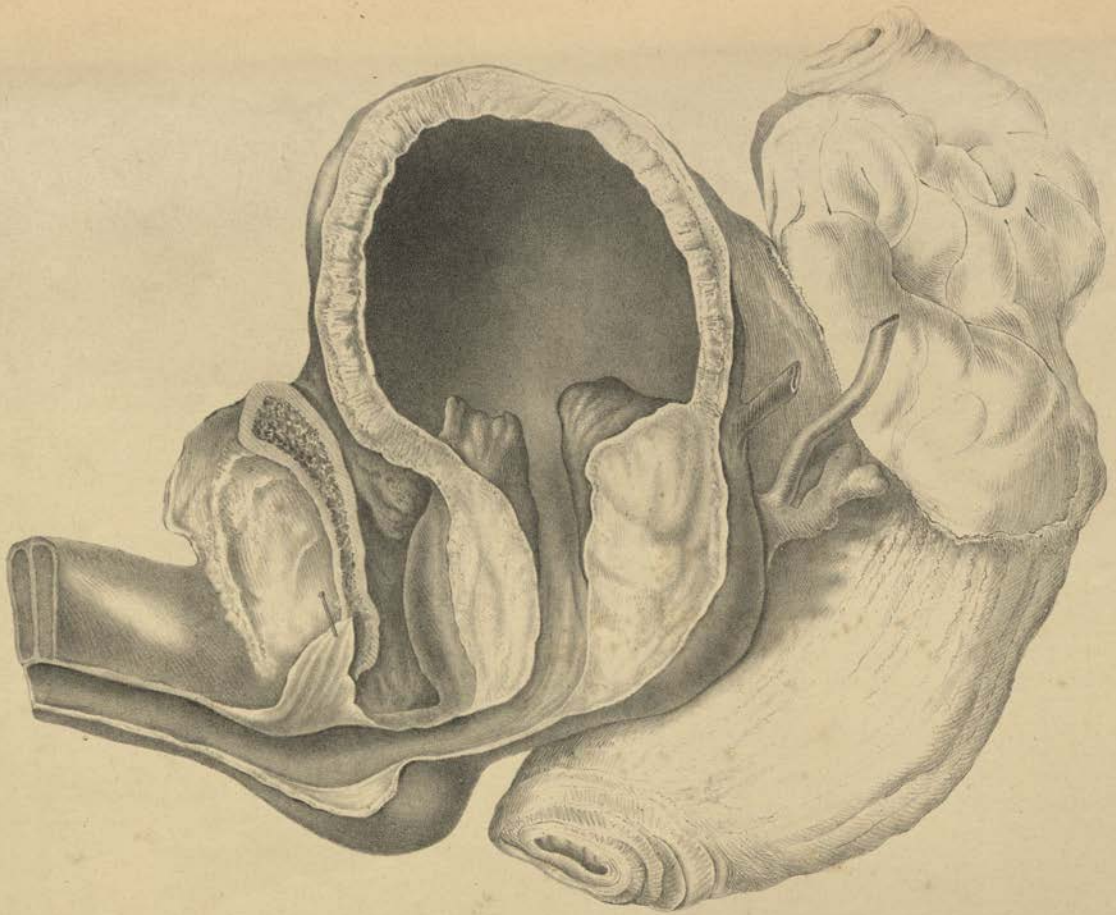

West, Newman & Co. Lith.

PLATE XXXIV.

ENLARGEMENT OF PROSTATE, URINARY CALCULI, &c.

FIG. 1. In the previous Plate the conditions of enlarged prostate are shown in a lateral section. In this one (which has been copied from Baillie's 'Morbid Anatomy') the bladder is seen laid open from above. As in the preceding portrait, the prostate is as large as an orange, and bulges into the bladder in all directions. The prostatic urethra, very much elongated, is flattened and diverted laterally, although not really narrowed. The possibility of a calculus, or indeed of many, being entirely concealed from the sound behind the bulging third lobe, may be easily conceived from an inspection of this drawing.

FIG. 2. A drawing to illustrate the condition presented by the impaction of calculi by the ureters. The ureters are much dilated, and there is a calculus in each. The fundus of the bladder is exposed, and the ureters are seen turned downwards. In the left ureter the calculus has all but gained the bladder. (From Baillie's 'Morbid Anatomy.')

FIG. 3. The spleen, both kidneys, bladder, and urethra of a dog. The left kidney has been converted into a single cyst by inflammation, consequent, no doubt, on the presence of calculi. In the contracted bladder are two large calculi which fill its cavity; the left ureter is very much dilated; the right kidney appears to be healthy, and its ureter is of normal size. It is clear from the fact that only one ureter is dilated, that the condition was not due to impediment in the exit of urine from the bladder, since under such conditions both must have suffered. There can be no doubt that the calculi were formed in the kidney, and that the dilatation of the ureter was due to their passage down it. The drawing is copied from a specimen which is in the museum of the Veterinary College.

FIG. 4. A kidney laid open, showing numerous calculi and cysts caused by their lodgment. At its lower part a bristle is seen passing through a fistulous opening which communicated with the descending colon. It is on account of this feature that the drawing has been reproduced. It is from a case published by the late Dr. Barlow, in the Guy's Hospital Reports for 1882. The calculus was of triple phosphate. The drawing has been reduced to about one-quarter the size of the original.

FIG. 5. The section of a phosphatic calculus, natural size, which was removed from the bladder of a man aged 27. The interest of the specimen consists in the fact that the man had been supposed to be cured by lithotrity, one year before the lithotomy operation, and his case had been published as a cure. It will be seen that three fragments of the original calculus are embedded in the large phosphatic mass. The calculus weighed 288 grains, and is an interesting example of the rapidity with which a phosphatic stone may form.

FIG. 6. A very large calculus, which was voided by a young woman, without operation. The case is recorded by Sir Astley Cooper, from the practice of Mr. Harris of

Redruth. The patient, a girl of 18, had suffered for seven years from great pain in micturition, and incontinence of urine. She had become very ill, when one day whilst making violent efforts to pass water, the large concretion here shown escaped from her. It is stated that she immediately began to recover, but her health was not perfectly re-established for twelve months. Three months after the expulsion of the stone, she menstruated for the first time. It is not explicitly stated that she recovered without incontinence, though the report seems to imply it. It was believed that the stone had passed through the urethra, and not through an ulceration. It weighed 650 grains, and had a nucleus, which was believed to be a piece of bone. It consisted chiefly of fusible calculus, but had layers of urate of ammonia. There is a deeply-marked groove at one end, which would suggest that it had rubbed against another stone; but the notes do not mention that any other was supposed to be present.

FIG. 7. Shows a yet larger stone which was removed from the bladder of a woman, without any operation. Its removal was effected by Mr. Headington of the London Hospital, who by means of his two forefingers removed the stone "without any difficulty." Mr. Headington satisfied himself by careful examination that it had passed by the urethra, and that there was no communication between bladder and rectum. It weighed 3 oz. 3 drs. troy, consisted chiefly of uric acid, and had a circumference of nearly 8 inches round its largest girth, and 5½ round its smaller. The case is recorded by Dr. Yellowly, in the 6th vol. of the Medico-Chirurgical Transactions. The patient had passed blood in her urine at the age of 7, and had continued to do so up to the date of her marriage at 20. She retained, however, very good health, and never complained of pain in micturition. After her third confinement she began to suffer from pain, discharge, and incontinence of urine. It was now easily ascertained that she had a very large stone in the bladder. For six months more, however, nothing was done for her relief, and at the end of this time, the stone was easily visible through the urethra. As already stated, it was now without difficulty pressed out by the fingers. She recovered and bore another child, but died two years later with symptoms of phthisis. It would appear that she had involuntary escape of urine ever after the removal of the stone. Dr. Yellowly gives references to several other cases of enormous calculi which escaped by the urethra in women. He very pertinently remarks that we have similar facts, as regards the dilatability of the cystic duct of the gall-bladder. All the cases which he mentions had permanent incontinence of urine afterwards; it would, indeed, be almost impossible that this should not have been the case.

Fig I.

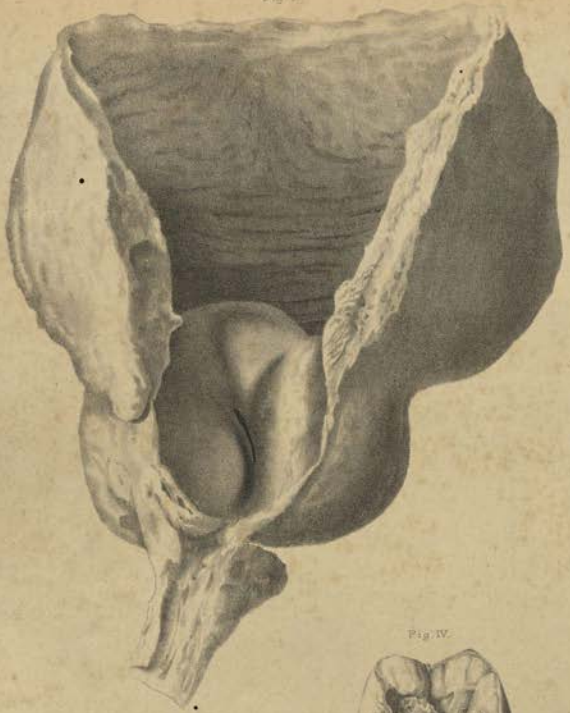

Fig II.

Fig III.

Fig IV.

Fig V.

Fig VI.

Fig VII.

PLATE XXXV.

OSTEITIS DEFORMANS (PAGET'S DISEASE).

All the figures in this Plate are copied from Sir James Paget's second paper on Osteitis Deformans, which was published in the 60th volume of the Medico-Chirurgical Transactions. The case was that of a gentleman, who was aged 46 when he began to suffer from aching in the bones, and who lived for 22 years afterwards with gradually increasing symptoms.

Figs. 1, 2, and 3, show his general contour six months before death; the position in which his head was carried, and the bending and enlargement of the bones of the left lower extremity, are well seen. In Fig. 4 we have a section of his skull, showing its great enlargement by the external deposit of loose porous bone. Figs. 5 and 6 show sections of the upper and lower parts of the femur; and fig. 7 illustrates the way in which the fibula was bent.

As already stated, the case was very slow in progress; the first symptom was aching pain in the thigh and limbs; and next the left tibia was noticed to be somewhat misshapen. Some years later it was noticed that his head was enlarging, so that he was obliged to increase the size of his hats; at the same time he lost in height, being reduced from 6 ft. 1 in. to 5 ft. 9 in. Before his death his sight was damaged by retinal hæmorrhage, and he also began to be deaf. His death was preceded by failure of strength and emaciation, and was finally ushered in by pleural effusion. The patient had never had syphilis, and did not inherit either gout or rheumatism, but a sister had died of cancer of the breast. This case may be regarded as a good typical example of the disease which it illustrates.

For the most recent details respecting Osteitis Deformans of Paget the reader is referred to a recent number of the 'Illustrated Medical News' (February, 1889).

AN

ATLAS OF ILLUSTRATIONS

OF

PATHOLOGY

COMPILED (CHIEFLY FROM ORIGINAL SOURCES)

FOR

THE NEW SYDENHAM SOCIETY.

FASCICULUS VIII.

DISEASES OF BRAIN

AND

SPINAL CORD.

(PLATES XXXVI. TO XLI.)

LONDON:

THE NEW SYDENHAM SOCIETY.

AGENT—H. K. LEWIS, 136, GOWER STREET, W.C.

1891.

PLATE XXXVI.

(*Copied from Auvert's Atlas, Plate 75.*)

FIG. 1.—HYDATID IN THE POSTERIOR CORNU OF THE RIGHT LATERAL VENTRICLE.

The patient was a youth, 17 years of age, of weak constitution, who during the earlier years of his life was much troubled with oxyurides. At the age of 12 he began to suffer from swimming sensations in the head. Some months later he had severe attacks of hemicrania on the right side, followed by vomiting, which afforded some relief. His health failed, the muscles became flabby, and he was exceedingly irritable in temper. When excited, there was very often involuntary twitching on the left side. One day, in his fifteenth year, whilst walking, he fell down suddenly in a fit, during which he was unconscious. After this had passed off, he complained of some weakness of the left side. From that time he became weaker in body and mind, and was at length confined to his bed. When the patient came under Dr. Auvert's observation, he was dull and stupid, vision very imperfect, the dimness being chiefly of the left eye, the pupil of which was dilated, and inactive to light. There was also nystagmus. He complained of constant right hemicrania, feebleness of the left limbs, and drowsiness; he frequently vomited after food, bowels always confined, P. 60. A fortnight later he began to suffer from true epileptic fits, which were very frequently repeated. Each fit lasted three minutes, and was attended with complete unconsciousness, relaxation of the sphincters, and spasmodic movements of the left side. All treatment failed, and death occurred during one of these attacks.

Autopsy.—The meningeal vessels were full of blood, and the pia mater was with much difficulty separated from the surface of the brain. The brain itself was firmer than normal. The lateral ventricles contained a quantity of turbid liquid, and in the posterior cornu on the right side was a hydatid, the size of a pigeon's egg, rather firmly attached to the subjacent plexus. There was no sign of tubercle anywhere. The liver and kidneys were enlarged, the latter containing yellowish nodules scattered here and there.

FIG. 2.—ABSCESS ON THE UNDER SURFACE OF THE RIGHT CEREBELLAR HEMISPHERE CLOSE TO THE PETROUS PORTION OF THE TEMPORAL BONE.

The patient was a man aged 37, who had always enjoyed good health. A fortnight before admission he was exposed to great heat and cold in a bath, and this was followed by stiffness of the neck, and troublesome buzzing in the ears, but these symptoms did not at first interfere with his occupation. Soon, however, he had violent headaches, and his mental condition was peculiar, so that he seemed to have no desire to move, though his limbs were not wanting in power. On examination it was observed that his face was pale, his eyelids closed, pupils active to light, tongue coated, bowels confined, skin hot and dry, appetite bad, respiration normal, pulse 85, hard. There was very severe headache, especially in the occipital region, which prevented sleep, and caused him to lie on his

belly to avoid pressure on the back of the head. By active medical treatment the patient was relieved of his pain, and he began to hope for a speedy recovery. In a short time, howevet, the pains returned, affecting chiefly the base of the head on the right side. He was feverish, sleepless, and had constant twitchings of the facial muscles, but no paralytic symptoms in the limbs. He answered questions slowly, but rationally. For another short space of time he experienced some relief, but the headache soon returned, with giddiness and utter prostration. He died comatose.

Autopsy.—The dura mater was intensely injected, and the sinuses were full of blood. The lateral ventricles were filled with turbid serum, and there was a collection of similar fluid at the base of the skull. The cerebellum was injected, and on section a large purulent focus was found on the under surface of the right hemisphere, which was near the petrous bone, but had not opened into the cranial cavity. The substance of the cerebellum in the neighbourhood of the collection of thick greenish pus was clearly softened. Spinal cord normal. Spleen soft, and its surface marked with scattered deposits of "tubercular" material. Kidneys enlarged and deeply fissured, and their yellowish cortical substance was sprinkled with very small granules.

Fig. I.

Fig. II.

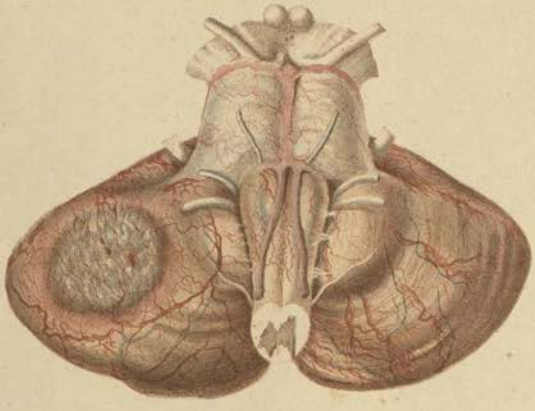

West, Newman Chromo lith.

PLATE XXXVII.

(Copied from Auvert's Atlas, Plate 76.)

FIG. 1.—HÆMORRHAGE INTO THE RIGHT HEMISPHERE AND MEDIAN LOBE OF THE CEREBELLUM.

From a widow, aged 54, who had always enjoyed good health, and was the mother of a large family. For some time past she had been troubled with headache and giddiness, which latterly had become worse, until she was one day suddenly attacked in the midst of her work with vertigo, nausea, and weakness, and speedily became unconscious. When Dr. Auvert saw the patient she was quite comatose, breathing stertorously, pupils dilated and inactive, divergent strabismus, and weak irregular pulse. In spite of active treatment, the patient scarcely showed any signs of improvement, and soon afterwards died.

Autopsy.—The cerebellum was larger than normal, and, on section, in the middle of the right hemisphere, as well as in the vermiform process, a very large hæmorrhage was found, consisting of black clot surrounded by a reddish zone of partially softened brain substance. The kidneys were hard and congested, and the left side of the heart hypertrophied. The uterus, ovaries, and Fallopian tubes were markedly congested.

FIG. 2.—TUBERCLES OF VARIOUS SIZES SITUATED ON THE UPPER SURFACE OF THE CEREBELLAR HEMISPHERES.

From a young man, aged 19, of strumous constitution, who had caught cold about two years ago, and subsequently developed a cough, accompanied with wandering pains in the chest, dyspnœa, and inability to lie on the left side. There was also wasting, and febrile symptoms. Under careful treatment he very greatly improved, and gained flesh; but the relief was of short duration, for he became affected with pains in the head, chiefly in the occipital region and upper part of the neck. These attacks of headache were periodic in their onset, and as they became more severe, vomiting, diplopia, and very painful spasmodic contractions of the limbs were observed. When I examined the patient, there was marked diminution of the respiratory murmur at the apex of the right lung, and over the posterior lobe, decided emaciation and weakness, spasmodic contractions in the limbs, as well as irritability of temper. The onset of the attacks of headache was followed by vomiting and spasms in the limbs, which rendered the patient apparently unconscious; and he was then observed to make attempts at masturbation. From this time he gradually became more emaciated, and finally passed into a condition of coma, which ended fatally three months after admission.

Autopsy.—The upper surface of the cerebellum was marked with numerous tubercles, varying in size, and on section its substance was softer and redder than normal. The lungs were stuffed with tubercles, particularly the right upper lobe. The liver was enlarged, and showed scattered crude tubercles in its substance. The cortical substance of the kidneys was dotted with yellowish granulations.

PLATE XXXVII. *(continued.)*

FIG. 3.—A TUBERCULOUS TUMOUR SITUATED BETWEEN THE LEFT SIDE OF THE PONS VAROLII, THE MEDULLA OBLONGATA, AND THE ADJACENT SURFACE OF THE LEFT CEREBELLAR HEMISPHERE.

The patient was a labourer, aged 30, of strong constitution, who had always enjoyed good health, though his parents were stated to have died of chronic cough. Three years ago he received a severe blow on the back of the head. Some months afterwards he complained of stiffness in the upper part of the neck, pain in the occipital region, buzzing in the ears, and giddiness. He continued his labours in the fields during the summer, but in the following autumn and winter the occipital headache became much worse, and was accompanied with nausea, vomiting, and great bodily prostration, so much so that he was hardly able to leave his bed. As spring came on he improved, and was able to get about again, but next winter his former symptoms returned with increased violence. He was now advised to take a "Turkish" bath, and whilst exposed to a very high temperature he lost consciousness. On returning to himself he found that he had lost power and feeling in his right limbs. On examination I found him dull and stupid, very emaciated, with complete paralysis and partial loss of sensibility on the right side, right pupil dilated, and complete blindness on that side, weak rapid pulse, diarrhœa, and distended abdomen. At the end of a fortnight by active medical treatment his symptoms were somewhat relieved, but a week later he had a sudden relapse, attenden with very severe pains in the left side of the head, and convulsions in the limbs, speedily followed by difficult breathing and coma, in which state he died.

Autopsy.—A tuberculous tumour the size of a small apple was found between the left half of the frons, the medulla oblongata, and the adjacent surface of the left cerebellar hemisphere. This tumour was dense and homogeneous in structure, and of a yellowish colour. On section its interior was softened, and presented a focus of recent hæmorrhage. The membranes of the cerebellum were much injected, and its substance felt softer than normal. At the apices of both lungs tubercles were found, showing very little softening. The surface of the kidneys was deeply fissured, and they contained numerous cysts. The mucous membrane of the colon showed a number of ulcers, which appeared to be due to tuberculous deposit.

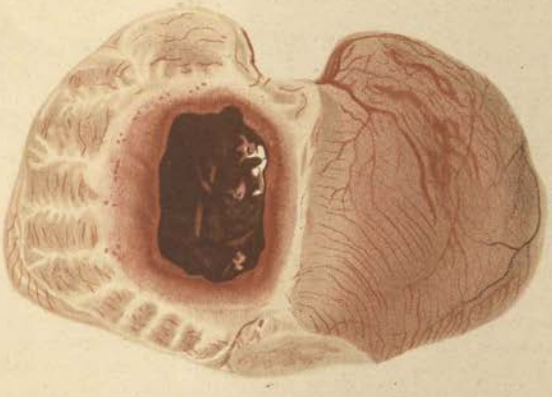

Fig I.

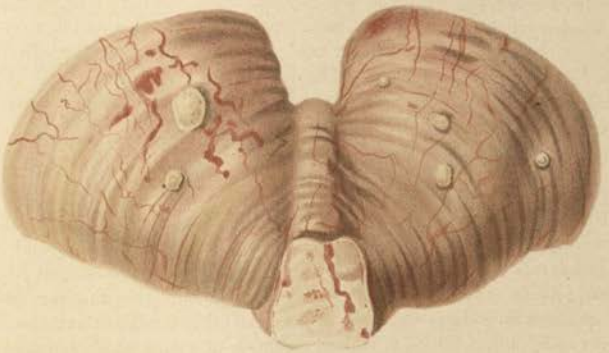

Fig II.

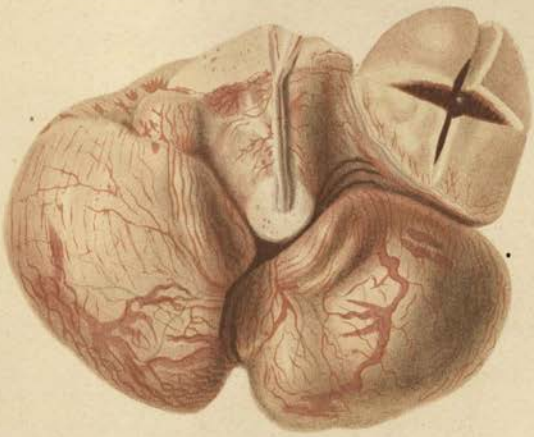

Fig III.

West Newman chromo lith.

PLATE XXXVIII.

The three figures in this Plate illustrate the effects of injuries to spinal column, attended by contusion of the cord. In fig. 1 the theca has only been laid open to a slight extent, and the cord itself is still entire. In figs. 2 and 3 the end has been divided longitudinally, so as to reveal the contusion and ecchymosis of its substance. It is important to remember that in these accidents attended by friable bending of the spinal column, and usually by temporary displacement of the bones, the restoration of the latter is often so perfect that, unless carefully looked for, the evidences of displacement may escape notice. It is also very often the case that the theca on the external surface of the cord itself shows no signs of injury, and it is only when the cord is sliced, as in figs. 1 and 2, that the real cause of the symptoms is revealed. Extravasation of blood into the spinal canal, whether within or without the theca, as shown in fig. 3, is but very seldom seen, and is probably not usually of much importance in reference to symptoms.

FIG. 1.—A SEVERELY CRUSHED SPINAL CORD.

The subject of this case was a man of middle age, who died in the London Hospital, under Mr. Hutchinson's care, in 1863. His injuries had been received in a fall, by which the head had been violently bent forwards into the sternum, and displacement, with fracture of the fifth cervical vertebra, had occurred. He had the usual symptoms of paralysis of all the muscles of the upper and lower limbs, with entire loss of sensation. The breathing was diaphragmatic, and death from embarrassment of the lungs occurred on the third day after the accident. On the autopsy it was found that the bones had been perfectly restored to position, and that there was no permanent compression of the cord. The theca were entire, and neither ecchymosis or any other condition indicated the seat of lesion. The cord externally appeared to be normal, but to the finger it was distinctly softened over a considerable length. When it was laid open, the conditions exhibited in the drawing were disclosed. Its substance had been crushed at the level of the displaced vertebra, and ecchymosis had extended upwards and downwards through the length of about three inches. Some allowance must probably be made in the drawing for appearances due to post mortem staining, the softening and ecchymosis having been in reality somewhat less extensive than the artist has represented.

FIG. 2.—THE CERVICAL SPINAL CORD OF A MAN WHO HAD DIED UNDER ALMOST PRECISELY SIMILAR CONDITIONS TO THOSE SPECIFIED IN THE PRECEDING CASE.

The injury was to the fourth cervical vertebra, and the patient survived it only two days. The restoration of the bones to position was so complete, that it was only after careful dissection the existence of the fracture could be detected. There was no blood in the theca, nor did the surface of the cord show the slightest evidence of contusion. On cutting the cord open longitudinally, however, its substance was found to have been crushed at the site of displacement, and a softened and ecchymosed tract three-quarters of an inch in length was disclosed.

PLATE XXXVIII. (*continued.*)

Fig. 3.—Hæmorrhage external to the Vertebral Theca.

(*Auvert's Atlas, Tab. LXXVIII.*)

A man, aged 30, was struck on his back by a sack of flour which had fallen from a height. He was paralysed in his lower extremities, but retained his consciousness. When, on the third day after the accident, he came under the care of Dr. Auvert, the chest-wall was motionless in respiration. There was much difficulty of breathing, and general distress. The heart beat irregularly and violently, but the pulse was not materially quickened. There was a distressing girdle pain at the level of the diaphragm. The impediment to respiration having gradually increased, death took place on the sixth day.

From the level of the third dorsal vertebra downwards to the third lumbar posterior, the part of the theca was occupied by a large adherent clot of blood.

(It would appear that this specimen was retained as a preparation in its present condition. There is no record of the cord itself having been sliced. It is not improbable that, had it been laid open, conditions similar to those shown in figs. 1 and 2 might have been disclosed.)

Fig. III.

Fig. I.

Fig. II.

West, Newman chromo lith.

PLATE XXXIX.

(Copied from Auvert's Atlas, Plate 79.)

FIGS. 1, 2, 3.—A TUBERCULOUS TUMOUR ON THE SPINAL DURA MATER.

From a girl, aged 15, who had been under treatment for some time with strumous ophthalmia. Her present illness began with weakness and impaired sensation of the legs, attributed to cold, and within a month she was completely paraplegic. On admission to the Hospital the lower dorsal and lumbar regions were painful on pressure, and the lower extremities were devoid of motion and sensation. Very soon afterwards gangrenous bed-sores appeared on the buttocks, trochanters, sacrum and knee, and the patient was troubled with frequent spasms in the legs. Dyspnœa and signs of phthisis developed, and the spasms in the legs were accompanied with very painful opisthotonus. The persistent cough, abundant expectoration, and diarrhœa were followed by marked emaciation, the opisthotonus became more frequent, and the patient gradually sank into a typhoid state, and died thirteen months after admission.

Autopsy.—Permission to examine the chest and spine only was granted. The lungs showed large vomicæ at their apices, and almost the whole of the remaining portions was stuffed with more or less degenerated tubercle. An oblong tuberculous tumour, of a greenish colour, and partly softened, measuring two inches in length and three-quarters of an inch in breadth, was found on the posterior surface of the spinal dura mater, corresponding to the lower half of the first dorsal, the second, and the upper half of the third dorsal vertebræ. The anterior surface of the arches of the first and second dorsal vertebræ, adjacent to the mass, were eroded by caries, and the contiguous portion of the dura mater was blended with the subjacent arachnoid by plastic exudation. The spinal cord at this spot was compressed by the tumour, and its substance softened.

Fig. I.

Fig II.

Fig III.

West, Newman chromo lith.

PLATE XL.

(Copied from Auvere's Atlas, Plate 80.)

FIG. 1.—CARTILAGINOUS DEPOSITS ON THE SPINAL ARACHNOID.

A peasant woman, aged 35, was found helpless in the street, and was brought into the Hospital. She was collapsed, cold, livid, and had a very weak pulse. There was also vomiting, and repeated action of the bowels. But very little urine was passed. Formerly she had been often troubled with spinal pains, and of late she had suffered from recurrent spasmodic attacks, which rendered her unconscious. At the time of admission there was severe headache, and præcordial pains, and she experienced tetanic contractions in all the limbs. At certain intervals of time there was opisthotonus of the spine and trismus. She died very soon after admission, in a convulsion which affected the whole body.

Autopsy.—The posterior surface of the spinal arachnoid from the sixth dorsal to the second lumbar vertebra was covered with cartilaginous scales of various sizes, which destroyed the transparency of the arachnoid, and rendered it rough and uneven. The substance of the spinal cord itself seemed harder than normal. The lungs were congested.

(In a note to the above description, the author states that the symptoms preceding the death of the patient resembled those of sporadic cholera.)

FIG. 2.—MYELITIS AFTER CONCUSSION OF THE SPINE.

A youth, aged 22, fell from a height upon his back, and lay on the ground for half an hour quite conscious, though unable to move his limbs. Slowly power returned in them, he rose and walked home, where he remained quietly for a few days. On the fifth day he returned to his work, but this caused him so much pain in the spine, and he felt so weak, that he gave it up and came to the Hospital on the seventh day. On admission he complained of deep-seated pain and burning sensations in the lower cervical and upper dorsal regions. It was increased by movement, though not by pressure; the patient was feverish, had much difficulty in swallowing, and was much troubled with nausea and vomiting. He had also a very painful sensation of constriction round the lower part of the chest, the pulse was rapid and irregular, respiration dyspnœic. The upper extremities appeared to be quite insensitive, though not paralysed. These symptoms rapidly increased, and he died of respiratory failure.

Autopsy.—On opening the spinal canal the membranes were found injected, and the substance of the spinal cord was so soft that it resembled a pulp. The condition extended from the sixth cervical to the fourth dorsal vertebra. The lower lobes of the lungs were partly hepatised, and everywhere showed much congestion.

Fig I.

Fig II.

West, Newman chromolith.

PLATE XLI.

(*Copied from Auvert's Atlas, Plate 75.*)

FIG. 1.—TUBERCLE IN PIA MATER OF CORD.

A youth, 18 years of age, had suffered from scrofula and rheumatism. He became the subject of fixed pain in the back, with weakness of the lower extremities. These symptoms increased to definite paraplegia. His bowels were very costive, and difficulty in voiding urine having increased, it at length became needful to use the catheter. Sensation in the lower extremities was not diminished.

A round, firm, tubercular mass, encapsuled in a cellular envelope, was found on the anterior surface of the cord about the level of the second lumbar vertebra. It was of a lardaceous consistence. The membranes were much congested above and below it. The lungs were in a state of advanced disorganisation from tubercular processes, and there were tubercular masses in the liver and spleen.

FIG. 2.—A FIBROUS TUMOUR LODGED IN THE CAUDA EQUINA.

A soldier, aged 63, who had led a dissolute life. He became the subject of severe pain in the back, which was followed by formication and weakness in the lower extremities. There were also involuntary erections, escape of urine and fæces. Eighteen months after the beginning of the pain, paraplegia of both motion and sensation was complete. A very large bed-sore formed, and death ensued.

He had been much exposed to the risk of syphilis, but it was not known that he had ever had constitutional symptoms.

A fibrous growth, the size of a large filbert, and of a fleshy aspect, was lodged in the posterior part of the cauda equina. It was opposite to the third and fourth lumbar vertebræ. The adjacent strands of the cauda were obviously softened.

Fig. I.

Fig. II.

AN

ATLAS OF ILLUSTRATIONS

OF

PATHOLOGY

COMPILED (CHIEFLY FROM ORIGINAL SOURCES)

FOR

THE NEW SYDENHAM SOCIETY.

FASCICULUS IX.

DISEASES OF THE TESTIS.

(PART I.)

(PLATES XLII. TO XLVI.)

LONDON:

THE NEW SYDENHAM SOCIETY.

AGENT—H. K. LEWIS, 136, GOWER STREET, W.C.

1894.

PLATE XLII.

FIG. 1.—Hydrocele of the Spermatic Cord. A small lobulated cyst is seen above, and wholly separated from, the tunica vaginalis, which has not been opened. The cyst may have developed in a portion of the processus vaginalis which had remained unobliterated; at the same time it is not impossible, from its proximity to the epididymis, that fœtal tubular remains may have served as the origin of the cyst.

FIG. 2.—Hydrocele of the Epididymis. In the work from which this figure is taken it is called a hydrocele of the cord, but it will be seen that the cyst is developed in direct continuity with the body of the epididymis, from which it could not be separated during life; and this is the chief clinical distinction between the two varieties of cysts.

FIG. 3.—Pedunculated cartilaginous body attached to the globus major. Below it is seen the hydatid of Morgagni.

FIG. 4.—A calcareous plate formed in the tunica vaginalis (that portion immediately covering the testis).

FIG. 5.—A number of calcareous and cartilaginous bodies formed in the visceral layer of the tunica vaginalis and on the globus major of the epididymis. The latter are pedunculated.

FIG. 6.—A multilocular cyst developed "between the tunica vaginalis and the tunica albuginea." The cavity of the tunica vaginalis is enlarged, and seen in section. Hydroceles of this variety are exceedingly rare.

FIG. 7.—A hydrocele of the upper part of the tunica vaginalis, the lower part having become obliterated by adhesion to the testicle, which is seen in section. Such a hydrocele, although not containing spermatozoa, would clinically resemble one of the epididymis.

All the above figures are taken from Sir Astley Cooper's work on the Testis.

Fig. I.

Fig. II.

Fig. III.

Fig. IV.

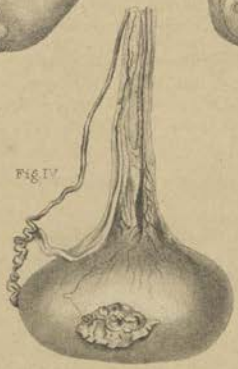

Fig. V.

Fig. VI.

Fig. VII.

West, Newman & Co. Lith.

PLATE XLIII.

HYDROCELE AND VARICOCELE.

Most of the figures forming this and the following Plate are taken from Sir Astley Cooper's great work on the Testis ('Observations on the Structure and Diseases of the Testis,' 1841).

FIG. 1.—THE COMMON HYDROCELE OF THE TUNICA VAGINALIS, laid open from in front, and showing the testicle, covered by its visceral layer of the serous membrane, projecting into the cavity. It will be noticed that the latter extends a short distance below the testis, and that there is an indication of little pouches on the right side. The most frequent and interesting pouch in connection with a common hydrocele is one extending between the testis proper and the body of the epididymis. This diverticulum begins at the site of the normal "digital fossa" on the outer side of the organ, and in some museum specimens can be seen to equal in size the rest of the vaginal cavity, producing one form of the so-called hour-glass hydrocele.

FIG. 2.—A VARICOCELE OF MODERATE SIZE UNRAVELLED, showing the extremely tortuous loops of veins, which, owing to the dissection, appear to reach further below the testis than they would during life. The testicle was small and flaccid, a condition present in a very considerable proportion (probably about 1 in 5) of cases of long-existing varicocele. The drawing illustrates an important point in the modern operation for radical cure of varicocele, namely, that as one ascends the cord the veins become collected into fewer trunks, and may be much more readily ligatured *en masse*. Hence it is inadvisable to attempt to place the lower ligature round the veins near to the testicle.

FIG. 3.—A LARGE VARICOCELE, suggesting the old and apt comparison to a bundle of earth-worms. The small veins as well as the large ones are very tortuous and dilated, and the testicle, which was no doubt atrophic, is partly concealed from view.

The vas deferens is seen as a nearly straight cord behind the plexus of veins.

Fig. I.

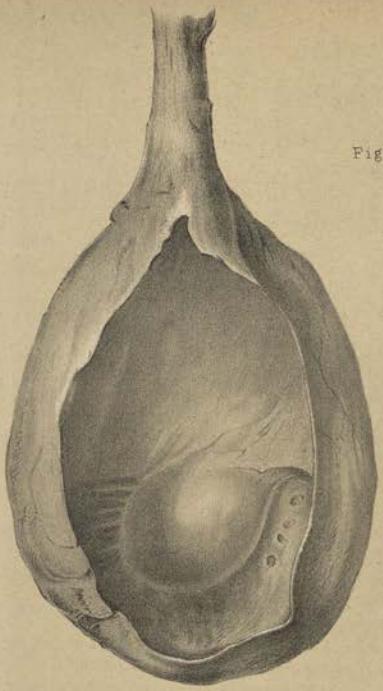

Fig. II

Fig. III

West, Newman & Co. Imp.

PLATE XLIV.

FIG. 1.—UNDESCENDED AND ATROPHIED TESTIS.

The drawing is taken from the inner aspect of the abdominal wall, and shows the ilium and pubis, the peritoneum lining the iliac fossa and posterior surface of the transversalis muscle, and the atrophied left testicle situated just above the internal inguinal ring. Through the latter projects the lower end of the epididymis and commencement of the vas, which in these cases of undescended testis is very apt to be looped down to a variable extent below the position of the testicle, and they are seen in this figure to be connected with the remains of the gubernaculum. The drawing is taken from a specimen in Guy's Hospital Museum. On the testicle is seen the body of the epididymis, above it the spermatic vessels coming down from the aorta and vena cava. The testis has been incised, no doubt with a view to ascertaining whether semen was present. The case is possibly the one alluded to by Sir A. Cooper (page 45) in which the subject of retained testes committed suicide, believing that virility was absent. Sir A. Cooper states that in this, as in other cases that he had examined, the "tubes were full of semen."

In one case precisely similar to that shown in the figure (specimen in the London Hospital Museum) a careful microscopic examination was made of the secretion on both sides, and no spermatozoa found. The man was aged from forty to fifty, had been married, but had no children. It is generally admitted that these retained testes, though they may at first secrete well, age prematurely.

An interesting point shown in Fig. 1 is the descent of a pouch of peritoneum down the whole length of the canal and into the scrotum. This is a very frequent complication of retained testis, and naturally predisposes to hernia.

FIG. 2.—ATROPHY (EXTREME) OF ONE TESTICLE AND EPIDIDYMIS.

The cause is not known, and the drawing is chiefly of interest as showing that extreme wasting of the testicle can exist whilst the corresponding vas deferens and vesicula seminalis retain their usual size. It is possible that the atrophy resulted from orchitis due to mumps in early life. The even wasting of both testis and epididymis points to some cause occurring at a very early age, or to a failure in development.

The vas on both sides is seen to be dilated at its termination, as are also the vesiculæ seminales, more especially that on the left side.

FIG. 3.—CYSTIC DISEASE (? SARCOMA) OF THE TESTIS.

There is unfortunately no history obtainable of this case. The testicle is greatly enlarged, very vascular in parts, and filled with cysts of various sizes, containing either clear fluid, or a sort of gummy or colloid material. These cases are rare, but every good Museum presents a few examples. The exact pathology is, like that of the cystic kidney, still very obscure It is a clinical fact that the cases are especially liable to be mistaken for hydroceles and punctured, and that after removal the prognosis is remarkably good, especially as compared with that of true sarcoma and carcinoma of the testicle.

Fig. I

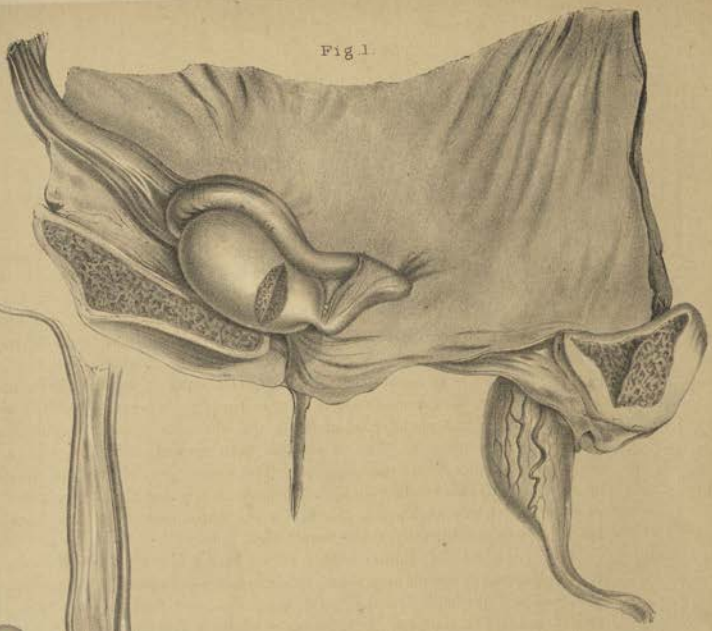

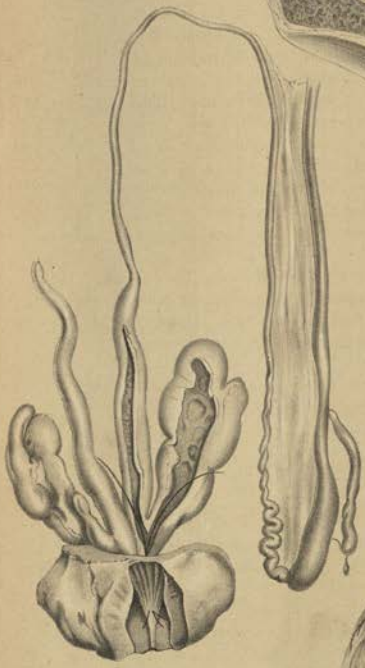

Fig. II

Fig. III

West, Newman & Co. Imp.

PLATE XLV.

SYPHILIS OF THE TESTICLE.

In this Plate the chief forms in which tertiary syphilis affects the testis are shown. During the secondary stage a symmetrical painless epididymitis is occasionally met with, involving chiefly or entirely the globus major; it is a disease of short duration (especially under mercurial treatment), and it has been impossible to obtain any illustration of its pathology, the exact nature of which still remains doubtful.

All the illustrations on this Plate (and Fig. 3 on Plate XLVI.) are taken from cases in the late stage of syphilis, both acquired and inherited, and the specimen has been in each case bisected and drawn of the natural size.

Fig. 1.—Breaking down Gumma in the Testis.

It was probable, from the history of this case, that syphilis had been acquired some twenty years before; during this time the patient had been the father of a healthy family. As is not uncommon in the case of the testis (and extremely rare in the case of such internal viscera as the liver and spleen), the gummatous deposit has softened and formed a sort of abscess. All distinction between testis and epididymis has been lost, and the proper secreting tissue has been wholly destroyed. The tunica vaginalis is obliterated, and the scrotum (the skin of which is marked by the hairs on the left of the figure, as also in Fig. 6) was adherent to the gummatous mass by tough connective tissue. Softening has occurred in more than one part of the gumma, and there was a sinus leading into a cavity. Excision was performed, as the testis caused much inconvenience by its size and the discharge from it, and did not yield well to treatment. It is obvious that when the bulk of a syphilitic testicle consists of tough fibrous tissue, as here, not much effect can be expected from the internal use of iodides; and clinically it is well known that whilst tertiary disease of the testis is, as a rule, a most satisfactory thing to treat, some cases show very little tendency for the swelling to be absorbed. Particularly is this the case if softening has once occurred, and the centre been invaded by the micro-organisms of suppuration. The whole of the testis may then break down and fungate, or simply melt away.

Fig. 2.—Gumma of the Testis due to Inherited Syphilis.

From a boy aged fourteen years, who presented many symptoms of congenital syphilis, including characteristic teeth, and who died in the London Hospital. The whole organ, including the epididymis, was invaded by yellowish gummatous deposit. Practically all trace of normal tubular structure has disappeared.

This illustration is of particular value since the opportunity very rarely occurs of obtaining specimens of inherited syphilitic orchitis, whilst every Hospital Museum is well provided with examples of orchitis due to acquired syphilis. It would seem that the testis is much more rarely affected in cases of inherited than in those of the acquired

disease. Undoubtedly, however, young infants or children, the subjects of the former, may develop chronic orchitis; just as the latter is frequently met with at an early period (*i. e.*, within a year or two) after the occurrence of a primary chancre. In the present case the disease did not probably develop until some years had elapsed after birth. Sometimes in the subjects of inherited syphilis one or both testes may be found to be atrophied or to have undergone fibrous degeneration, and both these changes may be due in part to old gummatous deposit which has been absorbed under treatment. In this case the liver was the seat of a deep puckered scar, the remains of a gumma; it has been represented in another Plate.

FIGS. 3 AND 4.—GUMMATOUS DISEASE OF TESTIS AND LUNG.

Both these specimens were obtained from a middle-aged man who died in the London Hospital in 1879 from acute intestinal obstruction. As may be expected, no full history was obtained, but it was said that he had no chest-symptoms. The left testicle, which is represented in the drawing, shows several gummata which have started in the peripheral part of the gland, and which are fusing together. It is interesting to note that in this early stage they have involved the tunica albuginea, just as intra-cranial gummata usually commence in the dura mater and most superficial parts of the brain. In most specimens of syphilitic orchitis it is quite impossible to decide in which part of the gland the disease has started, but such cases as the one figured confirm the belief that the connective tissue around the testis and traversing its substance is the original site. The early involvement of the tunica albuginea and visceral layer of the tunica vaginalis (which is inseparable from the former) accounts for the fact that with tertiary orchitis there is almost invariably inflammatory adhesion between the two layers of the serous sac or a hydrocele. The absence of marked congestion around the gummatous deposit in the testis is very marked in this specimen, and is very characteristic here, as in other viscera such as the liver.

The portion of lung represented includes on the left hand a small piece of pleura and several of the smaller bronchial branches. About a dozen gummata are seen of various sizes. Unfortunately details of microscopic examination cannot be given. The patient was a strongly-built subject, with no lesions pointing to tubercle in any organ; there was an old scar on the glans penis, and old epididymitis of the other side (the right).

It should be noted that in the lithograph the larger gumma of the lung has been made to present a granular surface; in the specimen and original drawing it was of a more homogeneous yellow appearance.

FIG. 5.—GUMMATOUS DEPOSIT IN TESTIS AND EPIDIDYMIS FROM ACQUIRED SYPHILIS.

The large, tough, leathery masses completely replacing the gland are seen in section; the tunica vaginalis has been inflamed and much thickened, and contains a layer of blood-stained lymph, almost amounting to a hæmatocele.

The history of the case is of much interest from the resistance to anti-syphilitic treatment, the difficulty of diagnosis from tubercular disease, and other points.

The patient was a short, stout, florid man, who contracted syphilis at the age of forty-five. He took mercury for five months, and no secondaries occurred until it was left off; then a rash appeared on his skin, and his nails inflamed. Three years later he was under treatment for diseased bone in one toe, and was said then to have sugar in his urine;

no symptoms of diabetes, however, developed. A few months after this his right testicle enlarged, and he was told the disease was "scrofulous." In April, 1885 (aged forty-nine, four years after the primary syphilis), he came under Mr. Hutchinson's care. Both testes were then enlarged, and on the left side the disease seemed to be chiefly in the epididymis. The vas deferens was greatly swollen above the testicle, but on rectal examination nothing abnormal was felt.

Iodide of potassium and mercury were administered, the latter to slight ptyalism; but the right testis continued to increase in size, and the skin over it became congested; the spermatic cord was very thick. Excision of this gland was performed.

The drawing shows almost complete destruction of the testis and epididymis by gummatous deposit of a firm leathery consistence; the proper tunics of the gland are much thickened, and a chocolate-coloured layer of blood and lymph occupied the vaginal cavity.

It will be noted that the disease, although undoubtedly due to tertiary syphilis, failed to respond to mercurial and iodide treatment. That of the left testis improved considerably, but about a year later this gland again rapidly enlarged. Under mercury, however, the swelling subsided this time, leaving a firm nodule apparently in the upper part of the epididymis.

It is by no means easy in many cases of chronic orchitis, &c., to be certain of the exact position of a particular lump or thickening, and the opportunity now and then occurs of proving by dissection that what was, for instance, supposed to be an enlarged globus major was really a projection from the testis itself. Especially in syphilitic specimens all distinction between epididymis and testis is apt to be lost. This was illustrated in the specimen from which the following figure was taken.

FIG. 6.—GUMMATOUS DISEASE OF TESTIS, WITH GREAT ENLARGEMENT OF THE ORGAN.

In this case the testicle is enlarged to about four times its normal size, and the swelling is remarkably even and oval in form. The tunica vaginalis has wholly disappeared, and the scrotal skin adhered to the gummatous mass. Although there was apparent fluctuation before removal, and afterwards on section some parts were very soft, there was nothing to be compared to an abscess. The remarkably even oval outline is noteworthy, and the great size of the gummata in this and the preceding figure. The question naturally arises, "Could such large masses be absorbed under anti-syphilitic treatment?" Clinical evidence points to an affirmative answer, although of course such a gland could never be of the slightest functional use.

The patient at the time of operation was aged twenty-nine; about two years previously he had had chancres, followed by skin-eruption. The right testicle had steadily enlarged for a long time (he said for years, but much reliance could not be placed on his dates); there was no testicular sensation in it; the tissues of the cord were matted together. The other testicle was normal, but he had some enlarged breaking-down glands in the neck. After a short trial of mercury and iodide of potassium, the diseased organ was removed. Recovery was protracted owing to secondary hæmorrhage.

All the figures given in this Plate are from original drawings in Mr. Hutchinson's collection.

Fig I.

Fig II.

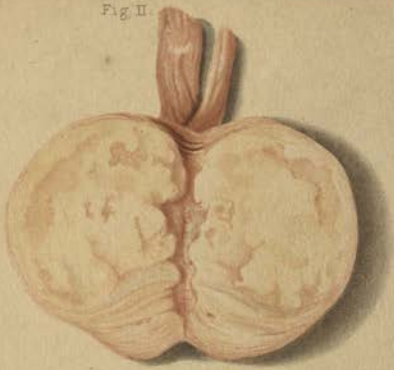

Fig III.

Fig IV.

Fig V.

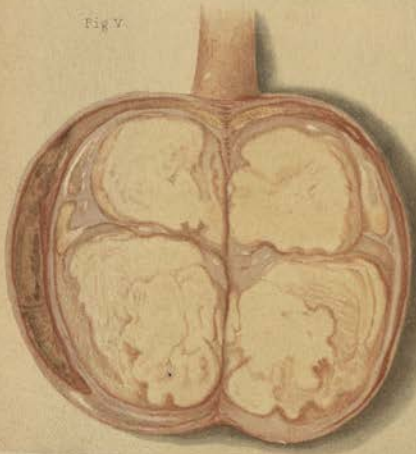

Fig VI.

West, Newman chromo.

PLATE XLVI.

TUMOURS OF THE TESTICLE. (3 FIGS.)
GUMMA OF THE TESTICLE. (1 FIG.)

FIG. 1.—MEDULLARY CANCER.

The outer surface of a very large and soft new growth of the testis is shown. The tumour was removed from a middle-aged man, otherwise in good health, who had known of its existence about nine months. A remarkable resemblance to the surface of the brain is seen, strongly suggesting the term "encephaloid," which, as applied to tumours, has considerably fallen into disuse. The finer details of the tumour are only shown in the upper part of the figure, and here it will be noticed there are great numbers of small cysts. The after history of the case cannot be given.

FIG. 2.—CYSTIC CHONDRO-SARCOMA.

This tumour had a very composite structure, the chief constituents being:—(1) Rounded and spindle-shaped sarcoma cells of various sizes; (2) Cysts scattered throughout the upper part; these are lined with a single layer of cubical epithelium, and contained a glairy fluid; (3) Fibrous and fibro-cellular tissue, with here and there patches of fatty degeneration; the latter has caused the yellow colour in the lower part of the drawing; (4) Cartilage nodules, not present in sufficient quantity to prevent the tumour as a whole being of softish consistence.

It is difficult to be certain from what part the tumour has grown; the epididymis is the most probable, since most of the testis itself is seen in section at the lower and right-hand corner of the drawing, and is comparatively little altered. We may then assume that the tumour is an example of mixed sarcoma of the epididymis.

The patient from whom it was removed was aged thirty at the time of operation; he had known of its existence about fifteen months. A hydrocele which developed over it was tapped six months before the excision. There was no family history of cancer or other tumours. Before removal the tumour felt very solid and hard; it was rather painful, and there was also pain in the lumbar region.

FIG. 3.—GUMMA OF TESTICLE, WITH HYDROCELE.

A syphilitic deposit of considerable size is seen in the centre of the testicle, the glandular structure of which above and below the actual gumma is invaded by inflammatory changes. The epididymis presents increase of fibrous tissue, and the whole organ is decidedly enlarged. The gumma reaches the surface of the testis in front, and its presence led to a secondary hydrocele. The walls of the sac are held open above, and its lining membrane is seen to be extremely congested, so that the transition into a hæmatocele would be an easy one.

PLATE XLVI. *(continued.)*

FIG. 4.—A SARCOMA INVOLVING THE WHOLE TESTICLE, AND SPREADING UP THE SPERMATIC CORD.

At first sight the drawing might suggest a lipoma, but the consistence of the tumour was much firmer, and its colour paler. Microscopically it was chiefly made up of spindle and round cells; intersecting fibrous bands are seen in the drawing. There was no trace of glandular structure left, and its complete replacement by sarcoma which has retained the normal shape and limits of the testis (except above) is noteworthy. The tunica vaginalis, as seen in front of the tumour, contained dark brown sanguineous fluid. The testis was removed from a man aged fifty. It was difficult to get above the limits of the growth in dividing the cord, and secondary deposits caused death within about a year from the operation.

All the figures given in this Plate are from original drawings in Mr. Hutchinson's collection.

West, Newman, lith.

AN

ATLAS OF ILLUSTRATIONS

OF

PATHOLOGY

COMPILED (CHIEFLY FROM ORIGINAL SOURCES)

FOR

THE NEW SYDENHAM SOCIETY.

FASCICULUS X.

DISEASES OF THE TESTIS.

(PART II.)

(PLATES XLVII. TO XLIX.)

WITH ADDITIONAL LETTERPRESS BY J. HUTCHINSON, JUN.

LONDON:

THE NEW SYDENHAM SOCIETY.

AGENT—H. K. LEWIS, 136, GOWER STREET, W.C.

1895.

PLATE XLVII.

FIG. 1.—SARCOMA (ROUND-CELLED OR LYMPHO-SARCOMA) OF THE TESTICLE.

Exterior aspect of the tumour, showing its vascularity and marked lobulation. The spermatic cord is shown in its coverings, and was not affected by the growth.

FIG. 2.—VIEW OF AN ANTERO-POSTERIOR SECTION OF THE ABOVE TUMOUR, SHOWING A GREYISH-BROWN SURFACE OBSCURELY DIVIDED INTO LOBES.

The tumour was moderately firm, and yielded but little "juice." The lobulations are somewhat convex on section, and give a lumpy outline to the tumour as a whole. All trace of normal testis structure has disappeared. A small extravasation of blood is seen in the right half of the section.

Microscopically the tumour was found to be composed of a mass of small cells (between which a delicate reticulum could be made out), the structure conforming to the type of lympho-sarcoma, and being not unlike granulation tissue. This latter fact is of interest, since in the case from which the drawing was obtained the opposite testis was removed eighteen months previously on account of enlargement, and microscopic investigation at first pointed to simple inflammatory overgrowth. Subsequent examination of the sections, however, proved the true sarcomatous nature of the disease in both organs. The patient was an elderly man (sixty-eight years old), and the history may briefly be given thus:—Steady enlargement of one testicle, attributed to injury in the first place; at the end of six months (when it had attained the size of a hen's egg) it was excised. Patient in good health for eighteen months, then similar steady enlargement of the other testicle, which was also excised. Two years later recurrence took place in one tibia, leading to spontaneous fracture of the bone, and he died (about six years after the first operation) with multiple growths in the subcutaneous cellular tissue, &c.*

FIG. 3.—A SLOWLY-GROWING TUMOUR OF THE TESTICLE, PROBABLY OF SARCOMATOUS NATURE.

The section shows numerous lobules with intervening bands of fibrous tissue. Fatty degeneration has occurred in many parts, giving a yellow colour to many of the lobules.

The tumour was a hard heavy one, which had been known of for nearly twelve years, having commenced to grow when the patient was thirty-one.

* The testis tumours were reported on by Messrs. Butlin, Cripps, Parker, and Shattock; and further details are to be found in the 'Pathological Transactions,' vol. xl. p. 193.

Fig. II.

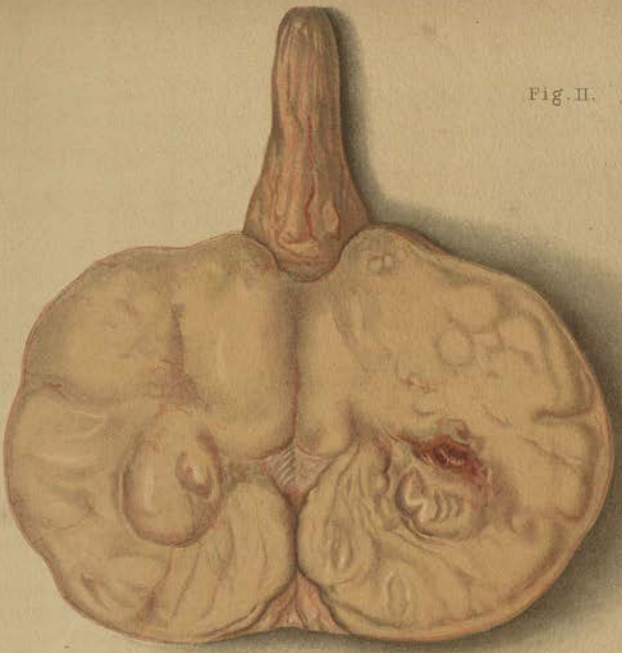

Fig. III.

Fig. I.

PLATE XLVIII.

FIG. 1,—HYDROCELE OF THE TUNICA ALBUGINEA.

A thick-walled cyst, formed apparently in the tunica albuginea and compressing the testis; the cavity of the tunica vaginalis can be seen to be quite independent of the cyst. The specimen, an example of a very rare form of hydrocele, is in the London Hospital Museum. The wall of the sac was composed of dense fibrous tissue with a few spiculæ of bone, and was lined by an organized false membrane. The contents were a greyish-brown fluid and flakes of lymph. The patient was a man aged sixty-three. A similar specimen of a hydrocele between the tunica albuginea and the visceral layer of the tunica vaginalis, or in the substance of the former, is figured in Curling's work on the Testis. Another case is represented in the present 'ATLAS' (Plate XLII. Fig. 6).

FIG. 2.—MALIGNANT TUMOUR OF THE TESTIS FROM A BOY AGED TWO YEARS.

The drawing shows a large tumour growing in the left testicle and distending the scrotum, the veins of which are much increased in size. It has an even rounded outline, and was considered to be a "medullary cancer," though more probably it was of sarcomatous nature. The tumour was first noticed at the early age of seventeen months; it was excised ten months later, and the patient died of secondary deposits in both lungs at the age of three years. There had been no recurrence in the cord or lumbar glands.

FIG. 3.—HÆMORRHAGIC SARCOMA OF TESTICLE.

This Plate represents a vertical section through a large soft tumour containing a number of cysts, and resembling a mass of blood-clot. The microscope, however, showed that it was in reality a sarcoma, extremely vascular, the vessels having very thin walls, and being liable therefore to rupture readily. Here and there extravasations are seen, but in many places there are true cysts containing sanguineous fluid. The growth is somewhat lobulated, and both testis proper and epididymis appear to be equally affected. A small separate nodule, slightly paler than the rest, is seen cut across in the cord. Clinically the hæmorrhagic sarcoma is most malignant, and when secondary deposits occur in the lumbar glands or elsewhere they are usually (in great part at least) hæmorrhagic also, and therefore of the same striking purple colour.

In the case illustrated the malignancy of this form of tumour was well exemplified. The patient was a man aged thirty-four, in whom the testis-tumour was of rapid growth (a few months), and who died, not long after the operation for its removal, with cerebral symptoms pointing to secondary deposit within the cranium.

Fig. I.

Fig. II.

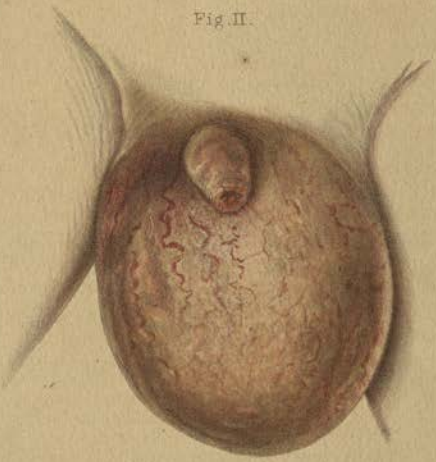

Fig III

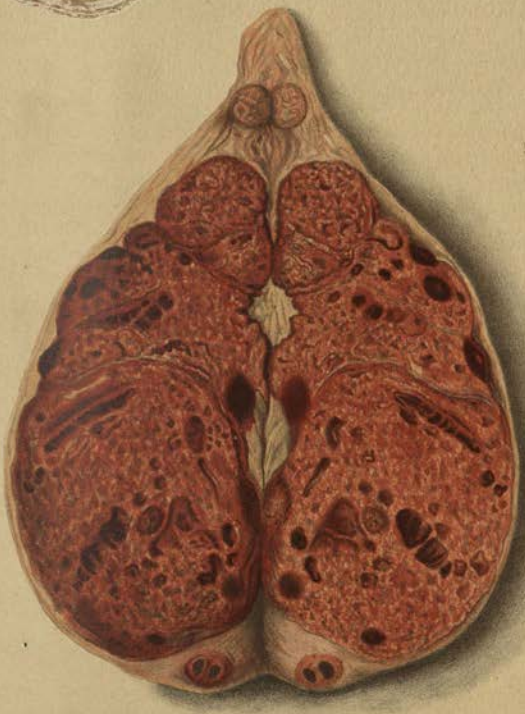

West, Newman, lithographers.

PLATE XLIX.

MISPLACED TESTICLE IN THE PERINEUM.

This drawing is taken by permission of the Staff of St. Bartholomew's Hospital, from the collection in their Museum. The left testicle forms an oval swelling between the anus and the (empty) corresponding side of the scrotum. The right testicle has descended to its normal situation. The oblique position of the scrotal raphé is well shown. A drawing from a similar case is given in Mr. Curling's work on the Testis. Such a malposition, due probably to abnormal attachment of the lower band of the gubernaculum testis, is a somewhat rare one, although a considerable number of cases have been recorded. Its inconvenience from the risk of traumatism in riding or even sitting down is obvious, and an operation to replace the testis in the scrotum is naturally indicated. As a rule, however, it is found necessary to excise the organ.

THE PATHOLOGY OF THE TESTIS.

In the following pages a brief account of the chief diseases of the testis will be given, especially those which have been illustrated in the present and preceding Fasciculi. The order in which the Plates have appeared will be followed as far as possible.

I. Hydrocele of the Cord.
(Plate XLII. Fig. 1.)

Of this form of hydrocele the following statements may be made:—

1. It may occur at any part of the cord from the internal abdominal ring down to the testis; it is always enveloped by the coverings of the cord, and is almost invariably situated in front of the vas deferens and main blood-vessels.

2. It usually originates in a persistent portion of the funicular process of peritoneum, and is therefore most common during infancy or early childhood. It has been shown, however, that a few examples may arise in connection with the vas aberrans, or the organ of Giraldés, in which case the cyst is usually near the epididymis.

3. It hardly ever attains a large size, and is but little liable to be transformed into a hæmatocele.

4. The fluid from this form of hydrocele is rarely found to contain spermatozoa.

Although due to persistence of a fœtal condition, the hydrocele may first form in adult life. This is also the case with cystic dilatation of the canal of Nuck in the female (to which hydroceles of the cord are closely analogous). When the swelling developes rapidly the diagnosis of strangulated hernia may readily be made, owing to the induced pain and nausea.* Like cysts of congenital origin in other parts, such as hygromata of the neck, hydroceles of the cord sometimes undergo spontaneous inflammation, and have been known to suppurate without apparent cause.† Here again there is a liability for such a case to be mistaken for one of incarcerated or strangulated hernia.

Two special varieties of hydrocele of the cord may be noted. In the first a narrow opening or canal leads from the cyst into the general peritoneal cavity; in the second a similar communication exists between the lower part of the sac and the cavity of the tunica vaginalis. The former variety has for long been known under the meaningless term of *infantile hydrocele*; to the second attention has only of late years been drawn, a striking case being figured and described by M. Réclus.* An elongated hydrocele

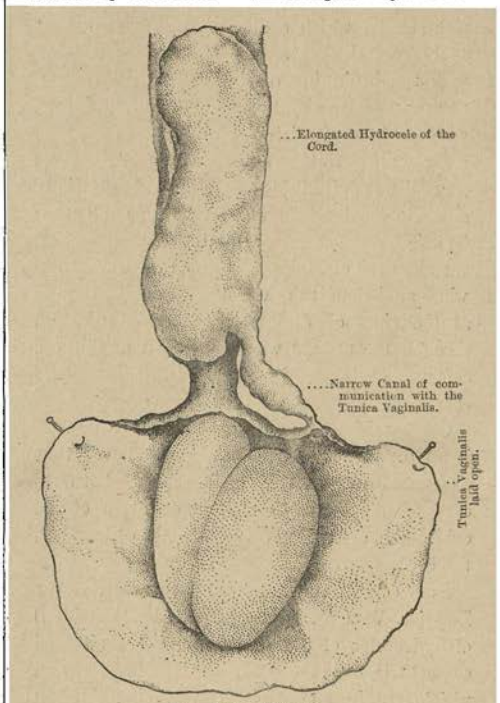

Fig. A (after Réclus).

of the cord reached in this specimen up to the external abdominal ring; at its lower end a narrow and rather sinuous channel led into the

* Instances of this are given by Curling, Nunn, Syme, and others.

† A good example of this occurrence was recorded by Curling ('The Diseases of the Testis,' 1878, p. 193).

* 'Traité de Chirurgie,' vol. viii. 1892, p. 41.

top of the dilated tunica vaginalis. Pressure exerted on the hydrocele of the cord led to gradual emptying of the upper sac into the lower, with the peculiar sensation caused in ganglia containing melon-seed bodies. Dissection showed that this was due solely to the small calibre of the aperture of communication, since neither melon-seed bodies nor flakes of lymph were present in the fluid. In fact it is rare for these hydroceles of the cord to contain anything more than a thin serous fluid. It has been already mentioned that occasionally, when situated low down and only slightly movable from the epididymis, they have been found to contain spermatozoa, the fluid being somewhat milky in aspect. The pathology of these exceptional hydroceles of the cord is well explained by a case reported by Mr. J. Jackson Clarke (Path. Soc. Trans. 1894, p. 105). The patient, an elderly man, had always been under the impression that he had three testicles. On dissection a smooth tense cyst was found above the right testis, which could be drawn somewhat apart from the cyst. The latter was connected with the beginning of the vas deferens by a narrow pedicle, about an inch in length, and of whip-cord-like consistence. The cyst contained a dense milky fluid swarming with spermatozoa; its wall was quite thin, except around a partially separate loculus. There can be no doubt that its origin consisted in a dilatation of the blind vas aberrans of Haller, and the cyst was somewhat analogous to a vesicula seminalis, though at the time of dissection the communication through the pedicle with the lumen of the vas deferens could not be made out in its whole course.

Curling himself never observed spermatozoa in any hydrocele of the cord, and believed that the cases in which their presence had been recorded were really examples of cysts of the epididymis extending up some little distance in the cord.

Four cases have, however, been recorded (by Langier, Vautrin, Uhde, Monod and Terrillon) of hydroceles of the cord which were situated some little distance from the epididymis, and which contained spermatozoa in their fluid. In Langier's case the tumour was close to the inguinal canal; in Vautrin's case microscopic examination proved the cyst to be lined with ciliated columnar epithelium; and no doubt in all a diverticulum from the vas deferens (or vas aberrans) formed the starting-point of the hydrocele.

The communication between a hydrocele of the cord and the general peritoneal cavity might be expected to be of only temporary persistence, when, as is so often the case in infants with a patent processus vaginalis, the upper end would become shut off by a natural process of adhesion a few months after birth. No doubt this is the rule, and the obliteration is accelerated by truss pressure, which is so frequently applied in these cases. Exceptions, however, occur where even in adult life a hydrocele of the cord may be capable of being emptied in an upward direction, may present a marked impulse on the patient's coughing, and may practically disappear on his lying down. A good example of this, in a man aged twenty-three, is recorded by Furneaux Jordan.*

The persistence of remains of the funicular process in the cord, for years after it has been shut off both above and below, has been repeatedly proved by careful dissection and microscopical examination; and Auguste Broca has shown that a potential sac communicating with the tunica vaginalis by a narrow orifice admitting a probe exists in many adults, the sac passing up amongst the constituents of the cord.

In practice that form in which the cyst can be emptied into the peritoneal cavity is of the most importance, since special caution is required in dealing with such cases. There is no doubt that many deaths have resulted in young children from ascending peritonitis following the surgeon's interference with this harmless sort of hydrocele (*e.g.*, from injection or tapping with an unclean instrument).† On the other hand, a few cases have been put on record in which a persistent "communicating" hydrocele of the cord has been cured by ligature of its neck. Probably careful dissection and complete removal is the best surgical treatment for hydrocele of the cord, but in children it is very rarely required, and in adults it can only be justified by the presence of definite symptoms of discomfort, &c. Nevertheless hydrocele of the cord deserves study from the errors in diagnosis to which it is apt to lead, errors made more probable by its comparative rarity.

It is especially with hernia that it has been mistaken, and it may be noted that several

* 'Brit. Med. Journal,' 1875, vol. ii. p. 257.

† For a detailed report of one such case see Mr. Poland, 'Path. Soc. Trans.' 1885, p. 294.

museum specimens* prove the occasional coexistence of hernia and hydrocele of the cord; further, that a collection of fluid in an old and otherwise empty hernial sac is hardly to be distinguished from a true hydrocele of the cord. In an interesting specimen of this form the true hernial origin of a long cyst of the cord was only ascertained by the presence of a fringe of omentum projecting from the wall of the sac; it was entirely cut off from the main part of the omentum which adhered to the peritoneal lining near the internal abdominal ring, nor did the hydrocele communicate at the time of dissection with the general cavity.

A hydrocele of the cord is very rarely converted into a hæmatocele, but examples are to be found of this occurrence in the Hunterian Museum, that of St. Bartholomew's Hospital, and in the Musée Dupuytren. Occasionally, in association with a malignant tumour below, a blood-cyst is seen in the spermatic cord.† The question then arises whether such blood-cysts may not be really of sarcomatous nature. See Plate XLVIII. Fig. 3, of this Atlas.

Finally, it may be noted that in old-standing cases of peritoneal effusion the spermatic cord occasionally presents ill-defined collections of fluid, which, however, are hardly worthy of the name of hydrocele. The so-called diffuse hydrocele of the cord is of the nature of œdema, and appears to be generally due to obstruction from above (*e.g.*, from pressure of a truss). It is certainly very rare.

II. Hydrocele of the Epididymis.
(Plate XLII. Fig. 2.)

The literature of this form of cyst and the numerous theories as to its possible origin are quite out of proportion to its practical importance; but a brief review of the subject may here be given without going into needless detail. In the first place it is to be noted that the so-called hydatids of Morgagni, the small usually pedunculated cysts found close to the globus major, have probably nothing whatever to do with hydrocele of the epididymis. According to Waldeyer, the hydatid is the terminal remains of the duct of Müller. Whether this is so or not —and the frequent occurrence of two or more "hydatids" on the same side, is certainly not in favour of this view—there is no evidence that these minute cysts ever become enlarged so as to form a hydrocele. Hydroceles of the epididymis are conveniently divided into two classes.

1. *Subserous or lenticular cysts*, of small size (rarely larger than a pea), situated beneath the layer of tunica vaginalis which covers the epididymis, and containing spermatozoa only very occasionally. They are of common occurrence, especially in elderly subjects, and possess clinical interest only in that they may be occasionally detected during life as apparently solid nodules. The tension of the cyst and its small size account for this fallacy. They are frequently multiple, and a plausible theory for their origin is that they are due to adhesions of the serous membrane lying between the epididymis and testicle; in other words, that they are inclusion-cysts. Such cysts would obviously not contain spermatozoa, though the contained fluid may be white or milky, owing to the abundant presence of epithelium or fatty material. Generally, however, it is clear and serous in character. A somewhat similar origin may here be noted of larger cysts, due to obliteration of the tunica vaginalis in great part, and distension of the remaining portion, which may happen to overlap the epididymis; a good example of this is shown in Plate XLII. Fig. 7.

The inclusion-cysts may be found along any part of the epididymis, but are much the most common in connection with the globus major. Their apparent hardness is due mainly to the extreme tension of their contents, but sometimes also to the tough fibrous tissue forming their wall. And it is quite possible that to a process of degenerative sclerosis in old age, such as has been clearly made out to occur in the female breast, and to account for multiple cysts in that organ, may be due the formation of some of these lenticular cysts. It is easy to see that should this be true, and the cyst be developed at the expense of one of the minute convoluted tubes, it may contain spermatozoa.*

2. *The large cysts of the epididymis* (spermatic cysts of the French writers, encysted or parenchymatous hydrocele of the epididymis, Curling). It is this form which is of real practical importance; it is represented in Plate XLII. Fig. 2 of this Atlas, and Figs. 10, 11, and 12 of Curling's work. Mr. Shattock has given a good representation of it† under the head of Parepididymal Cyst, and

* *E. g.*, one in the Hunterian Museum, No. 2460; and another in the London Hospital Museum, No. 41.

† Specimen in the London Hospital Museum.

* As in a case figured in the 'Path. Trans.' 1894, p. 106.

† 'Path. Trans.' 1892, Plate II. Fig. 3.

argues strongly in favour of its being due to dilatation of a vas aberrans or similar remains of Wolffian tubuli connected with the epididymis. In fact the final conclusion of the long conflict of views which has prevailed as to the origin of this form of hydrocele (which is especially noteworthy from its containing spermatozoa in the great majority though not in all cases) seems to be that it starts by distension of some fœtal tubular remains. It is only necessary to enumerate the latter, or at least such of them as may fairly be accused.

A. The vas aberrans of Haller—a somewhat convoluted thin-walled tube, blind at one end and opening at the other into the lower part of the canal of the epididymis or the beginning of the vas deferens. It may extend a short distance up the cord; the proportion of cases in which it is present has not been ascertained, but it is certainly fairly common, and may be double or branched.

B. The organ of Giraldés, a convoluted collection of tubules blind at both ends, lined with columnar epithelium, and forming two or three minute lobules at the side of the vas deferens close to the globus major.

C. The "vas aberrans of the rete testis," a small saccular dilatation of a tubule present in connection with the coni vasculosi in over fifty per cent. of subjects examined (Poirier), and usually measuring only 5 or 6 millimètres (one-fifth of an inch); whereas the vas aberrans of Haller is often, when unravelled, a few inches in length. The former is close to the globus major, and could therefore only account for cysts in this region; the vas aberrans of Haller is nearer the globus minor.*

The variety of hydrocele under consideration, originating probably from one or other of the fœtal remains just described, may be uni- or multi-locular. Its wall is commonly quite thin, but occasionally very numerous cysts are separated by tough fibrous tissue, as in a specimen dissected away from the epididymis and cord of a boy aged seven by Mr. Mallins.† Such complicated multiple cysts are obviously unsuitable for treatment by iodine injections. The cysts are lined by columnar or flattened epithelium, and the fluid contents differ in the most marked way from those of the common vaginal hydrocele. In the first place the fluid is either perfectly colourless, opalescent, or tinged with white (like milk and water). Secondly, it almost always contains active spermatozoa or their remains. Thirdly, alkaline carbonates, chlorides, and phosphates are present in considerable quantities, and the former may cause marked effervescence on the addition of acetic acid. Finally, albumen and fibrinogen are absent or very sparingly present.

The hydrocele cannot by pressure be wholly detached from the testis, though there is often a groove between the two, the upper part of the hydrocele being the largest, and suggesting the comparison to a inverted pear. Growth is slow, and it is rare for them to contain more than a few ounces of fluid. They have, however, been known to extend up into the inguinal canal, and Dr. Cameron ('Lancet,' 1884, vol. i. p. 842) removed no less than forty-six ounces of fluid containing spermatozoa from such a case.

It is a curious fact, perhaps explained by the pressure or stretching being directly exerted on the epididymis, that a comparatively small hydrocele in this position may be attended with greater sense of discomfort or pain than a large hydrocele of the tunica vaginalis. Nor are they as a rule so amenable to treatment by injection of iodine or carbolic acid as the more common form of hydrocele.

Hydroceles of the Visceral Layer of Tunica Vaginalis—Encysted Hydrocele of the Testis (Curling). Although two examples of this form of cyst are figured in the Atlas (Plate XLII. Fig. 6, and Plate XLVIII. Fig. 1), it must not be assumed that they are at all common; in fact they are so rare as to be pathological curiosities. They are sometimes referred to as cysts of the tunica albuginea, or as being formed between this membrane and the tunica vaginalis; but their real origin and nature are wholly obscure.

III. Hydrocele of the Tunica Vaginalis. (Plate XLIII. Fig. 1.)

A few words must suffice for *congenital hydrocele*. In this form the process of peritoneum which descends just before or with the testicle remains open the whole way down. Its chief features—the impulse on coughing, the marked reduction in size after the child has laid down

* Roth ('Zeitschrift für Anat. und Entwick.' ii. 1876, and Virchow's 'Archiv.' lxxxi. 1880) appears to have been the first to discover vasa aberrantia in connection with the rete testis.

† Specimen in Mus. R. C. S., No. 4274A; Path. Soc. Trans. 1888. See also No. 4265 in the same museum; in this specimen the fibrous tissue was so plentiful that the tumour was considered to be solid.

for some time or on pressure by the surgeon's hands, and its tendency to spontaneous cure—are too well known to require emphasis. With regard to the latter point exceptions occur, even if a truss be worn for long. Thus Curling mentions the case of a young man with congenital hydrocele persisting to the age of twenty-four, and being only cured by iodine injections.* The impulse on coughing, and the rate of decrease in size on pressure from below are also variable, owing to the size of the aperture of communication with the peritoneal cavity being sometimes large, at others extremely small. The following case well illustrates the latter point:—A young child presented a hydrocele which was apparently irreducible, and after a time it was tapped. Unfortunately inflammation followed the tapping, and the child died of peritonitis. After death a minute aperture of communication was demonstrated.

The translucency of the swelling is usually accepted as proof of its being fluid, but occasional exceptions occur in which a hernia in an infant (containing small intestine distended only with gas) is also translucent. It is of course possible for a congenital hydrocele to become converted into a congenital hernia, and hence the importance of truss pressure to secure obliteration of the upper part of the canal, usually followed by absorption of the fluid below.

One interesting form of congenital hydrocele is figured in Plate XLIV. Fig. 1. A testis wholly or partially undescended may be, and often is, situated at the upper end of a pouch of peritoneum, which reaches down to the scrotum (perhaps accompanied for a certain distance by a loop of the vas deferens). Specimens in the London Hospital and Guy's Museums well illustrate this condition. (See Fig. B opposite.)

The old view that the testis in its descent, during the last three or four months of fœtal life, *pushes* down a pouch of peritoneum has been considerably modified. We know that the pouch may descend independently of the testis, no doubt from some fibres of the gubernaculum being attached to the former; further, that in very rare cases a double pouch may be drawn down so as to prepare the way for an infantile hernia.*

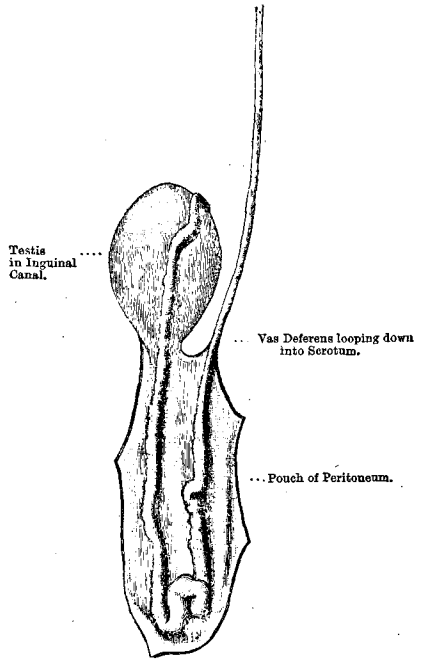

Fig. B (after Réclus).

In seeking the causes of the *ordinary hydrocele* of adults, an attempt has been made to place them all under the heading of inflammation—either of testis, epididymis, or of the tunica vaginalis. To quote Réclus, who is one of the strongest advocates of this view, "Inflammation, acute or chronic, patent or latent, such is the only cause of hydrocele, and each of the factors hitherto involved has no influence on the effusion except as a starting-point of inflammation." Every one admits that an orchitis or epididymitis is very frequently complicated with inflammation of and more or less effusion into the tunica vaginalis. This effusion is almost invariably present with gonorrhœal epididymitis, very frequently with tubercular disease (in 23 out of 60 cases according to one observer), usually present in traumatic orchitis, and not uncommon with syphilitic disease of the testis. It may complicate a new growth (as in the case of sarcoma represented in Plate XLVI. Fig. 2, where the fluid was mixed with blood), and has been met with in orchitis secondary to irritation

* The proportion of adults in whom the processus vaginalis persists, favouring congenital hernia or hydrocele, is a point of interest to determine. Ramonède, who examined the bodies of 215 adults dying between the ages of fifteen and forty-five, found the communication between peritoneum and tunica vaginalis "wholly or partially open" in 32 cases, *i. e.*, 14 per cent. Of infants at birth it is estimated that six out of eleven have a patent vaginal process.

* C. B. Lockwood on Hernia.

of the prostatic urethra or to stricture, and that due to small-pox, typhoid fever, parotitis, &c.

But this is far from proving that all cases of hydrocele are due to inflammation, or in other words are secondary affections. It will be noticed that Réclus admits the inflammatory cause may be latent, and certainly it is often remarkably so. It is true that operation on or dissection of some cases of apparently "idiopathic" hydrocele may reveal thickening of that part of the vaginal wall which covers the epididymis or testis, and perhaps adhesions between the layers. But the former condition is hardly conclusive evidence of previous inflammation, and the latter are rarely present (in only three out of eighteen cases operated on by Mr. Jacobson, and in these they were very slight). It is asserted that a slight traumatism is a not infrequent cause of effusion into the tunica vaginalis, but the statement is difficult to prove. On the whole we must be content with admitting an inflammatory origin in many cases of hydrocele, although the majority seem to be examples of merely passive or unexplained effusion.

As regards the side affected, hydrocele is a little more common on the left than the right side.

The Fluid contained in a Hydrocele. — The marked resemblance of ordinary hydrocele fluid in colour to normal urine, its somewhat lower specific gravity (1020 to 1024), the large quantity of albumen, and the presence of fibrinogen are well known.* Nor is it necessary to more than allude to the occasional admixture of blood which may occur, especially after tapping. The vascularity of the wall of old hydroceles is most strikingly seen in injected specimens, as undoubtedly the distension leads to enlargement of the anastomosing veins around the sac. These enlarged and tortuous veins can be seen to project on the inner surface, apparently covered only by the endothelium, and it is easy to see how slight traumatism, or the sudden diminution of tension due to tapping, may cause more or less copious hæmorrhage from these vessels. Hence the conversion of a hydrocele into a hæmatocele after tapping may occasionally be due to no fault of the operator, since it is difficult or impossible to distinguish the veins which run on the inner surface through the scrotum.

Cholesterine is frequently found in old hydroceles, and may sometimes be seen as brilliant golden particles or flakes, which slowly settle at the bottom of the fluid. Owing partly to concentration of the latter it may become thick and almost syrupy in consistence, with brown flakes largely composed of cholesterine. Loose fibro-cartilaginous bodies, perfectly spherical and smooth, Curling remarks are more frequently present in the cavity of a hydrocele than is generally supposed; and their presence may sometimes explain the failure of injections to effect a radical cure. They will be referred to again further on.

Occasionally a flocculent milky fluid (not containing spermatozoa) has been drawn off from a vaginal hydrocele. This form of "lymph hydrocele" is due to the presence of abundant fatty matter, but its origin is somewhat doubtful. Communication with one or more lymphatic vessels may account for some cases, degeneration of inflammatory exudation for others. In the lymph-scrotum and lymph-hydrocele met with in Egypt, India, and some other countries, the condition is undoubtedly due to the filaria sanguinis hominis, the parent worm lodging in some part of the lymphatic system and obstructing the upward flow, and the embryo filariæ have been detected in the hydrocele fluid. Dr. Bancroft has found in clear fluid from such a hydrocele a red hair-like mass made up of four parent worms. He has also pointed out that the filariæ in the blood may be associated with and perhaps cause orchitis, as well as lymph-hydroceles and lymph-scrotum. See Bancroft, Path. Trans. 1878, p. 407 (cases reported from Queensland).

It is possible that communication between the hydrocele and lymphatic vessels may also account for the cases in which a copious light buff-coloured deposit (free from all trace of blood) is found lining the hydrocele cavity. There is a very good specimen of this in the R. C. S. Museum (No. 4150). This deposit may quite prevent translucency being obtained. The other chief causes for the absence of this important symptom of a hydrocele are—1, fibrous or cartilaginous thickening of the wall; 2, abundant inflammatory lymph within the cavity, or actual suppuration; 3, previous injection with

* In a small proportion of cases (1 in 25 according to Mélin) the fluid let out coagulates spontaneously on standing. Lisfranc and Chaumet have recorded cases in which the contents of the hydrocele were of jelly-like consistence, and could not be evacuated through a cannula. M. Bréville's analysis of the fluid in ten cases of ordinary hydrocele is as follows:—Water, 91 to 96 parts; albumen, 3·5 to 7 parts; chlorides and phosphates, ·5 to 1 part; fibrinogen and cholesterine in varying amount.

strong iodine solution; and 4, the occurrence of hæmorrhage from the walls of the hydrocele.

In a remarkable case operated on by Chalot a hydrocele in an infant of only six weeks was quite opaque. Puncture, twice repeated, let out a creamy fluid containing cholesterine and much fatty matter, and was followed by ultimate cure of the hydrocele.

A few cases have been recorded (by Curling, Luschka, Reverdin, and Krause) in which the fluid obtained from a hydrocele of the tunica vaginalis contained spermatozoa, no doubt from rupture into it of a small hydrocele of the epididymis.

The amount of fluid contained in a hydrocele of the tunica vaginalis may reach to an almost incredible quantity. In one case recorded by Rochard nearly a gallon of fluid was drawn off; in the celebrated case of Gibbon the historian, Cline is said to have drawn off six quarts! A hydrocele of some standing is frequently complicated by a hernia above it, but when very large the hydrocele may distend the inguinal canal, and bulge in hour-glass form in the iliac fossa. Sir J. Lister, Sir G. Humphry, Rochard, and others have recorded examples of this.

In a case reported by Bazy, the upper abdominal portion of the hydrocele was much the larger, and extended above the level of the umbilicus. In one under Prof. Tillmanns the hydrocele detached the peritoneum from the transversalis fascia, behind the anterior abdominal wall, as it extended upwards.

As the fluid accumulates it is apt to form a pouch by projecting into the digital fossa, which intervenes on the outer side between the testis and epididymis. As a rule the aperture of this pouch widens, so that one sac is produced; but sometimes a well-marked diverticulum, opening into the general cavity of the tunica vaginalis by a rounded aperture, results. In this case a second form of hour-glass hydrocele is produced. This distension of the digital fossa is not without practical interest, for the body of the epididymis becomes displaced and flattened. In some specimens where the vas has been injected with mercury the body of the epididymis can be seen to be displaced to the outer side of the testis for an inch or more, and strongly curved (the globus major of course retaining its connection with the testis). Often, too, the vas itself is separated from the epididymis. In the operation of excision of the parietal layer, which is now often performed for radical cure of hydrocele, it is obvious that unless good allowance is made for this displacement there is danger of wounding either vas or epididymis.

Changes in the Sac-wall.—Of these by far the most frequent in an old hydrocele is simple fibrous thickening. The cremaster muscle becomes also, as a rule, hypertrophied. Whether as a result of traumatic inflammation, of the deposit of blood-clot on its inner surface, or of simple hypertrophy, the tunica vaginalis may become extremely thick and hard, so hard that it suggests calcareous degeneration to the touch. And as a matter of fact deposit of lime-salts, and even the formation of bony plates, is not unknown. There is a remarkable specimen* in the London Hospital Museum, consisting of a large number of true bony plates (some as large as a shilling) which were discharged by suppuration from the wall of an old hydrocele. There are two specimens in the College of Surgeons Museum in which the wall of the hydrocele is almost entirely calcified. In these cases, and in others in which the fibrous thickening is very pronounced, the testis is generally atrophic. Their unfitness for radical cure by injection is obvious.

Sometimes the fluid in an old hydrocele is slowly absorbed, and the testis is left surrounded by tough fibrous tissue, half an inch or more in thickness. Especially if the hydrocele is of inflammatory origin, adhesions are apt to form between the parietal and visceral layers. These adhesions may also be the result of injections, and vary from delicate bands to complete fusion of the two layers. Such fusion may obliterate the lower part of the cavity, whilst above the testicle a collection of fluid remains which may simulate a hydrocele of the epididymis.

M. Gosselin asserted that a testis of which the tunica vaginalis was completely obliterated by adhesions is incapable of secreting spermatozoa. This statement, improbable as it sounds, has been copied into a number of works, but Réclus has proved its absolute want of foundation. Out of eleven specimens examined, in all of which the cavity of the tunica vaginalis had disappeared, spermatozoa were clearly demonstrated in the corresponding testis in all but three. And each of the subjects in which they were not found was over seventy years old, an age at which the secretion has ceased in at least 50 per cent. of individuals.

* No. 2038.

Under usual conditions the testis is situated at the back and towards the lower part of a hydrocele. If, however, inversion be present the testis will be placed in front. One effect of the long continued pressure of an old hydrocele is to flatten both the testicle and epididymis so that they come to project into the cavity less and less; the serous membrane over them takes part in the general thickening, which may indeed be especially marked in this part of the hydrocele.

Complications of Hydrocele. — Some of these have already been noted. In cases of old thick-walled hydroceles the testis and epididymis may undergo atrophy from pressure, and from invasion of the fibrous tissue. The transformation into a hæmatocele from traumatism is well known, and rupture of the sac into the scrotal tissues from the same cause has been observed in many cases. Inflammation and suppuration after simple tapping (and occasionally in the absence of the latter) form an important complication, which is more frequent than some writers would lead one to infer. It may be diagnosed by the painful induration which comes on about the testis and cord, the rapid re-accumulation of fluid, œdema of the scrotal tissues, and general febrile reaction. It calls for prompt incision, washing out the inflammatory deposit with antiseptics, and free drainage.

The occurrence of a hernia above a hydrocele is often met with, and there is no doubt that one condition leads to the other; thus a hernia, or the truss pressure employed for it, obstructs the lymphatic return and tends to produce a hydrocele; on the other hand, a large hydrocele, by its dragging effect upon the cord, seems to predispose to the descent of a hernia.

A few words as to the treatment of hydrocele will not be out of place here, since the subject is so closely related to its pathology.

Acupuncture and the use of setons are practically abandoned; simple tapping is reserved for some cases in which there is a probable tendency to spontaneous cure, and for others in which palliative treatment is alone advisable.

Careful injection with tincture of iodine is probably the best form of "radical cure," but will not succeed where there is a loose body in the sac, or where the hydrocele is old and thick-walled. Antiseptic excision of the wall is indicated for such cases, with care not to damage the epididymis or vas, &c. No method, however, is absolutely infallible, recurrence having been noted after every one. In suitable cases treated by iodine injection by competent surgeons the proportion of failures does not appear to be more than from 5 to 10 per cent.

IV. Cartilaginous and Calcareous Bodies in the Tunica Vaginalis, &c.

(Plate XLII. Figs. 3, 4, and 5.)

These may be either pedunculated and somewhat rounded in shape, or may occur in flakes or plates in the substance of the lining membrane, both forms being illustrated in this Atlas. When pedunculated they are usually met with attached to the globus major (Figs. 3 and 5), and by stretching and ultimate detachment of their stalk they become loose in the tunica vaginalis. They are never seen except in subjects of adult life or old age, and rarely exceed the size of a pea.* Their surface is smooth and polished, and may show no trace of any previous attachment of a pedicle. It is interesting to note that similar rounded cartilaginous or ossific bodies have been met with in hernial sacs, and in the general peritoneal cavity; in the latter their origin has occasionally been proved to arise from the appendices epiploicæ. Two examples found loose in the tunica vaginalis and preserved in the London Hospital Museum were analysed and found to contain fatty matter, cholesterine, and calcareous salts. Curling proved the presence of bone-corpuscles in some of them. Their practical interest lies in their usual association with hydrocele, and it is stated that the irritation of these loose bodies may start or keep up the over-secretion of fluid. On the other hand, they may be merely the result of a plastic inflammation of the tunica vaginalis, possibly started by some lesion (*e. g.*, stricture) of the bulbous urethra. This is the view held by Réclus.

Transverse section of the loose bodies shows concentric fibrous laminæ; in the centre may be a calcareous nodule, or a small cavity containing fluid. It is of interest to note that traces of blood-clot are not infrequently present in them. Hæmorrhagic infiltration of the hydatid of Morgagni, from which a loose body is occasionally derived, has been observed.

Laminæ of calcareous or bony material have been noticed in the substance of the tunica vaginalis in many cases, nearly always in association with old hydrocele. One of the most striking

* Chassaignac removed one during life which was three-quarters of an inch long by half an inch across; it is figured in Lebert's 'Pathological Anatomy.' Richter met with three in one case which were the size of a hazel nut.

specimens is to be found in the London Hospital Museum (No. 2038). In this case a great number of bony plates, varying in diameter up to half an inch, were thrown off by suppuration from the wall of a hydrocele in an old man. Sir Astley Cooper records other similar examples. In one, analysis of the bony plates showed them to consist of about 40 parts of animal and 60 of earthy matter (carbonate and phosphate of lime). Mention may here be made of the not infrequent calcareous degeneration of inflammatory deposit in the epididymis (either tubercular or gonorrhœal in origin) which has been known to ultimately excite suppuration and troublesome sinuses.

In some of the lower animals (*e. g.*, the ram, goat, and bull) calcification of the tubular structure of the testis is sometimes seen. One of the few instances recorded in the case of the human testis is given in the Path. Trans. 1885, p. 296, by Dr. J. Price. In the body of a man aged sixty-four both testis and epididymis were practically replaced by true bone, so that hardly any trace of tubular structure remained. The affection was symmetrical. The only cause suggested was old orchitis due to stricture of the urethra, and ossification of the inflammatory products; but there was no certainty that the man had ever had orchitis.

In the Guy's Hospital Museum* there are three specimens of calcareous (and probably bony) deposit in the testis proper. One remarkable fact was that in each case *both* testes were similarly affected, though not to the same extent. The calcareous masses are situated towards the front of the testis, but in its substance, are of considerable size, well isolated, and of a rounded shape. There is no proof of the theory that they were due to old inflammation.

V. Varicocele.

(Plate XLIII. Figs. 2 and 3.)

The veins of the spermatic cord are conveniently divided into two sets, one (the anterior), containing the most numerous veins, lying in front of the vas deferens, and a second smaller posterior division lying immediately adjacent to the vas; both being within the infundibuliform fascia. In addition to these are numerous superficial veins, which may communicate near the testicle with the deeper ones, and which may partake in the general enlargement forming a varicocele. It is the anterior set which is dealt with in the operation of antiseptic ligature, and it is a point of considerable interest that in the centre of this bundle of veins, and therefore almost certain to be included in the ligatures, runs the spermatic artery. Out of thirty dissections the artery was found imbedded in the anterior bundle of veins in twenty-five cases. In only one did it run close to the vas and well separated from the veins (this has been erroneously stated by some writers to be its normal course). Owing to the anastomosis between the artery to the vas and the spermatic artery itself, the former is enabled to carry on the nutrition of the testicle after ligature of the latter.

The chief conditions accompanying a varicocele of long standing are—1, more or less atrophy of the testicle; and 2, relaxation of the scrotum, with atrophy of the cremaster and dartos muscles.

1. The proportion of cases of varicocele in which *the testicle is more or less atrophic* is variably estimated by different observers. Thus Sir James Paget states that atrophy of the testis from this cause hardly ever occurs, M. Tillaux that it is the usual condition. The fact is that in a large number of cases of varicocele even of long duration no difference can be detected between the testes of the two sides. In the minority (perhaps 1 in 5 cases) the testis on the side of the varicocele can be distinctly felt to be softer and somewhat smaller than the opposite organ, whilst now and then very marked atrophy is met with. On the whole the chance of atrophy may be said to be proportionate to the degree and long duration of the varicocele. As Mr. Jacobson* points out, a certain degree of softness and apparent diminution in size of the testicle may be a merely temporary condition, disappearing with the lapse of time, with altered sexual relations, or after a successful operation for the cure of the varicocele.

2. *Relaxation of the Scrotum, &c.*—In many cases the skin of the scrotum is abnormally lax and pendulous, the dartos and cremaster atrophic. In one case under our observation the testicle always hung nine inches below the external ring, and its coverings seemed to have lost all their tone and suspensory power; nor are such extreme examples very uncommon. This fact has led many surgeons (*e. g.*, Championnière, Henry (of New York), Le Dentu, Sir Astley Cooper), to advocate excision of a large portion of the scrotal

* Nos. 2351 (25, 37, 159).

* 'Diseases of the Male Organs of Generation,' p. 526.

skin as a remedy for varicocele, either with or without ligature of the dilated veins. This method of treatment is a very old one; it was urged by Dionis in 1707, and though probably rarely quite satisfactory when practised alone, is of undoubted utility when combined with the antiseptic ligature of the veins.

It is only necessary to mention such rare complications as thrombosis of the veins,* and scrotal extravasations (both usually due to traumatism). Neuralgia of the testis and general aching pains in the part (increased by active exercise or prolonged standing, and by constipation) are fairly frequent subjective symptoms, with regard to which it may be noted that they are very inconstant, and by no means proportionate to the size of the varicocele. The same holds true of varicose veins of the leg, the most extreme cases of which may suffer the smallest amount of inconvenience. It is often asserted that varicocele is an affection which disappears with the advance of old age, and Nélaton stated that only 1 in 5000 old men were affected with it. This is directly opposed by Horteloup, who found 42 cases out of 1600 inmates of the Bicêtre Infirmary at Paris, a percentage of about 2·5, rather over that given by Curling and Bennett as the proportion of young recruits rejected for the English army on account of varicocele. We may put it in another way—that elderly men with varicocele have rarely any inconvenience from it, and it is in them never brought under notice by a rigid physical examination.

Of all the many theories that have been advanced to account for varicocele, and for its remarkable proneness to occur on the left side of the body, we must notice one recently advocated by Mr. Bennett† and Mr. Spencer.‡ They hold that varicocele is caused by persistence and dilatation of fœtal veins which should have atrophied; it is, in fact, a congenital abnormality. It may be urged against this theory that it offers little or no explanation for the escape of the veins of the right testis, and that in bad cases of varicocele not one bundle of veins alone is dilated, but every vein of the scrotum as well as of the cord. Nor does the statement that in 85 per cent. of cases of varicocele "there are scars of old nævi or evidence of varix in other parts of the body" appear to offer convincing support. Varix of the lower limb-veins, and of the labia majora in the female (the latter corresponding to the scrotum), is always found to be due to obstruction above to the return of the venous blood, or to the mechanical interference with the circulation caused by prolonged standing, &c. M. Gaujot's observation of the frequency with which varicocele developes in young recruits, and his explanation that their muscular exertion during drilling, and the compression due to parts of their uniform, have much to do with this, are of interest. Further, it may be noted that the spermatic veins are long, tortuous, and pendulous in the erect position, and that their fairly sudden bend at the external ring may help in causing obstruction. At the same time, if one rejects the theory of pressure by the sigmoid flexure, there seems to be no explanation for the frequency with which the left side only is affected. This is well brought out in the statistics collected by Nébler, which give out of a total of 7600 cases 7000 in which the left side alone was affected, 300 the right alone, and the same number in which both sides were involved.

The cases in which varicocele has apparently followed rapidly an injury (contusion or sudden strain) are probably largely, though not entirely, to be explained by the accident having first drawn attention to a previously existing distension of the veins.

This is not the place to discuss the various methods of treatment, but it may be said that antiseptic ligature of the veins at two points, with excision of the intervening portion, and shortening of the cord by carefully securing the two divided ends together, has largely superseded all other plans for cases in which an operation becomes necessary. But care must be taken not to excise too many veins;* only the anterior bundle as a rule, and sometimes excision of part of the scrotum is also indicated. That the operation is at all frequently followed by further atrophy of the testis (in spite of the inclusion of the spermatic artery) is not probable, though no statistics are available on this point.

* *Vallin has published a case fatal from phlebitis attacking a varicocele, and Miflet one in which suppurative phlebitis placed the patient's life in grave danger. Schwartz (Encyclop. Internat. de Chir. t. vii. p. 544) records a case of extensive extravasation of blood from a varicocele, which occurred during a violent fit of coughing.*

† 'On Varicocele,' p. 33.

‡ 'St. Barth. Hosp. Reports,' 1887, p. 137; and Path. Soc. Trans.

* Mr. Jacobson observed a case of gangrene of the testis after the operation, which was attributed to this cause.

VI. Retention and Malposition of the Testicles.

(Plate XLIV. Fig. 1; and Plate XLIX.)

Before considering the various forms of malposition of the testis, we may note that the early and permanent descent of that organ, with obliteration of the processus vaginalis (except where it forms the serous investment of the gland), is one of the most striking peculiarities of the human race. Almost all the various abnormalities in position, &c., of the testis have their more or less exact counterpart in the normal condition of one or other of the lower animals.* The patent funicular process is found in monkeys as being the rule throughout their life, and it is of some interest that the congenital form of hernia, to which it predisposes in man, is occasionally, though rarely, met with in them. The chimpanzee and gorilla have, however, a closed tunica vaginalis. "In a few mammals, such as the elephant, the testes remain permanently within the abdomen; in a much larger number, as the rodents, they only descend at each period of the rut."† Sappey has recorded the case of a man in whom both testes were from time to time drawn up within the inguinal canals, and many somewhat similar cases could be adduced. It is well known that as regards mobility in the sense of power of retraction of the testis, the child possesses a higher degree than the adult, a fact again suggesting the comparison with lower animals.

The chief dates as regards the descent of the human testicle may be briefly given thus: About the tenth week of intra-uterine life the testis will be found touching and just below the kidney; at the end of the third month a short interval may separate the two; the testis then lies on the ilium, and by the end of the fifth month is close to the internal abdominal ring. Already the inguinal canal is to some extent prepared for its further descent, inasmuch as the processus vaginalis (to which is attached part of the gubernaculum) invariably precedes the testis. After a slow transit through the canal the latter organ reaches the scrotum during the ninth month. According to Wrisberg three out of every four infants at birth have both testes in the scrotum, in one out of five one or both organs are in the groin, and only one out of eleven has one or both still in the abdomen. At birth it is said that in ten out of eleven cases the processus vaginalis is still open, that of the left side becoming first closed as a rule.

Congenital defects due to arrest of development become more common the later the stage which such defect corresponds with (this is very well shown in the different degrees of hare-lip and cleft palate); hence, remembering the very early period of fœtal life in which the testes are situated just below the kidneys, and its short duration, we are not surprised to find that retention of the testis in this position is infinitely rare; in fact, there seem to be only two or three cases on record. The second degree of imperfect descent, that in which the testis remains in the iliac fossa, is more common, though not so frequent as the third, in which it occupies the inguinal canal. The fourth variety, where the testis is situated just outside the external ring (or in the inguino-scrotal furrow) is also fairly frequent.* Plate XLIV. Fig. 1 represents the second degree, where the testis in the adult is still above the internal ring, and shows also how in these cases the tail of the epididymis and the vas deferens are apt to loop down into the canal, sometimes to the bottom of the scrotum, the processus vaginalis always accompanying them. See also Fig. B, page 5.

It is important to note that the testis may occupy the inguinal canal at one time, at another (perhaps by forcible expulsive efforts) emerge from the external ring. It has been suggested that abnormal shortness of the vas deferens may prevent the further descent of the testis. This view was not accepted by Curling, but it may be affirmed most positively that in many cases of operation for imperfect descent the shortness and inextensibility of the cord constitute the chief obstacle to bringing down the organ to the bottom of the scrotum, and the cause of comparative failure. Inflammatory peritoneal adhesions have been invoked, apparently with reason,† as an occasional cause for arrest of the testicle in its descent, or abnormal smallness of the external abdominal ring. Imperfect formation of the gubernaculum (especially of its scrotal portion) is a more probable cause.

There are a few cases on record in which the testis has not descended simply because it did not exist, and in which the vas deferens passed

* The same statement is also true with regard to the abnormalities of the kidney.

† Quain's 'Anatomy.'

* This is the normal condition in the marmoset and some other animals.

† One of the clearest cases is recorded by the late Prof. John Wood (Path. Soc. Trans. 1856, p, 265).

through the inguinal canal only to end blindly. Of this extraordinary malformation a good example is in the London Hospital Museum (No. 2062), in which no trace of the testes could be found; and Fischer, of Boston, has recorded a similar bilateral case in a man aged forty-five.

Like other forms of arrest of development, the failure in descent of the testis may be hereditary. Godard has recorded an instance in father and son, Gosselin in the grandfather as well.

Three other forms of malposition remain to be mentioned, the first two apparently due to abnormal attachments of the gubernaculum. In the first the testis passes through the inguinal canal, and is then drawn into the perineum, between the scrotum and anus (Plate XLIX.). Many examples of this have been observed, and a considerable proportion of them operated on. In the second the testis also emerges from the external ring, but passes into Scarpa's triangle. In the third it takes the course of a femoral hernia through the crural ring. Both of these last two are extremely rare malpositions, and the small size of the femoral aperture in males would make the last almost incredible. Two of Curling's cases (one dissected), and others observed by Guincourt (operated on), Vidal, Eckardt, &c., establish the possibility of its occurrence; and it may be noted that the ovary has similarly been known to protrude through the femoral ring. On the subject of the gubernaculum testis, and its relation to malpositions, the elaborate work of Mr. C. B. Lockwood* is of much value. It confirms almost entirely the description first given by Mr. Curling. The gubernaculum is a band (muscular in great part), which can be first detected about the tenth or twelfth week of fœtal life. Its attachments above are—1, the testis; 2, the epididymis; 3, the peritoneum. Sometimes it is also attached to the cæcum, vermiform appendix, or ileum on the right side, the sigmoid flexure on the left. Its attachments to the peritoneum are of interest as accounting for the descent of the processus vaginalis sometimes quite independently of the testis; and to the cæcum, &c., in connection with some cases of congenital hernia.

Inferiorly the gubernaculum (at the fifth month) can be ascertained to "spread out like a fan into Scarpa's triangle, upon the pubis and root of penis, and towards the scrotum. In a fœtus of the sixth month a thick fasciculus passed onwards into the perineum, where it ended in the tissues about the anus and over the tuber ischii" (Lockwood). Sometimes a distinct attachment to the tuber ischii has been demonstrated (Cloquet). In a fœtus of the eighth or ninth month it is not difficult to dissect out three main bands to the pubis, the scrotum, and to Poupart's ligament.

It is now easy to see how preponderance of the perineal portion may account for the malposition figured in Plate XLIX., and in Curling's work (Fig. 3, after Godard), or how the scrotal band may be so ill-developed as to leave the testicle in the canal or at the external ring. But that the gubernaculum ever passes through the femoral ring is very doubtful. In the rare cases in which the testis is situated in Scarpa's triangle, it must either have come through the inguinal canal, and then been displaced by abnormal attachment of the gubernaculum, or, if at first retained within the abdomen, may have been protruded as a hernia into the femoral canal.

Torsion of the Cord with Hæmorrhage into, Atrophy, or Gangrene of the Testis. — Of this complication of incomplete descent of the testis, to which attention was first prominently directed by Mr. Bryant,* several cases have been recorded. It would seem that when the testis is not anchored in the scrotum, but comparatively free just below the external ring, a sudden exertion may lead to twisting of the cord, analogous to a volvulus of the intestine, or to torsion of the pedicle of an ovarian tumour. A similar accident has been known to befall the spleen, a floating kidney, &c. The remarkable fact about torsion of the spermatic cord is that in almost all the published cases it has affected an imperfectly-descended testicle. It may be noted here that in the normal descent a slight twist may occur, in no way affecting the nutrition of the organ. Anterior inversion, in the sense that the epididymis looks forwards and the body of the testis backwards, is fairly common (? 1 in 20 subjects); whilst lateral inversion (a still slighter degree) has been met with, and would no doubt be much more common but for the pressure of the thighs tending to make the testicle face either directly forwards or backwards. Even if the testis hangs normally, there may be a partial twist of the

* 'The Development and Transition of the Testis,' 1888, p. 97.

* 'Medico-Chir. Transactions,' 1892, p. 247.

constituents of the cord. In two such cases, one dissected, the other observed in the operation for varicocele, I have found the vas deferens the most anterior of all the structures forming the cord, but in both it passed to the back of the testicle lower down.

In the cases to which Mr. Bryant has drawn attention there is a sharp and severe torsion of the cord, the testis becomes engorged with blood, and may be almost unrecognisable as a black mass of clot; if left to itself gangrene will supervene, or complete atrophy of the organ. So certain appears one or other of these results that in operating on such a condition it appears to be useless to untwist the cord and leave the testis, a better ultimate result being obtained by removal of the organ, a course which facilitates the operation of radical cure of the hernia which may coexist. It is a frequent practice in some parts of the country, in order to obtain atrophy of the testes in some of the domestic animals, to vigorously twist the cord and testis, and the result appears to be remarkably constant.

Mr. Bryant's paper, already referred to, contains particulars of three cases, one reported by Prof. Keen of Philadelphia, and one by Mr. Nash of Plymouth.* The age of the respective patients was 15, 16, and 23 years. Mr. Barker† reports a fourth case in a lad of 15, Mr. Davies-Colley a fifth (aged 14). As Mr. Barker suggests, it is probable that others have been regarded as examples of inflamed incarcerated hernia. In a sixth case, under the care of Mr. Page‡ (a lad aged 17), as indeed in most of the others, the symptoms closely resembled those of strangulated hernia. Sudden onset after a straining effort, sometimes vomiting, severe local pains and tenderness over a swelling filling the inguinal canal and reaching to a variable extent below it, such are the chief symptoms of acute torsion of the cord, and all of them may be due to strangulated intestine. But with torsion of the cord there has been noticed in several of the cases more marked inflammatory reaction than with hernia, such, for instance, as a temperature of 101° or 102°. The amount of twisting is described usually as amounting to three half-turns of rotation, and it is always the epididymis which presents the most severe signs of strangulation. It may be coal-black from infiltration of blood, which latter also occurs in the testis proper. In Keen's case the hæmatoma was in an advanced condition of gangrene, and pyogenic micro-cocci and bacilli were proved to be present in the serum. A patent funicular process (as one would expect) was noted in each case, and in Nash's case, the specimen from which is in the Royal College of Surgeons' Museum (A, 4262), a band of great omentum seemed to have much to do with the strangulation of the epididymis, which was twice twisted on its long axis. The other cases appear to have had a simple pathology, consisting in torsion of the whole cord above the testis, well represented in a figure given in Mr. Bryant's valuable paper.* In this case, and in Davies-Colley's one, an attempt was made to save the organ by untwisting the cord; atrophy followed in the former, sloughing of the testis in the latter. In the other four cases the cord was ligatured, and the swollen and engorged testicle removed. They form a group of clearly defined examples of a lesion of the testis whose pathology has only of late been recognised. In fact no mention of its occurrence in the human subject will be found in some of the special works on the testis, or general treatises on surgery, either English or foreign.†

As we have seen, the examples quoted have all related to imperfectly-descended testes. But we must go a step further and admit that torsion of the cord may occur in a fully-descended organ. Mr. Nash‡ gives a most interesting example, which may be thus summarised: A lad, aged 19, after some vigorous athletic exercise, was seized with pain in the right testis, vomiting, and faintness. The testis and epididymis were tender, the latter swollen, and a lump could be felt a short distance up the cord. The epididymis lay in front. Reduction, with complete relief of the symptoms, was effected by rotating the organ to the right.

There can be little doubt that this case fur-

* Originally published in the 'Brit. Medical Journal,' June 6th, 1891.

† 'Lancet,' April 8th, 1893.

‡ 'Lancet,' July 30th, 1892.

* 'Medico-Chir. Trans.' vol. lxxv. p. 249.

† Amongst the earliest well-recorded cases are those of Langton ('St. Barth. Hosp. Reports,' vol. xvii. p. 188, under the heading of "Hæmatoma of the Epididymis"), and Nicoladoni ('Archiv für Klin. Chir.' 1884). In the former case the testis was found to be extremely mobile, the epididymis was almost black, gangrene of it and the testis followed the attempt to preserve them after untwisting. See also Bramann (Langenbeck's Archiv, vol. 40, p. 137). Fischer, Socin, Meyer, and Trendelenburg have also published cases.

‡ 'Brit. Med. Journal,' April 9th, 1893.

nishes the explanation of some hitherto obscure instances of "traumatic orchitis" without other traumatism than a straining effort, which have been followed by extreme atrophy of the testis. One such, occurring in a lad aged 14, has lately come under observation. After the onset of symptoms he was so ill as to be confined to bed for three weeks. The scrotum was said to be quite dark, "as though bruised," though there had certainly been no contusion; and after the testicle had gone through a period of orchitis it (with the epididymis) atrophied to an extreme degree, both organs being stony, hard, and not one-fourth the size of the opposite ones. Congenital syphilis and gonorrhœa were wholly excluded, nor did the symptoms and course agree with an orchitis due to either.

Further, we must admit that lesions closely resembling these, due to twisting of the cord, may be found without proof of the occurrence of the latter. Messrs. Jacobson and Stephen Paget have recorded examples, both in young men, in which, after sudden descent of the testis into the canal or below the external ring, the severe symptoms already noted came on and necessitated operation. In both the organ was removed, and found to be quite disorganised from infiltration with blood; but in neither "was there any twisting of the cord." In the first case (which occurred in 1879, before torsion of the cord was recognised) there had been a previous attack, after which the patient had worn a truss until a few days before the second one, which led to the operation.

In a case of congenital strangulated hernia, with testis retained in the canal, which came under care in the London Hospital, after division of the stricture and return of the small intestine, the testis and epididymis were seen to be coal-black from hæmorrhage into them, and were removed. No twisting of the cord was noticed, but obviously this condition is especially likely to be overlooked when the testis is high up. And even when it has reached the scrotum the probability of this escaping notice is considerable, and for this reason the subject has been here treated at considerable length, as well as on account of its novelty. It is not unlikely that twisting of the cord may occur on several occasions, and be spontaneously relieved, no other explanation fitting well with such a case as the following: A healthy man, aged 30, free from gonorrhœa, stricture, &c., had repeated attacks of apparently causeless "orchitis" on one side. The testis was well descended. Each attack left the epididymis more swollen, and was attended by considerable pain and tendency to vomit. In the intervals he stated that he was fairly well, but that the testis never regained its usual size, was somewhat painful, and the condition much interfered with his work. Ordinary treatment failing to improve the condition, I excised the organ (without noticing any twist of the cord), and was surprised to find the lesion consisted in both old and recent hæmorrhage into the whole of the epididymis, converting that organ into a tough mass of clot.

It is certainly a fact of great interest that the cord should be capable of such marked rotation as found in some cases (one and a half or two complete turns), and the exact method is not obvious. Possibly a sudden contraction of some of the more oblique fibres of the cremaster may have some effect in its mechanism. However this may be, one general statement may safely be made, that torsion of the cord occurs chiefly in those cases where the testis is abnormally mobile, either from imperfect descent or from absence of the usual adhesions to the bottom of the scrotum. These latter are, it is well known, largely the remains of the middle part of the gubernaculum, and vary much in their development in different individuals.

That torsion of the spermatic cord may occur in the lower animals as well as in man was proved by Bland Sutton,* who has figured and described a specimen of it obtained from "an old pug-dog." The testis here was completely retained (close to the kidney), and was the seat of a malignant tumour, which had caused great increase in its size. In these respects the case differs from the ones already reviewed, and approaches more closely to twisting of the pedicle of an ovarian tumour.

Development of Tumours.—It is hardly necessary here to recall the fact that imperfectly-descended testes appear to be specially liable to the development of new growths. As is the case with the normally-descended organ, these are, in the great majority of cases, of a malignant character. A few examples of cystic disease (with or without the formation of cartilage nodules), and one of enchondroma, have been recorded; whilst the number of cases of malignant disease is far greater. Monod and Terrillon

* 'Med. Chir. Trans.' 1892, p. 257.

have tabulated 42 cases, and in these, which have been carefully investigated, sarcoma and carcinoma appear to occur in equal proportions. The reasons alleged are very unsatisfactory. Virchow's explanation that the testis in the inguinal canal or just below it is specially liable to traumatism is of little weight, seeing that many instances have been recorded where the tumour started in a testis retained in the iliac fossa, where it would be peculiarly exempt from injury. In the case given by Bland Sutton (from a dog) the organ lay immediately below the kidney. According to the latter authority, "retained testes in dogs, bulls, horses, and rams are as liable to become the seat of malignant disease as in man." Another theory, that the ill-developed or rudimentary condition of the retained testis renders it prone to take on new growth, is no more convincing; for how rarely does this occur in other rudimentary organs, such as the male mammary gland, in comparison with the fully developed and functional female breast!

The age at which the growth developes is from seven to forty years (Monod and Terrillon), and its progress to a fatal issue, owing often to secondary glandular or visceral deposits, is rapid. If situated within the abdomen it may attain an extraordinary size, resembling an ovarian tumour, and its proximity to the iliac veins may lead to thrombosis of the latter. In several cases an attempt has been made to remove the tumour, with on the whole discouraging results. Almost the only case reported in which much benefit was obtained is one operated on by Guyon, who in 1879 removed a "true carcinomatous tumour" affecting a retained testicle in a young man, who six years later was in good health. In another (inguinal retention), operated on by Després, the patient was quite well at the end of four years. The tumour was a sarcoma, as in a case operated on by Mr. Treves,* in which recurrence took place twenty months after the operation.

On Imperfect Descent in relation to the Function of the Testis.—An important group is formed by those cases in which all the genital organs and sexual features are non-developed, the testes being invariably small, sometimes retained, but more often they can be found at or just below the external rings. In such patients the imperfect descent cannot be regarded in any way as a cause of the general non-development, but merely as one of its features. The following is a typical instance: A man aged 24 has the appearance and alto voice of a boy of 15. He presents no trace of sexual hair, the penis and scrotum are quite rudimentary, the former only two inches long and the thickness of a small little finger. The testes are placed high up, but can be pressed down into the scrotum; they are firm, and about the size of horse-beans. It is doubtful whether he has ever experienced any sexual desire; he is nervous and desponding, and often sheds tears. In another still more extreme case there was no trace of pubic or facial hair, the testes were no larger than hazelnuts, the prostate and vesiculæ seminales could not be detected per rectum, and the penis was not more than an inch and a half long. He was aged 32, and presented the same despondent mental condition as the previous case. In some of these patients with symmetrical non-development of the testes, &c., there is excessive deposit of fat in the mammary regions and elsewhere. For such cases no treatment is of use, and it is probable that the minute structure of the testes is as imperfect as their diminutive size would lead one to infer; in other words, the patients are probably both impotent and sterile. But what is the condition when both testes are retained in the inguinal canals or iliac fossæ, but where the penis is of good size and the other male characteristics present?

It must be admitted that such cases are very uncommon. Marshall, who found 11 cases of ectopia testis out of nearly 11,000 young men examined for the Army, only observed one bilateral case. Rennes (out of 3600 French conscripts) had not met with one. Jacobson* records one only; the subject had each testis in the inguinal canal. He died after an operation for strangulated hernia at the age of 32, and no spermatozoa could be found in the testis examined. There is in the London Hospital Museum a specimen of double retention of the testes (just within the internal rings), from a well-developed man of about 40 or 50 years. He had been married, but had had no children. No spermatozoa could be found in the secretion of either testis. Curling's examination of the semen from nine similar cases (*i. e.*, of bilateral retention, or of unilateral retention where the other gland had been removed or placed *hors de combat* by old inflammation, &c.) gave emphatic support to the view that such organs are in-

* Specimen in R. C. S. Museum, No. 4239.

* *Loc. cit.* p. 82.

capable of secreting spermatozoa. A large amount of corroborative evidence has been obtained from dogs and horses, as well as from men (by Prof. Spooner, Godard, Follin, Goubaux, and others). On the other hand, we have a few cases in which retained testes in men have been proved to secrete spermatozoa. One of the clearest examples is quoted by Curling from Mr. Hutchinson (the testis examined was removed from the inguinal canal of a man aged 27), and in a case of Beigel's (of double retention) the seminal fluid was said to contain spermatozoa. Valette,* Monod and Arthraud,† and Mr. Poland‡ give confirmatory cases. The two French writers just quoted have proved that retained testes are liable to important degenerative changes, consisting in—1, arterio-sclerosis; 2, increase of fibrous tissue, starting in the tunica albuginea and body of Highmore; and 3, fatty and granular changes in the epithelium which should secrete the spermatozoa. This degeneration may occur comparatively early in life. We are now in a position to answer the question proposed with a fair amount of confidence in the following way.

Given a male adult with both testes retained in the inguinal canals, or within the abdomen, or with one testis retained and the other not capable of secreting spermatozoa into the vas deferens:—

1. The subject may have sexual desire and every sign of virility (on this point the evidence is absolutely conclusive).

2. The fluid emitted may *contain* spermatozoa, and the younger the patient (within obvious limits) the more likely is this to be the case.

3. The retained testis, however, probably ceases to secrete normally long before old age comes on (in other words, tends to atrophy prematurely), and in some cases may never possess the power of secreting spermatozoa.

So important is this subject that the following evidence from five specimens in the London Hospital Museum may be briefly quoted:—

1 (No. 1978). Patient, an elderly man, who died of cancer of the penis.
Left testis, down in the scrotum, weighed 435 grains (rather over the average).
Right testis, situated half an inch above the internal ring, weighed 110 grains only; presented a normal appearance on section, but appeared to contain no spermatozoa.

2 (Museum, No. 1980). Age not known.
Right testis in scrotum and normal.
Left testis retained in the inguinal canal; it was about the size of the other, but had undergone general fibroid degeneration.

3 (No. 1981). An old man.
Left testis in scrotum, rather larger than normal.
Right testis in the inguinal canal, about one-third the size of the other. Whilst its lobulation can be well made out, it was of a very light colour, and had certainly undergone fatty degeneration.

4. Left testis in scrotum, and normal in size, &c.
Right testis in the abdomen, a band of the gubernaculum leading from its neighbourhood into the scrotum. *The epididymis and vas were of good size*, but the testis proper was hardly larger than a pea.

5. From a young man aged 25.
Left testis in scrotum, weighed 300 grains.
Right testis situated at external ring, weighed only 132 grains. To palpation it would have felt fairly normal, but there was reason to think it did not secrete spermatozoa, as none were found in the corresponding seminal vesicle, whilst freely present in the opposite one. Both vesicles were full of fluid.

In not one of these five cases, it will be noted, was the imperfectly-descended testis of both normal size and healthy structure; and this fact fully justifies the surgeon, when operating on a hernia complicating this condition, in removing the testis should it prove impossible to bring it down and fix it in the scrotum. But there are other reasons to be taken into consideration. The first is the special liability of the retained testis to take on malignant growth; the second is the danger of gonorrhœal or traumatic epididymitis occurring and leading to peritonitis. As regards gonorrhœa, the risk appears to be slight (though Monod and Terrillon mention two cases); but traumatic inflammation has led in several cases to fatal peritonitis. A testis retained in the canal, or at the external ring, is especially liable to contusion, or to injurious compression by the abdominal muscles. Further, should a co-existent hernia require the use of a truss, the pressure of the latter may be unbearable on the testis, or, if persisted in, may

* 'Lyon Médicale,' 1869.

† 'Arch. Gén. de Méd.' 1887.

‡ 'Guy's Hosp. Rep.' 2nd series, vol. i. p. 162. In this case a man aged 22 had both testes undescended, but had two children.

lead to orchitis. In fact, the subjects of ectopia testis are sometimes debarred from all active exercise on this account, and are liable to frequent attacks of severe pain, sickness, &c., on slight provocation.

Tubercular Disease of the Testis.

In former times a number of cases were grouped under the heading of "chronic orchitis." In Curling's great work no less than forty pages were devoted to chronic orchitis as it occurred in adults and children. But he evidently thought that many of the cases adduced were syphilitic, and at the present time we should have no doubt whatever. His illustrations and the statement that "the chief anatomical character of this form of orchitis is the presence of a peculiar yellow homogeneous and caseous substance in the body of the testicle" are conclusive. In fact for practical purposes it may be said that either tubercle or tertiary syphilis is the cause of almost all the cases of chronic orchitis. Clinically it is sometimes extremely hard to decide between the two, and even when the opportunity for dissection occurs it may be by no means easy, although the discovery of the tubercle-bacillus has much facilitated it. Many of the museum specimens of supposed "scrofulous deposit" in the testis, obtained by castration in former days, are undoubtedly examples of gummatous disease, the true nature of which has at most only been recognised during the last thirty or forty years.

Like syphilis, tubercle may affect the testicle at any age; it has been observed in infants only a few weeks old, and, on the other hand, has been known to develop as late as seventy years. Various observers estimate the frequency with which the testis is involved in tubercle of various parts of the body as from 1 in 50 to 1 in 100 cases.

As with syphilitic orchitis, and perhaps in an even higher degree, there is a tendency for tubercle to affect both testes in the same patient, and occasionally the onset is simultaneous.

A statistic obtained from various French observers on this point gives the following result:—Out of 142 cases of tubercular orchitis, in 91 the disease was bilateral, in 51 unilateral. In childhood the proportion of bilateral cases is decidedly less, and the left testis in them is most commonly affected. Jullien ascribes this fact to the earlier and more complete descent of the left gland, and to its greater exposure to injury, and in confirmation of this view points out how rarely tubercle affects a testis retained within the abdomen.

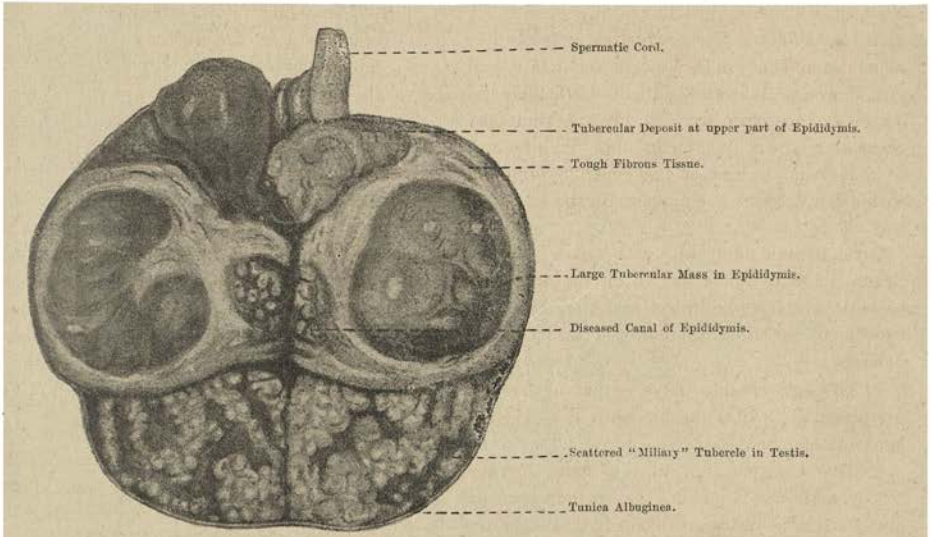
Spermatic Cord.
Tubercular Deposit at upper part of Epididymis.
Tough Fibrous Tissue.
Large Tubercular Mass in Epididymis.
Diseased Canal of Epididymis.
Scattered "Miliary" Tubercle in Testis.
Tunica Albuginea.

Fig. C.

The epididymis rather than the testis proper is undoubtedly the primary seat of tubercular deposit in the majority of cases, sometimes the globus major, at others the globus minor, being the part first affected. As shown in one of Curling's illustrations, the whole of the epididymis may be converted into a cheesy mass, whilst the testis remains apparently healthy; but in such

capable of secreting spermatozoa. A large amount of corroborative evidence has been obtained from dogs and horses, as well as from men (by Prof. Spooner, Godard, Follin, Goubaux, and others). On the other hand, we have a few cases in which retained testes in men have been proved to secrete spermatozoa. One of the clearest examples is quoted by Curling from Mr. Hutchinson (the testis examined was removed from the inguinal canal of a man aged 27), and in a case of Beigel's (of double retention) the seminal fluid was said to contain spermatozoa. Valette,* Monod and Arthraud,† and Mr. Poland‡ give confirmatory cases. The two French writers just quoted have proved that retained testes are liable to important degenerative changes, consisting in—1, arterio-sclerosis; 2, increase of fibrous tissue, starting in the tunica albuginea and body of Highmore; and 3, fatty and granular changes in the epithelium which should secrete the spermatozoa. This degeneration may occur comparatively early in life. We are now in a position to answer the question proposed with a fair amount of confidence in the following way.

Given a male adult with both testes retained in the inguinal canals, or within the abdomen, or with one testis retained and the other not capable of secreting spermatozoa into the vas deferens:—

1. The subject may have sexual desire and every sign of virility (on this point the evidence is absolutely conclusive).

2. The fluid emitted may contain spermatozoa, and the younger the patient (within obvious limits) the more likely is this to be the case.

3. The retained testis, however, probably ceases to secrete normally long before old age comes on (in other words, tends to atrophy prematurely), and in some cases may never possess the power of secreting spermatozoa.

So important is this subject that the following evidence from five specimens in the London Hospital Museum may be briefly quoted:—

1 (No. 1978). Patient, an elderly man, who died of cancer of the penis.
Left testis, down in the scrotum, weighed 435 grains (rather over the average).
Right testis, situated half an inch above the internal ring, weighed 110 grains only; presented a normal appearance on section, but appeared to contain no spermatozoa.

2 (Museum, No. 1980). Age not known.
Right testis in scrotum and normal.
Left testis retained in the inguinal canal; it was about the size of the other, but had undergone general fibroid degeneration.

3 (No. 1981). An old man.
Left testis in scrotum, rather larger than normal.
Right testis in the inguinal canal, about one-third the size of the other. Whilst its lobulation can be well made out, it was of a very light colour, and had certainly undergone fatty degeneration.

4. Left testis in scrotum, and normal in size, &c.
Right testis in the abdomen, a band of the gubernaculum leading from its neighbourhood into the scrotum. *The epididymis and vas were of good size*, but the testis proper was hardly larger than a pea.

5. From a young man aged 25.
Left testis in scrotum, weighed 300 grains.
Right testis situated at external ring, weighed only 132 grains. To palpation it would have felt fairly normal, but there was reason to think it did not secrete spermatozoa, as none were found in the corresponding seminal vesicle, whilst freely present in the opposite one. Both vesicles were full of fluid.

In not one of these five cases, it will be noted, was the imperfectly-descended testis of both normal size and healthy structure; and this fact fully justifies the surgeon, when operating on a hernia complicating this condition, in removing the testis should it prove impossible to bring it down and fix it in the scrotum. But there are other reasons to be taken into consideration. The first is the special liability of the retained testis to take on malignant growth; the second is the danger of gonorrhœal or traumatic epididymitis occurring and leading to peritonitis. As regards gonorrhœa, the risk appears to be slight (though Monod and Terrillon mention two cases); but traumatic inflammation has led in several cases to fatal peritonitis. A testis retained in the canal, or at the external ring, is especially liable to contusion, or to injurious compression by the abdominal muscles. Further, should a co-existent hernia require the use of a truss, the pressure of the latter may be unbearable on the testis, or, if persisted in, may

* 'Lyon Médicale,' 1869.

† 'Arch. Gén. de Méd.' 1887.

‡ 'Guy's Hosp. Rep.' 2nd series, vol. i. p. 162. In this case a man aged 22 had both testes undescended, but had two children.

lead to orchitis. In fact, the subjects of ectopia testis are sometimes debarred from all active exercise on this account, and are liable to frequent attacks of severe pain, sickness, &c., on slight provocation.

Tubercular Disease of the Testis.

In former times a number of cases were grouped under the heading of "chronic orchitis." In Curling's great work no less than forty pages were devoted to chronic orchitis as it occurred in adults and children. But he evidently thought that many of the cases adduced were syphilitic, and at the present time we should have no doubt whatever. His illustrations and the statement that "the chief anatomical character of this form of orchitis is the presence of a peculiar yellow homogeneous and caseous substance in the body of the testicle" are conclusive. In fact for practical purposes it may be said that either tubercle or tertiary syphilis is the cause of almost all the cases of chronic orchitis. Clinically it is sometimes extremely hard to decide between the two, and even when the opportunity for dissection occurs it may be by no means easy, although the discovery of the tubercle-bacillus has much facilitated it. Many of the museum specimens of supposed "scrofulous deposit" in the testis, obtained by castration in former days, are undoubtedly examples of gummatous disease, the true nature of which has at most only been recognised during the last thirty or forty years.

Like syphilis, tubercle may affect the testicle at any age; it has been observed in infants only a few weeks old, and, on the other hand, has been known to develop as late as seventy years. Various observers estimate the frequency with which the testis is involved in tubercle of various parts of the body as from 1 in 50 to 1 in 100 cases.

As with syphilitic orchitis, and perhaps in an even higher degree, there is a tendency for tubercle to affect both testes in the same patient, and occasionally the onset is simultaneous.

A statistic obtained from various French observers on this point gives the following result:—Out of 142 cases of tubercular orchitis, in 91 the disease was bilateral, in 51 unilateral. In childhood the proportion of bilateral cases is decidedly less, and the left testis in them is most commonly affected. Jullien ascribes this fact to the earlier and more complete descent of the left gland, and to its greater exposure to injury, and in confirmation of this view points out how rarely tubercle affects a testis retained within the abdomen.

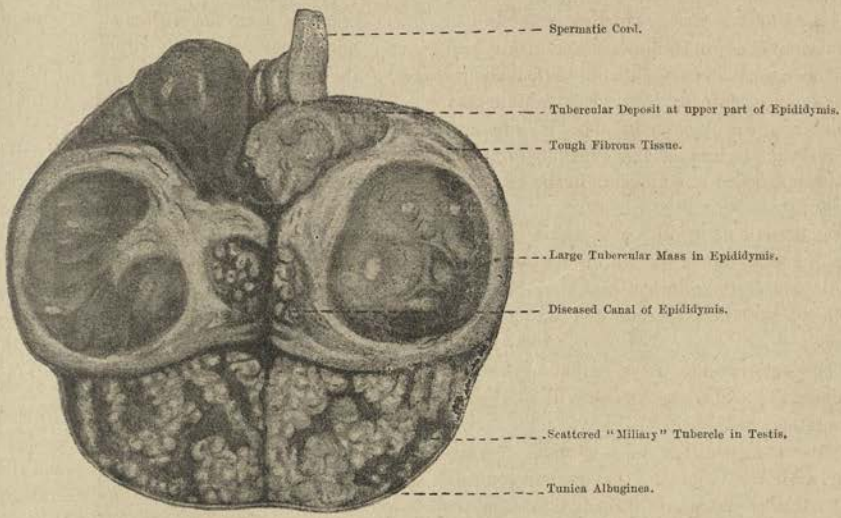
Spermatic Cord.
Tubercular Deposit at upper part of Epididymis.
Tough Fibrous Tissue.
Large Tubercular Mass in Epididymis.
Diseased Canal of Epididymis.
Scattered "Miliary" Tubercle in Testis.
Tunica Albuginea.

Fig. C.

The epididymis rather than the testis proper is undoubtedly the primary seat of tubercular deposit in the majority of cases, sometimes the globus major, at others the globus minor, being the part first affected. As shown in one of Curling's illustrations, the whole of the epididymis may be converted into a cheesy mass, whilst the testis remains apparently healthy; but in such

advanced cases it is usually found that miliary tubercles are scattered through the body of the organ.

Firm pearly nodules of tubercle in the testis may exist for long as such, though there is a tendency for them to coalesce and break down, forming abscesses, as in the case of the epididymis. Resorption or organisation into tough fibrous tissue, with perhaps calcareous degeneration, is not uncommon, and even if both testes are affected extensively the disease may be wholly arrested without the formation of sinuses. This fact is of obvious importance in connection with the question of operative interference. Miliary tubercle is seen especially towards the peripheral part of the gland, the rete testis, like the epididymis, presenting mainly cheesy deposit of "crude tubercle."

The preceding figure (Fig. C) represents a much enlarged tubercular testis obtained by castration from a young man, in whom the disease was apparently primary in that organ, for no signs of lung or other visceral tubercle could be found. It is slightly exceptional in the very large size of the main caseous deposit and the amount of fibrous tissue which surrounds it.

The small "miliary" tubercles of the testis tend to coalesce, and may produce cheesy masses similar to those met with in the epididymis. This process, as already noted, will be most marked towards the posterior part of the gland, and the caseous masses here may, as shown in the next figure (after Réclus), ultimately fuse with the deposit in the epididymis.

Fig. D. Caseous Masses of Tubercle in both Globus Major and Minor, and also along the posterior border of the Testis Proper. A few scattered tubercles are also seen in the latter.

As it is difficult to obtain sections of the very earliest stage of tubercle in the testis, so considerable doubt and discussion have prevailed as to the exact starting-point of the disease. Some authorities (amongst them Curling and Malassez) have held that it commences as an intra-tubular change, with the reservation that the wall of the tubes outside the epithelium may show the most striking lesions. That proliferation and degeneration of the epithelium in the tubules is a constant occurrence in tubercle of the testis can hardly be disputed. On the other hand, the connective tissue between the tubules sometimes shows giant-cells and fine reticulum, with masses of small cells tending to degenerate. And as in all probability tubercle of the testis is often started by the bacilli being carried thither in the blood-stream, we should expect that miliary tubercle would develop close to the fine vessels, and not necessarily within the tubules.

Some of M. Malassez's illustrations show a degenerated and perhaps shrunken tubule forming the very centre of a mass of tubercle, at the margin of which is cell-infiltration compressing and distorting the adjacent seminiferous tubes. It is then impossible to admit the intra-tubular origin of tubercle as being invariable, though it may sometimes occur. In the case of the epididymis the canal can be more easily proved to be the seat of tubercular disease than the much finer tubules of the testis.

An important complication of tubercular orchitis is invasion of the vas deferens, which may become remarkably thickened (even to the size of one's little finger). The thickening is rarely uniform along the whole length of the vas, being most marked towards the testis and the prostate. On section a creamy or yellowish fluid may be pressed out, in which tubercle bacilli can be found. After castration the diseased vas may lead to most obstinate suppuration.

In a considerable proportion of cases the tubercular infection spreads from the testes to the vesiculæ seminales, prostate, and neck of the bladder, the bacilli being conveyed with the semen. It must not, however, be assumed that this is invariably the result if the primary focus in the testis is not removed, for not very rarely the disease of the latter becomes wholly quiescent, and no infection of the prostate, &c., is ever observed. This fortunate result may occur even when both testes have been extensively affected with tubercle. The converse is also true: that the vesiculæ seminales and adjoining parts may be for long the seat of this disease without the testes becoming involved. M. Guel-

liot, who has made an exhaustive study of tubercular "vesiculitis," based upon 45 cases, found the testes and epididymis exempt in 14 of them.

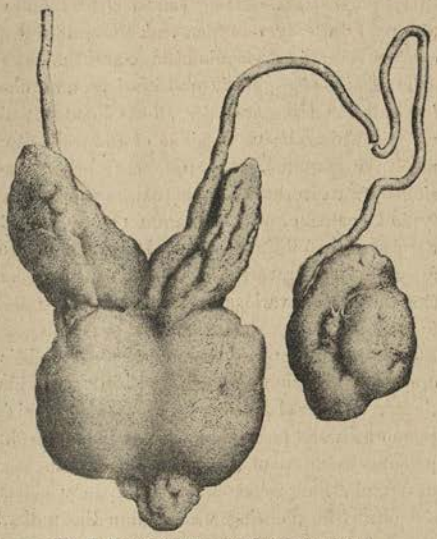

Fig. E (after Réclus). See description below.

The above figure, reduced from the original in M. Réclus's work, illustrates a point in connection with the spread of tubercular infection from the epididymis to the prostate and adjacent parts, namely, that the vas is somewhat irregularly enlarged. Towards either end, where its wall is thinner and more delicate than in the intermediate part, the swelling of the vas due to tubercular infiltration is the most decided. Occasionally the enlargement of the vas is quite lumpy, and tubercular abscesses in the course of the cord have been met with.

The case from which Fig. E was derived was a man who developed signs of tubercle in the lungs and genito-urinary system at the age of fifty-five. The epididymis and testis on both sides became extensively diseased, though neither broke down into an abscess before his death. The abscess in the prostate, however, burst into the urethra. Hæmaturia, due to ulceration of the neck of the bladder, occurred on several occasions. From this region the tubercle appeared to have spread up the left ureters (which curiously happened on this side to be double) to the left kidney. At the post-mortem the lungs were found to be studded with tubercle.

The condition of the two testicles is of special interest, as illustrating different stages of tubercular disease. On the right side (the one shown in Fig. E) there was neither inflammation of the scrotum nor any approach to abscess formation in the gland. The cavity of the tunica vaginalis was obliterated, and there was a great deal of tough fibrous tissue round the tubercle-deposit in the testis and epididymis. Half-way down the body of the latter, and projecting so that it could be felt plainly during life, was a nodule with calcareous centre, indicated in the figure. In short, the disease on this side was wholly quiescent, and had the patient lived would have probably given no further trouble. The left testicle was adherent to the scrotum, which latter was much inflamed, and the epididymis presented several masses of tubercle which were softening and on the point of breaking down into abscesses. There was a fair-sized hydrocele with recent bands of lymph.

In connection with tubercular orchitis adhesions of the gland to the scrotum, periglandular abscesses and sinuses are frequently met with. The discharge from the sinuses, which usually open at the lower end of the epididymis, is a thin purulent fluid. The tunica vaginalis may be congested, and a moderate degree of hydrocele is common; but tough adhesions or complete obliteration of the cavity are rare. Occasionally the serous membrane presents numerous small elevations, due to tubercular deposit in or just beneath it, well shown in the accompanying figure copied from Réclus's work.

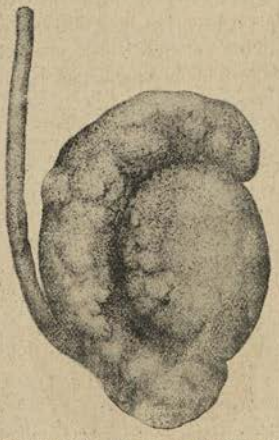

Fig. F (after Réclus). The whole Epididymis is studded with Tubercle, and its surface, as well as that of part of the Testis, is marked by elevations due to the deposit.

VII. Syphilitic Orchitis.

(Plates XLV. and XLVI., Fig. 3.)

The following characters of the syphilitic testicle may be enumerated:—

1. In the earliest stage, when isolated gummata are present, they are found in the testis proper, the epididymis being as a rule free. In tubercular disease the exact reverse holds good. The gummata are elastic but fairly firm, and may appear to be embedded in healthy tissue. Indurated masses due to old epididymitis (from gonorrhœa or stricture, &c.) are nearly always situated in the tail or globus minor.

2. In a more advanced stage, when the whole organ is affected, it is more uniformly enlarged than in tubercular disease, as a rule of stony hardness, comparatively painless, and testicular sensation is absent.

3. Both testes are frequently affected at the same time, or with an interval. Dr. Goodhart* found, in 62 autopsies on cases of tertiary syphilitic orchitis, that the disease was bilateral in no less than 38 cases. Sometimes both glands enlarge quite simultaneously, but this is the exception. Tubercular disease, it should be remembered, is also not infrequently bilateral.†

4. Whilst slight thickening of the cord is not very rare with syphilis, marked enlargement of the vas deferens is far more common in tubercular disease.

5. The effect of treatment by "specifics" in recent cases is most marked. It must be remembered that syphilitic orchitis is rather prone to relapse.

Gummata of the testicle may be either single or multiple; occasionally as many as six or seven have been observed in the one gland. As a rule, by fusion they come to form one mass, and in this respect contrast with tubercular deposit in the testis, which is frequently scattered about in many discrete nodules (see Fig. D). On section the gumma projects slightly, is usually well defined, and may be surrounded by a circle of congestion. Their consistence is decidedly firmer than that of tubercular deposit, and when they have existed some time they usually shade off into dense fibrous tissue. In their earliest stage they may be pinkish grey in colour, but soon take on the characteristic "wash-leather" yellow hue.

The exact site of the earliest change in syphilitic orchitis is difficult to ascertain with certainty, but it is probably along the tracts of connective tissue which separate the tubules, and the vessels which run in this tissue are extensively affected. Profuse cell-exudation presses on the adjacent tubules, and causes them to atrophy, their membrana propria being first thickened, the lining cells degenerate and ultimately wholly disappear. The tubules become converted into bands of fibrous tissue.

The onset of syphilitic orchitis is, as a rule, indolent and almost painless, but cases are met with in which the usual signs of acute inflammation are present. Exactly the same is occasionally seen in cases of tubercular orchitis, the typical course of which is even more indolent than the syphilitic disease. But there is no reason to separate these "acute" cases from the others, as various writers have attempted to do.

The date after infection at which syphilitic orchitis may come on varies within very wide limits. Cases have been recorded in which gummata were formed in the testis whilst the secondary eruption was still present; on the other hand, thirty or forty years may elapse from infection, during which time the patient may be apparently free from symptoms. Out of fifteen unpublished cases of tertiary orchitis the average period was seven to eight years after the primary infection, the shortest time one year, the longest twenty-five.

One marked feature of syphilitic orchitis is the even rounded enlargement of the testis which it produces. It is rare, however long the disease has lasted, for the organ to become puckered and lumpy in the way that tertiary syphilis affects the liver. The explanation lies presumably in the tough nature of the capsule of the testis, the tunica albuginea. The fact is of some importance in diagnosis; an enlarged testis with decided protuberances or bosses is more likely to be due to malignant disease (or tuberculosis) than to syphilis.

The leathery tough yellow mass which forms the characteristic gummatous deposit in the testicle is found microscopically to be composed of almost amorphous material in the centre, cells withered and starved by the deficient vascular supply, and by their mutual pressure. Sometimes neither cells nor fibrous tissue can be made out, and in any case they stain very badly. At the periphery of the gumma reticular or fibrous tissue is found, with masses of small cells which stain more distinctly, and which can often be seen to be grouped in greatest abundance round the vessels, which themselves are greatly altered, their lumen narrowed by a pro-

* 'Path. Trans.' 1877, p. 322.

† Lympho-sarcoma of the testis has the same peculiarity, but is a far rarer disease than syphilitic orchitis.

cess of endarteritis, or the whole vessel-wall thickened. In the dense fibrous tissue surrounding the gumma remains of the tubules can often be detected, with microscopic gummata (masses of small cells undergoing central caseation, but barely visible to the naked eye).

The final ending of a gumma is of considerable practical interest. Unlike those situated in the deeper organs, such as the liver, gummata of the testis are very liable to break down, causing hernia-testis or sinuses, through which much of the diseased organ may be shed.* In the case of a sailor under our observation this process had been carried out so completely that merely two stumps formed by his spermatic cords remained. His syphilis was only of a few years' duration, and practically no treatment had been adopted for it. The appearance left by this "natural castration" was most curious; a good deal of the scrotum had sloughed with the testis, and the stump-end of the cord was near the external ring on each side. It is certainly rare in these days of efficient treatment by iodide of potassium, &c., to meet with hernia-testis due to syphilis, and most of the museum specimens, such as are figured by Curling from the London Hospital Museum, are of old date.

Remembering this fact, it is very curious that until about 1860 it was denied by the French surgeons that a syphilitic testicle ever broke down or formed a "hernia." Plate XLV. Fig. 1 illustrates the formation of abscess cavities in a large syphilitic testicle.

When softening has occurred in a syphilitic testis one of three conditions may result: 1, a superficial abscess may break through the scrotum, and one or more sinuses exist without any fungus or hernia-testis; 2, a gumma in connection with the tunica albuginea may break down and part of the testis be exposed—the so-called superficial fungus (Réclus); and 3, a deep-seated gumma may burst through all its coverings, and the protruding part be composed in great part of inflamed testicular substance—the deep fungus or true hernia-testis. In all three forms the scrotal tissues around the aperture are usually much thickened. The superficial form of hernia or fungus-testis may be recovered from under treatment with preservation of the function of the gland, which is most improbable in the case of the third variety.

* "The earlier it (gumma of the testis) occurs the greater is probably the risk of suppurative inflammation." —Hutchinson, 'Syphilis,' p. 266.

The second termination of a gummatous testis consists in organisation into tough fibrous tissue, amongst which no doubt persist for very long traces of the leathery deposit. The length of time which the latter may exist unchanged is practically unlimited, and it is a noteworthy point that calcareous degeneration of a gumma is of extraordinary rarity, especially compared with old tubercular deposit.

Fatty degeneration may occur in the gummatous deposit, and occasionally crystals of cholesterine and stearic acid have been found in the centre.*

Fibroid degeneration or diffuse sclerosis of the testis has been regarded as one form of syphilitic disease independent of the formation of gummata. It may be granted that this condition is sometimes met with in the subjects of tertiary syphilis, but it is very difficult to prove that it has not been preceded by gummatous deposit, and, as already noted in many cases, microscopic examination tends to show the contrary. We may assert that a gumma of the testis is sooner or later almost always attended by the formation of tough fibrous tissue, and that with fibroid induration there is usually some evidence of the previous occurrence of a gumma. Hence it seems illogical to separate the two processes under distinct headings. In Plate XLV. Fig. 1, it will be noticed that the fibrous tissue predominates over the gummata; in the other figures the reverse is the case.

It cannot be pretended that a correct diagnosis is always possible between syphilitic and tubercular orchitis, since occasionally the most careful microscopic examination is required to decide the question. Cases where suppuration has occurred are the most difficult ones to decide. The presence of a yellowish-white slough points strongly to syphilis; of a thin free discharge from the sinus, to tubercle. The sinuses due to the latter are situated below or behind the organ; those due to breaking-down gummata may be in front, but are sometimes also below.

The Complications of Syphilitic Orchitis.—Of these the most frequent and important is (1) *inflammation of the tunica vaginalis.* A certain amount of fluid exudation (hydrocele) is very often present, and mixed with the fluid may be flakes of lymph, leading ultimately to adhesions between the two layers and sometimes to complete fusion. As shown well in Plate XLV. Fig. 5,

* Cases recorded by Nepveu and Lancereaux.

the lymph may be so mixed with blood as to form a mild degree of hæmatocele, and in these cases the walls of the serous covering may be extremely thickened and fibro-cartilaginous in consistence.* The covering of the epididymis may thus become particularly dense.

In many cases, however, there is only simple serous effusion into the tunica vaginalis, and now and then it happens that the hydrocele is so large as to require tapping, after which the surgeon recognises the syphilitic nature of the case by feeling the enlarged indolent hard testis beneath. Curling, who notes that the term *hydrosarcocele* was formerly applied to this condition, states that he rarely found the effusion to exceed two or three ounces. The frequency of this complication is variously estimated. It happened that in the examination of 23 specimens of syphilitic testis by Réclus he found only two in which the tunica vaginalis was affected. Clinical experience and the examination of museum specimens would lead one to give the proportion as very much larger.

It is not infrequent for a gumma to involve the tunica albuginea and the delicate visceral layer of the tunica vaginalis which overlies it (as shown in Plate XLV. Fig. 3, where the gummata form small projections on the surface). It is of interest to compare this fact with what is observed in the case of gummata of the brain; in the latter situation, according to Fournier and Gowers, the meninges are usually first involved, the brain-substance afterwards. With regard to the testis, we may say that there is no strong evidence that the gummatous deposit commences in its investing membranes, but that the rete testis, where the lobules are passing into the vasa afferentia, appears to be the commonest starting-point.

Another complication of syphilitic orchitis is (2) *thickening of the cord*. Clinically this is often observed to a moderate degree, but the exact nature and site of the thickening has not been sufficiently demonstrated by post-mortem examination. Cases have been described (by Hélot, Réclus, &c.) in which the vas deferens was enlarged to two or three times its normal size, a fact of much interest in connection with the diagnosis from tubercular orchitis; but this is certainly a rare condition. True gummata have been met with along the cord,† also a very rare occurrence. Tédenat describes a case in which the veins were thickened and knotty. It is possible, though not yet proved by dissection, that in syphilitic orchitis the lymphatic vessels running up the cord with the surrounding areolar tissue are swollen. Undoubtedly in some cases the lumbar glands are secondarily affected, a fact established by post-mortem examination, though not, I believe, referred to by any writer. Hutchinson ('Syphilis,' p. 268) suggests that when the vas is thickened with syphilitic deposit in the testicle a stricture of the urethra is in some cases, though not in all, responsible for the former condition.

The third complication which remains to be noticed is (3) *involvement of the epididymis*. This is frequent; for instance, Fournier noticed it 11 times in 39 cases, Réclus 8 times in 14. The various drawings in the present 'Atlas' prove how in advanced cases of gummatous disease all trace of distinction between these two parts may be lost. Nevertheless often the disease is confined to the testis proper; whether it is ever limited to the epididymis in the tertiary stage is much more doubtful.* We know, however, that during the secondary stage the globus major, or the whole of the epididymis, may be for a time the seat of painless enlargement. Taking every care to exclude a possible gonorrhœal or tubercular origin, we must fully admit the existence of this secondary epididymitis, which is usually symmetrical, and rapidly subsides under mercury. That it is at all frequent (as the writings of Diday and Dron would lead one to infer) is improbable, for one may follow up a hundred cases of secondary syphilis without observing a single undoubted example.

The co-existence of Syphilitic Disease of the Lungs and Testes.—Plate XLV. Figs. 3 and 4 furnish an interesting example of the simultaneous occurrence of gummata in these organs. The specimens were obtained accidentally from a man who was apparently in good health when seized with intestinal obstruction. Unfortunately the examination was made before the discovery of the tubercle bacillus had made the differential diagnosis a matter of greater certainty; but the deposit in the testis was of a tough leathery consistence, and no doubt at the time was entertained of the gummatous nature

* Kocher, Rollet, Virchow, and Réclus have published examples of this.

† Verneuil, Kocher, Lancereaux, Fournier.

* M. Dron claimed to have seen cases of syphilitic disease confined to the epididymis during the tertiary or late secondary stages; Rollet, Jullien, Lancereaux, and other observers have sought for it in vain.

of both this and the nodules in the lungs. There is moreover a considerable amount of evidence to confirm the view as to syphilis producing similar changes in both organs. One of the most striking cases is recorded by Dr. Pye-Smith ('Path. Trans.' 1877, p. 334). A man aged 42 years had suffered for two years from cough, loss of flesh, and pallor, later from chronic synovitis of one knee, periostitis of one ulna (with the development of a sloughing abscess over it), for which amputation had to be done; and ultimately he died of Jacksonian epilepsy. To quote Dr. Pye-Smith's words:— "The post-mortem examination showed that the diagnosis and early treatment had been entirely wrong. There was not a trace of tubercle in the lungs or the pia mater, nor in any other organ of the body, including the vertebræ and the lymph-glands, which were carefully searched. . . . With the exception of mitral disease the whole of the lesions were clearly the result of syphilis." These chiefly consisted in caries of the frontal bone, a gumma of the dura mater, scarring of the trachea and bronchi close to the bifurcation, adhesions of the pleuræ, tough fibrous degeneration in the lungs (starting from around the bronchi), with some firm cheesy nodules interspersed. Both knees showed fibroid degeneration of the cartilages, and both testes showed intertubular fibroid induration.

Lancereaux has recorded equally conclusive cases in full detail, and Hutchinson ('Syphilis,' p. 269) narrates two in which the patients were for long under treatment for supposed advanced phthisis. In both the testis on each side became affected; in one hernia-testis led to loss of most of one gland; in the other the swelling of the organ was enormous. Under mercury complete recovery, so far as was possible, ensued both as regards the testes and lungs. It should be noted that mercury succeeded here where iodide of potassium, in one case at any rate, had failed.

The co-existence of destructive syphilitic disease of the lungs and testes furnishes one more point of resemblance between tuberculosis and syphilis, and from a practical point of view is of great interest.*

* In two papers by Dr. Goodhart ('Path. Trans.' 1877, p. 313) and Dr. Moxon ('Guy's Hosp. Reports,' New Series, vol. xiii.) is to be found a most *important* collection of cases bearing on this point. As might be expected, in several there was evidence of both tertiary syphilis *and* tubercle.

IX. Tumours of the Testicle.

The new growths met with in this organ are perhaps more difficult to classify than those of any other part of the body, for the reason that mixed forms are frequently met with, *i. e.*, a testicular tumour may present the anatomical features of two, three, or even more varieties. Moreover, in no other organ is it so hard to distinguish between carcinoma and sarcoma in certain specimens. Finally, one marked variety, known as Cystic Disease, presents such ambiguous clinical and microscopical characters that its true nature must remain at present undecided.

Grouping the tumours of the testis singly, according to their order of importance, we will consider—1, Carcinoma; 2, Sarcoma; 3, Cystic Disease (including Cystic Adenoma). The two last are especially liable to contain cartilage in their structure, and sometimes myxomatous tissue also; and some writers make a separate class of these mixed or complex tumours. Much rarer varieties are the following:— 4, Pure Enchondroma; 5, Osteoma; 6, Fibroma; 7, Myoma; and 8, Dermoid Cysts. Most of these are, however, so rare as to be mere pathological curiosities.

Sarcoma and carcinoma of the testis in their malignant tendencies, and especially in the early involvement of the lymphatic glands, resemble each other closely. Hence it will be convenient, after briefly describing their separate structure, to consider their common features.

Carcinoma.—In the testis this form of malignant growth is generally of the soft or "encephaloid variety," and its minute structure shows large alveolar spaces full of cells, bounded by tracts of fibrous tissue. When cut across an abundant whitish juice is readily obtained. Owing to hæmorrhages into the tumour, or degeneration of the rapidly growing cancer, irregular cystic spaces are produced. The occurrence of hard cancer or scirrhus in connection with the testis has been denied by some, but Nepveu* collected nine cases in which the tumour was very firm on section, of no great dimensions, and in which the fibrous tissue was extremely abundant. In other words, the resemblance to scirrhus of the breast was very close. The distinction between the two forms, scirrhus and encephaloid, depends mainly upon the size of the alveoli and the relative amount of fibrous tissue. When the alveoli

* 'Mémoires de Chirurgie,' 1880.

are small or much subdivided there may be considerable difficulty in distinguishing between cancer of the testis and sarcoma, especially as the stroma of the carcinoma may be infiltrated by embryonic cells, which conceal the alveolar arrangement to some extent. Several writers, in recording cases of testicular tumour, have solved the difficulty by describing them as mixed carcinoma and sarcoma.

It can hardly be doubted that the epithelial cells filling the alveoli are originally derived from those lining the tubes, and it is certain that the testis and not the epididymis is the starting-point of the growth, although in advanced cases all distinction between the two becomes lost. Out of 34 cases examined by Kocher and Réclus, in 12 cancer was apparently confined to the testis alone.

Sarcoma.—In the majority of cases the minute structure is somewhat complex; thus small round cells are found with spindle-shaped, and occasionally with giant multi-nucleated ones. In the rare variety myxo-sarcoma, peculiar branched and oat-shaped cells are found in a mucoid basis-substance. Melanotic sarcoma has been met with in the testis, but probably always as a secondary deposit. With all forms of sarcoma nodules of cartilage and cysts are frequently present. Two interesting varieties are illustrated in this 'Atlas'; the first the hæmorrhagic sarcoma (Plate XLVIII. Fig. 3), the second lympho-sarcoma (Plate XLVII. Figs. 1 and 2).

Hæmorrhagic Sarcoma.—The vascularity of this form of tumour is quite extraordinary, and the readiness with which blood-cysts and general hæmorrhagic infiltration occur may quite obscure its true sarcomatous structure. However, by careful microscopic examination it is possible to make out not only the embryonic connective tissue cells, but also multi-nucleated ones concerned in the formation of the new vessels. It is a most curious fact that secondary deposits in the abdominal glands, &c., show the same tendency to hæmorrhagic infiltration. In the case of the testis a very close resemblance indeed to hæmatocele may be produced, and even on exploratory incision much doubt may be felt. The sarcoma will, however, be found to include the testis, whereas in a hæmatocele the latter will be separated by a tough fibrous capsule—the thickened tunica vaginalis and albuginea.

Lympho-sarcoma (Lymphadenoma of Testis).—The rare form of tumour known under the above titles is noteworthy from the fact of its tendency to involve both testes in the same patient, as well as from certain peculiarities in its structure. MM. Malassez, Monod, and Terrillon contend that it should be considered as a form of lymphadenoma, and the latter have collected some seven or eight cases in a very careful account.* But it is doubtful whether any valid reason exists for separating it from the sarcomata. Cases have occurred of invasion of both testes by tumours having other structures, although it must be admitted this is extremely rare. The case from which Plate XLVII. Figs. 1 and 2, was taken is a good instance of the involvement of the second testis by a growth having exactly the same microscopical nature—lympho-sarcoma—as that for which the first one had been excised two years before. An analogy is afforded by the cases of consecutive or simultaneous growth of cancer in both breasts. As to the structure, the French writers lay great stress upon the presence of a delicate reticulum between the individual cells, the latter being quite indistinguishable from those of round-celled sarcoma. But alveolar sarcoma possesses a still better marked reticulum, and in the case of "lymphadenoma" of the testis Monod and Terrillon admit that it cannot always be demonstrated. It may be noted that out of the seven cases collected by them in one the history is almost entirely wanting, and another was apparently an ordinary case of gummata of the testis.

In examining microscopic sections of lympho-sarcoma of the testis one is struck by the fact that the infiltration respects the tubules of the gland, at any rate for a considerable period. Perfectly normal tubules will be seen to be imbedded in masses of cells, amongst which the reticulum already referred to can often be made out. Ultimately, however, the tubules disappear in the growth.

The tunica albuginea, which at first limits the tumour and gives it an even rounded or oval shape, yields at last, and the elastic lobulated mass may attain to a very considerable size, perhaps that of a fœtal head at full term (in a case recorded by Zélat it measured six inches in long diameter).

Lympho-sarcoma is one of the most surely malignant forms of tumour of the testis, and no case has been recorded of permanent cure by castration. The lumbar glands, the liver and other abdominal viscera, the bones, and the

* 'Archives Gén. de Méd.' 1879, p. 34.

subcutaneous tissues, are the chief sites of secondary deposit. In the case (Letulle's) which most suggested a true lymphadenomatous nature there were numerous ulcers with thickened walls in the small intestine. Leukhæmia has been examined for in two or three cases, but the proportion of white corpuscles was not found to be materially increased.

After careful examination of the evidence adduced in favour of applying the term lymphadenoma to these tumours, it seems more reasonable to consider them as lympho-sarcomata, such as are met with in other organs.

The peculiar naked-eye appearances of the example figured in the 'ATLAS,' the pinkish-yellow colour, and marked lobulation, are almost exactly reproduced in an example given by Sir Astley Cooper ('On the Testis,' part ii. plate vi. fig. 1).

CYSTIC DISEASE OF THE TESTICLE.

(Plates XLIV. Fig. 3; and XLVI. Fig. 2.)

There is no disease of the testis in regard to which more doubt exists as to the exact nature and origin than this. In some cases the structure suggests a true adenoma of the gland, being composed almost entirely of simple cysts lined with cubical or columnar epithelium, and a certain amount of supporting connective or fibrous tissue. In others the structure is remarkably complex, cartilage, bone, myxomatous growth, sarcoma, or cancer being found blended with the cysts in varying quantity. The latter form is well illustrated by Plate XLVI. Fig. 2. Nor is it possible, either by clinical features or apparently by the most careful microscopical research, to decide whether a given example of cystic disease will prove to be innocent or malignant. The four cases under Sir Astley Cooper's observation were said to have done well after operation, but we do not know how long they were followed up. Perriquet, like many other observers, was struck by the resemblance in structure of the cystic testis to the cystic disease of the ovaries, and asserted the innocent nature of these tumours; but in the case he based his assertion on, the patient died shortly after the removal of the organ, from multiple deposits. Mr. De Morgan* exhibited, at the Pathological Society, a good example of general cystic disease of the testis; there was some cartilage present, but "there were no characters of cancer either in the solid structures or in the fluid contents of the cysts." Nevertheless two years after the castration the patient returned with an enormous secondary growth in front of the lumbar spine, and many others in the lungs. These secondary deposits were found to contain great numbers of cysts, mixed with cartilage and spindle-cells. Mr. Warrington Haward* has recorded a similar case in which there was a large secondary tumour in the inguinal glands, others in the pelvic and lumbar glands, and many in the lungs. The primary tumour in the left testicle was made up almost entirely of cysts, so closely grouped that there was very little intervening tissue, and this almost entirely fibrous. Here and there, however, were small nodules of cartilage and collections of epithelioid cells. In the case from which Spec. 2416 in the Hunterian collection was obtained (where multitudes of cysts are present in the testis) the patient died of internal cancer a few weeks after removal of the organ.

On the other hand, a good number of cases might be adduced which justify the favourable prognosis given by some surgeons after removal of a cystic testis. It may fairly be urged that the resemblance in structure to a simple cystic adenoma does not conclusively prove the innocent nature of the growth, since the ordinary form of rectal carcinoma cannot in microscopic sections be distinguished from those of simple adenoma of the part.

Like cystic disease of the ovary, that of the testis may start in very early life. Thus in Athol Johnstone's case† the patient was a child of less than three years when the tumour was first noticed. As a rule, early adult life is the usual age for its commencement. Out of twenty-six cases collected by Conchet‡ all but two of the patients were between twenty and forty years old; out of Sir Astley Cooper's four cases one was aged forty-nine, the other three thirty years or under.

We can find no case in which both organs were affected; in this point cystic disease of the testis differs somewhat from the cystic-adenoma of the ovaries.

When once the enlargement has commenced it is remarkably even and rounded in form, and

* 'Path. Trans.' 1867.

* 'Path. Trans.' 1877, p. 177.

† 'Path. Trans.' vii. p. 241.

‡ 'Mém. de la Soc. des Sciences Médicales de Lyon,' t. iv. p. 175.

may ultimately entirely replace the testis proper and epididymis. Usually, however, at the time of operation some traces of tubular structure are found spread out over some part of the cystic growth, and the epididymis (probably wasted and flattened) can also be detected. Testicular sensation is wholly lost in advanced cases. The increase in size is steadily progressive, like that of a cancerous or sarcomatous tumour, and may attain very great dimensions. Thus one specimen, after removal, weighed six pounds four ounces. There is but little tendency to infiltrate the scrotum, or to spread up the cord, even when the growth is irritated by puncture or passing a seton through it. This recalls the clinical fact that cystic disease of the testis has been very often mistaken for hydrocele (from the imperfect sense of fluctuation obtained), or for hæmatocele (on account of the opacity to transmitted light), and has in many cases been submitted to various attempts at cure based on these erroneous diagnoses.

The growth, from its size and weight, may cause dragging pains in the loins and varicocele. The scrotal veins are usually distended over it, and the feeling of fulness and weight may vary considerably from time to time, owing apparently to the varying amount of blood in the tumour. Sir Astley Cooper pointed out and figured the large size of the vessels running amongst the cysts, and occasionally the latter are found to contain sanguineous fluid.

In contrasting cystic disease of the testis with a purely malignant (cancerous or sarcomatous) growth of the same organ, we must emphasize the even rounded outline of the former with the frequently lobulated or bulging character of the latter (compare Plate XLVI. Fig. 1, and XLVII. Figs. 1 and 2). Their semblance to syphilitic enlargement of the gland may be very close, although the latter is usually more flattened from side to side than the organ affected with cystic disease.

It has already been noted that the remains of the testis lobules can sometimes be found thinned out over the periphery of the tumour, from which they can be peeled off; and Mr. Caird* figures a case in which both epididymis and testis were wholly distinct from the cystic tumour. In Plate XLVI. Fig. 2, the separation of the bulk of the testis is well shown.

Curling proposed the theory, which has met with support from other writers, that the disease is primarily one of the rete testis, and is due to a morbid dilatation of the ducts; and this would explain the fact that the lobules are sometimes not involved, but merely stretched over the growth. Mr. Quarry Silcock* dissected a specimen in which the formation of cysts was apparently of the nature of degeneration, and associated with the overgrowth of tough fibrous tissue at the mediastinum testis, analogous to the cases of general cystic degeneration of the breast. But this view, of course, in no way explains the malignancy of many cases, nor does it agree with the microscopical characters sometimes found. Thus in Caird's case the greater number of the cysts were lined with *tesselated squamous epithelium*, there being a Malpighian layer with characteristic "prickle-cells." Nor does it explain how in some specimens every part of the organ is replaced by the cysts. The latter may contain clear serous fluid, pultaceous gruel-like matter, colloid material, blood-clot, and frequently intra-cystic growths. Cholesterine, granular matter, and more or less altered epithelial cells are very frequent in the contents. The cysts vary in size up to that of a pigeon's egg, but no approach to the enormous size of ovarian cysts has been observed. The epithelium is usually cubical or spheroidal, and forms only one layer, but, as just noted, may be tesselated and squamous, or columnar with cilia. Occasionally in the smaller cysts the epithelium forms concentric pearls.

M. Malassez, who has carefully investigated several specimens, holds a theory differing entirely from that advocated by Curling.

According to the French observer the first stage is the formation of epithelial collections in the connective tissue outside the ducts of the testis, mucoid degeneration in the centre of these leading to the formation of cysts. Hence he applies the term myxoid epithelioma to the disease under consideration, admitting that it may become malignant by direct extension, or by causing secondary deposits. It is extremely difficult or impossible to make this explanation agree with the cases where the epithelium forms in nearly all the cysts a single even layer, still less with the undoubted presence in some of columnar ciliated cells.

Finally, a theory must be mentioned which involves the presence of rudimentary fœtal re-

* 'Edinburgh Medical Journal,' 1885.

* 'Path. Soc. Trans.' 1888.

mains in the testis as the origin of the cysts. It is true that this might well account for the complex nature of some of the specimens, and for the early age at which the disease may commence; but so many arguments can be readily adduced against it, and it is moreover so purely hypothetical, that further discussion is unnecessary.

It is possible that in the future the cases of cystic disease may be divided into two or more classes, and that we may be in a position to decide which are innocent and which malignant; but at present the most that can be said is that the more the intervening tissue contains cells of sarcomatous nature, and the more complex in structure the whole tumour, the greater is the risk of secondary deposit in the viscera.

In the following remarks the various forms of malignant tumours of the testis will be considered together. Their growth is usually rapid, and their tendency to degenerate in parts equally marked. Extensive fatty change is illustrated in Plate XLVII. Fig. 3, cystic formation in Plate XLVI. Fig. 1. Sometimes patches of mucoid or caseous material are met with in the centre of a testicular tumour, and blood extravasations are not uncommon in other forms than the hæmorrhagic sarcoma. The frequent occurrence of islands of cartilage in the sarcomata and mixed tumours has been already mentioned, but, curiously, pure enchondroma of the testis is an extremely rare disease, very few undoubted cases being on record. Nodules of fibro-cartilage are occasionally met with in an otherwise healthy epididymis, but whether they should be regarded as tumours with tendency to increase is very doubtful.

In the Royal College of Surgeons' Museum (No. 4261) is a remarkable tumour of the testis, the centre of which has been converted into porous bone. It was removed from a patient of seventy-two years, and was said to have grown for seven years. A similar osseous development is met with now and then in tumours of the breast.

The rapid growth and enormous size a malignant tumour of the testis may present need no emphasis, but it is of interest to note that some examples, which from their structure and ultimate wide dissemination must be considered highly malignant, have had at first a remarkably slow growth, although perhaps it would not be correct to speak of their "pre-cancerous stage."

The two following instances, a fair number of which could be adduced, will suffice. In Guy's Hospital Museum* is a soft carcinomatous testis, the size of a cocoa-nut, which was removed from a man aged forty by Mr. Cooper Forster. Its growth had extended through a period of three years. A man of about the same age had a large sarcoma of the testis (round and spindle-celled) removed; it had steadily grown during the last twelve years! Yet its malignancy was borne out not only by its structure, but by the patient's speedy death from secondary deposits (which could indeed be felt within the abdomen at the time of operation). These latter formed a large glandular mass (soft and brain-like in consistence) reaching up to the liver, with separate nodules in the peritoneum over the descending colon.

Growths secondary to Tumours of the Testis.

A general statement may be made about these, that whenever their minute structure deviates at all from that of the original tumour (and striking examples of exact repetition are not uncommon, *e. g.*, hæmorrhagic sarcoma, or chondro-cysto-sarcoma in lymphatic glands or lungs and testis), the secondary growths tend to be less complex; at the same time they may be softer and of greater rapidity of growth than the primary tumour.

Both carcinoma and sarcoma of the testis are usually followed by secondary deposits in the lymphatic glands, and of these latter by far the most likely ones to become involved are the group situated in front of the aorta, from the level of its bifurcation to about the second lumbar vertebra, known as the median lumbar glands. Emphasis is laid upon this point because some writers have stated that the lymphatics of the testis first traverse those glands which lie along the external and common iliac vessels. It would appear improbable that this should ever be the case, since the testis in its descent draws down its lymphatics as well as its blood-vessels, and the termination of the former must obviously be at about the same level as the origin of the spermatic arteries, *i. e.*, a little below the renal vessels.

But a certain number of cases clearly prove that the secondary deposit may occur in glands lower than the aortic or lumbar ones. In the R. C. S. Museum (No. 4237) is a specimen of

* No. 2351 [80].

cystic sarcoma of the testis obtained from a patient who died from the effects of a large secondary growth, which apparently commenced just inside the pelvis, destroying the ischium and part of the ilium. Hunter, who placed the specimen in the museum, thought that the tumour "commenced in a lymphatic gland close upon the obturator internus."

A parallel case is recorded by Mr. J. H. Targett,* in which a round-celled sarcomatous mass (secondary to a similar growth in the testis) was situated over the iliac vessels (obstructing the veins), and dipped into the pelvis. It was adherent both to the capsule of the hip-joint and to the skin of the groin, its upper limit being at the bifurcation of the common iliac artery. It is obvious that the growth must have commenced not in the lumbar but in the iliac glands.

Such cases as these, however, are quite exceptional; as a rule the secondary growth lies just in front of the aorta, and can therefore be recognised during life, even when of only moderate size. The secondary growth may obstruct either of the great vessels in this situation; this is illustrated in one of Sir A. Cooper's plates showing an immense tumour, secondary to a testis-growth, which has originated in the lymphatic glands in front of the aorta and vena cava, both of which vessels (*but especially the vena cava*) are infiltrated. The latter vessel is thrombosed at its lower end. Any secondary growth extending in front of the aorta and vena cava in all probability originates in the lumbar lymphatic glands. In a case of chondrifying sarcoma of one testis (patient only 21 years old at the time of death) a huge secondary mass covered the great vessels in front of the spine, reached down to the pelvis, and enveloped the iliac vessels and ureters, and grew into the hilum of one kidney, causing obstruction of the renal vessels and degeneration of the renal glomeruli. It was supposed to have started in connection with the kidney, but a lymphatic-gland origin is more probable.

Next in frequency to the lymphatic glands as the site of secondary growth come the liver and lungs, and hæmorrhage into the peritoneal cavity from such a tumour of the liver has in several cases been observed as an immediate cause of death. When the *inguinal* glands are invaded the testicular growth has almost always first involved the scrotum.

* 'Path. Soc. Trans.' 1890, p. 194.

Malignant tumours of the testis are rarely accompanied by marked hydrocele, though in Plate XLVI. Fig. 4 an example of this is shown (the fluid in this case being dark in colour from admixture with blood). The tunica albuginea is often somewhat thickened, and large veins run on its surface; in the later stages the growth grows through this covering and extends up the cord. Hence the rule in operating for removal of a suspected malignant tumour of the testicle is to divide the spermatic cord as high as possible.

Part ii. plate 8 of Sir A. Cooper's work shows a recurrence of cancer in the left spermatic cord following excision of the testis. The lower end has formed a large rounded mass like a testicle, and from this point up above the corresponding kidney there is one continuous huge lobulated mass, which has pressed on and wrapped round the sigmoid flexure and the ureter, and infiltrated the kidney. The rapid dissemination is largely due to the very free supply of lymphatics in the testis, which in this respect rivals the mammary glands.

During life there can rarely be much question between tubercular orchitis and tumour of the testis, but it is different with regard to syphilitic orchitis; and the following points may be noted:—

Tumours of the testicle differ from gummatous enlargement in that—

1. They may attain a far larger size, and as a rule increase more rapidly than the syphilitic testicle.

2. They are more rounded, and tend to protrude at some part, *i. e.*, they are more bossy, and do not have the even oval form (laterally compressed) that is the rule in tertiary syphilitic enlargement.

3. They may produce obliteration of the vaginal sac, or sometimes a hæmatocele (see Plate XLVI.), but they are rarely complicated by hydrocele, as is so common in syphilitic disease of the organ.

4. Lumpy thickening of the cord is only met with in the case of tumours, or perhaps in rare examples of tubercular disease. Gummata hardly ever extend along the cord into the inguinal canal.

Malignant Tumours starting in a Retained Testis.

These have already been noticed in dealing with the complications of retained testis. A few words more will suffice. Their origin will nearly

always be close to the external iliac artery; as the tumour grows it will lie in the position of a distended bladder, and may rise and fall with distension and evacuation of that viscus. As they may be remarkably elastic and apparently fluctuating to the touch, it is obvious that mistakes in diagnosis may readily occur, especially if the absence of the testis from the scrotum is not noticed. It is curious that even if the tumour be of large size the epididymis may be still recognised by palpation at one part of it.*

Malignant Tumours of the Testis in Early Life.

Plate XLVIII. Fig. 2 illustrates the occurrence, at a very early age, of a malignant tumour of the testis. This is not so rare as might be expected, as the mention of the following examples will suffice to prove:—Mr. Howard Marsh, † case of a boy in whom the tumour was first noticed at the age of under two years; Mr. T. Holmes,‡ two cases under four years; Mr. Langstaff, ten months; Sir W. Blizard, two years and a half; Mr. Earle, one year.

In the College of Surgeons' Museum§ is perhaps the youngest example on record, the testis being removed for malignant disease when the patient was only seven months old. Mr. H. Ludlow found, in compiling statistics of malignant disease of the testicle, that one in ten occurred during the first five years. The most liable period, however, would appear to be precisely that during which "cystic disease" prevails, *i. e.*, from twenty to forty years. It may be noted that the kidneys and supra-renal bodies, developed in close proximity to the testes, have also been observed in many cases to become the seat of malignant growths at a very early age.

There is the same terrible certainty of a fatal issue as when the tumour starts in later life, whether removal of the primary growth be effected or not. And the secondary deposits in both cases are most liable to occur in the abdominal glands, the lungs, occasionally the brain, &c. Formerly these tumours of the testis were all described as carcinoma; we know now that many are of the nature of round-celled sarcoma, but the distinction is by no means easy to make in individual cases, and is of purely histological importance.

* Dr. Mahomed, 'Path. Trans.' 1883, p. 182.
† 'Path. Soc. Trans.' 1875, p. 140.
‡ Ibid. vols. xi. and xii. § No. 2401.

X. Hæmatocele.

It does not seem desirable to abandon this term for the one proposed by Réclus and other French writers of "pachyvaginalitis." Apart from the awkward nature of the latter word, it implies an inflammatory origin to these collections of blood and lymph which is far from being proved in all cases, and it can only be applied where the disease is confined to the cavity of the vaginal sac. A true hæmatocele or blood-cyst may be met with not only in this position, but also in the cord, the scrotal tissues, or in connection with the epididymis. Some of the very largest specimens have no connection with the tunica vaginalis; for example, in the Royal College of Surgeons' Museum* is a huge blood-cyst with the characteristic thick walls and chocolate-coloured contents, which, with another large cyst, lay wholly above the apparently healthy testicle. The specimen was obtained by Mr. Rivington from a man aged 57, who gave the history of repeated traumatism sustained long previously to the operation, No. 4292 in the same collection shows a thick-walled hæmatocele of the cord situated between a large hernial sac above and a distended tunica vaginalis below, and other examples of hæmatocele of the cord are not very rare.

Traumatic blood-cysts in the scrotum below the tunica vaginalis (and sometimes communicating with the latter) have also been met with, though as a rule the extravasation is soon absorbed in this situation. A hæmatocele may occur alone, or as a complication of disease of the testis, &c.; thus with syphilitic orchitis, malignant tumour, and even with tubercular disease of the epididymis, examples of typical hæmatocele have been recorded. In a large proportion of the cases either a direct traumatism or a vigorous straining effort have been responsible for the first onset of the hæmatocele, or the conversion into it of a previously existing hydrocele. Sometimes it has been due to tapping the latter.

Fig. G illustrates the main features of an uncomplicated hæmatocele which has existed for a long time. The sac-wall becomes of great density and thickness from the deposit of layers of clot and organising lymph, very much in the manner of an aneurism undergoing cure. The wall of the tunica vaginalis in the case figured was half an inch in section at the lower part; in

* Spec. 4299.

a specimen obtained by Sir W. Blizard* it was nearly three times this thickness. The even lamination is sometimes almost as striking as that of a hydatid cyst wall. Calcification and even the production of true bony plates are occasionally met with. The vessels running in the walls of an old hæmatocele may present marked dilatations resembling small aneurisms, and as many of them are of new formation they are specially predisposed to recurrent rupture. The contents of the sac vary much in consistence and colour, the variations depending on the length of time the fluid has remained in the cavity and the occurrence of recent hæmorrhage. Often it consists of a thick syrupy brown fluid

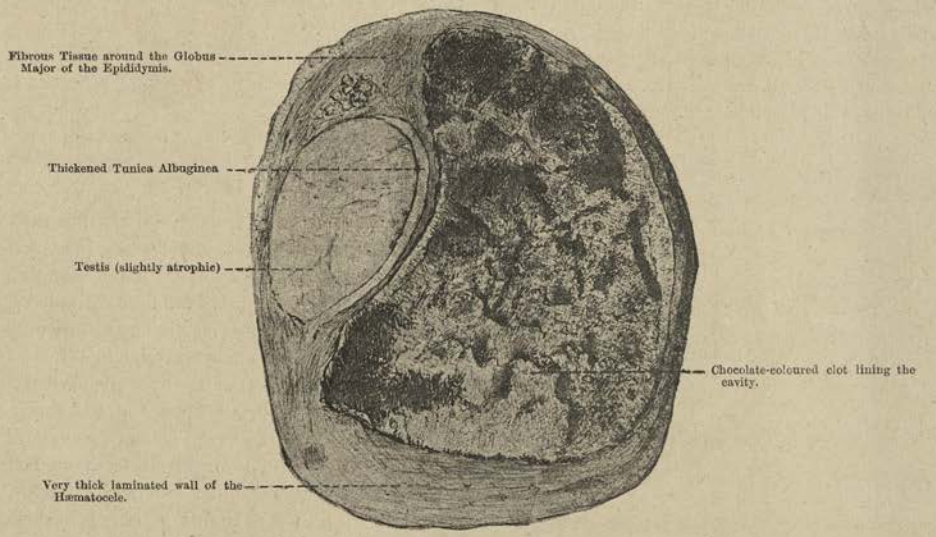
Fibrous Tissue around the Globus Major of the Epididymis.
Thickened Tunica Albuginea
Testis (slightly atrophic)
Chocolate-coloured clot lining the cavity.
Very thick laminated wall of the Hæmatocele.

FIG. G. Vertical Section of a Hæmatocele.

with flakes of cholesterine, and lining the wall masses of chocolate-coloured material, which can be peeled off from the denser and less dark laminæ beneath. Sometimes rounded or irregular lumps of clot are found floating in the fluid, and these are supposed occasionally to calcify. The plates of calcareous matter in the wall resemble closely those in a large artery due to atheroma.

The usual position of the testis is that shown in Fig. G, namely, about the centre of the posterior wall of the hæmatocele. It will be noticed how slightly it projects into the cavity, and in some specimens this projection is even less marked. The testis and epididymis are usually

* Museum R.C.S. No. 4157.

embedded in tough fibrous tissue, and after a time undergo atrophy. In a few cases of old hæmatocele careful dissection has revealed only mere traces of either.

The progress of a hæmatocele is as a rule in the direction of steady increase in size and weight, though some cases remain stationary after a time, and rarely resorption takes place, leaving only a collection of blood-pigment and cholesterine in the centre of a thick mass of fibrous tissue. Inflammation and suppuration, due to traumatism (such as tapping and the entrance of micro-organisms), is an occasional result.

It may be noted that the subjects of hæmatocele are usually elderly men with more or less degeneration of the arterial system. Less than five per cent. of the cases occur in individuals under twenty years of age.

XI. Atrophy of the Testis.

Atrophy of the testis occurs in one of two forms. In the first, resulting usually from gummatous (or much more rarely from tubercular) orchitis, the organ is hard to the touch, perhaps lumpy; the tunica albuginea is thickened and strongly adherent to the fibrous tissue within, perhaps puckered like the capsule of a cirrhotic liver. The section of the testis cuts firmly; there may be tough old caseous matter, and a good deal of fibrous tissue. If remains of the

seminal tubes are still present they are usually intimately blended with the connective tissue freely present.

In the second form (such as may result from orchitis due to mumps, traumatism, and sometimes from tubercular or gonorrhœal epididymitis) the organ is wasted but soft, and seems too small for its tunics, which are neither thickened nor puckered. On section the testis is paler and less vascular than usual; the tubules may perhaps be unravelled from the fibrous tissue, which is slightly and uniformly increased in amount. Hence the tubules, which are themselves diminished in size, stand out far less than normal, and microscopic examination proves that whilst mere traces of their epithelium remain their internal coat is much thickened. In short, the first form of atrophy seems to depend upon an intertubular, the second to a parenchymatous or intra-tubular, sclerosis and degeneration.

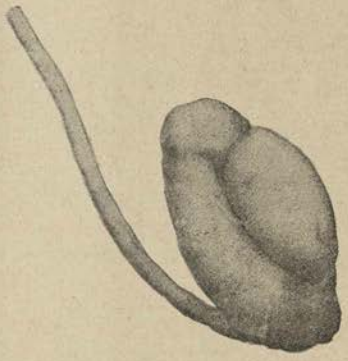

Fig. H (after Réclus). Atrophy of the Testis Proper, the Epididymis remaining of normal size.

The accompanying figure represents atrophy of the testis proper, resulting from orchitis due to mumps. The latter had occurred when the patient was aged seventeen, and affected both testes. He died at the age of forty-three of sarcoma of the left testis (the one figured being the right). On section of the atrophied gland to the naked eye the testis tubules could hardly be made out amidst the opaline connective tissue. Under the microscope the walls of the tubules were found to have undergone fibroid degeneration, and their epithelium to have almost wholly disappeared.

A more extreme example of atrophy is figured below, from a case attributed to old traumatic orchitis. The sclerosis has caused marked puckering of the surface of both epididymis and testis.



Fig. I (after Réclus). Atrophy of the Testis after Traumatic Orchitis. Both Testis and Epididymis are seen to be somewhat lumpy.

Orchitis due to the two causes here illustrated (traumatism and mumps) would appear to be more often followed by atrophy of the gland than that due to any other. Some of the most extreme examples of atrophy, however, are met with in connection with general emaciation due to advanced tuberculosis. Its relation to varicocele, hæmatocele, &c., has been already alluded to, and it may be noted that it sometimes follows gonorrhœal epididymitis, with blocking of the tortuous duct traversing the globus minor. In fact, considering how frequent it is to find a hard persistent nodule in this position of considerable size, which must prevent the passage of semen, long after gonorrhœal epididymitis has occurred, it is surprising that atrophy is not more common from this cause. But even complete division of the vas deferens, as experiment on the lower animals and surgical accidents in the human subject have proved, is not necessarily followed by atrophy of the testis.

FINIS.

A TREATISE

ON THE

PATHOLOGY, DIAGNOSIS, AND TREATMENT

OF

NEUROMA.

BY

ROBERT W. SMITH, M.D., T.C.D., M.R.I.A.,

Fellow of the Royal College of Surgeons in Ireland: Lecturer on Surgery at the Richmond Hospital School of Medicine; Surgeon to the Talbot Dispensary, House of Industry, and to the Lunatic Asylum at Island-Bridge; Secretary to the Pathological Society of Dublin; Fellow of the Royal Medico-Chirurgical Society of London.

"L'anatomie pathologique des nerfs, est encore à faire."—CRUVEILHIER.

London:

THE NEW SYDENHAM SOCIETY.

1898.

PREFATORY NOTE.

THIS work was originally issued in the form of an edition limited to a little over two hundred copies, in 1849, and was hence written fifty years ago. So carefully recorded are its observations, however, that their value is as great as at the time of original publication, and the reader will be struck by the practical absence of anything that seems antiquated. That the work appeared just before the general adoption of anæsthesia in operations is illustrated by the directions given on page 34. There is moreover no mention of the word sarcoma throughout the book. It has been found necessary to reduce the size of the plates by one-half.

February, 1898.

A TREATISE

ON

THE PATHOLOGY, DIAGNOSIS, AND TREATMENT

OF

NEUROMA.

AMONG the tumours, so numerous and so diversified, which afflict the human body, there are few more remarkable, or more obscure as to their origin, than those which form the subject of the present memoir.

The term Neuroma, introduced into medical nomenclature by M. Odier of Geneva,* has been employed to designate a tumour connected with a nerve. The disease, however, was known long before the name which it now possesses was assigned to it; and it may, I think, be inferred from the writings of Morgagni† and Boerhaave,‡ that these authors were not unacquainted with this remarkable form of tumour, although Cheselden§ appears to have been the first to give a distinct account of the disease. The observations, however, of this celebrated surgeon refer to but one species of the affection, viz., the cystic, a variety by no means as frequent as the solid form of the disease.

The descriptions which have been transmitted to us by Hippocrates and Galen are not sufficiently precise to justify us in concluding that the tumours which they have termed "Ganglions" were identical with those which at the present day are understood by the term "Neuroma"; and the same remark may be applied to the account of the "Node" of Jean de Vigo‖ and Ambrose Paré.¶

In modern times the disease has been carefully studied by several of the continental writers, to whose observations I shall have frequent occasion to refer in the following pages.

Pathologists have endeavoured to classify neuromatous tumours. Barkow* has arranged them into local and general, according as they occupy one nerve, and exist alone, or are formed in numbers, and are connected with several of the nervous trunks. This division is, however, founded upon an accidental circumstance, and establishes no distinction, either as regards the structure or causes of neuromatous tumours.

Knoblauch† has divided them into those which are the consequence of a morbid process, and those which result from an original vice of conformation: "Dividimus, igitur, nervorum intumescentias in duas magnas classes, quarum altera eos nervorum tumores complectitur, qui ex statû pathologico oriunter; altera eos in se continet, qui vitia primæ conformationis habendi et vera ganglia sunt." I shall have occasion to revert to this arrangement hereafter, when detailing some of the remarkable cases of neuroma which have fallen under my own observation.

It is, however, sufficient for practical purposes to state that neuromatous tumours are either of spontaneous origin, or the result of wounds or other injuries of the nerves; among the latter may be included the tumours which form upon the extremities of nerves divided in amputations. In the idiopathic variety of the disease there is in general but a single tumour, which, whether it be solid or composed of a cyst filled with fluid, is usually painful; but when several such tumours exist, either upon the same or upon different nerves, they are, in most instances, solid and free from pain. The traumatic varieties of Neuroma, whether solid or fluid, are, in almost all cases, the source of severe suffering.

* Manuel de Méd. Pratique; 8vo. 1803.
† De Sedibus et Causis Morb. Ep., 50.
‡ Prælect. Acad. de Morb. Nervorum, t. i.; 1762.
§ Anatomy of the Human Body, ed. 5, plate xxviii.; 1740.
‖ Practic. in Arte Chirurg.; 1512.
¶ Œuvres d'Ambrose Paré; 1633.

* Bemerkungen iiber die Nervensanschwellungen, in Nov. Act. Physic. Med., vol. xiv., part 2; Bonn, 1829.
† De Neuromate et Gangliis Accessoriis Veris; Francofurti ad Mœnum, 1843.

General Characters and Symptoms of Idiopathic Neuroma.

Neuromatous tumours are usually of an oval or oblong form, their long axis corresponding with the direction of the trunk of the nerve to which they are connected. They vary considerably in size, being sometimes smaller than a grain of wheat,* while in other instances their dimensions equal or even exceed those of a large melon†; and between these two extremes every variety of size occurs. There may be either one or several upon the same nervous trunk, and they are occasionally found existing simultaneously upon all the spinal nerves. They are comparatively rare in the ganglionic system.

In general they are solid throughout, but in some instances are composed of a cyst filled with fluid. They are of slow growth, but continue steadily to enlarge, although years may elapse before they attain such a size as to render them the source of inconvenience; they are moveable in the transverse direction, but not in the course of the trunk of the nerve upon which they are seated.

Even when they have reached a very considerable size they do not contract any adhesion to the investing integument, unless from their situation they are exposed to continued pressure; the skin is not discoloured, nor, unless the tumour be of unusual magnitude, do we ever see tortuous and dilated veins ramifying beneath it; they are not prone to attacks of inflammation, nor have I ever seen them suppurate, or known their removal by absorption. Descot, however, states that in one instance both the pain and the tumour spontaneously disappeared.‡

The pain accompanying neuroma has always been considered as one of the most important characteristics of the disease. When the tumours exist in great numbers, they are, in the majority of cases, the source of little or no uneasiness to the patient; but the solitary neuroma is in general the seat of agonizing torture, the pain darting along the trunk and branches of the nerve with all the suddenness of an electric shock.

"In some instances the pain is not severe when the parts are kept at rest, but in most a tickling or tingling, creeping, or numbing sensation, or a combination of these, is felt in parts near or below the tumour; and in many a most excruciating pain, independent of, but much increased by pressure, exacerbated at intervals, is complained of at a distance from it, but in the direction of the trunk or branches of the nerve affected. The powers of sensation and motion are, however, seldom impaired; but motion aggravates or brings on the pain; and prickling, accompanied or alternated with numbness, is felt in the limbs, and severe pains dart in the direction of the nervous branches."*

In some instances the pain is continued, but is subject to exacerbations whenever the tumour is pressed upon or accidentally touched; but in other examples of the disease paroxysms of the most severe character will occur without any apparent exciting cause, and continue during a variable period of time. It has been observed that, during this paroxysmal period, the tumour appears to be in a state of erethism, and manifests the most acute sensibility.†

Frequently no other cause can be assigned for the occurrence of the paroxysms than mental emotions, or variations in the state of the atmosphere; and during dry weather the pain has been observed to cease entirely.‡

It not unfrequently happens that the pain, which at first occurred only in paroxysms, at length becomes continued, torturing the patient both by day and night.

"Simul dolores antea in paroxysmorum tantum modum se ostendentes permanent, ut ægroto ne minimam quidem quietem præbeant, non solum diu sed etiam noctu eum crucient, somnum auferant eumque miserum reddant."§

It has been stated by Aronssohn and others, as a pathognomonic sign of neuroma, that when the trunk of the nerve is compressed above the tumour the pain ceases, and that the tumour, which had previously been acutely sensible, can then be touched without any uneasiness being caused.‖ It is also worthy of notice that, in the majority of cases of idiopathic neuroma, the pain is limited to the parts below the tumour. In the traumatic form of the disease, however, it may extend both upwards and downwards, darting along the trunk of the nerve towards the centre of the nervous system.

Several examples are upon record in which neuroma has occasioned epileptic convulsions, which have been permanently cured by the excision of

* Vide Plate VI., fig. 5.
† Vide Plate II.
‡ Dissertation sur les Affections locales des Nerfs; 1825.

* Copland's Dictionary of Practical Medicine, p. 872.
† Aronssohn sur les Tumeurs developpées dans les Nerfs; Strasb., 1832. Hasler, Dissertatio de Neuromate; Turic., 1835.
‡ Baumeister, Dissertatio de Tumoribus Nervorum; Bonn, 1835.
§ Knoblauch, Op. cit., p. 11.
‖ Op. cit., p. 30.

the tumour.* The following case, recorded by Knoblauch,† as having occurred in the practice of Professor Chelius, affords a good example of the solitary, painful, idiopathic neuroma.

A female, twenty-seven years of age, consulted Professor Chelius in September, 1837, respecting a tumour in the popliteal space, and gave the following history of the origin and progress of the disease:—

In 1824, when she was about fourteen years of age, she began to suffer occasionally from pain of a spasmodic character in the right leg, to which, however, she paid but little attention, as the motions of the limb were in no respect interfered with. When she had attained the age of seventeen she engaged in an occupation which required constant exertion, and it frequently happened that during an entire day she was unable to sit down even for an hour.

From this period the spasmodic pain in the leg occurred much more frequently, and was always attended with a sense of fatigue in the foot; it recurred every third or fourth hour, continued throughout the evening, and frequently at night awoke her from sleep. At length her sufferings became so constant and so severe, that she consulted a physician, by whose advice one moxa was applied to the leg, and a second directly above the popliteal space, in which region there was at this period no tumour discovered. When the sloughs thus formed had separated, the suppurating surfaces were dressed with irritating applications for six weeks. A course of chalybeate waters was then directed, which not only exercised a beneficial influence upon the general health of the patient, but likewise caused a diminution of the local pain; but when she returned home, and resumed her former occupation, the pain recurred with all its former severity; and whenever the cicatrix which marked the situation of the moxa above the popliteal space was touched, dreadful suffering was experienced throughout the entire limb.

Shortly afterwards, having married, and aborted at an early period of her pregnancy, she suffered a great increase of pain. She was now advised by another practitioner whom she consulted, to take the oil of turpentine; she did so for a considerable time, but no benefit resulted from its use.

Having become pregnant a second time, the pain in the foot, between the fourth and fifth month of pregnancy, increased to such a degree as to be scarcely endurable; it continued with greater or less intensity during the whole period of utero-gestation; her general health, however, during all this time, remained unaffected.

In 1835 she consulted an eminent physician, who, during his examination of the limb, discovered a tumour near the superior portion of the popliteal space, which had escaped the observation of all her former attendants, and to the existence of which she had never drawn attention, inasmuch as, singular to say, pressure upon it never gave her any uneasiness.

Various internal remedies and local applications were now made use of, but without being productive of the slightest benefit; the pain in the foot continued unmitigated, and was subject to violent exacerbation at the approach of each menstrual period.

The severe measure of amputation was now proposed to the patient, who declared, however, that, rather than submit to it, she would prefer death. She placed herself under the care of a homœopathist, but did not derive any benefit from the treatment pursued. Her local sufferings increased; she had no respite from them by day, and but little during the night; she never slept till long after midnight, and then only obtained, in consequence of exhaustion, an unquiet and broken slumber. Occasionally paroxysms of pain occurred, of such severity as to induce convulsions, and unseat for a short period the patient's reason.

In the winter of 1836 she again sought for professional assistance, her sufferings having continued without intermission, and with scarcely any alleviation. The tumour, which was now as large as a pine-apple, was treated with medicated fomentations during a period of eleven weeks, and then punctured in two places; poultices were then applied for a fortnight longer, at the end of which time some purulent matter was discharged, but the size of the tumour remained unaltered, and the sufferings of the patient unalleviated.

In September, 1837, she repaired to Heidelberg to consult Professor Chelius. She was emaciated and exhausted by want of rest and the violence of the continued pain; her pulse was quickened, and in the evenings she had slight febrile exacerbations.

The tumour now extended from the upper part of the popliteal space to near the centre of the back of the thigh; it was of an oblong form, equally solid to the feel and elastic throughout. The integuments covering it were healthy and moveable, except at the circumference of the

* Portal, Cours d'Anatomie Méd., t. iv., p. 247.
† Op. cit., 17, *et seq.*

cicatrices where the punctures had been made. Pressure upon the tumour caused no uneasiness, but when any—even the most gentle—effort was made to draw it downwards, or to push it upwards, the patient was at once seized with intolerable pain, which darted like an electric shock throughout the entire extremity. The limb was slightly flexed, and any attempt to extend it produced dreadful agony.

Chelius, having recognized the tumour as a neuroma connected with the sciatic nerve, and deeming its extirpation dangerous, proposed to the patient to submit to the removal of the limb. She, now anxious to be by any means, however severe, freed from her intolerable sufferings, at once consented. The operation was performed upon the 23rd of September, 1837; the wound healed by the first intention, and the patient, now exempt from all uneasiness, left Heidelberg upon the 24th of October.

The examination of the amputated limb proved the correctness of the diagnosis which had been formed. The tumour,* which was of about the size of a pine-apple, was found to be a neuroma connected with the sciatic nerve, which, along with the femoral artery and vein, corresponded to its anterior or deep surface; and from its lower extremity proceeded the posterior tibial nerve and several small branches, destined for the gastrocnemius muscle and the integuments, but the peroneal and communicating or external saphenus arose above the tumour, and ran along its external surface, the fibres of the peroneal being separated from each other where the nerve crossed the middle third of the tumour, to which it was connected by a loose cellular structure.

The tumour, although everywhere solid, was not of the same consistence throughout; in some parts, especially below, the feeling of elasticity was so great, that it might readily have been supposed that in these situations fluid existed; other portions possessed nearly the firmness of cartilage.

The investments of the tumour consisted of an external capsule, seemingly formed by the condensation of the surrounding cellular tissue, and beneath this of a membranous expansion continuous with and apparently composed of the distended sheath of the sciatic nerve.

A section of the morbid growth exhibited a lobulated structure, of different degrees of consistence, but nowhere presenting any of the characters of malignant disease.

* Vide Plate XIII., fig. 9.

Malignant tumours are occasionally found involving the trunks of the nerves, but the true neuroma is, I believe, a disease of the benign character. Bayle, Cayol,* and other eminent pathologists, have stated that it is identical with scirrhus; but the following considerations induce me to agree with those who maintain the opposite opinion:—

1. To whatever size the tumour may attain, or however long it may have existed, we do not find that it affects the surrounding tissues otherwise than by its pressure; it never converts them into a texture similar to itself; the form alone of the nervous trunk with which it is connected is altered, its component fibres being separated from each other and flattened; it contracts no intimate adhesion either to the contiguous textures or to the integuments, which can be freely moved even over the largest tumours; nor does it affect the lymphatic glands, either in the vicinity or at a distance.

2. It does not exert that specific and destructive influence upon the constitution which forms so remarkable and so constant a feature in the history of cancer; it is true that the general health of the patient is frequently impaired, but this is to be ascribed in such cases to the continued suffering which he endures, and not to any specific reaction upon his system.

3. The disease does not recur after the removal of the tumour, either in the part originally affected or elsewhere. Whether the tumour (when of spontaneous origin) has been extirpated, or the operation of amputation performed, the patient has been in every instance permanently relieved from suffering. How different is this result from the melancholy consequences of operations undertaken for the cure of malignant disease.

The case recorded by Liston† does not tend to establish the malignant nature of neuroma; it was an instance of a medullary tumour in the popliteal space, involving the posterior tibial nerve; but, as remarked by Knoblauch,‡ "has formationes heterologas neuromatum nomine appellari nolimus, quum nihil cum istis commune habeant et imprimis quoad medendi rationis successum tantopere ab iis differant. Dentur his nomina ipsis propria, ut etiam Strukius§ casum a se observatum fungum medullarem nervi mediani nominat."

* Dict. des Sciences Méd., t. iii.
† Practical Surgery, p. 294.
‡ Op. cit., p. 22.
§ Dissert. sistens observ. Fung. Medull. Nervi Mediani; Gryphiæ, 1836.

4. The character of the pain which accompanies neuroma is totally different from that which distinguishes cancer.

5. The structure of neuroma, as revealed by the microscope, presents none of the characters which are supposed by modern pathologists to be diagnostic of malignant disease.

Neuroma is generally confined to one nerve, and exists as a single tumour; but in some instances almost every nervous trunk belonging to the cerebro-spinal system is found studded with numerous tumours, as in the two remarkable instances which I shall shortly have occasion to describe.

In the latter case the tumours are generally free from pain, and are principally inconvenient from their size and number; but in the former and more common variety of the affection there is usually severe pain complained of, and this is equally the case whether the neuroma be a solid tumour, or merely a cyst containing fluid, as in the following instance, which I brought under the notice of the members of the Pathological Society of Dublin in 1840,* and which was subsequently submitted to their consideration in a more detailed form by my friend, Mr. Adams,† who gave the following account of the case:—

"Owen Nolan, aged 40, was admitted into the Richmond Hospital in October, 1836, to be treated for an old stricture and a sarcocele. He had been a dragoon in the British army, but was now out of the service, and acted as a stable-servant.

"While in hospital he directed my attention to a tumour of an oblong form, about an inch and a half in length, situated a little above the internal condyle of the left humerus. It appeared to be an enlargement of the ulnar nerve, which, in the situation of the swelling, seemed to have acquired four times its natural size. This tumour appeared to one feeling it as if it were solid; it was moveable in the transverse direction only.

"This information was obtained at the expense of some suffering to the patient; he dreaded any one handling the swelling, or anything even touching it, because, at the moment of such examination, and even for a quarter of an hour afterwards, a stinging pain was felt all along the course of the branches of the ulnar nerve. The pain was most severely felt in the fleshy portion of the palm, at the inner side, where the ulnar nerve divides and its branches sink deep into the hand, as also along the side of the little finger, and the ulnar edge of the ring finger.

"It is, however, to be observed that the patient never suffered any pain in the tumour, except when it was suddenly touched or pressed upon, and, from the situation of the disease, these were accidents which seldom occurred.

"Independently of this affection and the disease Nolan was then under treatment for in the hospital, it is to be remarked that his general health had suffered much while on service in India. He stated that, while on duty, he had been thrown from his horse, and of this fall he still bore on his person the sad memorial, in a dislocation of the bones of his left forearm backwards at the elbow-joint, which had never been reduced. So that he neither sought for any active treatment to be applied to accomplish the removal of the neuroma, nor did we, under the circumstances, think it right to propose any to him.

"When he was somewhat relieved of the sarcocele and stricture, he left the Richmond Hospital, and in the latter part of the year, 1839 was admitted into the Hardwicke Hospital for fever, of which he died.

"The neuroma was found to consist of a swelling, about one inch and a half long, of the ulnar nerve,* in that part of its course where it is situated near and above the internal condyle of the humerus. This swelling, when cut into, proved to be a cyst containing a transparent, albuminous fluid; the cyst was formed within the neurilemma; the filaments of the nerve, separated from each other, were spread out over the surface of the cyst, and were reunited into a trunk below the tumour."

Cheselden's case was remarkably similar to the preceding; he describes it as "a tumour formed in the centre of the cubital nerve, a little above the bend of the elbow; it was of the cystic kind, but contained a transparent jelly. The filaments of the nerve were divided, and ran over its surface.† The tumour occasioned a great numbness in all the parts that nerve leads to, and excessive pain upon the least touch or motion."‡ An example of cystic neuroma of the ulnar nerve has also been recorded by M. Bauchéne, who presented the specimen to the Society of the School of Medicine of Paris.

As the solid variety of neuroma is not in every case painful, so likewise, in some instances, the fluid, or, to use the term which has been employed by Cheselden, the cystic form of the disease, is the source of no uneasiness whatever to the

* Dublin Journal, vol. xix., p. 116.
† Dublin Quarterly Journal, New Series, vol. v., p. 549.

* Vide Plate XIII., fig. 6.
† Vide Plate XIII., fig. 8.
‡ Op. cit.

patient, as in the following remarkable case recorded by M. Bertrand :—

"La tumeur était située à la partie supérieure et interne du bras gauche, elle avait la volume d'un gros œuf d'oie, lisse, arrondie, sans changement de couleur à la peau, rénitente, élastique, avec fluctuation très obscure. J'incise la peau, le tissue cellulaire sous-cutané, et l'aponévrose brachiale suivant le diamètre longitudinal de la tumeur; je plonge un bistouri dans celle-ci, et il s'en élance un flot de sérosité sanguinolente mêlée à des caillots de sang. Notre première idée fut celle d'un anevrysme; je disséquai attentivement, et je vis que c'était un kyste développé dans l'epaisseur du nerf médian. Je crus d'abord que le nerf, interrompu dans son trajet, se continuait en haut et en bas avec les extrémités de la tumeur; mais une dissection minutieuse me démontra la disposition suivante.

"Ayant complètement vidé le kyste du liquide qu'il contenait, j'en remplis la cavité avec du coton, de manière à lui rendre le même volume; je fixai ensuite le tout sur une table au moyen d'épingles enfoncées dans les bouts supérieure et inférieure du nerf. Le névrilème, l'un et l'autre de ces bouts, se continuait sans interruption sur le kyste, de manière à lui former une première tunique complète. Au-dessous se trouvait une couche de tissu cellulaire très mince. Au-dessous de cette couche et du côté du centre du membre s'apercevaient quatre cordons amincis et comme rubanés d'une demi-ligne de largeur, divergents, et longeant toute l'étendue du kyste; un autre faisceau nerveux un peu plus gros s'épanouissait en une membrane si ténue, qu'il me fut impossible d'en suivre les fibres; enfin venait une membrane muqueuse semblable à celle qui revêt l'intérieure de tous les kystes.

"Nous voyons que ce kyste s'est formé dans le tissue cellulaire unissant les cordons nerveux qui, par leur assemblage, constituent le corps du nerf; qu'en se développant, il s'est porté vers les parties les moins résistantes, et par conséquent vers la peau, où il faisait une saillie lisse et arrondie; que du côté de l'humérus il était un peu aplati, là aussi se trouvaient les cordons nerveux du nerf médian, enveloppés chacun de leur névrilème particulier; que de ces cordons, les uns étaient très distincts mais seulement aplatis et comme rubanés, et d'autres au contraire, étalés en une membrane qu'il était impossible de suivre par la dissection; qu'un pouce au-dessus du kyste ces cordons s'écartaient l'un de l'autre pour se porter sur lui en continuant leur degré de divergence, et se réunissaient un pouce au-dessous de son extrémité inférieure pour reconstituer le corps du nerf; ainsi, dans toute son étendue, le nerf éparpillé avait la forme de deux cônes adossés par leur base, qui se trouvait à la partie moyenne de la tumeur; toutes ces parties étaient recouvertes par une couche de tissu cellulaire sur laquelle était ajouté le névrilème commun.

"Ce kyste, comprimant ainsi le nerf, était situé en dedans et en arrière de l'artère et des veines brachiales. Il n'avait jamais fait éprouver la moindre douleur au vieillard qui en était porteur, puisqu'il jouissait de toute l'intégrité du sentiment et du mouvement, assez pour jouer du violin quelques jours même avant sa mort. Il n'avait au bras qu'une tumeur ne le gênant pas, dont il n'avait jamais parlé, et que nous ne pûmes constater qu'à l'examen de son cadavre."*

I do not think our knowledge of the pathology of the nerves is as yet sufficiently advanced to enable us to assign satisfactory causes for the occurrence of the atraumatic forms of neuroma. Some authors assert that they are the result of chronic neuritis. Dr. Copland observes, that "neuroma is undoubtedly a consequence of chronic inflammation of the tumefied part, inasmuch as the changes observed in it are similar to those which result from chronic inflammation in other parts of a like structure."† Others, as Barkow, have arranged the causes of all neuromatous tumours under the three following heads:—mechanical causes, as pressure, blows, wounds, the irritation of a foreign body in contact with a nerve, &c.; internal local causes, as the disease or degeneration of neighbouring parts; general causes, the most frequent among which is supposed to be the rheumatic diathesis. It is stated by Dubois and Siebold‡ that, in all the instances of neuroma which they observed, the patients suffered from rheumatism.

That inflammation of the nerve may occasionally be the cause of neuroma cannot be denied; but the instances are, in my opinion, comparatively speaking, rare, in which the origin of the disease can be distinctly traced to an attack of neuritis, either acute or chronic. In some cases, neuroma is the source of no uneasiness to the patient, who cannot even assign the period of its origin. It is difficult, in such instances, to suppose the existence of inflammation, and altogether impossible in those remarkable examples of the disease

* Thèses de la Faculté de Paris; 1837, No. 220.
† Op. cit., p. 872.
‡ Sammlung chir. Beobachtungen; 1803.

in which the tumours exist in multitudes upon all the nervous trunks in the body, are free from pain, are not accompanied and have not been preceded by any of the phenomena, either local or constitutional, that are usually considered as indicating the presence of inflammatory action. It may be added, that when the tumour has been excised along with the corresponding portion of the nerve, the latter is not found to present any of the anatomical characters of inflammation.

There appears to me to be still less foundation for the opinion of those who have connected this disease with the rheumatic diathesis; there are few affections of more frequent occurrence than rheumatism,—few more rare than neuroma. It is probable that, in the instances alluded to by Dubois and Siebold, the pains complained of by the patients had not their origin in rheumatism, but that they were those vague and wandering aching sensations, which frequently precede the appearance of neuromatous tumours.

With the exception of the traumatic forms of the disease, I fear it must be confessed that we know nothing with certainty regarding the causes of neuroma. It may in some instances result from inflammation, while in others it may be owing to an exudation of a specific character, the consequence of local congestion or irritation, as supposed by Knoblauch, who has thus expressed himself upon the subject: "Celandum autem non est nos sæpe de neuromatum origine in tenebris versari, neque ullo modo causam invenire posse. Sed quæcunque est causa occasionalis, nos statuere posse existimamus, proximam causam esse aut texturam homologam in nervo existentem, aut nimiam exhalationem, tamquam congestionis localis, irritationis aut ipsius inflammationis productum, quod, ab initio fluidum, postea in statum solidum transferatur et organisationem recipiat."*

Although neuromatous tumours occasionally present individual peculiarities, dependent upon accidental circumstances, it may, I think, be safely affirmed that their general anatomical characters are remarkably uniform. The solid idiopathic neuroma originates either in the cellular structure which connects the neurilemma or external sheath to the trunk of the nerve, or within one of the smaller sheaths, by which each of the fibres, the aggregate of which constitutes the nervous trunk, is enveloped.

In these two cases the disposition of the nervous fibres upon the surface of the tumour, as also the coverings of the latter, are somewhat different.

* Op. cit., p. 10.

In the former, where the tumour originates in the neurilemma or its connecting cellular structure, we usually find that the nervous fibres, although flattened and increased in breadth, are not separated from one another as widely as in the latter, supposing the tumour to be of the same size in each case, they are more confined to one surface of the tumour, generally its deep aspect; but when the neuroma originates in one of the central sheaths, it presses, as it grows, more equally upon the surrounding fibres, which are, in such cases, found more widely dispersed over the surface of the morbid growth.

Again, in the latter case, the tumour, when large, is generally invested by a greater number of coverings than in the former; its immediate capsule is the sheath of the fibre where it has originated; external to this we find a thin investment formed by the condensation of the cellular tissue which connects the general sheath to the trunk of the nerve; this sheath or external neurilemma forms the most superficial covering, with the exception, of course, of the subcutaneous cellular texture.

In some cases the coverings of the tumour are easily separated from one another, and with very little dissection can easily be shown to be distinct membranes*; but in others they are intimately united, forming a dense capsule of considerable thickness.

The degree of adhesion of the tumour to its immediate investing membrane also varies considerably in different instances, the connexion being sometimes so close, that it is impossible to remove the tumour from its sac without the aid of the scalpel; while in other instances, when the sac is opened, the tumour can, without difficulty, be detached by the finger from all its connexions.

I have never seen the capsule undergo any cartilaginous or osseous transformation; it is smooth and shining externally, and its internal surface presents, in general, a glistening aspect, more especially when it is but loosely connected to the tumour.

The oval or oblong form, which so large a proportion of neuromatous tumours acquire as they increase in size, is to be ascribed to the circumstance of their being covered by the neurilemma, which admits most readily of their growth in the direction of the trunk of the nerve.

A section of a neuroma usually discloses an exceedingly dense homogeneous texture; the surface is smooth,† of a greyish white colour, and

* Vide Plate XII., fig. 3. † Vide Plate VI., fig. 2.

frequently the elasticity of the structure is such that the cut surface becomes convex; it seldom presents the same shade of colour as the nervous tissue; its texture is essentially fibrous, or fibro-cellular, but so exceedingly close and dense, that the unassisted eye can scarcely ever detect the course or arrangement of the fibres. In the majority of cases the tumour is solid throughout, and everywhere presents the same appearance and an equal degree of density; indeed the uniformity of the aspect of the interior of neuromatous tumours is not one of their least remarkable features.

It has been stated by Dupuytren* that one of the characters which distinguish neuroma from the fibro-cellular encysted tumour (or painful subcutaneous tubercle of English authors) is, that in the former there is a cavity containing fluid, the latter being always solid throughout. This I believe to be by far too general an assertion, and my experience would lead me to say that it is only in exceedingly large tumours that cavities are occasionally found; a neuroma may even attain the size of an infant's head without any cavity being formed in it. The tumour connected with the vagus nerve, represented in Plate VI., figs. 1 and 2, was everywhere solid. The existence of a cavity containing fluid in the smaller neuromatous tumours I believe to be the exception.

When, however, the tumour has attained a very large size, cavities occasionally form in its interior†; they vary considerably in their dimensions, do not communicate with one another, and are lined by a distinct, shining membrane, which, sometimes villous, is generally smooth. Some contain a serous fluid; in others the contents resemble rather synovia or albumen, or may present the characters of purulent matter‡; others, again, are filled with fibrine; and, finally, some are empty. The lining membrane, generally pale, is sometimes very vascular; but I have never seen in any of the cavities of neuromatous tumours fluid or coagulated blood, lardaceous or medullary matter, or any of the substances which are found in malignant tumours; nor have I ever known the neuroma itself, no matter how long it may have existed, or to whatever size it may have attained, assume the external characters or acquire the internal structure of cancerous or encephaloid growths.

The trunk of the nerve immediately above and below the tumour is normal in appearance, and the intermediate portion is merely altered in form, and thrown out of its natural course; it either passes as a single trunk along the posterior or lateral surface of the tumour, or else its separated fibres are dispersed over the surface of the neuroma. In a few instances I have seen some of the nervous filaments enter the superior extremity of the tumour, although I was unable to trace them through it; but I have not yet met with any example of the passage of the entire trunk of the nerve through the neuroma, as is stated to happen occasionally: "Mox nervus cum toto trunco suo in uno latere tumorem intrat, altero autem ex eo rursum egreditur, mox complures rami et intrant et exeunt."*

When the neuroma is of large size it is exceedingly difficult to trace all the separated fibrillæ joining again into a trunk below the tumour, and in some instances it is quite impossible to follow them with the scalpel; but if the tumour and the portion of the nerve connected with it be left for some time in nitric acid, it will become manifest that there is no interruption of continuity in the fibrillæ. It should, however, be mentioned, that in the first case recorded by Aronssohn, the author states that the continuity of the nervous fibres was destroyed†; perhaps if the preparation had been macerated in nitric acid it would have been found that this opinion had been hastily formed.

From what has been stated in the preceding pages respecting the symptoms and characters of painful neuromatous tumours, it is manifest that their diagnosis, although it may be occasionally obscure, is not in general attended with any very serious difficulty. The oval or oblong form of the tumour, its being moveable from side to side, but not in the direction of the nerve upon which it is placed, the attempt to move it in the latter direction being productive of severe pain, its freedom from adhesion to the surrounding structures, the healthy condition of the integuments, the extraordinary sensibility of the tumour, the peculiar electric character of the pain, its terrible severity, paroxysmal type, and extension along the trunk and branches of the nerve, constitute a group of symptoms, which, in the majority of cases, are sufficient to establish the true nature of the tumour.

"Neuromata oculis subjecta, e loco, si tumor nervi decursui respondet, e forma plerumque ovata, ita ut diameter longitudinalis nervi, cui

* Leçons Orales, tom. i., pp. 547—8.
† Vide Plate XII., fig. 3.
‡ Aronssohn, Op. cit.

* Knoblauch, Op. cit., p. 7.
† Op. cit.

insidet, decursui respondeat, e cute sana tumorem tegente, et e doloribus ictui electrico similibus, cognosci poterunt. Cum tumoribus aliis in nervi vicinitate sitis, qui fortasse neuromati similia excitent symptomata, non facile confundi poterunt neuromata. Nam etiamsi illi tumores cum doloribus conjuncti sint, tamen exquisita illa sensibilitas, qualis neuromatum est, nunquam invenietur. Præterea dolores urentes secundum nervi decursum in toto membro se extendentes deerunt.

"Tum potius expectandum sit, continua alieni tumoris in nervum pressione, partium paralysin magis quam dolores perpetuos effici. Præterea symptomata, quæ tumor alienus gignit, subito prorsus desinent aut minuentur, si tumor ita e loco suo removeatur, ut pressio illa deficiat, cujus rei contrarium in neuromate observamus. Quo magis id elevare studebimus, id quod minime tantum fieri poterit, eo majores dolores, eo majora mala hâc efficiemus. Neuroma, ut jam diximus, in unum alterumve tantum latus, reliqui autem tumores aut in omnes partes aut nullo modo, si quidem cum partibus vicinis intime cohærent, moveri possunt. A neuralgiis itidem sub paroxysmorum forma provenientibus, neuroma, si illæ nervo patente insident, et præsentiâ tumoris quamvis parvi, et eo differet, quod in hoc paroxysmus pro libito pressione excitari potest."*

THE TREATMENT OF NEUROMATA.

It is, I conceive, unnecessary to dwell at any considerable length upon the treatment of neuromatous tumours, for it has been established by experience, that operation alone is adequate to their permanent cure. No other mode of local treatment has been found effectual; and every endeavour to promote their absorption, either by counter-irritation, discutient or emollient applications, has been unsuccessful. It has been even stated by Camper† that he generally found such attempts aggravate the disease. It will, therefore, be sufficient to consider what operation should be performed,—should the portion of the nerve with which the tumour is connected be excised along with it?—is it in any case proper to dissect out the tumour from the nervous fibres among which it has grown?—or, finally, may cases occur in which it is justifiable to have recourse to the severe measure of amputation? Generally speaking, the cases alone which require the aid of operative surgery, are those of the solitary and painful neuroma; for the instances are rare, indeed, in which any other circumstance connected with the tumour, except the suffering which it may induce, can justify us in having recourse to any of the serious operations above alluded to.

The annals of surgery furnish numerous instances in which the excision of the neuroma, along with the corresponding portion of the nerve, has been followed by complete and permanent success: the cases recorded by Camper,* Aronssohn,† Alexander,‡ Dubois,§ Reich,‖ Baumeister,¶ Cheselden,** Ruhbaum,†† Home,‡‡ Dupuytren,§§ Velpeau,‖‖ and numerous other writers, both in England and upon the Continent, furnish ample evidence of this important practical fact,—important, as demonstrating the non-malignant character of the disease. Experience has further established that neither sensibility nor the power of voluntary motion are, of necessity, ultimately lost in consequence of the excision of even several inches of some of the largest nerves in the body.

Upon this subject Velpeau remarks: "Malgré la déperdition de substance que l'on fait éprouver à ces nerfs, il ne faut pas croire que la sensibilité et la myotilité soient nécessairement abolies pour toujours. Le rétablissement de ces fonctions finit souvent par s'opérer, et il ne reste presque plus de traces de leur interruption. On a pu emporter ainsi un ou deux pouces du nerf cubital, du nerf radial ou du nerf médian, sans qu'il en soit résulté d'accidents sérieux et sans paralysie permanente."¶¶

In the case operated on by Reich, the tumour was situated upon the ulnar nerve, four inches of which were removed along with it; the operation was successful, the pain ceased, and there remained only a slight degree of insensibility in the little finger.*** I shall presently have occasion to refer to another case, in which, after the removal of nearly an inch and a half of the median nerve, sensibility and the power of voluntary motion were perfectly regained; and I have seen the same happy result follow the excision of a portion of the posterior tibial nerve (where it passes behind the inner ankle) along with a neuroma the

* Knoblauch, De Neuromate, &c.
† Demonstration. Anatomic, Pathol., lib. i., c. 2.

* Op. cit.
† Op. cit.
‡ Dissert. de Tumoribus Nerv.; Lugd. Bat., 1810.
§ Horn's Archiv für Med. Erfahrg.
‖ Sammlg. Auserlesn. Abhdlg. z. Gebrauch. prakt. Aerzte.
¶ Op. cit.
** Op. cit.
†† Schmidt's Jahrb.
‡‡ Op. cit.
§§ Dict. de Médecine, tom. iv.
‖‖ Leçons Orales, tom. iii.
¶¶ Op. cit., tom. iii., p. 414.
*** Alexander, Diss. de Tumoribus Nervorum.

size of a Spanish nut. Even the sciatic nerve may be divided, and a portion of it excised, without permanently destroying the functions of the limb. "L'observation prouve d'ailleurs que par suite de cette excision la vie est rarement compromise, que les fonctions du membre ne sont pas entièrement détruites, et que souvent même la sensibilité et la myotilité se rétablissent presque comme auparavant. M. Malagodi qui a fait l'excision d'une forte portion du nerf sciatique pour un cas de névralgie que rien n'avait pu calmer, a vu le membre, paralysé d'abord, reprendre peu à peu ses fonctions et la malade être complètement rétablit au bout d'une année."*

The size of the nervous trunk which has been operated upon, and the quantity removed, will, of course, influence the period at which the complete restoration of sensibility and of the power of voluntary motion is established; in some cases a few months are sufficient for this purpose, in others a year may elapse, but sooner or later the functions of the part are regained. There is, however, another effect of the operation, which is of longer duration, and to which few authors have alluded, namely, a peculiar coldness of all the parts supplied by the branches of the nerve which has been the subject of the operation. It has been mentioned by Mr. Adams, in recording a case of traumatic neuroma, to which I shall hereafter have occasion to allude. This diminution of temperature is not only felt by the patient, but is at once appreciable by any person examining the parts. In the case of neuroma of the posterior tibial nerve, to which I have already referred, the coldness of the foot for a long period after the removal of the tumour was very remarkable.

The instances in which the removal of the corresponding portion of the nerve along with the neuroma has proved successful are so numerous, that it will be sufficient briefly to allude to a few of the more remarkable cases which have been placed upon record: in all the cure was complete, as far as respects the exemption from suffering and the non-recurrence of the tumour; but it is to be regretted that the final result, as regards the restoration of the sensibility and power of voluntary motion of the limb, has not been more accurately mentioned.

NEUROMA OF THE MUSCULO-CUTANEOUS NERVE OF THE ARM, OR PERFORANS GASSERII: *Hunter.*—A lady, aged twenty years, had a tumour on the outer side of the right arm, just below the centre of the biceps muscle. It was as large as a pullet's egg, and moveable among the surrounding parts, but principally in a lateral direction. It was extremely painful when anything pressed against it, which caused the patient to be extremely cautious in defending it from external accident. It had been several years in attaining the size that has been mentioned above, but as it was now beginning to increase more rapidly, the lady was induced to submit to have it removed. The operation was performed by Mr. Hunter, assisted by Sir Everard Home. When the tumour was fully exposed it was found to terminate at its upper and lower extremities in a white cord, which proved to be the musculo-cutaneous nerve. It was, therefore, thought prudent to remove the whole by dividing the nerve at the two ends of the tumour. The patient lost the use of her fore-finger and thumb, and there was numbness in all the parts supplied by the nerve; the skin which covered them was unusually rough and dry, and the cuticle desquamated. It is to be regretted that the account of this case has not been brought down to a later period after the performance of the operation, in order that it might be ascertained whether sensibility was ultimately restored or not. Velpeau, in alluding to the case, remarks: "Il y eut dans les premiers temps perte de sensibilité dans le pouce et l'indicateur, mais cette fonction se rétablit bientôt."* Upon what authority this statement has been made I know not; it is not to be found in the history of the case, as recorded by Sir Everard Home.†

On examining the tumour it was found that three inches in length of the nerve had been removed, and that this portion of it was divided into two fasciculi, each of them very much flattened, and passing over two opposite sides of the tumour. There was also a nervous (?) expansion, not thicker than a common membrane, which completely invested the whole of the tumour, and when that was divided it could be readily separated everywhere, except at the extremities, where the connexion was somewhat stronger. I think it is evident that the *nervous* expansion here spoken of was merely the neurilemma, within which the tumour had grown. Velpeau has recorded a case of neuroma of the musculo-cutaneous nerve so very similar to the preceding, that it is unnecessary to enter into its details, further than to say that the tumour was successfully removed.‡

* Velpeau, Op. cit., p. 424.

* Op. cit., tom. iii., p. 417.

† Transactions of a Society for the Improvement of Medical and Chirurgical Knowledge, vol. ii., p. 152, &c.

‡ Op. cit.

NEUROMA OF THE MEDIAN NERVE: *Dubois.*—In this instance the tumour was as large as a moderate-sized melon, and was situated upon the median nerve of the right arm. It was successfully removed by this distinguished surgeon, along with several inches of the nerve.* The tumour was moveable, indolent, and without adhesion to the integuments, which were not discoloured. In this case the sensibility of the fingers was destroyed, whether permanently or not has not been recorded. "Post operationem non aliud ægrotanti superfuit incommodum, quam quod in deletâ sensibilitate laterum digitorum positum fuit."†

NEUROMA OF THE INTERNAL CUTANEOUS NERVE OF THE ARM: *Reich.*—A gentleman, forty-four years of age, of an athletic constitution, when eleven years old, struck his right elbow against a stone with such extreme violence that he was thrown down as if by a thunderbolt, and deprived of his senses for several hours. When he recovered he felt an acute pain in the part which had been struck. The surgeon who was called to see him could only discover the external marks of a slight contusion, which, under the usual treatment, disappeared in a few days. The slightest touch, however, produced an acute pain in the part which had received the blow, where, after a short period, a small tumour began to form, by degrees increased in size, and was most painful when pressed upon.

Having at length become almost unable to aid himself with his right arm, in consequence of the excessive sensibility of the tumour, the patient sought the advice of a great number of surgeons in succession, who prescribed various local applications, none of which, however, afforded him relief from suffering. Upon the 21st of May, 1809, he consulted Reich. The tumour was then two inches in length and one in breadth; it was elevated about three lines above the surrounding integument, and was situated in front of the elbow. Its sensibility was such that the slightest touch caused a most acute pain, which the patient compared to an electric shock, such was the rapidity with which it darted along the limb. A consultation was held by Reich and Brugmans, who were both of opinion that the tumour was a neuroma, and that its extirpation alone offered a hope of recovery. The patient willingly assented to have the necessary operation performed, which was therefore done by Reich upon the 12th of June. The sufferings of the patient were dreadful during the operation, but all pain ceased at once the moment the tumour was removed. The wound was perfectly cicatrized upon the fifteenth day, and at the expiration of a few weeks the patient was able to execute all the motions of the arm without suffering pain; finally, before ten months had passed over, the condition of the limb was as perfect in every respect as it had ever been.*

Two cases of neuroma of the internal cutaneous nerve have likewise been recorded by Aronssohn, in which the extirpation of the tumour was followed by complete success†; and I have already alluded to an instance observed by Portal, in which the extirpation of a neuroma of the external cutaneous nerve permanently relieved the patient, not only from his local sufferings, but also from epileptic convulsions.‡

The history of the treatment of neuromatous tumours supplies but few examples in which the second mode of operation to which I have alluded has been adopted; the results have not been very satisfactory, nor have they afforded much encouragement to the practice of dissecting out the tumour from the branches of the nerve, among which it is, as it were, entangled.

NEUROMA OF THE AXILLARY PLEXUS: *Sir Everard Home.*—Pierre Coillot, a Frenchman, thirty-five years of age, was admitted into St. George's Hospital upon the 13th of July, 1796, under the care of Sir Everard Home. He had a tumour situated in the middle of the hollow between the two folds of the axilla; it was rendered very prominent by raising the arm; it admitted of lateral motion, which was, however, very circumscribed. The first symptom which the patient noticed was a darting pain in the fingers; this came on in July, 1795, and increased from that time, but the tumour in the arm-pit was not discovered until June, 1796, and was then as large as a pullet's egg. When he was admitted into the hospital it was more than double that size; the pain was very severe, and much increased when any pressure was made upon the tumour.

The relations of the tumour to the great nerves and blood-vessels in the axilla, and its obscure motion, were circumstances deemed by Sir Everard Home unfavourable to an operation; he was, therefore, induced to try a variety of

* Spangenberg, Ueber Nervenanschwellungen, in Horn's Archiv f. Med. Erfahrung., vol. v.
† Alexander, Diss. de Tumoribus Nervorum.
* Alexander, loc. cit.
† Op. cit.
‡ Op. cit.

means, with a view to relieve the symptoms; but these proving ineffectual, and the pain becoming more severe, the removal of the tumour was proposed to the patient, as the only means likely to relieve him from his severe sufferings. He cheerfully consented to the performance of the operation, declaring that his present agonies could no longer be endured.

When the tumour was laid bare, its inferior extremity was found to terminate in a strong, white cord; when this was pulled it caused no pain in the part itself, but the arm felt overstretched, and gave the patient the greatest uneasiness. This circumstance recalling to his mind the case of neuroma operated upon by Mr. Hunter,* led Sir Everard Home to consider this as an example of the same disease. He therefore cut through and dissected off a considerable portion of the membrane which covered the tumour, which he was then enabled to disengage with his finger from the remaining portion of its investment; upon which it was immediately expelled by the action of the surrounding muscles. After the operation the patient at once felt relieved from the distressing symptoms which he had previously complained of.

The tumour, of a yellowish-white colour, was about three inches and a half in length, and two in thickness; it was of an oval form; when cut through it was found to consist of a fibrous structure of great density; towards the surface the texture presented a radiated appearance.

Upon the day succeeding the operation the patient was free from pain, and could move his fingers without difficulty. He continued to proceed favourably until the fourth day, when loss of appetite, a hot skin, and a rapid pulse, indicated the existence of fever. Severe local inflammation, followed by suppuration, also attacked the wound; the heat of skin increased; the pulse became more rapid; there was great prostration; and the patient abandoned himself to despair. He died upon the seventh day after the operation.

On examining the parts after death, the tumour was found to have been incased in one of the large nerves of the axillary plexus; the principal portion of the nerve passed along the posterior surface of the tumour. The cyst which had surrounded it was contracted, and more than four times thicker than at the time of the operation. In consequence of having been inflamed, the cavity was lined with lymph, and almost filled with coagulated blood, as suppuration had not completely taken place. The inflammation and swelling had extended some way into the surrounding parts, which were consolidated into one mass. The other parts of the body were found in a natural state; so that, Sir Everard remarks, there was no evident cause of death but what arose from a considerable degree of inflammation upon the substance of a large nerve for three inches in length, which also affected the other nerves of the plexus. A similar tumour had formed in one of the other nerves, but was much smaller in size. It lay directly between the axillary artery and the tumour which had been removed.*

A case of neuroma of the median nerve, in which the extirpation of the tumour was followed by a fatal inflammation of the nerve, has also been recorded by Aronssohn.†

NEUROMA OF THE SCIATIC NERVE: *Velpeau.*—In this case the operation of extirpating the tumour, without cutting across the nerve connected with it, was successfully performed. "J'ai eu l'occasion d'observer un névrôme développé dans l'épaisseur du nerf sciatique. La tumeur existait à la partie postérieure de la cuisse, à quatre travers de doigt au-dessous de la fesse. La tumeur, qui datait de plusieurs années, et qui s'était développée sans cause connue chez une demoiselle âgée de trente et quelques années, avait le volume de la tête d'un nouveau-né.

"Aidé de M. Gorsse, médecin de la malade, j'en fis l'extirpation de la manière suivante. Couchée sur le ventre, ayant un oreiller sous le tronc, la malade fut maintenue dans cette position, ayant la jambe étendue par d'autres aides. Ayant incisé les téguments parallèlement à l'axe du tronc et dans l'étendue de six pouces, à partir du bord externe de l'ischion, j'eus à inciser le fascia sous-cutané, le fascia lata et diverses couches graisseuses avant d'apercevoir la tumeur. Une fois isolée par sa face postérieure, cette tumeur fut accrochée et tirée en arrière, pendant que je l'isolais en dedans et en dehors au moyen d'une dissection lente et délicate. Je la dégageai ainsi de la longue portion du muscle biceps, qui fut refoulé en dedans avec le demi-tendineux et le demi-membraneux.

"C'est alors seulement qu'il devint évident que le nerf sciatique supportait toute cette masse, dont il formait en quelque sorte l'axe. La crainte d'amener la gangrène, ou au moins une paralysie incurable du membre, en excisant un nerf aussi volumineux, me fit hésiter un instant. Voyant, d'ailleurs, que la tumeur était parfaitment libre au

* See p. 12.

* Op. cit., p. 157. † Op. cit.

milieu de la grande traînée celluleuse qui s'étend de l'ischion au jarret, je me demandai s'il n'y aurait pas moyen de la dégarnir des filaments nerveux et de l'enlever seule.

"Après donc en avoir détaché toute la circonférence, et avoir disséqué le nerf par en haut, puis par en bas, comme pour une préparation anatomique, je reconnus qu'il en restait à peu près un tiers d'intact ou de simplement enchâssé sur le plan antérieur du névrôme. Les deux autres tiers de ses cordons étaient épanouis à la manière d'une cage ou d'un panier d'huîtres sur les deux côtés de la tumeur.

"Soutenu par le courage extrême de la malade, je me mis à isoler chacun de ses filets à l'aide du bistouri, et je parvins à les dégager à peu près en les refoulant vers leur centre commun en avant. Le névrôme ainsi enlevé laissa une caverne à loger les deux poings, que je remplis d'abord de boulettes de charpie, et qui fut traitée plus tard par la réunion immédiate secondaire.

"Un engourdissement manifeste, une paralysie incomplète de la moitié externe du pied et du voisinage de la malléole correspondante, sont les seuls accidents qui aient pu m'inspirer quelques craintes pendant une semaine ou deux après cette grave operation; mais ces symptômes se sont amoindris par dégrés, et la guérison, complète au bout de trois mois, est restée définitive. Mademoiselle H. s'est mariée depuis, et sa santé est demeurée parfaite."*

The records of surgery furnish numerous examples in which the operation of amputation has been performed for the cure of neuromatous tumours, as in the instances which occurred in the practice of Graef,† Louis,‡ Odier,§ Chelius,‖ Dieffenbach,¶ and others, among whom Velpeau** mentions Mr. Warren of Boston. This assertion is not, however, strictly correct; for the case alluded to has been recorded by the eminent American surgeon as an example of the painful subcutaneous tubercle, a disease which he distinguishes from neuroma, as is evident from the following passage: "We do not happen to have met with any such enlargement as would constitute a tumour of the nerves, in the sense we attach to this term."†† The case of neuroma of the sciatic nerve, in which amputation of the thigh was performed by Chelius, has been already described;* the following instance, in which the arm was amputated by Louis, is remarkable both for the size and structure of the tumour.

* Velpeau, Op. Cit., p. 420.
† De Mastodynia Nervosa; 1821.
‡ Encyclopédie Méthodique.
§ Op. cit.
‖ Knoblauch, p. 17.
¶ Romberg, Lehre v. d. Nervenkrkhten; 1840.
** Op. cit., p. 414.
†† Surgical Observations on Tumours, p. 451.

Neuroma of the Median Nerve: *Louis.*—A female, aged 22, consulted M. Louis concerning a tumour situated upon the front of the fore-arm, midway between the bend of the elbow and the wrist. It had existed for fourteen years, was deep-seated, apparently upon the interosseous ligament, and had occurred without the patient being able to assign any satisfactory cause for its origin. At first a slight induration, it gradually increased, and its volume enlarged in every direction. She had consulted several of the most eminent surgeons; she had had recourse to charlatans; but the numerous remedies which were proposed and tried proved totally inefficacious, and the patient resolved to leave the tumour to itself.

It was not constantly painful, but darting pains occasionally shot through it, which in time became more frequent and more intense, and the tumour itself enlarged to such a degree, that finally it occupied the entire of the fore-arm, from the elbow to the wrist. Its greatest transverse diameter was six inches. Alarmed by the enormous size of the tumour, and the increase in the frequency and intensity of the darting pains, which now harassed her almost continually, the patient came to Paris, and, by the unanimous advice of the numerous practitioners whom she consulted, submitted to the operation of amputation, which was performed by Louis, four inches above the elbow-joint.

The operation was completely successful, and the patient soon acquired a degree of health to which she had been for many years a stranger.

Upon examining the limb after its removal, it was found that the tumour, deeply seated among the muscles, was surrounded by a fine, semi-transparent membrane, upon which a number of enlarged lymphatic vessels ramified. When this cyst was opened the tumour appeared divided into several more or less considerable lobes, each of which was surrounded by a membrane of the same nature as that which invested the entire; each lobe was composed of several small lobules, closely applied against each other, and of a vermicular form, and each was furnished with a very slender pedicle, consisting of a branch of the median nerve. To these nervous filaments the lobules were fixed in clusters, resembling somewhat bunches of grapes. This structure was firm and

* Vide p. 7.

compact, homogeneous, of a yellowish colour, and apparently consisted of coagulable lymph.

At the lower part of the tumour the fibres of the nerve, which in the natural state advance towards the hand parallel to one another, were seen separated from each other, and greatly enlarged, as far as the annular ligament of the carpus, where they regained their natural appearance, and approached each other, before they passed beneath the palmar aponeurosis.*

Delaroche and Petit-Radel, who have recorded this case in the work referred to, have described the tumour as being connected with the radial nerve; the anatomist will, however, at once perceive that the description applies to the median. Descot has made a similar observation.† In the cases related by Odier, Graef, and Dieffenbach, in which amputation was followed by a permanently successful result, the radial, median, and sciatic nerves were respectively the seat of the disease.

From the results of the treatment by operation of the recorded cases of neuromatous tumours, it appears that the excision of the tumour along with the corresponding portion of the nerve, and the amputation of the limb, have each proved successful in almost every instance in which these methods of treatment have been adopted; but that the operation of dissecting out the tumour from the nervous fibres which surround it has been followed by death in more than one of the few instances in which this plan has been selected, a fatal inflammation of the nerve having ensued.

It is, in my opinion, an operation which should only be performed when, from the peculiar circumstances of the case, it is impossible to have recourse to any other; for instances may, undoubtedly, occur, in which the size of the tumour would render necessary the removal of so large a portion of the principal nerve of a limb, that a reasonable fear might be entertained of the occurrence of permanent paralysis or of gangrene (as happened in a case recorded by Swan); and, upon the other hand, the situation of the tumour may be such as to preclude the possibility of having recourse to amputation. Under such circumstances the surgeon is justified in endeavouring to disengage a large painful neuromatous tumour from the nervous fibrillæ among which it is entangled.

If the neuroma is small, and not connected with the principal nervous trunk of the limb, it then becomes a matter of less importance whether a portion of the nerve be removed with it or not; but if in the course of the operation the surgeon should find any considerable difficulty in disentangling the tumour from the nervous filaments, let him at once abandon the attempt, and without hesitation, dividing the nerve above and below the tumour, remove the intervening portion along with the neuroma.

"Neuromatis remotio e nervo præparatione et ipsa methodus est, quæ propter magnum periculum prorsus omittenda est. Nam præterquam quod intolerabilibus afficit ægrotum doloribus, ne ubique quidem adhiberi poterit, si quidem tumorem sæpe tam arcte cum nervo conjunctum et singulis filis circumdatum invenimus, ut plane removeri non possit. Ex hac methodo sequuntur convulsiones vehementissimæ, nervi inflammatio et ex hâc ipsa mors."*

Upon the whole, as Mr. Adams has remarked,† I would say the rule should be, to cut across the nerve above and below the tumour, and remove the intermediate portion along with the neuroma; but there may be cases in which it may be practicable, and perhaps prudent, without sacrificing the nervous trunk by division, to dissect out the tumour from the nervous fibrillæ which surround it.‡

General Development of Neuromatous Tumours.

Although numerous instances of solitary neuroma have been placed upon record, the annals of pathology contain as yet but few examples in which neuromatous tumours have been developed in almost countless numbers throughout the greater part of the nervous system;—not only connected with the deep-seated trunks, but visible in almost every superficial nerve of the body; not limited to the extremities, but likewise involving the nerves of the great cavities; not confined to the cerebro-spinal, but also implicating the grand sympathetic system; not the seat of pain, but, on the contrary, the source of no apparent injury to the patient; unaccompanied by any lesion of innervation, even when such nerves as the vagus and the phrenic are involved from one extremity to the other. Pathology is, I fear, at fault in its attempts to explain the origin and nature of this strange disease. How forcibly do such cases exemplify the truth of the observation

* Delaroche et Petit-Radel, Art. Tumeur, Encyclop. Méthod.
† Op. cit., p. 250.

* Knoblauch, Op. cit., p. 14.
† Dublin Quarterly Journal, vol. v.
‡ Surgeons, nowadays, whenever possible, dissect out the neuroma from the nerve in which it is situated, and only sacrifice part of the nerve-trunk when this is impracticable. The two ends of the divided nerve should then, if possible, be carefully sutured together. Even if this be done, restoration of function, especially motor, will probably be slow.

of Cruveilhier: "L'anatomie pathologique des nerfs, est encore à faire."

Among the earliest recorded examples of the general development of neuromatous tumours, as far as I have been able to ascertain, is one thus briefly noticed in the work of Descot: "M. le Professeur Richerand a déposé dans les collections de la Faculté une nerf sciatique préparé par M. H. Cloquet, qui présente un développement extraordinaire dans toute sa longueur, et des séries de renflemens ou de ganglions fusiformes. Malheureusement, M. Richerand n'a pu se procurer aucun renseignement sur le sujet dont cette pièce a été extraite, et dont toute le système nerveux présentait des tumeurs analogues."*

More detailed accounts, however, of this remarkable affection of the nerves have been published by Schiffner, Wutzer, and other writers, and several instances have fallen under my own observation. This form of the disease constitutes the second class of neuromatous tumours of Knoblauch, who is of opinion that in such cases the tumours are the result of an original vice of conformation, and should be considered as accessory ganglia: "Vitia primæ conformationis habendi, et vera ganglia sunt."† Before considering this opinion, it will be more convenient to lay before the reader a condensed account of the cases recorded by the authors to whom I have just referred, as well as a description of those which came under my own immediate notice.

The patients in the two examples published by Schiffner were brothers and cretins, natives of Silesia. The elder, Florian Saulich, during the first seven years of his existence continued diminutive in size, and unable either to walk or speak; dull and stupid, he remained always either in the sitting or recumbent posture, and devoured with greediness the food that was offered to him. In the seventh year of his age, without any apparent cause, he was attacked with violent convulsions, which continued with scarcely any remission for three days, after which, by slow degrees, he recovered, and became able to walk, but his step was uncertain and his gait unsteady. He likewise now began to utter sounds, but up to the period of his death, at the age of 34, was never able to speak distinctly, or to render himself intelligible by language. Slothful and indolent by nature, fatigued by the slightest bodily exertion, he shunned the light and the society of men, and sought solitude and darkness, and frequently was found in remote places, buried in sleep; and when roused from this state to eat his food, he gorged himself to such a degree, that vomiting frequently ensued; but he neither drank nor evinced any sign of thirst. The slightest cause of anger rendered him savage, and when this fit of passion had passed over, he sunk into sleep, exhausted. Frequently the most trivial excitement induced convulsions. In the thirty-fourth year of his age, some cause having induced a dreadful fit of anger, he was seized with apoplexy, which proved fatal in a few days.

* Op. cit., p. 253. † Op. cit., p. 1.

AUTOPSY.—The brain was remarkably firm, and its convolutions unusually distinct, but all the cerebral nerves were unnaturally soft, with the exception of the optic and the fifth pair. The eighth pair, immediately after passing through the jugular foramen, became enlarged, and formed a tumour upon each side of the neck, in the region of the second and third cervical vertebræ; its pharyngeal and superior laryngeal branches were also enlarged. The trunk of the nerve then for a short distance resumed its normal size, but presented another tumour corresponding to the fifth cervical vertebra; throughout the remainder of its course it exhibited several other tumours, four or five of which, each as large as a filbert, existed in the vicinity of the bifurcation of the trachea; the branches which entered into the composition of the cardiac, œsophageal, and pulmonic plexuses were likewise enlarged and studded with tumours. The nerves composing the cervical and brachial plexuses were similarly affected, even as far as their origins from the spinal marrow. All the branches of the brachial plexus presented the same abnormal condition, but more especially the internal cutaneous nerve, which, throughout its whole course, was studded with neuromatous tumours, one of which, situated above the internal condyle of the humerus, was of considerable size. The branches of the median, even as far down as the fingers, and the filaments of the spinal accessory in the region of the trapezius muscle, exhibited the same morbid condition.

With respect to the nerves of the lower extremity, a large tumour existed upon the left sciatic near the tuberosity of the ischium, at a short distance below which the nerve divided into two branches, each of which, as far as the popliteal space, presented numerous tumours; the anterior and posterior tibial, and their branches, even as far as the toes, were similarly affected, as well as the peroneal, upon which, just above the external ankle, there existed a tumour of con-

siderable size. The right sciatic and its branches were in a similar condition, but the tumours were larger than upon the opposite side. The nerves of the sympathetic system were unaffected.

Erasmus Saulich, the brother of Florian, was the subject of the second case related by Schiffner, and was likewise afflicted with cretinism. He died at the age of 33 years, having been for a long time previously paralytic of the lower extremities.

It is unnecessary to detail the particulars of the *post mortem* examination, except in so far as they refer to the condition of the nervous system. The first, second, third, and fourth pair of cerebral nerves exhibited no morbid appearance, but numerous small tumours studded the buccinator, pterygoid, and masseteric branches of the third division of the fifth, and the facial filaments of the portio dura of the seventh pair. The glossopharyngeal and the par vagum, both in its cervical and thoracic portions, presented several oblong tumours. In the cervical region the branches which the latter nerve distributes to the larynx, as well as those by which it communicates with the sympathetic, were considerably enlarged; while in the chest numerous tumours were found in the œsophageal and posterior pulmonic plexuses. The occipital, spinal accessory, and cervical nerves were similarly affected. In the axillary plexus neuromatous tumours likewise existed, and its median, ulnar, radial, and cutaneous branches presented them throughout their entire course. Those which existed upon the external and internal cutaneous nerves surpassed the others both in number and in size. Upon the lumbar nerves the tumours were less numerous, but larger. In the centre of the left sciatic nerve there was a tumour as large as a filbert; in each popliteal, one of the form and size of an almond; and in the muscular and cutaneous nerves of the leg they existed in great numbers. The superior cervical ganglion, upon the right side, was as large as a moderate-sized filbert, as was also the inferior ganglion upon the left side.* The phrenic nerve was normal.†

In the case related by Wutzer the patient died of organic disease of the brain, at the age of 39.‡ In this instance all the spinal nerves were enlarged and covered with tumours. "Porro huic apparuit," says Knoblauch, "res memorabilissima atque inexpectata, omnes nervos spinales quadruplo amplificatos et in decursu multis duris nodis præditos fuisse. Massæ incrementum præcipue e neurilematis hypertrophia pendere videbatur. Hujus cadaveris plexum brachialem elephantis potius quam hominis putasses. Ceterum ægrotus, qui constitutione robusta gaudebat, usque ad paucos dies ante mortem negotiis functus, neque de extremitatum doloribus questus est."* The history of the remarkable instance of the general development of neuromatous tumours, which occurred in the practice of Bischoff, has been detailed with great minuteness by Knoblauch, but an abstract comprising the most important features of the case will here suffice.

George Armbruester, thirty-eight years of age, an idiot from his infancy, was admitted into the Lunatic Asylum of Heidelberg in January, 1840. He was tall and thin, although muscular, and of a strong constitution, but indolent, and so impatient of exertion that, when urged to labour, he became violently excited, and gnashed his teeth. His fits of passion lasted for several hours, and sometimes even for an entire day, after which he generally lapsed into melancholy. He shunned the society of men, and had recourse to solitude whenever strangers visited the house of his parents. His complexion was sallow, and his countenance stupid and devoid of expression. Five months after his admission into the Asylum he died of gangrene of the lung combined with pleuritis.

Autopsy.—Upon the day succeeding his death the body was carefully examined by Bischoff. Upon opening the head the first circumstance which attracted observation was the slight depth of the falx cerebri, which, throughout the whole of its anterior portion, did not dip between the hemispheres, which were here closely connected to each other by the arachnoid membrane. When the brain was removed, two round tumours, each resembling a mulberry in size and form, were seen, one upon either side, connected with the portio dura and portio mollis of the seventh pair of nerves, at their entrance into the internal auditory foramina. Similar tumours, but of much smaller size, and of an oblong form, were observed at the origins of most of the cerebral nerves; the third, fourth, and sixth, the three portions of the eighth, and the hypoglossal, presented small oval tumours at their roots, as well as the spinal accessory upon each side.

The greater number of the spinal nerves presented similar tumours: there was one upon the anterior root of the fourth cervical of the left side; also upon the sixth and seventh of the

* Vide Plate XV., figs. 5 and 6.
† Den Oestreich. Med. Jahrbüchern, vol. iv. and vol. vi.
‡ Hekers Annalen der Gesammt. Heilkunde, vol. iii.

* Op. cit., p. 27.

right side, after these nerves had passed through the intervertebral foramina; that connected with the seventh was half an inch in breadth, and upwards of an inch in length. They existed in considerable numbers upon the nervous branches composing the right brachial plexus; most of the thoracic nerves were normal, but upon all the branches of the *cauda equinæ* there appeared numerous tumours of various sizes, and in many instances three or four upon the same trunk. All the cerebral and spinal nerves, throughout their whole course, were remarkable for their great size.

The branches and ganglia of the sympathetic system were likewise unusually developed; the cervical ganglia were nearly double their natural size, and the first thoracic considerably enlarged, but the semilunar ganglia far surpassed the others in their dimensions; they each formed a tumour as large as the shell of a Spanish nut; that of the left side was irregular in form,* solid and smooth upon the surface; that of the right† was circular, its diameter being one inch; it was elastic, and communicated to the fingers a sense of fluctuation. There was a cavity in its interior, filled with a reddish, pultaceous, semi-fluid substance, in which several small crystals were discovered by microscopic examination. The branches of the solar plexus were greatly enlarged upon each side.

Somewhat similar to the preceding cases is the instance recorded by Barkow,‡ who found in the body of a man of weak intellect several neuromatous tumours developed upon the vagi and phrenic nerves. The left vagus began to increase in size in the middle of the neck, and where it crossed the arch of the aorta presented several tumours, the largest of which was upwards of half an inch in breadth. All the branches given off by the nerve, below the point where it began to enlarge, were much thicker than natural. The recurrent branch was studded with several small tumours. The right vagus presented similar appearances; it commenced to enlarge in the region of the larynx. The anterior and posterior pulmonic plexuses, as well as the œsophageal branches, were crowded with small tumours, giving them a nodulated aspect, which gradually disappeared as the nerves approached the diaphragm. The left phrenic was normal, but the right was greatly enlarged where it passed between the pericardium and the lung.

It is very singular that in the year 1843 two examples of the general development of neuromatous tumours should have occurred in the hospitals of the House of Industry, within a few weeks of each other; they were strikingly alike in almost every respect; and they appear to me to demonstrate the incorrectness of the opinion of Knoblauch, that such tumours are to be considered as original vices of conformation, as true accessory ganglia. I shall now carefully detail the particulars of these two remarkable cases, to the elucidation of which the majority of the plates accompanying this memoir have been devoted.

John M'Cann, thirty-five years of age, was admitted into the Richmond Hospital, under the care of Doctor Hutton, in 1840, having a large tumour upon the right side of the neck,* of a globular form, and equal to a moderate-sized cocoa-nut in magnitude; it extended from the mastoid process to within a short distance of the sterno-clavicular articulation. It presented an uniform surface, and admitted of being moved freely in the transverse direction, but could neither be pushed upwards nor drawn downwards; the external jugular vein grooved its surface, the integuments did not adhere to it, nor (although it obviously extended deep into the neck) did it appear to have contracted a close adhesion to any important part; the larynx was not displaced, nor was there any interference with the functions of respiration or deglutition. It was solid throughout, and had existed for upwards of fifteen years, but had never been painful, nor was it now (although of so large a size) the source of much inconvenience to the patient, whose general health was not impaired.

A second tumour, about as large as a walnut, existed underneath the left side of the tongue; it likewise was solid, and free from pain, but its presence was the source of much annoyance to the patient when eating. He could not, with any degree of accuracy, state at what period this tumour commenced to form, being unaware of its existence until it had attained such a size as to interfere with the motions of the tongue.

In consequence of the size of the tumour in the neck, and its relations to the larynx and great vessels and nerves, as well as from an apprehension of its being of a malignant character (notwithstanding its slow growth and freedom from pain), it was not deemed advisable to attempt its removal, more especially as the existence of the sublingual tumour appeared to confirm the opinion which had been formed respecting the nature of the disease. The patient, therefore, left the

* See Plate XV., fig. 2.
† See Plate XV., fig. 3.
‡ Op. cit., p. 524.

* Vide Plate I.

hospital shortly after he had been admitted, and resumed his business in the country, that of a cattle-driver, an occupation which exposed him to the inclemency of the weather, not only during the day, but frequently also in the night time.

In 1843 he was again taken into the hospital, having upon the day previous to his admission been found by Doctor Adrien lying upon the side of the road, and complaining of pain in the left hip. Upon examining the part, a large solid tumour was discovered upon the back of the thigh, which the man stated had been growing for nearly two years. It extended from the fold of the nates to the inferior third of the thigh, and exceeded in magnitude the head of the patient; it admitted of being moved from side to side, and, although more prominent in some parts than in others, its general surface was smooth. Several large veins ramified beneath the integuments, which were not adherent to the tumour. The patient suffered no acute pain, the chief inconvenience of which he complained being referable to the existence of so large a tumour in such a situation.

His general health had, however, undergone a material alteration since the period of his first admission into the hospital; he was now pale, and greatly emaciated; he had no relish for his food, nor did he sleep at night; yet he made no complaint of any particular distress, nor could he assign the cause of his restlessness; he had neither diarrhœa nor perspirations; his pulse was quick and weak, but respiration was undisturbed. In this condition he lingered for a few months, gradually pining and wasting away, and towards the end of the year died with hectic symptoms and without pain, but emaciated to the last degree. The tumour in the neck had neither enlarged nor undergone any alteration since 1840, the date of his first admission, nor had the inconvenience arising from the sublingual tumour increased.

It was the opinion of all who witnessed the case, that this immense tumour upon the back of the thigh was of a malignant character, and its appearance was looked upon as establishing the correctness of the diagnosis which had been originally formed regarding the nature of the cervical tumour.

Upon the day succeeding that upon which the patient died, I made a careful examination of the body.* Independent of the tumours which have been already mentioned, several others were now discovered, which had escaped notice during life, although, most probably, some of them had existed when the man was first admitted into the hospital. The largest was situated upon the posterior part of the right thigh, immediately beneath the lower margin of the glutæus maximus muscle; it was of an oblong form, and considerably larger than a lemon. There was one upon the outer side of the right arm, near its centre, of the size of a pigeon's egg; and another upon the front of the right forearm, immediately above the carpus, nearly as large as a hen's egg: they all admitted of being moved in a lateral direction. The intercostal spaces upon each side, as well as the abdominal parietes and right inguinal region, presented numerous tumours about the size of large peas.

Upon laying open the cavity of the abdomen, the first object which attracted my attention was a white solid, oblong tumour, situated in the right iliac fossa, between the iliacus internus muscle, and the outer margin of the psoas magnus. It was three inches and a half in length, and one and a half in breadth. It was connected with the anterior crural nerve, several filaments of which, separated from one another, were spread out upon its anterior surface; these filaments were themselves enlarged, and presented numerous smaller tumours.

Upon tracing the nerve upwards, it was found that all the branches entering into the composition of the lumbar plexus were greatly increased in size, some of them being nearly three-quarters of an inch in diameter; this enlargement commenced where the nerves issued from the intervertebral foramina. The anterior crural* measured three-quarters of an inch in diameter from the lower extremity of the tumour down to its point of exit from the pelvis. Three tumours, each as large as an almond, existed upon the pelvic portion of the inferior musculo-cutaneous or external cutaneous branch of the plexus; and the trunk of the nerve in the interspaces was as large as that of the ulnar in its normal state at the elbow. The anterior division of the nerve was hypertrophied and studded with tumours throughout the whole of its course along the anterior and external region of the thigh. The branches of the anterior crural presented similar appearances, the long saphenus nerve, in particular, being crowded with tumours from its origin to the foot. There existed upon the nerves of the anterior and lateral regions of the right lower extremity upwards of 150 tumours.

* Plate I.

* Vide Plate IV., fig. 1.

The nerves of the front of the left lower extremity* were similarly affected, and presented, from the lumbar plexus to the knee, more than 130 tumours; they were all of an oblong shape, the smallest being about the size of grape-stones, while the largest exceeded an almond in magnitude; upon the surface of several of them, delicate nervous filaments were distinctly visible, running from above downwards.

The right sciatic nerve presented at the lower margin of the glutæus maximus an oval tumour,† five inches in length and three and a half in breadth; the principal portion of the nerve lay upon its anterior surface, but numerous filaments, widely separated from each other, traversed its lateral aspects; it was enclosed in a capsule formed by the distended neurilemma. From the lower extremity of the tumour down to the popliteal space, the trunk of the nerve varied from three-quarters of an inch to one inch and a half in diameter, and each of its component fibres presented a series of oval or oblong tumours, several of which were as large as an almond. The anterior and posterior tibial nerves were in like manner studded with small tumours. The total number discovered upon the right sciatic and its branches exceeded seventy.

It was, however, upon the left sciatic that the most remarkable example of neuroma hitherto recorded was observed‡; one immense tumour occupied the posterior surface of the nerve from the lower margin of the glutæus maximus to within four or five inches of the centre of the popliteal space. Its vertical diameter was eleven inches, and its transverse ten. The extent of its surface from above downwards measured fifteen inches, and from side to side one foot and a half. A dense capsule, formed by the neurilemma, invested its entire surface, to which, however, it did not adhere very closely, except in a few situations, where the connexion was intimate.

The portion of the trunk of the nerve which corresponded to the anterior aspect of the tumour was spread out into a vast number of flattened fibres, which, following the convexity of the neuroma, formed a series of curved lines, diverging above, and at the lower extremity of the tumour re-assembling to form the nervous trunk; these separated and flattened fibres were themselves the seat of more than fifty tumours, the largest of which was about the size of a grape, and upon the surface of some of them numerous fibrillæ could be traced. The trunk of the sciatic, at its origin from the sacral plexus, and for some distance below it, measured an inch and a half in diameter, and several oblong tumours were connected with its enlarged fibres.

At the lower part of the popliteal space there was found a tumour of the form and size of a lemon,* connected by its deep or anterior aspect with the posterior tibial nerve, but the external popliteal and several other branches likewise crossed its surface; they presented a plexiform arrangement, and were all enlarged, some of them being equal to the branches of the sacral plexus in magnitude.

The nerves of the leg were also of immense size, and covered with tumours throughout the entire of their course, from the popliteal space to the foot. The reader will be able to estimate the size to which they had attained, when he is informed that the branches represented in Plate III., fig. 2, constituted, previous to the separation of their fibres by dissection, only three trunks, viz., the anterior and posterior tibial, and the external saphenus or communicans tibialis. The number of tumours which existed upon the left sciatic and its branches exceeded 200.

Nerves of the Right Upper Extremity.†—The nervous trunks which enter into the composition of the right brachial plexus commenced to enlarge immediately upon emerging from the intervertebral foramina, more especially the fifth and sixth cervical, to the trunk formed by the union of which there adhered a circular tumour, larger than a cherry; the neurilemma formed for it a loosely adherent capsule, the internal surface of which was smooth and glistening; the plexus itself, before giving origin to the nerves of the arm, presented several oblong tumours, which it was difficult to separate from each other.

A perfectly oval tumour, as large as a hen's egg, sprung from the external root of the median nerve, which was flat like a ribbon, and its fibres separated from one another; this tumour was in close relation to the brachial artery, and was enclosed in a dense, smooth capsule, continuous with the sheath of the nerve. The entire of the remainder of the median nerve presented numerous oblong swellings of various sizes, the most considerable of which was placed immediately above the carpus; it was pear-shaped, two inches and a half in length, and one and a half in breadth at its upper or widest part; it lay upon the front of the nerve, the separated fibres of which, as they

* Plate IV., fig. 2.
† Plate III., fig. 1.
‡ Plate II.

* Plate III., fig. 2.
† Plate V., fig. 1.

ran over its surface, formed a series of curved lines, arranged like the divisions of a melon.

The external and internal cutaneous, the ulnar, musculo-spiral, and circumflex nerves, were all, in like manner, covered with tumours, more especially the circumflex, which presented one continued series of neuromatous swellings throughout the whole of the axillary portion of its course. Upon the musculo-spiral, besides numerous small tumours, there existed two of considerable size, one of which, as large as a grape, was situated near where the nerve reaches the external side of the humerus, while the other, which was of the size of a pigeon's egg, was placed near the elbow, between the brachialis anticus and the supinator longus. Upwards of 100 tumours were counted upon the nerves of the right upper extremity.

NERVES OF THE LEFT UPPER EXTREMITY.*—The branches forming the left brachial plexus were similarly affected, and presented bulbous enlargements in their course across the neck. A pyriform tumour, nearly four inches in length, and two and a half in breadth, was connected with the lower and posterior part of the plexus; it involved the common origin of the musculo-spiral and circumflex nerves, but was more especially connected with the former, which, by the growth of the tumour, was deflected from its course, flattened, and its fibres separated; its capsule adhered so loosely to it as to admit of being everywhere detached without the use of the scalpel, except towards the apex of the tumour, where the latter sprung from the plexus; here the capsule was closely adherent and continuous with the neurilemma.

Although upon this side the tumours were not as numerous as upon the opposite, yet no branch of the plexus was exempt from them. They were all of an oblong form, existed in the fore-arm as well as the arm, and were most numerously developed upon the internal cutaneous and musculo-spiral nerves; they numbered upwards of sixty. I may here observe that, both in the upper and lower extremities, the tumours existed not only in connexion with the general sheath which invested the entire nerve, but that they were, in numerous instances, found upon the most delicate fibril that could be separated from the nervous trunk by an ordinary dissection.†

PNEUMOGASTRIC NERVES.—The pneumogastric nerve upon the right side‡ was enlarged to an immense size throughout the whole of its course from the base of the skull to the diaphragm; it exceeded the normal size of any nerve in the human body, with the exception of the great sciatic, and throughout the cervical and thoracic divisions of its course presented a most irregular and nodulated appearance; it resembled a large, tortuous, varicose vein. This remarkable condition was produced by a vast number of oblong tumours, varying from half an inch to one inch in length, occupying uninterruptedly the entire course of the nerve, and so closely connected to each other that they could not be rendered distinct without a difficult and tedious dissection. One large, solid, globular tumour occupied nearly the whole of the cervical portion of the nerve, which, along with the carotid artery and jugular vein, corresponded to its deep surface. The tumour was five inches in length and four in breadth, loosely connected to the side of the larynx, and covered by a thick and adherent capsule.* Upon the summit of this large neuromatous tumour, and connected with it by cellular tissue, a smaller one existed, which also sprung from the vagus nerve, and resembled somewhat in form the suprarenal capsule. The left pneumogastric† was also enlarged from the angle of the jaw to the commencement of its thoracic portion, and presented a series of tumours, the largest of which occupied the lower part of the cervical division of the nerve; one equalled an almond in size, and over its surface there ran a delicate fibre, separated from the trunk of the nerve; the latter resumed its normal size shortly after its entrance into the cavity of the chest.

HYPOGLOSSAL NERVE.—Upon the under surface of the tongue, and towards its left side,‡ there existed nearly twenty tumours, of a white and glistening aspect, and of various sizes, from that of a hemp-seed to that of a walnut; they were all connected with the smaller branches of the left hypoglossal nerve; there were none upon the trunk of the nerve, and but few upon its primary divisions. They were principally connected with the terminating branches, which could not in every instance be distinctly traced over the tumour to the muscles they were intended to supply. The branches connected with the two largest of the tumours, after a short course, spread out into a number of delicate filaments, which appeared to be lost upon the capsules which invested the tumours. Some of the smallest of the tumours were situated deep between the muscles,

* Plate V., fig. 2. ‡ Plate VI., fig. 1.
† Plate VI., figs 8, 9, 10, 11.

* Plate VI., fig. 2. ‡ Plate VI., fig. 4.
† Plate VI., fig. 6.

and in size, form, and relation to the fibres of the nerve, resembled very much the Pacinian corpuscles of the digital nerves.

PHRENIC NERVES.*—Upon the phrenic nerves in the neck nothing abnormal was observed, but in their course along the pericardium they each presented three or four small tumours, resembling grains of wheat in size and shape; the neurilemma was continued over them: the nerves between the tumours were of normal size.

INTERCOSTAL NERVES.—The anterior branches of the dorsal nerves upon each side were greatly enlarged, from the spine as far forwards as the costal cartilages; the enlargement commenced where the nerves issued from between the bodies of the vertebræ, but became much more remarkable after their communication with the thoracic ganglia of the sympathetic, and in most instances appeared to be owing to a general hypertrophy of the entire trunk of the nerve, rather than to the development of distinct tumours upon the individual fibres. The fourth intercostal of the left side† had attained such a size at its vertebral extremity as to occupy nearly the entire breadth of the intercostal space, and completely conceal the artery and vein; the sixth was nearly as large; but by far the most remarkable appearances were connected with the fifth.

A large oval tumour, about two inches in length, and one and a half in its vertical diameter, occupied the posterior extremity of the fifth intercostal space, the breadth of which was increased by the absorption of the contiguous portions of the fifth and sixth ribs, between which the tumour was firmly wedged; the bones, however, were not carious, nor had they the rough and corroded aspect which the bodies of the vertebræ present when partially destroyed by the pressure of an aneurism; on the contrary, the surfaces in contact with the neuroma were perfectly smooth, and seemingly more dense than any other portion of the bones. The increase of space required for the accommodation of the tumour was provided at the expense chiefly of the rib superior to it. The tumour projected forwards, pushing the pleura before it, and posteriorly had also passed the level of the ribs, and was in contact with the muscles of the vertebral grooves. The intercostal nerve, which was split into three portions as far back as its junction with the sympathetic, traversed the inferior part of its anterior surface; and upon two of these portions smaller tumours existed. The principal tumour was enclosed in a very thick capsule, which was easily divisible into two distinct layers, the external being connected with the neurilemma of the intercostal nerve, while the internal appeared to be proper to the tumour itself. The communicating branch of the sympathetic formed an oval tumour, nearly as large as a cherry-stone, and in many other of the intercostal spaces these branches were much larger than natural.

Two large tumours existed in the pelvis; they lay upon the front of the sacrum, and were connected with the anterior branches of the sacral nerves,* several of the filaments of which traversed their anterior surface; these filaments were enlarged, and several small tumours existed upon them. The capsules of the larger tumours were remarkable for the looseness of their connexion. There was no morbid alteration noticed in the brain or spinal marrow, or in their membranes; nor did the enlargement of the nerves in any instance extend within the spinal canal; it did not commence until after the trunk formed by the junction of the anterior and posterior roots had passed through the intervertebral foramen.

In this remarkable case, the total number of tumours existing upon the nerves which were removed from the body exceeded 800; they presented a striking uniformity, both in their external characters and in their internal structure; their form was oval or oblong; their colour, a yellowish white; they were solid, and each surrounded by a capsule, which was continuous with the neurilemma; their surface was smooth; their long axis corresponded with the direction of the nerve upon which they existed, and they were only moveable from side to side. Their section exhibited an exceedingly dense, close texture, of a whitish colour, and somewhat glistening aspect, presenting a uniform degree of solidity, and remarkable for a total absence of vascularity. Examined by the aid of the microscope, they were found to be composed essentially of a fibro-cellular structure, the fibrous tissue predominating in by far the greater number, the areolar preponderating in a few†; the fibres were arranged in bands or loops, amongst which permanent oval or elongated nuclei became apparent on the addition of acetic acid. In no one instance, out of the numerous specimens examined, was there any trace discovered of nerve-tubes, nor any indication whatever of the presence of any of the

* Plate VI., fig. 5. † Plate VI., fig. 3.

* Plate VI., fig. 7. † Plate XV., fig. 12.

structures considered by modern pathologists as characteristic of malignant disease.

A few weeks only had elapsed after the death of the patient whose case has been just detailed, when an opportunity was afforded me of observing another, and even more remarkable example of the general development of neuromatous tumours. In this instance the nature of the disease was at once recognized by the intelligent clinical clerk of the hospital, Mr. M'Dermott (now Dr. M'Dermott, of Bath), to whom I am indebted for the following particulars connected with the history of the case, and whose assistance I had in conducting the *post mortem* examination.

Michael Lawlor, thirty-two years of age, a farmer resident in the county of Wicklow, was admitted into the Whitworth Hospital under the care of Dr. Corrigan, upon the 7th of December, 1843, labouring under the symptoms of gastro-enteritis, which had commenced six weeks previously. In the investigation of the case, when the hand was laid upon the abdomen to ascertain the amount of tenderness upon pressure, numerous small tumours were felt beneath the integuments; they were about the size of peas, moveable, and of firm consistence. Upon being questioned respecting them, the patient stated that many of a similar character, but of larger dimensions, existed in different parts of his body; and he exhibited one of great size, situated between the tuberosity of the ischium and the trochanter major of the left side; it was of an oval form, and as large as a swan's egg, slightly moveable in the transverse direction, and equally solid throughout; the integuments were healthy, and could be moved freely over the surface of the tumour, pressure upon which caused pain, and irritated the fibres of the glutæus maximus, so as to throw its fasciculi into prominent relief. The sensation complained of was that of numbness, rather than of pain, the patient stating that the limb felt as if it were "asleep"; it closely resembled, in short, the well-known sensation which follows a blow received upon the ulnar nerve at the elbow.

This large tumour was the first to which the notice of the patient had been attracted, and was of the size of a gooseberry when first observed, six months previous to his admission into the hospital; its appearance was preceded for about six months more by a sensation in the part "like the trickling or dropping of cold water down the limb." He could not attribute its formation to any local injury. He had always been a healthy man until within a year previous to his admission, when, having contracted a severe cold, he suffered much from pains in his limbs; during this period he likewise underwent great distress of mind in consequence of having lost his farm; he became thin, and the functions of the digestive organs began to be deranged.

Another tumour, larger than that just described, and of the existence of which the patient seemed to have been ignorant, was discovered, placed deep in the hypogastrium, and another, of the size of a small walnut, upon one of the branches of the right anterior crural nerve; these three were painful when pressed upon, but a vast number of others not the source of any uneasiness, were visible in different parts of his body and limbs; they were all moveable from side to side, of firm consistence, and oval or elliptical in form, their long diameter being in the direction of the nerves upon which they occurred, and the course of many of which was, in the emaciated state of the patient, clearly demonstrated by the chains of these swellings and the thickened state of the nerves in the intervals between the tumours.

No satisfactory account could be got from the patient as to the mode of origin or the duration of any of the tumours, with the exception of that upon the back of the left hip; indeed, of the very existence of many of them he was ignorant, nor is it likely he would have alluded to them, had it not been for the accidental discovery of those upon the front of the abdomen. The special senses and temperature of the surface were perfectly natural. His appetite had been giving way, and his bowels had become remarkably torpid, during the six months previous to the attack of gastro-enteritis of which he died; he also suffered from thirst and occasional attacks of vomiting. He had a slight difficulty in passing water, and stated that upon one occasion there was a remarkable diminution of the secretion for a period of two days, almost amounting to suppression.

There was no pain along the spine, but the patient complained that a sense of "trickling cold," proceeding from about the angle of each scapula, and meeting at the spine, passed down the back, dividing again at the sacrum, to follow the course of each sciatic nerve. Latterly his rest was much broken, he had progressively lost flesh, and his stomach had become so irritable as frequently to reject food shortly after it had been taken; his skin was hot and dry, and his pulse 106. He died about ten days after his admission into the hospital.

Autopsy.—The body was greatly emaciated;

the front and sides of the abdomen presented a singular appearance, owing to the existence of a vast number of tumours* in the subcutaneous cellular tissue; they were of a rounded form, of the size of large peas, solid to the feel, and moveable beneath the integuments, which were elevated by them; they were thickly disseminated over the whole front of the abdomen, with the exception of the supra-pubic region, and were found upon dissection to be connected, below with the terminating branches of the musculo-cutaneous divisions of the lumbar plexus, and above with the filaments of the lower intercostal nerves, which are distributed to the muscles and integuments of the upper part of the abdomen. The four or five inferior intercostal spaces presented numerous similar tumours, which were attached to the subcutaneous divisions of the corresponding intercostal nerves. Upwards of 200 of these small neuromatous tumours were scattered over the front and sides of the chest and abdomen. There were, likewise, a considerable number connected with the posterior branches of the dorsal and lumbar nerves.

Nerves of the Right Lower Extremity.—The right sacral plexus (the component branches of which were much enlarged) presented an immense tumour, which filled the true pelvis†; it lay upon the pyriformis muscle and front of the sacrum, behind the pelvic fascia, and had compressed the rectum and bladder; it was not much smaller than the egg of an ostrich, being six inches in length and five in breadth. Besides the partial covering which it derived from the pelvic fascia, it was enclosed in a dense and adherent capsule, which it was impossible to distinguish from the membranous investment of the united sacral nerves. The tumour felt solid, but when cut into was found to contain a number of cavities or cysts, some of which, lined by a smooth and polished membrane, were filled with a viscid, albuminous fluid; others contained unorganized fibrine, and presented a rough and flocculent surface; there was no communication between the different cavities. The solid portions of the tumour were composed of a dense, white, fibro-cellular structure.

The trunk of the sciatic nerve, throughout the greater part of its course, was one inch and a half, and in some places two inches in diameter, and the numerous oval and elliptical tumours which existed upon all its fibres gave it a singularly irregular appearance; it has been represented in Plate XI., separated by dissection into three fasciculi, the central of which is, of itself, in several places larger than the normal sciatic nerve. The neurilemma was much thickened, and everywhere closely adherent to the tumours. An oval tumour, as large as a lemon, occupied the lower part of the popliteal space*; it was connected with the posterior tibial nerve, the flattened fibres of which were separated from one another, as they crossed the surface of the tumour. The external and internal popliteal nerves were also widely separated by this large neuroma. The nerves of the leg, more especially the anterior and posterior tibial, were thickly studded with tumours of various sizes, but in general presenting elliptical forms.

The nerves upon the anterior aspect of the limb,† from the lumbar plexus to the knee, were similarly affected, being covered with tumours as closely as possible crowded together; the long branches of the anterior crural formed chains of tumours, which elevated the integuments. The external cutaneous branch of the plexus, which escapes from the pelvis between the two anterior spinous processes of the ilium, almost equalled in magnitude the normal sciatic nerve, being three-quarters of an inch in diameter at its origin, and not less than half an inch in any part of the pelvic portion of its course. The lumbar nerves, before uniting to form the plexus, were of immense size, being in some places fully an inch in diameter. The total number of tumours which were counted upon the nerves of the right lower extremity exceeded 450.

Nerves of the Left Lower Extremity.—Upon the posterior surface of the left sciatic nerve, immediately after its exit from the pelvis, there existed an oval tumour, five inches in length, and nearly four in breadth‡; it was covered by the glutæus maximus, and admitted of being moved from side to side, but was fixed in the direction of the nerve; the latter, which was double its natural size, when it reached the upper extremity of the tumour began to spread out into numerous flattened fibres, which crossed its anterior or deep surface§ in curved lines, and at its lower extremity became re-united into an immense nervous trunk, one inch and a half in diameter; these ribbon-like fibres presented more than twenty oblong tumours, of various sizes, one of them being as large as an almond.

The principal tumour was covered by a capsule,

* Plate VII. † Plate XI.

* Plate X., fig. 2. † Plate IX., fig. 1. ‡ Plate XII., fig. 1. § Plate XII., fig. 2.

which was continuous with the neurilemma, but beneath this, and in immediate contact with the surface of the neuroma, to which it was closely adherent, there existed a second membranous envelope united to the external capsule by reticular tissue. A section of the tumour* exhibited an exceedingly dense, inelastic, fibrous structure, of a yellowish white colour, and totally destitute of any trace of vascularity. Several small cavities, lined by a smooth, polished membrane, and containing a clear but viscid fluid, were cut through in making the section.

The trunk of the sciatic nerve, from the lower extremity of the tumour down to its bifurcation, varied from three-quarters of an inch to one inch and a half in diameter; it was thickly set with tumours of various sizes, from that of a grape to that of a seed of a lemon, and presented a singularly entangled appearance, like a number of thick and knotted cords irregularly twisted together. When the fibres were separated by dissection, as far as their close adhesion to each other would permit, each fasciculus presented an almost uninterrupted chain of tumours,† similar to those observed in the opposite limb. The same general development of neuromatous enlargements was also observed upon the branches of the sciatic distributed to the leg.

Upon this side neither the lumbar plexus nor its branches in the pelvis exhibited any abnormal appearance, but the divisions of the anterior crural from Poupart's ligament to the knee were covered with tumours,‡ the regularity of the forms and arrangement of which gave to some of the branches the appearance of a string of large beads. The tumours were not, however, as numerous here as upon the branches of the right anterior crural nerve. The total number removed with the nerves of the left lower extremity was 300.

Nerves of the Right Upper Extremity.—The right brachial plexus and its branches were covered with tumours throughout their entire extent, even to the palm of the hand, and the course of the cutaneous nerves along the arm and fore-arm was rendered as distinctly visible through the integuments by chains of tumours,§ as if they had been exposed by the scalpel of the anatomist. The enlargement of the nerves forming the plexus commenced abruptly at the intervertebral foramina, after the junction of the anterior and posterior roots, which were themselves normal in appearance. An oblong tumour, two inches in length, and half an inch in breadth, occupied the upper part of the external cutaneous nerve, close to its origin from the plexus, and a series of smaller tumours existed upon the trunk and branches of the nerve* throughout their entire course. A similar series of swellings marked the course of the internal cutaneous and of the branches of the musculo-spiral distributed to the integuments of the fore-arm; numerous large, oblong tumours existed upon the median and ulnar nerves and their branches, and likewise upon the circumflex in its course round the humerus. Upwards of 200 tumours studded the nerves of the right upper extremity.

Nerves of the Left Upper Extremity.†—The nerves entering into the formation of the left brachial plexus were enlarged, but not to the same extent as those of the right, nor were the tumours which existed upon them as numerous, but all the branches given off by the plexus were remarkable for their great size; the median, larger than natural throughout its whole course, was in many places more than half an inch in diameter, and the same observation applies to the external and internal cutaneous, the ulnar, and the musculo-spiral. The nerves upon this side presented upwards of 100 tumours, many of which exceeded an inch in length.

Pneumogastric Nerves.—The pneumogastric nerves commenced to enlarge shortly before their entrance into the chest, and throughout the whole of the thoracic division of their course formed two immense trunks.‡ At its superior part the right vagus was occupied by a tumour two inches and a half in length, and three-quarters of an inch in breadth, and for three inches below this the nerve exceeded half an inch in its transverse diameter; the remaining portion of the thoracic division of the nerve presented an uninterrupted series of oval tumours, about the size of small grapes. The superior part of the nerve almost equalled the œsophagus in its dimensions. The left vagus, enlarged before it entered the thorax, attained, near the arch of the aorta, a diameter of three-quarters of an inch, and then gradually diminished in size, as it coursed along the mediastinum, and at the diaphragm had resumed nearly its normal dimensions. The branches of communication between the nerves, both anterior and posterior to the œsophagus, were greatly enlarged, and covered with tumours of an oblong form, several of which were three-quarters of an inch in length. Upwards

* Plate XII., fig. 3.
† Plate XII., fig. 1.
‡ Plate X., fig. 3.
§ Plate VIII., fig. 1.

* Plate VIII., fig. 2.
† Plate IX., fig. 2.
‡ Plate X., fig. 1.

of sixty tumours existed upon the pneumogastric nerves and their communicating branches in this most remarkable case.

The phrenic nerves were nearly twice as large as natural throughout their entire course,* and as they passed along the side of the pericardium they each presented a series of small, oblong tumours, somewhat larger than grains of wheat. The supra-orbital nerves were also enlarged, and could be rolled like whip-cord beneath the integuments. Upwards of 1,400 neuromatous tumours were removed along with the nerves in this unprecedented case, and yet this falls far short of the total number which had been formed, for upon many of the smaller nervous branches which were not dissected out they may be said to have existed in crowds, and I feel satisfied that there would be no exaggeration in stating the aggregate to be at least 2,000. There was nothing abnormal noticed in the nervous centres. The gastro-intestinal mucous membrane presented the usual anatomical characters of chronic inflammation.

To the preceding instances of the general development of neuromatous tumours, I shall add but one other, the particulars of which have been communicated to me by Dr. Henry Kennedy, of this city, who for many years has had the case under his observation; a brief extract of it will, however, here suffice.

A gentleman, about forty-five years of age, of active habits and vigorous constitution, consulted the late Mr. Colles, sixteen years ago, respecting several small tumours which had formed upon his legs and arms; they were not painful, nor the source of any inconvenience. Mr. Colles, although he confessed that he knew not their cause, and was equally ignorant of any mode of treatment by which they could be removed, except by operation, informed him that they were not of a serious nature, or likely to produce any impairment of his general health. He merely recommended a course of tonic medicines, and a strict attention to diet.

From that period to the present time the tumours have gradually increased in number, but have not become much larger than they were when the attention of the patient was first attracted to them; the only one which increased to any considerable extent was one which he endeavoured to reduce by pressure; it ceased to grow as soon as he abandoned the attempt. At the time of the formation of each tumour he experiences a remarkable feeling of general irritability, as well as a peculiar sensation in the part, somewhat resembling a rheumatic pain; but he cannot always, from mere sensation, refer this trivial uneasiness to the exact situation of the tumour; indeed the latter is generally formed before his attention is attracted to the part. Their number at present amounts to about sixty; they are principally situated upon the inside of the limbs, are solid, moveable from side to side, and not in the slightest degree painful; they appear at very uncertain intervals, and none of them have ever diminished in size.

The patient himself is of opinion that the primary cause of their formation is indigestion, as he always suffers from derangement of the stomach and bowels, and great acidity, for some time previous to the development of each tumour; he also finds that exposure to wet, very warm clothing, or sitting long near a hot fire, have a tendency to induce their formation. No medical treatment has ever appeared to exert any influence over them; some are as small as duck-shot, others are one inch in length and half an inch in breadth; they are principally of an oval form, their long axis being parallel with the nervous trunks.

If the cases just described be compared with those which I have extracted from the memoir of Knoblauch, it will be scarcely possible to avoid arriving at the conclusion that they must all be considered as belonging to the same class, and that in all the nature of the tumours was identical. I have already alluded to the opinion entertained by this author, that such tumours are not the results of a morbid process, but of an original vice of conformation,—that they are, in fact, true accessory ganglia. The three cases, however, which I have detailed, are in opposition to this opinion, for here the successive development of the tumours could be traced, and the periods of their origin in several instances assigned, while in none of them could any trace of nervous structure be detected. These circumstances appear to me sufficient "pour faire écarter l'analogie séduisante au premier abord, mais en réalité trompeuse, qu'on a été tenté d'établir entre ces renflements morbides et les véritables ganglions nerveux normaux."*

Neuroma of the Ganglionic System.

Although neuromatous tumours are, undoubtedly, of much more frequent occurrence upon the nerves which originate from the brain and spinal cord,

* Plate X., figs. 4, 5.

* Bouvier, Tumeurs Fusiformes des Nerfs; Bulletin de l'Acad. Royale de Médecine, t. xii.

than upon those which constitute the sympathetic system, yet the latter are by no means exempt from this remarkable disease; and we have upon record several examples of neuroma connected with the ganglionic system. It is, however, to be remarked, that the enlargements here noticed consist in hypertrophy of some of the elements of the ganglia, much more frequently than in the development of tumours upon their branches, as in the following remarkable example of enlargement of the cervical ganglia of the sympathetic, recorded by Cruveilhier* in his admirable work upon pathological anatomy. In 1827 some of the students of the "Ecole Pratique," while engaged in the dissection of a body which had been brought into the anatomical theatre, discovered several tumours in front of the cervical portion of the vertebral column. M. Bérard, whose attention was immediately directed to them, at first supposed them to be diseased lymphatic glands, but soon discovered that they were formed at the expense of the cervical ganglia of the great sympathetic nerve; they constituted at the left side of the spine a series of tumours, occupying the situation of the ganglia, and communicating with each other and with the anterior branches of the cervical nerves.†

At the upper part of the column, and near the base of the skull, there existed an oblong tumour, about one inch in length and half an inch in breadth; it occupied the situation of a nervous ganglion which frequently exists, and may be termed *the accessory superior cervical ganglion*‡; it was as firm as cartilage, and was continuous above with a thick nervous cord, which adhered to the inferior surface of the petrous portion of the temporal bone, and to the cartilaginous portion of the Eustachian tube, which appeared as if it had been compressed by the tumour. Several voluminous filaments sprung from its inferior extremity, but their destination could not be ascertained, as they had been divided in the manner represented in the Plate before the specimen was shown to Bérard. From its posterior surface three filaments arose, and were lost in the rectus capitis anticus major, while its outer side gave origin to several branches, one of which formed an anastomosis with the filaments of the superior cervical ganglion which ascend in the carotid canal to the cavernous sinus; the others communicated with the first and second cervical nerves.

A fusiform tumour, two inches and a half in length and one in breadth, replaced the superior cervical ganglion; its surface was slightly nodulated, its colour greyish, and its consistence that of a dense, fibrous tumour. Its lower extremity terminated in a thick, nervous trunk, which after a short course swelled out into a tumour of an irregular form, which represented the middle cervical ganglion; from its upper extremity there arose the filaments destined to traverse the carotid canal, while by its outer border it received the branches which establish its communication with the cervical nerves.

When this remarkable tumour was divided longitudinally, there was disclosed a dense, fibrous structure, of a greyish-white colour, the fibres presenting somewhat of an areolar disposition; there was no trace of nervous tissue discoverable in its interior. This fibrous structure was common to all the tumours, and even the communicating cords between the ganglia presented the same aspect, but those by which the latter were connected with the cervical nerves were natural in appearance.

The inferior cervical ganglion was nearly as large as an almond, and irregular in form; it communicated by a very large trunk with the second thoracic ganglion, which latter was of normal size; its cardiac filaments were larger than natural. The various anatomical elements of the ganglia in this remarkable case presented no overgrowth, with the exception of their fibro-cellular tissue,* the nervous substance being rather in a state of atrophy. It is unfortunate that no means existed of procuring a history of the symptoms observed during life.

Coincidence of Multiple Neuromata with Mental Defects.

It is a remarkable circumstance that in several instances this preternatural development of the ganglionic system has coincided with idiotcy and cretinism, as in the cases which have been recorded by Schiffner and Bischoff; and in the

* Anatomie Pathologique du Corps Humain, prem. livraison.

† Plate XV., fig. 4.

‡ "Elle remplace un ganglion nerveux qui existe assez souvent, et qu'on peut appeler *ganglion cervical supérieur accessoire*. Ce ganglion reçoit en effet et émet une partie des branches que reçoit et qu'émet le ganglion cervical supérieur, dont le volume est alors sensiblement diminué."—*Cruveilhier, loc. cit.*

* "Quel est celui de ces élémens qui a été le siége de la transformation? Ce ne sont pas les filamens nerveux, ils sont inaltérables; ce sont les vésicules ou cellules, c'est la substance grise; les nerfs proprement dits comprimés ont disparu, et des ganglions nerveux ont présenté absolument la même structure qu'une tumeur fibreuse. Ce qui confirme cette manière de voir, c'est que la transformation fibreuse existe le long du cordon du grand sympathique, qui contient de la substance grise, et nullement le long des filets de communication avec les paires cervicales qui n'en contiennent pas."—*Cruveilhier, loc. cit.*

thesis on idiotism by Cayre,* supported in 1819, the author states that he observed, in a case of congenital idiotcy, the cervical ganglia of the sympathetic three times larger than natural, and the thoracic and semi-lunar ganglia also much beyond their normal size.

Solitary Neuroma of Gasserian Ganglion.

The ganglia of the cerebro-spinal nerves are rarely the seat of neuroma; only one example of the disease occupying this portion of the nervous system has hitherto fallen under my observation. In this instance the tumour implicated the Gasserian ganglion, and was the source of more severe and uninterrupted suffering than I have ever witnessed either in this or in any other affection.

In the year 1836 an emaciated and unhealthy-looking female, about forty years of age, was admitted into the Richmond Hospital, under the care of Dr. Hutton, complaining of neuralgia of the right side of the face. She stated that the pain had commenced several months previously, had gradually increased in severity, and had now become almost insupportable; she had lost flesh, her sleep was broken, and her appetite had failed. Her countenance indicated extreme suffering; the pain (which, although subject to exacerbations, never altogether ceased) was accurately limited to the right side of the face and forehead, and when indicating the situations in which it was most severe, the patient marked with her finger the course of the branches of the fifth pair of nerves, and more especially the point of exit of the superior maxillary from the infra-orbital foramen. Her sufferings were so much increased by mastication that she ate but little, and speaking aggravated the pain to such a degree that she always remained silent, unless when interrogated, and even upon these occasions she frequently replied by signs. She had no respite from suffering during the day, and at night sleep seldom came to her relief, nor did any of the numerous remedies employed succeed in affording even temporary ease. After having endured more severe and more uninterrupted pain than I had ever witnessed in any other instance, death terminated her protracted agonies, four months subsequent to her admission into the hospital.

Autopsy.—When the cranium was opened and the brain removed, a tumour was seen in the right division of the spheno-temporal fossa†; it was somewhat of the form and size of a walnut, and occupied the situation of the Gasserian ganglion; it extended across the inner extremity of the great wing of the sphenoid bone, as far forwards as the foramen lacerum orbitale, and was covered by the superficial lamina of the dura mater, which was attenuated to a remarkable degree. The trunk of the fifth nerve appeared to enter the posterior part of the tumour, the interior of which, however, presented no trace of nervous structure; the ophthalmic division crossed the anterior part of its superior surface; the superior maxillary emerged from it at the foramen rotundum; and the third division seemed to be identified with a remarkable prolongation of the tumour which passed through the foramen ovale, the circumference of which was increased to more than double its natural extent.

The surface of the petrous portion of the temporal bone, which supported the posterior part of the tumour, was absorbed, as well as the superior wall of the horizontal portion of the carotid canal; between this rough and denuded portion of the bone and the deep surface of the tumour ran the Vidian nerve, which, throughout its whole course, from Meckel's ganglion to the hiatus Fallopii, was much larger than natural. The tumour was solid, and of uniform consistence; its section exhibited a cellular structure,* without any trace whatever of nervous tissue; nerve-fibres could, however, by the assistance of the microscope, be seen upon various parts of its surface. The non-ganglionic portion of the nerve was compressed, but not enlarged.

Traumatic Neuroma.

Under the title of Traumatic Neuroma may be included all the varieties of the disease which arise from mechanical causes, such as wounds, blows, pressure, the irritation produced by a foreign body in contact with, or lodged in a nerve, &c. In these cases there is, in general, but one tumour, which is, in almost every instance, the source of severe suffering, the pain not being limited to the parts below the tumour, but frequently extending likewise along the trunk of the nerve towards its origin. This form of neuroma, when it is the consequence of a wound of the nerve, usually consists of a solid tumour, not invested by the neurilemma, and destitute of any distinct capsule. It is extremely liable to form when the entire nervous trunk has not been completely cut across, and in such cases appears to be more than usually painful.

* Essai sur l'Idiotie; Thesis de 1824. † Plate XIII., fig. 12.

* Plate XV., fig. 11.

Traumatic Neuroma of the Median Nerve.—Catherine Mulvany, twenty-seven years of age, was admitted into the Richmond Hospital in 1846, under the care of Mr. Adams. She stated that about two years previously she fell against a window, and received a wound across the front of the fore-arm, about one inch above the wrist-joint. The median nerve was almost completely cut across, as well as part of some of the tendons, and six months elapsed before the wound was perfectly cicatrized. Subsequently a tumour formed in the course of the median nerve, underneath the central part of the cicatrix.*

This tumour, when the patient presented herself at the Richmond Hospital in September, 1846, was about the size of a small almond; it was hard to the touch, and, to use her own expression, the source of "awful suffering." When at her work, if anything, even her dress, accidentally touched the tumour, severe pain darted downwards to the palm of the hand, and upwards to the shoulder. She also complained of numbness and coldness of all the parts supplied by the median nerve, the ulnar side of the ring-finger and both sides of the little finger being perfectly free from pain or uneasiness of any description.

The proper surgical treatment of the case obviously was to cut out the neuroma, to effect which involved the necessity of removing a portion of the median nerve along with the tumour. The patient gladly assented to have the operation performed, as she found her sufferings daily becoming more severe. The neuroma was removed on the 9th of September, 1846; the wound healed in the course of a week; and when the patient visited the hospital again, a few months afterwards, her statement was to the effect, that some feeling of coldness and numbness still existed in all the parts supplied by the extreme branches of the median nerve, but that there was no morbid sensibility in the seat of the cicatrix where the neuroma had existed.

Fifteen months after the performance of the operation the patient applied at the hospital, seeking advice for a sprain which she had received, and being questioned respecting the results of the operation, she had only one observation to make, showing that any difference from the normal state of the hand now existed, namely, a remarkable coldness of the fingers supplied by the branches of the median nerve. This circumstance, however, in no way interfered with the uses of the hand, which, for all practical purposes, were fully restored.

* Plate XIV., fig. 11.

Upon examination of the portion of the median nerve removed, which was about one inch and a quarter, including the neuroma, it was noticed that the nerve, both above and below the tumour, was in every respect normal. A few delicate fibrillæ passed over the surface of the tumour, a section of which presented a hard, white, homogeneous texture; it was not surrounded by any distinct cyst. The fibres of the nerve which had been divided by the original injury could be traced a short distance into the substance of the tumour.*

The following case affords a remarkable example of an exceedingly painful neuroma, arising from the lodgment of a foreign body in the ulnar nerve. The gradual subsidence and ultimate disappearance of the tumour, when the foreign substance, having altered its position, ceased to irritate the nerve, render this case peculiarly interesting.

Traumatic Neuroma of the Ulnar Nerve.—A medical practitioner residing in the country was suddenly seized, upon the 11th of June, 1848, with a sharp pain in the left arm, near the centre of the deltoid muscle, and upon examining the part about an hour afterwards, a small blue spot, like an ecchymosis, was observed. Although he suffered pain whenever he moved the arm, he paid but little attention to the circumstance for three weeks, when, after a day of constant exercise of the limb, the pain became extremely severe, and the region of the shoulder swollen. To relieve these symptoms blisters were applied.

Upon the 4th of July, while riding very fast, he felt a violent pain in the elbow; it darted suddenly along the ulnar side of the fore-arm, and was intensely felt in the little finger and along the ulnar side of the ring-finger, and during several hours after, shocks of this description occurred, with the rapidity and suddenness of electricity, and the affected fingers became numb. He continued to suffer, for the three following weeks, violent pain whenever he moved the arm; and upon the 23rd discovered a small tumour situated high in the axilla, and which, whenever it was touched, was the source of intolerable agony.

Upon the 27th he came to Dublin, and consulted several eminent practitioners, some of whom recommended the removal of the tumour, but all concurred in advising that the limb should be maintained in a state of perfect quietude, and that he should for a time abandon his professional pursuits.

About a fortnight afterwards he again came to town, and upon this occasion I saw him in con-

* Dublin Quarterly Journal of Medical Science, vol. v.

saltation with Dr. Stokes. Since the period of his first visit the tumour had diminished in size, and the pain had become more endurable, but was always aggravated by pressing upon the tumour. The case was obviously one of neuroma of a branch of the brachial plexus, and the course which the violent shocks of pain followed, clearly indicated that the affected nerve was the ulnar.

The tumour, situated high in the axilla, was nearly twice as large as a garden-pea, of rather an oblong form, and firm to the touch; the trunk of the nerve could be distinctly traced entering its upper, and emerging from its lower extremity, and the tumour could be grasped between the fingers as distinctly and with as much ease as though it were an enlarged lymphatic gland. The patient's general health appeared to have suffered from the long continuance of pain; his aspect was sallow, and his mind depressed; but as he reported that the tumour was becoming smaller, and the paroxysms of pain less severe, there was no indication for any active interference with the disease; he was, therefore, merely recommended to keep the arm quiet, and to abstain from business, in short, to persist in the plan of treatment which had already been found beneficial.

I saw him again three weeks afterwards, about the beginning of September; the tumour had now almost totally disappeared, and pressure upon it caused scarcely any pain, but the *ring* and little fingers still remained numb; his general health had improved, and his manner was more cheerful. He now returned home, and resumed his professional pursuits, though he still occasionally suffered from pain in the region of the shoulder and arm.

Upon the evening of the 30th September, after a day of severe pain, a small tumour appeared near the inferior angle of the scapula, and upon careful examination there was felt beneath the skin something resembling the point of a needle; after considerable difficulty, an unbroken worsted needle was extracted. From this time forward the local distress gradually diminished, and his health improved, although for several months after the removal of the foreign body the fingers continued numb, the hand and wrist weak, and pain was occasionally felt in the arm.

In the fourth volume of the Medico-Chirurgical Transactions, Dr. Denmark has related the case of a soldier wounded in the arm by a musket-ball at the storming of Badajoz. The injury was followed by the formation of a small tumour in the site of the wound, accompanied by symptoms of so severe a nature as to render it necessary to have recourse to amputation. The examination of the limb discovered a small portion of the ball imbedded in the substance of the musculo-spiral nerve, which was here enlarged to twice its natural diameter.

In many instances the origin of a painful neuromatous tumour can be distinctly traced to the receipt of a severe blow or contusion, as in one of the cases recorded by Alexander, in which a dreadfully painful tumour of the internal cutaneous nerve succeeded to a blow upon the elbow.* The following example, related by Dr. Gibbs, of the disease originating from the same cause, is interesting, as showing that even the traumatic neuroma may, for many years, cease to be the source of any uneasiness to the patient, and then again become exquisitely painful.

Traumatic Neuroma of the Radial Nerve.—Philip Chilaieff, forty-two years of age, a sailor, was admitted into the General Naval Hospital of St. Petersburgh on the 24th of December, 1828. He stated that about fifteen years ago he received a blow with a handspike on the outer side of the right arm; that the pain which he experienced at the time was severe; and that numbness down the fore-arm, to the back of the hand and fingers, ensued. Six months after the infliction of the injury he discovered a moveable subcutaneous tumour, of the size of a kidney-bean, about four inches above the elbow-joint, just below the insertion of the deltoid muscle. It was painful to the touch, and the pain, which was increased by exercise of the limb and changes of weather, followed the course of the branches of the musculo-spiral nerve. After a short time his sufferings ceased, and the tumour remained stationary for a period of twelve years and a half, when it began gradually to enlarge, and at the same time the pains extending down the fore-arm recurred.

At his admission into the Naval Hospital the tumour was as large as a hen's egg, moveable from side to side, connected with what appeared to be a nervous cord above and below, and highly painful on being handled. Upon the 3rd of January, 1829, the tumour was removed; an incision, five inches in length, was made, extending from below the insertion of the deltoid muscle to within an inch of the external condyle of the humerus. On dissecting back the integuments, a tumour of a bluish-white colour was brought into view; it lay between the commencement of the supinator longus and the brachialis anticus; the musculo-spiral nerve was connected with its

* See p. 15.

upper extremity, and below was seen emerging from behind it.

The tumour having been separated from its lateral connexions, the nerve was divided three-quarters of an inch below it. The man instantly exclaimed that he had lost the power of raising his fingers, as well as the feeling in the outer part of the fore-arm and back of the hand. The tumour was then detached from all its deep relations, and lastly, the nerve divided three quarters of an inch above it. The wound having been dressed, the limb was placed in the flexed position, and enveloped in flannel.

Upon the following day the patient complained of a sense of constriction across the lower part of the chest, and also of pain shooting up the right side of the neck in the course of the nerves entering into the composition of the brachial plexus; he was bled largely, and an active purgative was prescribed. Upon the fifth day half the wound was found to have united by the first intention; there was complete loss of sensation along the outer side of the fore-arm and back of the thumb and fingers supplied by the dorsal branch of the radial nerve; the loss of sensation extended as far as the middle finger, the ring and little fingers being sensible when pinched.

From this period nothing occurred to interrupt the cure of the wound, with the exception of the formation of an abscess under the integuments, towards the lower and outer side of the arm. At the expiration of about one month the wound was perfectly healed, and the patient had regained some use of the extensor muscles of the fingers, and the numbness was gradually disappearing. Electricity and frictions with stimulating liniments, were employed daily; and on the 16th of April the patient was dismissed from the hospital, with a tolerably free use of the arm, and sensation, to a considerable degree, restored in the hand and fingers.

The tumour, on examination, was found to be invested by the neurilemma, which was greatly thickened, and upon its internal surface were seen the fibres of the nerve separated from each other. A section of the tumour exhibited a soft, striated structure, the striæ appearing to run from the circumference towards the centre, and circumscribing small cells filled with a gelatinous substance. The tumour, which was of an oval form, was two inches and a half in length, and nearly two in breadth. The length of the portion of the nerve extirpated with it was four inches.*

* Edinburgh Med. and Surg. Jour., vol. xxxii.

When, in a former page, I alluded to the surgical treatment of neuromatous tumours, I deemed it superfluous to mention that, in performing the operation of excision of the tumour along with the corresponding portion of the nerve, the latter should be divided *above* the tumour first. I thought it unnecessary to caution the surgeon against what may be termed the cruelty of cutting across the nerve, first below, and again above the neuroma, nor would I now allude to it, were it not that in the case which I have just related, the operator adopted this most objectionable method. In all cases where the surgeon thinks it proper to remove the corresponding portion of the nerve along with the neuroma, the nerve, for obvious reasons, should be cut across first above the tumour. "The nerve should be divided above and below the diseased part, and the tumour removed with the cyst entire; care being taken that the nerve be divided at its upper part first, and as early in the operation as possible, by which means the pain of the operation, which is often very severe, is considerably diminished."*

An example of neuroma connected with the internal saphenus nerve, and originating in a severe strain of the knee-joint, has been recorded by Wood†; the patient was under the care of Professor Syme, by whom the tumour was successfully removed.

The proper surgical treatment of this form of neuroma obviously is, to excise the corresponding portion of the nerve along with the tumour, in every instance where the situation of the disease will permit of its being done. The cases are very few, indeed, in which either the locality or any other circumstance connected with the tumour can render it necessary to have recourse to amputation. Traumatic neuroma never attains such a size as that the removal of the corresponding portion of the nerve can create in the mind of the surgeon any well-grounded apprehension of danger to the functions of the limb, for the results of operations have shown that there does not, of necessity, remain either loss of sensibility or of the power of voluntary motion after the excision of even three or four inches of such nerves as the median or the ulnar, although, as remarked by Todd and Bowman, perfect restoration of the action of the nerve may not always take place, owing, most probably, to the fact that the central and peripheral portions of the same fibres do not

* Observations on Neuroma, by Wm. Wood, Esq.; Trans. Med.-Chir. of Edinburgh, vol. iii.

† Op. cit.

always meet again. The central portion of a motor fibre might unite with the peripheral segment of a sensitive one, and thus the action of each would be neutralized. The surgeon will, however, rarely meet with examples of traumatic neuroma of such a size as to render necessary the removal of so large a portion of the nerve. In the generality of cases the tumour is small, as compared with the size to which it so frequently attains when the disease is of spontaneous origin.

It is worthy of notice that the size of the tumour does not appear to influence the severity of the pain, for a traumatic neuroma not larger than a grain of snipe-shot is frequently as painful as one of the size of a nut. Mr. Rynd has lately shown me a drawing of one not larger than the head of a pin, which caused the most intense suffering, and even produced epileptic convulsions. It was situated in the extremity of the thumb, upon one of the terminating filaments of the median nerve. In this instance amputation of the thumb through the metacarpal phalanx was performed by Sir Philip Crampton, and the patient permanently relieved, not only from pain, but likewise from the epileptic attacks.

The operation of dissecting out the tumour without dividing the nerve, which, as already mentioned, has been occasionally practised in cases of idiopathic neuroma, is not applicable to the variety of the disease which we are now considering; for in almost every instance of neuroma resulting from the wound of a nerve, the tumour is found to be so incorporated with the nervous fibres that the removal of the former without the division of the latter is altogether impossible. In most instances there is no distinct capsule isolating the tumour, and the fibres of the wounded nerve can generally be traced into the interior of the latter for a short distance.

Neuroma Succeeding to Amputations.

Among the traumatic neuromatous tumours I have ventured to include the enlargements formed upon the extremities of nerves divided in amputations. Their existence in such cases is so constant that we may, perhaps, consider them as representing the normal condition of the ends of the nerves in stumps.

Although in some instances they are productive of paroxysms of violent neuralgia, yet in the majority of cases they are not the source of any uneasiness whatever. They are generally of an oval or oblong form, of a greyish-white colour, and remarkable for the density and firmness of their texture.* They vary considerably in size, being in some instances as small as a garden-pea,† in others as large as a grape or a plum. It has been stated by Meckel that their size bears a direct ratio‡ to the quantity of the surrounding cellular tissue, and the length of time which may have elapsed since the division of the nerve. I am inclined, however, to believe that this form of neuroma ceases to enlarge very soon after its formation; that, having attained a certain size, it remains ever after stationary; and that its volume is in direct proportion to that of the nerve upon which it is formed. I have invariably found the largest tumours connected with the largest trunks; and this is in accordance with what we should expect, if we are to consider them as being formed for the protection of the divided extremities of the nerves.

When a section of one of these tumours is made, there is disclosed an exceedingly dense fibrous structure, destitute of vascularity; but the disposition of the fibres of the nerve in the interior of the tumour is by no means uniform. In some cases the nerve appears to terminate at its upper extremity, in others its fibres can be distinctly traced throughout the whole length of the tumour§; but in general the filaments of the nerve, spread out and separated from one another, become incorporated with and disappear in the fibrous structure of the neuroma.‖

In some instances the tumour is situated several inches above the surface of the stump, and at a higher level than the other structures divided in the amputation.¶ In such cases a fibrous cord,** in which no nervous structure exists, usually extends from the extremity of the tumour, and is lost in the tissue of the cicatrix.††

The trunk of the nerve leading to the tumour generally presents a relaxed appearance, its fibres

* "Ce tubercle a une couleur grisâtre; il est souvent si solide et si dur que le scalpel émousse en le coupant, et fait entendre un bruit semblable à celui que produirait son action sur un cartilage."—*Manuel d'Anatomie Générale, par T. F. Meckel*, tom. i. p. 282.

† Plate XIV., fig. 1.

‡ "Le volume de ce tubercle est en raison directe de l'abondance du tissu cellulaire, et du temps qui s'est écoulé depuis la blessure."—*Loc. cit*

§ Plate XIV., fig. 10.

‖ Plate XIV., figs. 3, 6.

¶ Van Hoorn, De iis quæ in partibus Membri, præsertim osseis, amputatione vulneratis notanda sunt; Lugd. Batav., 1803.

** Plate XIV., fig. 4.

†† "M. Breschet a observé aussi que ces tubercles ne formaient pas précisément l'extrémité du nerf, et qu'au dessous il existait un cordon fibreux qui se rendait dans le tissu de la cicatrice où l'amputation avait été pratiquée."—*Descot*, p. 45.

forming a series of undulating lines,* which are most conspicuous in the principal nerve of the limb, and between these waving fibres are seen lines of adipose tissue. The relaxed state of the nerve, and the removal of its extremity to a greater or less distance from the surface of the stump, are probably to be ascribed to its elasticity, owing to which it retracts when divided. At all events there results from the condition alluded to, this important advantage, viz., that the end of the nerve is less exposed to pressure and other external sources of irritation than it would be, were it close to the surface of the stump.

With respect to the cause of the formation of these remarkable tumours, I cannot agree with those pathologists who ascribe them to the effects of pressure exercised upon the surface of the stump, for they are constantly found to exist in cases where, from the period of the amputation up to the decease of the individual, the stump has never been submitted to pressure. I believe that the final object of their formation is the protection of the extremity of the nerve. They are not found connected with the large blood-vessels of the stump, which are equally exposed to pressure; for the sensitive extremities of the divided nerves alone require protection, and this is afforded effectually by the interposition between them and the surface of the stump, of a dense, fibrous cushion, formed of coagulable lymph, and endowed with scarcely any sensibility. To the question, therefore, of Cruveilhier, "Ces renflemens sont-ils un moyen de protection pour les extrémités des nerfs?" I would reply in the affirmative, although this distinguished pathologist himself uppears inclined to ascribe them to the effects of pressure, friction, &c.†

In some cases (fortunately of comparatively rare occurrence) the tumours in question appear to occasion neuralgic pains of the most severe character, coming on in violent paroxysms, subject to atmospheric influences, producing a spasmodic state of the muscles, and frequently a conical stump.

No satisfactory reasons, admitting of general application, have as yet been assigned in explanation of these phenomena, nor have the peculiar circumstances which have occasioned them in individual cases been clearly pointed out. The adhesion of the end of the nerve to the cicatrix of the stump; its irritation by osseous spiculæ springing from the extremity of the sawn bone; the including of a nervous filament in a ligature; the occurrence of a conical stump; such are a few among the many circumstances which have been stated as the occasional causes of these terribly painful tumours.

Mr. Langstaff, in his Observations on the healthy and morbid Conditions of Stumps,* having briefly alluded to the various circumstances which may interfere with the union of the wound by the first intention, and to the morbid appearances which the bone not unfrequently presents, remarks: "In all such stumps I have invariably found the nerves greatly enlarged at their extremities, and generally firmly adherent to the surface of the stump."

From this and other passages in the memoir alluded to we may infer it to be the opinion of the author, that the enlargement of the ends of the nerves divided in amputations is not a constant occurrence, but is only to be looked for in cases where the stump has not healed favourably, or where the extremity of the bone has become the seat of some morbid process. It is true that any of the diseased actions to which Mr. Langstaff has alluded may give rise to the painful tumours under consideration, but I cannot by any means agree in the opinion which the author seems disposed to maintain, that the formation of these tumours is to be considered as the result of a morbid process going on in some of the other structures of the stump. On the contrary, I believe, as already stated, that these peculiar enlargements are, after a certain time, to be found in almost every instance, and that the cases in which they are the source of severe neuralgia are comparatively rare.

For the history of the following remarkably interesting case, as well as for the opportunity of examining the stump, I am indebted to Mr. Colles and to Mr. Wilmot, two of the surgeons of Steevens's Hospital.

John Byrne, thirty-six years of age, on the 18th March, 1846, had his right arm nearly torn off, at the commencement of its inferior third, by its becoming entangled in a machine for cutting hay. He was at once brought to Steevens's Hospital, where the limb was amputated as close as possible

* Plate XIV., figs. 8, 9.

† "Il serait difficile de dire pourquoi les cicatrices des nerfs, divisés dans les amputations, présentent constamment un renflement gangliforme. Les frottemens, les pressions auxquelles sont soumises ces extremités nerveuses, entrent-ils pour quelque chose dans la production de ces renflemens gangliformes? On serait tenté de le croire, si l'on considère que, dans les expériences faites sur les animaux vivans, la section des nerfs, pratiquée dans la continuité des membres avec ou sans perte de substance donne pour résultat des cicatrices on trés légèrement renflées ou nullement renflées."—*Anatom. Pathol.*, liv. 35.

* Medico-Chirurgical Transactions, vol. xvi.

to the seat of the injury. Extensive sloughing of the integuments, however, ensued, and the result was the formation of a very large cicatrix, which alone covered the end of the bone.

About two months after the receipt of the injury, and before the wound was perfectly healed, the stump became painful, but not to such a degree as to call for any very active treatment. Four months elapsed before cicatrization was completed. The patient then left the hospital, but in about a month or six weeks afterwards began to suffer from severe pain in the stump, of an intermittent character, and his general health became greatly impaired.

In May, 1847, he was again admitted into the hospital. The pain had now become constant, and had greatly increased in severity; it was referred particularly to the inner side of the stump, about an inch above its extremity, and here a small and highly sensitive tumour could be felt. He remained only six weeks in the hospital upon this occasion, but again presented himself for admission in November, 1848, having, during the intervening period, employed, but without success, innumerable local applications and internal remedies. He had now no respite whatever from suffering, either during the day or at night, nor could he tolerate the slightest pressure upon the small and exquisitively painful tubercle already alluded to. Amputation of the stump was now performed about two inches and a half above its extremity, and the patient has since remained free from suffering.

The anatomical examination of the stump proved extremely interesting. The extremities of the median and ulnar nerves presented the usual bulbous swellings,* which were situated close to the surface of the cicatrix. They exhibited the ordinary characters of such tumours, as they have been already described; they were smooth upon the surface, and of a white colour, without any trace of vascularity. The trunks of the nerves appeared gradually to enlarge as they approached the tumours, owing to the deposition of lymph between their fibres.

A third tumour,† of an oblong form, about the size of a small nut, and uneven and nodulated upon its surface, was situated at the inner side of the stump, nearly an inch and a half above the end of the bone. It was connected with the extremity of the internal cutaneous nerve, and presented distinct evidence of having been acutely inflamed; its surface was almost as brilliantly red as I have ever seen the conjunctiva in the most acute conjunctivitis, and its interior appeared as if it had been minutely injected. There was no enlargement of the nerve, but its sheath was exceedingly vascular, its substance dark-coloured, and its fibres, separated into packets as they entered, could be traced to unequal distances in the interior of the tumour.

It is worthy of observation that, in this instructive case, the tumours which were closely connected with the cicatrix were never the seat of pain, while that which was far removed from the surface of the stump was not only the source of exquisite suffering, but likewise exhibited the anatomical characters of acute inflammation. But there existed between them this important difference, that the extremities of the nerves with which the former were connected, had been included in the incision in the first operation; while the nerve which terminated in the latter, having been torn across at a much higher level, was thereby placed beyond the line of incision, and consequently remained in the stump, under all the disadvantages of a lacerated nerve.

With regard to the treatment of this variety of neuroma, when it occasions severe and constant neuralgia of the stump, two modes of proceeding are open to the surgeon. He may either excise the tumour along with the extremity of the nerve connected with it, or he may have recourse to amputation of the stump.

The former method should, I think, be adopted in every instance, where the neuralgia is limited to the course of one nerve, and in which exquisite sensibility upon pressure, in some particular spot of the stump, indicates the locality of the tumour which is the source of the patient's sufferings. In performing the operation, it is prudent to remove a considerable portion of the trunk of the nerve along with the neuroma. It lessens the probability of a recurrence of the neuralgia, and does not increase the severity of the operation, the pain attending which may be said to have terminated the moment the trunk of the nerve is divided.

Should the excision of the neuroma fail in affording relief, as is sometimes the case, the surgeon may then have recourse to amputation of the stump; and in all instances where this proceeding has become necessary, the operation should be performed at a considerable distance above the cicatrix; for in cases such as those we are now considering, in which excision of the neuroma has been unsuccessfully performed, the

* Plate XV., figs. 7, 8.
† Plate XV., fig. 9.

failure of the operation is frequently attributable to the existence of chronic inflammation, implicating a greater or less extent of the trunk and sheath of the nerve.

The same caution should be adopted in those cases in which amputation has been had recourse to in the first instance, for the tumour which is the source of all the distress is often situated far above the cicatrix, as in the case of Byrne, recorded in page 34.

When the trunk of a nerve traverses a morbid structure, or lies in immediate contiguity with parts which have been the seat of chronic disease, it frequently appears hypertrophied, and sometimes even presents distinct tumours. In a patient labouring under elephantiasis, Nægele* found the tibial nerve of the affected limb larger than usual, and studded with numerous small cysts, both on its surface and in its interior; and in protracted cases of disease of the ankle and elbow-joints I have frequently seen the posterior tibial nerve behind the malleolus, and the ulnar between the olecranon and the internal condyle of the humerus, twice as large as natural.

The increase of size is not, however, in these instances, to be ascribed to hypertrophy of the nervous structure, but should rather be considered as the effect of irritation established in the neurilemma, the vascularity of which, in such cases, is often considerable. By submitting the nerve to analysis by nitric acid, it can be demonstrated that the hypertrophy of the fibres is only apparent, and that the enlargement is owing to effusion and deposition of plastic matter in the neurilemma and its connecting cellular structure.

* Archives Générales de Médecine, vol. xiii.

BIBLIOGRAPHY.

ARONSSOHN, . . . Observations sur les Tumeurs développées dans les Nerfs. Strasbourg, 1822.

ANDRAL, ... Pathological Anatomy, Translated by Townsend and West, vol. ii.

ABERCROMBIE, . . . Diseases of the Brain and Spinal Cord. 1834.

ALEXANDER, . . . Dissertatio de Tumoribus Nervorum. Lugd. Batav. 1810.

ADELMANN, ... Siebold's Sammlung. Chirurg. Beobachtungen, vol. iii.

ARNEMANN, ... Ueber die Reproduction der Nerven. Goettingen, 1786.

ADAMS, ... Dublin Quarterly Journal of Medical Science, vol. v.

BISCHOFF, ... De Neuromate et Gangliis Accessoriis Veris, Dissertatio Inauguralis Medica (Knoblauch). 1843.

BERARD, ... Dictionnaire de Médecine et Chirurgie Pratique, t. iv.

BERTRAND, ... Thèses de la Faculté de Paris. 1837.

BAUMEISTER, . . . Dissertatio de Tumoribus Nervorum. 1835.

BAUCHÊNE, ... Dissertation sur les Affections locales des Nerfs, par Pierre-Jules Descot. 1825.

BLANDIN, ... Gazette des Hôpitaux. 1839.

BARKOW, ... Bemerkungen über die Nervensanschwellungen, in Nov. Act. Physic. Med. 1829.

BOUVIER, ... Bulletin de l'Académie Royale de Médecine. 1847.

BELL, ... A System of Operative Surgery, vol. ii. 1814.

COPLAND, ... Dictionary of Practical Medicine, vol. ii.

CAMPER, ... Demonstrat. Anatom. Pathol., lib. i., c. 2.

CHESELDEN, ... Anatomy of the Human Body.

COOPER, ... Lancet, vol. i.

CRUVEILHIER, . . . Anatomie Pathologique du Corps Humain, livs. vi., xxxv.

CHELIUS, ... De Neuromate et Gangliis Accessoriis Veris, Dissertatio Inauguralis Medica (Knoblauch). 1843.

CARLILE, ... Dublin Journal of Medical Science, vol. xv.

COVERCELLI, . . . Siebold's Sammlung. Chirurg. Beobachtungen, vol. i.

CRAIGIE, ... Elements of Pathological Anatomy. 1848.

DUPUYTREN, . . . Dictionnaire de Médecine, tome quatrième.

DUBOIS, ... Horn's Archiv für Med. Erfahrung, bd. v.

DESCOT, ... Dissertation sur les Affections locales des Nerfs.

DIEFFENBACH, . . . Romberg, Lehrbuch d. Nervenkrankheiten. 1840.

DENMARK, ... Medico-Chirurgical Transactions, vol. iv. London.

EHRMANN, ... Compte rendu sur les Travaux Anatomiques. Strasbourg, 1827.

FRORIEP, ... Chirurg. Kupfertafeln.

GIBBS, ... Edinburgh Medical and Surgical Journal, vol. xxxii.

GRAEFE, ... De Mastodynia Nervosa, Diss. Auct. Heineke. 1821.

HASLER, ... Dissertatio de Neuromate. 1835.

HOME, ... Transactions of a Society for the Improvement of Medical and Surgical Knowledge, vol. ii.

HEINEKE, ... Dissertatio de Mastodynia Nervosa. 1821.

HESSELBACH, . . . Siebold's Sammlung. Chirurg. Beobachtungen.

KNOBLAUCH, ... De Neuromate et Gangliis Accessoriis Veris, Dissert. Inauguralis Medica. 1843.

LANGSTAFF, ... Medico-Chirurgical Transactions, vol. xvi.

LEVÊQUE-LASSOURCE, Dissertatio Inauguralis. Paris, 1807.

LITHIUS, ... Dissertatio Anatomico-Patholog. de Vitiis Nervorum Organicis. 1838.

LARREY, ... Clinique Chirurgicale.

LAURENCE, ... Lancet. 1829, 1830.

LOUIS, ... Encyclopédie Méthodique, part. Chirurg., t. ii.

LISTON, ... Practical Surgery. 1840.

LOBSTEIN, ... De Nervi Sympathetici humani Fabric. et Morbis.

MECKEL, ... Manuel d'Anatomie Générale, t. i.

MARANDEL, ... Dictionnaire des Sciences Médicales, t. ii.

MAYO, ... Human Pathology.

NASSE, ... Handbuch der Speciell. Therapie. Leipzig, 1832.

NÄGELE, ... Archives Générales de Médecine, t. xiii.

OTTO, ... Pathological Anatomy, translated by South.

OTTO AND WALTHER, Museum Anatomicum.

ODIER, ... Manuel de Médecine Pratique. 1803.

OLLIVIER, ... Traité de la Moëlle Epinière et de ses Maladies. 1824.

PORTAL, ... Cours d'Anatomie Médicale, t. iv.

PETIT-RADEL, . . . Dict. de Chirurg. de l'Encyclop. Method., Art. "Tumeur."

PRING, ... A View of the Relations of the Nervous System in Health and Disease. 1815.

PALMER, ... London Medical Gazette, vol. xvii.

REICHE, ... Sammlung Auserlesn. Abhdlg. z. Gebrauch prakt. Aerzte.

RUHBAUM, ... Schmidt's Jahrbücher. 1841.

RICHERAND, ... Dissertation sur les Affections locales des Nerfs, par Descot. 1825.

SANDIFORT, ... Museum Anatomicum, vol. iii.

SÉDILLOT, ... Journal Générale de Médecine, t. l.

STEIN, ... Dissertatio de Neuromate Nervi Ischiadici.

SPANGENBURGH, . . Horn's Archiv für Med. Erfahrung.

SCHIFFNER, ... Medic. Jahrbücher des Oestreich. Staates, bd. iv.

SWAN, ... A Treatise on the Diseases of the Nerves.

VELPEAU, ... Leçons Orales de Clinique Chirurgicale, t. iii.

VAN HOORN, . . . De iis, quæ in partibus Membri, præsertim osseis, Amputatione vulneratis, notanda sunt; Lugduni Batavorum, 1803.

WOOD, ... Transactions of the Medico-Chirurgical Society of Edinburgh, vol. iii.

WERNER, ... Hufeland's Jour. der prakt. Heilk. 1823.

WEINHOLD, ... Ideen über die abnormen Metamorphosen der Highmorshöle. Leipz., 1810.

WUTZER, ... Heker's Annalen der gessammt. Heilkunde, 1835.

ZAGORSKY, ... Mémoires de Petersburg, t. iii.

PLATE I.

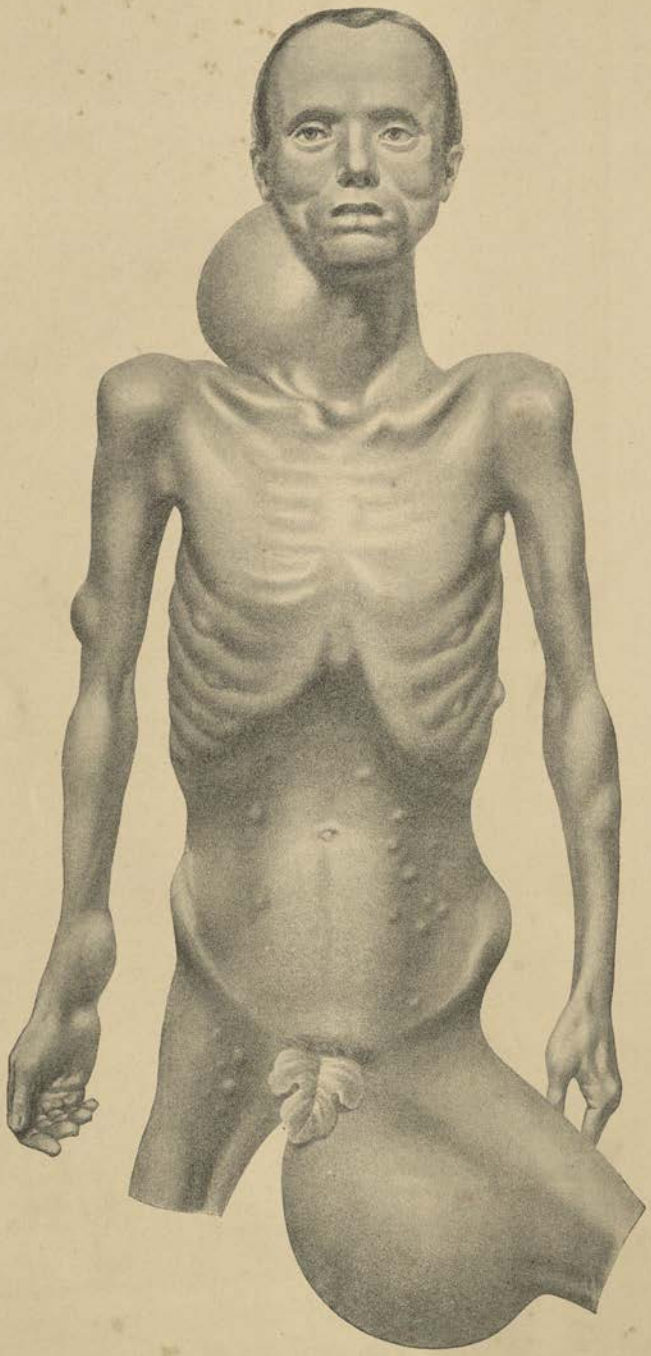

The Plates from I. to VI. inclusive, have reference to the case of John M'Cann, related at page 21.

PLATE I.

External appearances of the body. The large tumours which occupied the left sciatic, the right vagus in the neck, and the right median in the fore-arm are here represented; also numerous small ones in the right inguinal region, on the front of the abdomen, and in the intercostal spaces. A tumour of moderate size is likewise seen in the right arm. It was connected with a branch of the radial nerve.

PLATE II.

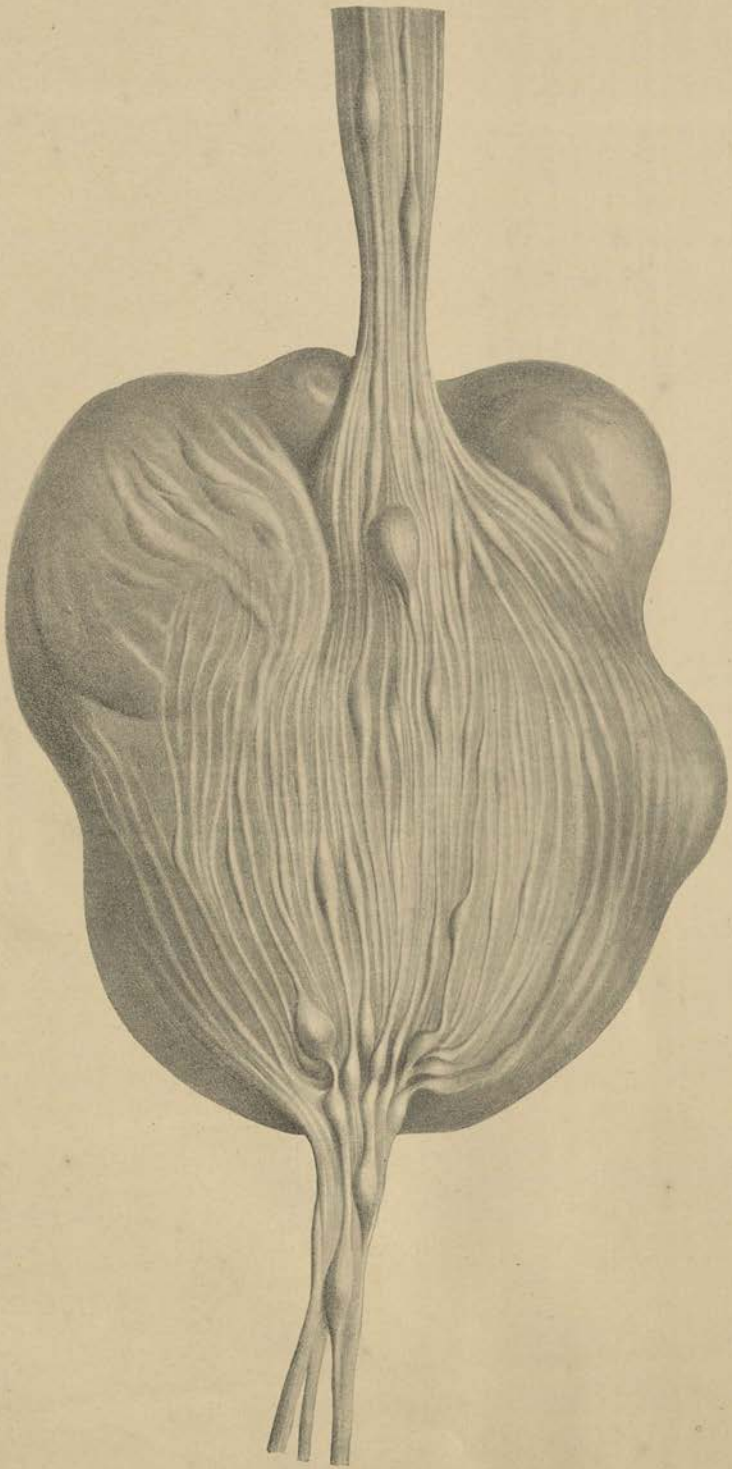

PLATE II.

Neuroma of the left sciatic nerve, ten inches in its transverse, and eleven in its vertical diameter. The fibres of the nerve are seen separated from each other, and studded with small oblong tumours.—See p. 23.

PLATE III.

Fig. 1.

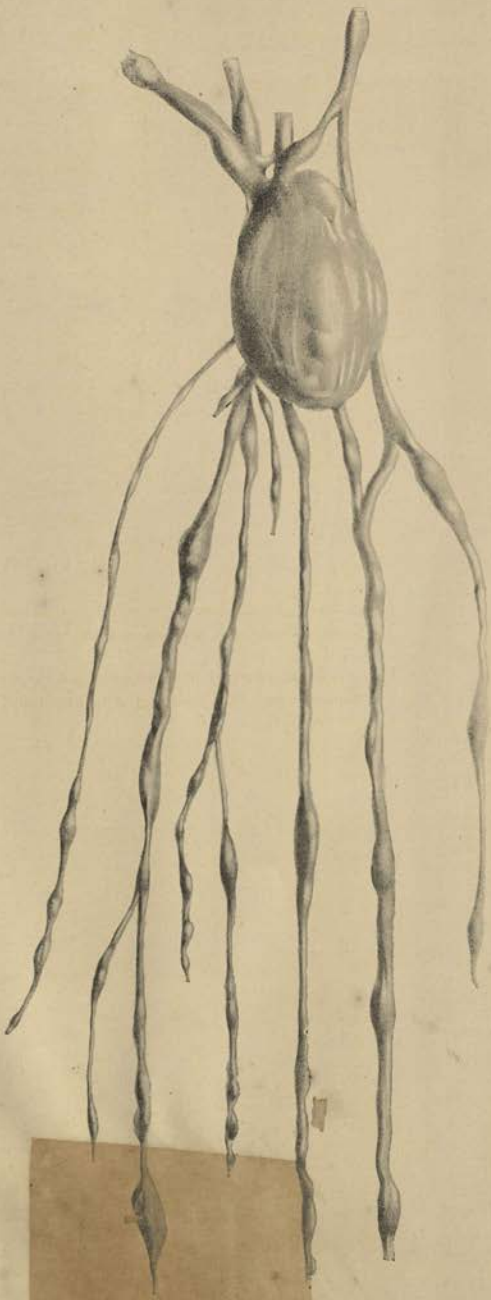

Fig. 2.

PLATE III.

FIG. 1.—The right sciatic nerve, presenting at its superior part a large tumour, five inches in length. Numerous small ones are seen upon the trunk of the nerve throughout its entire course.—See p. 23.

FIG. 2.—The anterior and posterior tibial and the external saphenus nerves of the left side. The large tumour occupied the lower part of the popliteal space.—See p. 23.

PLATE IV.

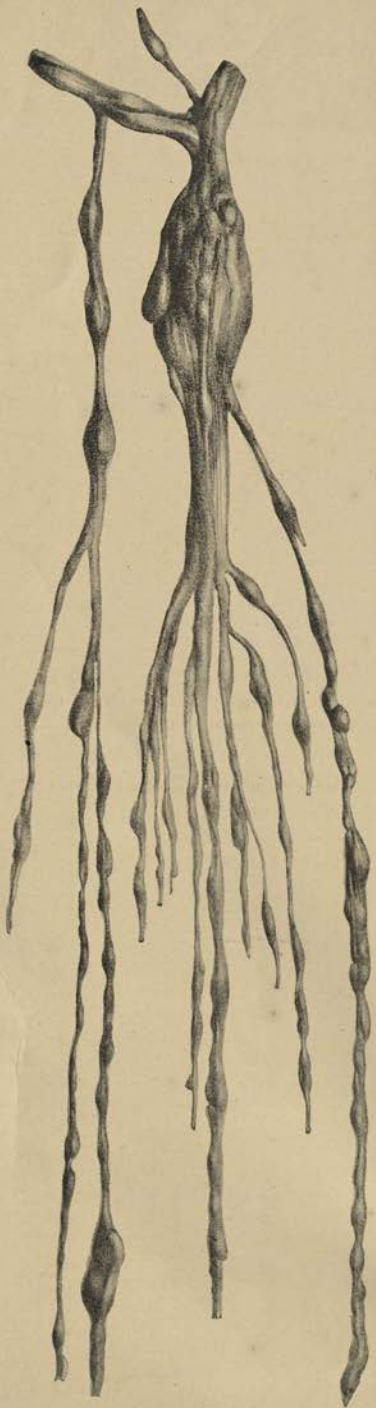

Fig. 1.

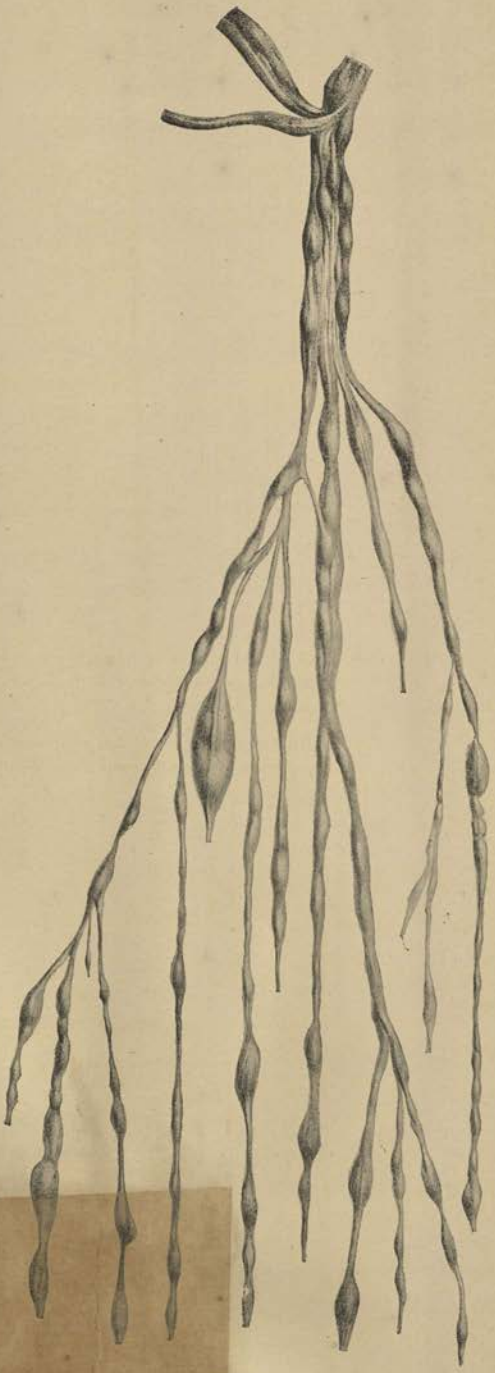

Fig. 2.

PLATE IV.

FIG. 1.—The right anterior crural nerve and its branches from the lumbar plexus to the knee. The large oblong tumour connected with the superior part of the nerve was situated in the iliac fossa.—See p. 22.

FIG. 2.—The left anterior crural and its principal branches crowded with tumours, upon the surface of many of which nervous filaments are seen.—See p. 23.

PLATE V.

Fig. 1.

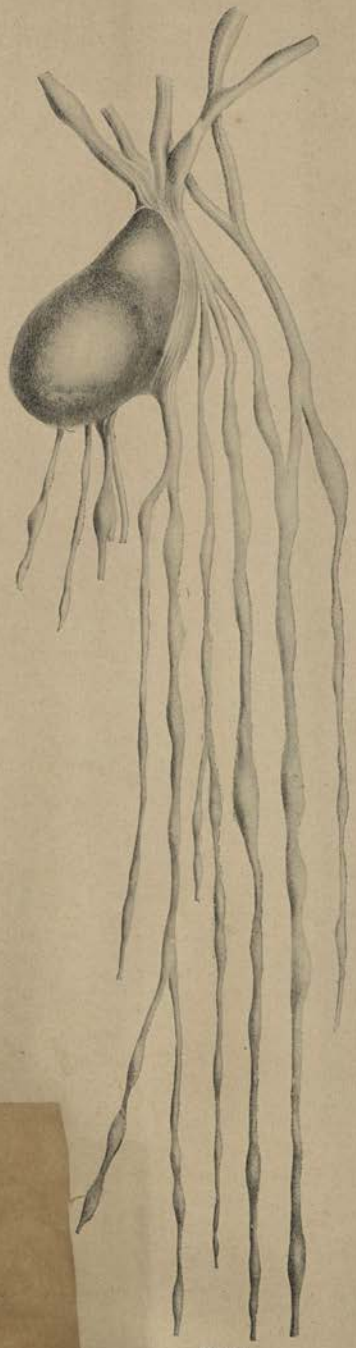

Fig. 2.

PLATE V.

FIG. 1.—The nerves of the right upper extremity. Two large tumours are seen upon the median nerve, one above, upon its external root, the other below. Two of considerable size are also seen upon the ulnar, and one of a circular form connected with the fifth and sixth cervical nerves at their entrance into the brachial plexus.—See p. 23.

FIG. 2.—Nerves of the left upper extremity. A large pyriform tumour occupies the lower and posterior part of the brachial plexus. It involved the common origin of the radial and circumflex nerves.—See p. 24.

PLATE VI.

Fig. 5.

Fig. 6.

Fig. 1.

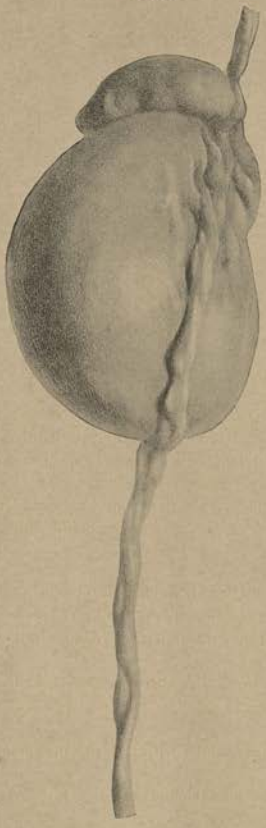

Fig. 7.

Fig. 3.

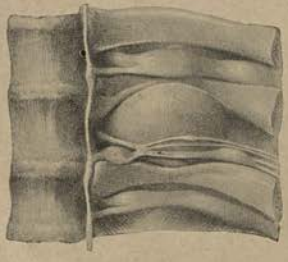

Fig. 4.

Fig. 8.

Fig. 9.

Fig. 2.

Fig. 10.

Fig. 11.

PLATE VI.

FIG. 1.—The right pneumogastric nerve immensely enlarged, and having connected with its cervical portion a neuroma of great size. The nerve crosses the deep surface of the tumour.

FIG. 2.—The neuroma represented in Fig. 1, laid open, and in part detached from its capsule. It was everywhere solid, and composed of an exceedingly dense fibrous structure, somewhat elastic.—See p. 23.

FIG. 3.—This figure represents the fourth, fifth, and sixth intercostal nerves. A large neuroma occupies the fifth intercostal space, having the branches of the nerve spread out upon its surface; and a small one is seen upon the communicating branch of the sympathetic.—See p. 25.

FIG. 4.—Neuromatous tumours upon the under surface of the tongue, connected with the branches of the left hypoglossal nerve.—See p. 24.

FIG. 5.—Small neuromatous tumours connected with the left phrenic nerve in the thorax.—See p. 25.

FIG. 6.—The cervical portion of the left pneumogastric nerve, greatly enlarged, and covered with tumours.—See p. 24.

FIG. 7.—Neuromatous tumours which existed in the pelvis, connected with the anterior branches of the sacral nerves.—See p. 25.

FIGS. 8, 9, 10, 11.—These figures represent neuromatous tumours upon the delicate fibrillæ of different nerves.

PLATE VII.

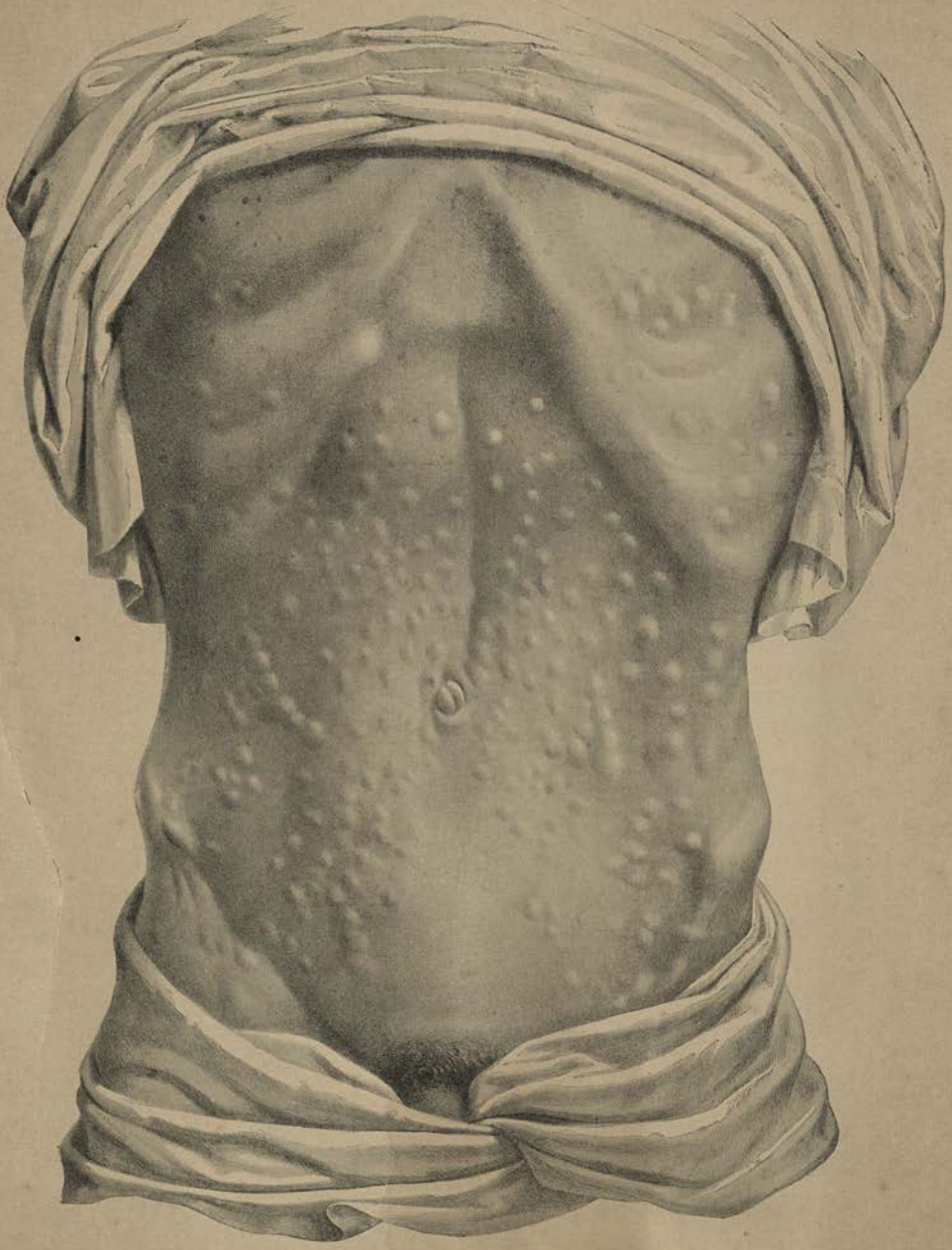

The Plates from VII. to XIII. inclusive, illustrate the morbid appearances observed in the case of Michael Lawlor, described at page 26.

PLATE VII.

The front of the abdomen and of the lower part of the thorax, covered with a vast multitude of small superficial, neuromatous tumours.—See p. 27. How readily the tumours here represented might be confounded with malignant tubercles, will be obvious to any person who compares this remarkable Plate with the third of the thirty-second livraison of the work of Cruveilhier.

FIG. 1.

FIG. 2.

PLATE VIII.

FIG. 1.—The right upper extremity, in which chains of tumours mark the course of the cutaneous nerves, rendering them visible through the integuments.

FIG. 2.—The nerves of the right arm and fore-arm, studded with tumours of various sizes throughout their entire course, from the brachial plexus to the hand.—See p. 28.

PLATE IX.

Fig. 1.

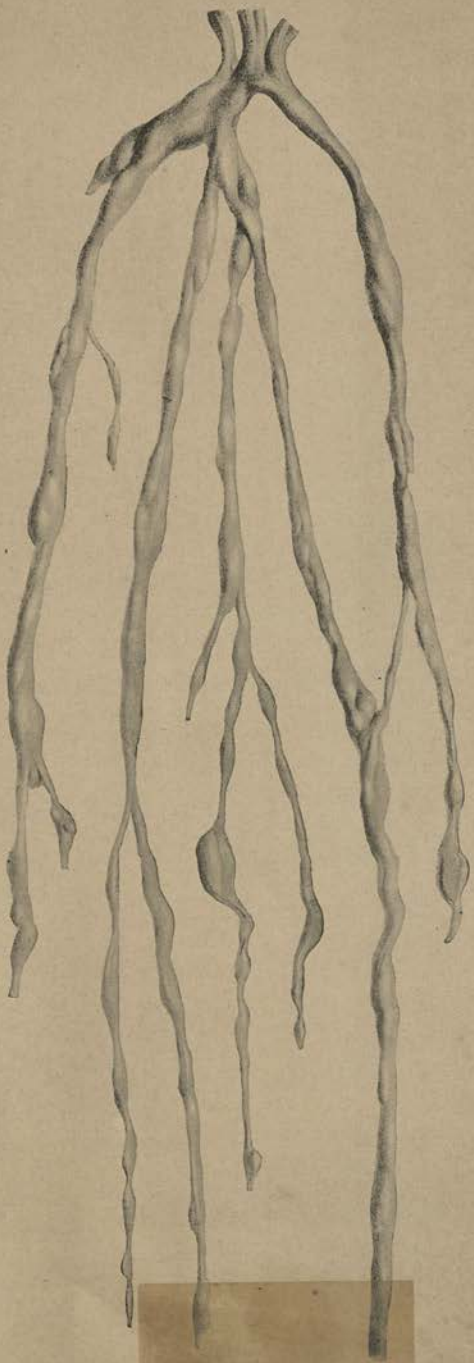

Fig. 2.

PLATE IX.

FIG. 1.—The right anterior crural nerve and its branches, together with a portion of the lumbar plexus. The cutaneous branch, which leaves the pelvis between the two anterior spinous processes of the ilium, almost equals in size the normal sciatic nerve.—See p. 27.

FIG. 2.—Nerves of the left upper extremity, greatly enlarged, and presenting numerous tumours.—See p. 28.

PLATE X.

Fig. 1.

Fig. 2.

Fig. 4.

Fig. 5.

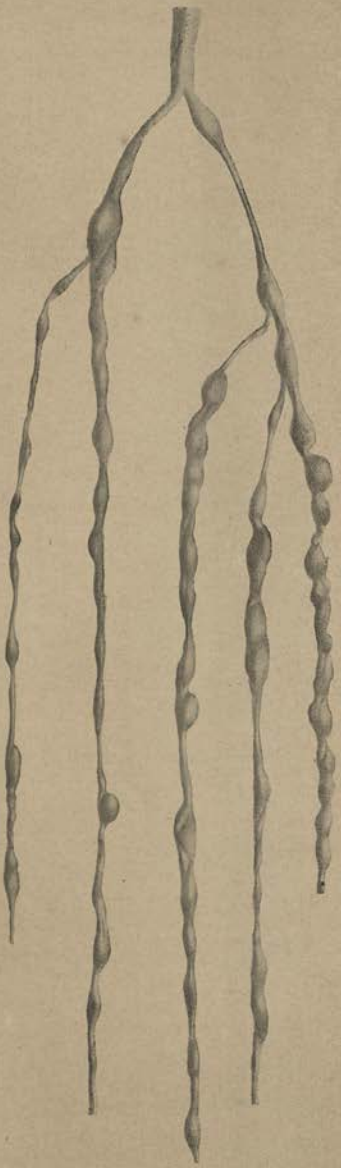

Fig. 3.

PLATE X.

FIG. 1.—This figure represents the œsophagus and the pneumogastric nerves in the thoracic division of their course. The nerves are enormously enlarged, and everywhere covered with tumours.—See p. 28.

FIG. 2.—The popliteal and tibial nerves of the right side. A large tumour is seen connected with the posterior tibial, the fibres of which are spread out upon its surface.—See p. 27.

FIG. 3.—The branches of the left anterior crural nerve.—See p. 28.

FIGS. 4, 5.—The portions of the phrenic nerves which correspond to the pericardium, presenting several small oblong tumours.—See p. 29.

PLATE XI.

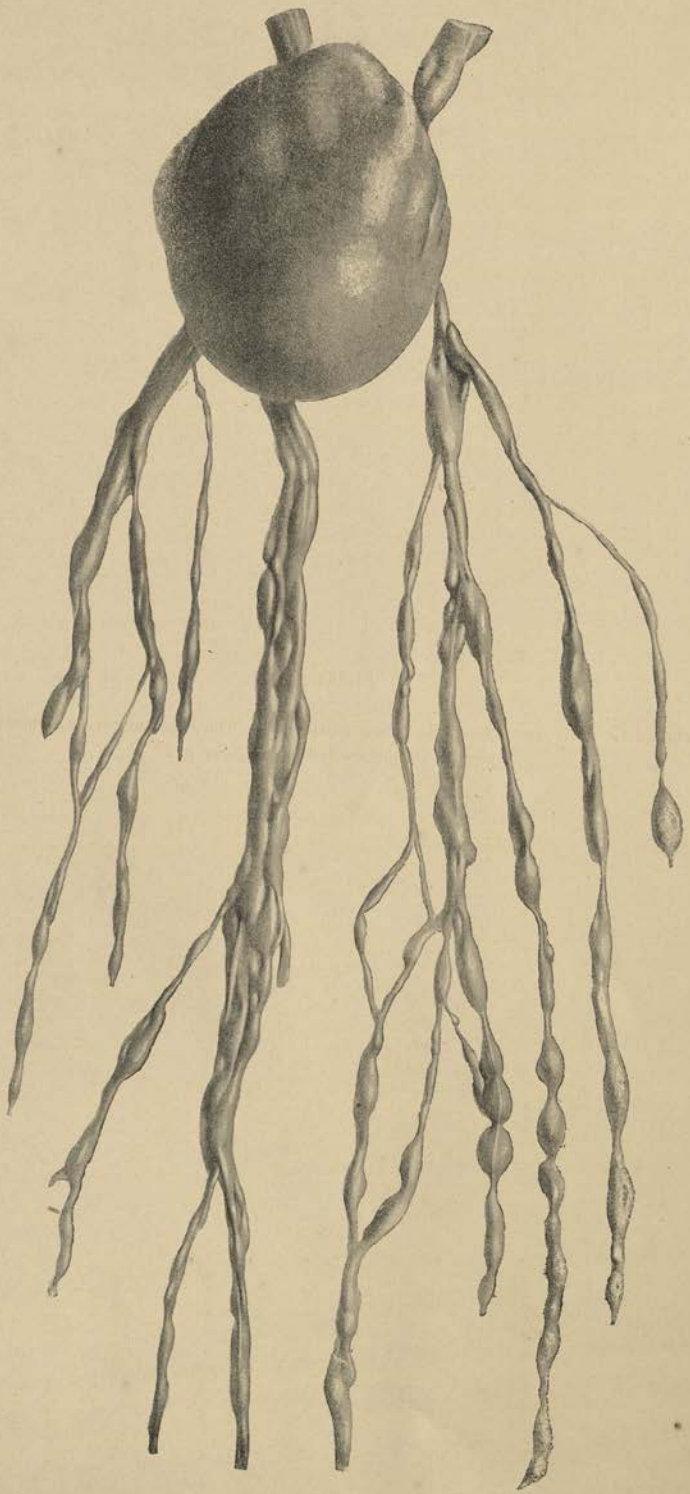

PLATE XI.

The right sciatic nerve, from the sacral plexus to the knee. The large tumour is connected with the sacral plexus; it filled the true pelvis.—See p. 27.

PLATE XII.

Fig. 3.

Fig. 2.

Fig. 1.

PLATE XII.

FIG. 1.—The left sciatic nerve covered with tumours. One of great size occupies its superior part, and was covered by the glutæus maximus.

FIG. 2.—A posterior view of the tumour represented in Fig. 1, showing the separation of the fibres of the nerve from each other.

FIG. 3.—This Figure exhibits several small cavities in the interior of the tumour, and likewise shows the two capsules by which it was invested, separated from each other.—See p. 27.

Fig. 10.

Fig. 1.

Fig. 5.

Fig. 6.

Fig. 2.

Fig. 8.

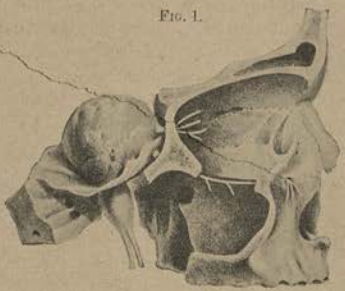

Fig. 12.

Fig. 7.

Fig. 11.



Fig. 9.

Fig. 3.

Fig. 4.

PLATE XIII.

FIG. 1.—Neuroma connected with the external branch of the median nerve distributed to the index finger. It was not the source of pain, nor did it cause any inconvenience sufficient to induce the patient to have it removed. It was moveable in the transverse, but not in the vertical direction. Its structure was dense and fibrous. The specimen was obtained after the patient's death, which was caused by chronic pulmonary disease. The relation of the tumour to the nerve is seen in Fig. 2.

FIG. 3.—This figure, copied from the work of Cruveilhier, shows a neuroma connected with the internal branch of the median nerve distributed to the index finger. The filaments of the nerve, separated slightly from each other, cross the front of the tumour. The latter was, for the most part, solid, but contained a small clot of blood. Cruveilhier has described it as being of a malignant character, but it does not appear that anything was known of the history of the case, for I think it may be inferred from the following passage, that the specimen was found in a subject brought into the anatomical theatre: "On m'a rapporté que le sujet auquel appartenait cette pièce présentait un grand nombre de tumeurs cancéreuses dans diverses parties du corps."—Liv. xxxv., Pl. 2. I am inclined to believe that the tumour was similar to that delineated in Figure 1, and that the case afforded an example of the general development of neuroma.

FIG. 4.—This figure (also copied from the work of Cruveilhier) represents a spheroidal neuromatous tumour, connected with the musculo-spiral nerve at the bend of the elbow. It lay between the supinator longus and the brachialis anticus. The fibres of the nerve were separated from one another, and could be traced, some in front, and others behind the tumour. Many of them were apparently lost in the capsule which invested the neuroma, but none could be followed into the interior of the latter. In this instance, also, Cruveilhier has stated that the nature of the tumour was encephaloid, but has not adduced any proof whatever in support of the assertion; on the contrary, he confesses that he knew nothing of the history connected with the case. He remarks: "Le sujet sur lequel cette tumeur a été trouvée venait de l'amphithéâtre de l'école pratique. Je manque de toute espèce de renseignemens sur la maladie à laquelle il a succombé. Il est probable que c'est à un cancer siégeant dans telle ou telle partie du corps et que la tumeur décrite n'était qu'un des effets consécutifs de l'infection cancéreuse."—*Loc. cit.*

FIG. 5.—Neuroma developed in the centre of the popliteal nerve. The tumour was solid, of a fibrous structure, and everywhere surrounded by the fibres of the nerve. It was not painful, nor was its existence suspected during life.

FIG. 6.—Neuroma of the ulnar nerve. The tumour, which consisted of a cyst filled with a serous fluid, was situated where the nerve passes between the internal condyle of the humerus and the olecranon process of the ulna.—See p. 9, case of Owen Nolan.

FIG. 7.—A serous cyst, developed among the branches of the median nerve distributed to the thumb. It appeared to have originated in the subcutaneous cellular tissue, and afterwards, as it enlarged, to have become connected with the nerves. It is sometimes difficult, as has been remarked by Wood, to distinguish tumours which are merely contiguous to nerves, from the true neuroma which originates within the neurilemma. Such tumours are, however, generally moveable in all directions, and, when drawn away from the nerve, cease to be painful upon pressure.

FIG. 8.—Neuroma of the ulnar nerve; case recorded by Cheselden.—See p. 9.

FIG. 9.—Neuroma of the lower part of the sciatic nerve. The posterior tibial proceeds from its lower extremity, and the peroneal runs over its surface. The limb was amputated by Professor Chelius.—See p. 8.

FIG. 10.—A portion of the brachial plexus, showing remarkable fusiform enlargements of the roots of the median nerve. They were surrounded by a large mass of scirrhous lymphatic glands, but the fibres of the nerves were healthy. The patient died of cancer, which commenced in the axillary glands, and afterwards attacked the breast.—See Dublin Journal, vol. xii., p. 65.

FIG. 11.—*This figure, copied* from the work of Cruveilhier, represents enlargements of nerves, somewhat resembling those delineated in Fig. 10. Nothing was known of the history connected with the specimen.

FIG. 12.—Neuroma of the Gasserian ganglion. A prolongation of the tumour has passed through the foramen ovale.—See p. 31.

PLATE XIV.

Fig. 2.

Fig. 1.

Fig. 3.

Fig. 4.

Fig. 7.

Fig. 8.

Fig. 5.

Fig. 6.

Fig. 11.

Fig. 9.

Fig. 10.

PLATE XIV.

FIG. 1.—This figure represents the appearances of the extremities of the nerves in a case where the fore-arm had been amputated near its centre. None of the tumours were painful.

FIGS. 2, 3.—The sciatic nerve removed from a stump. The limb had been amputated for popliteal aneurism several years before the death of the individual. The tumour formed upon the extremity of the nerve is unusually large, but was not painful. The mode of termination of the fibres of the nerve in the interior of the tumour is seen in Fig. 3.

FIG. 4.—The details of the dissection of a stump, after amputation of the arm near its centre, are represented in this Figure. The cicatrix of the integument was intimately adherent to the extremity of the bone. The brachial artery was remarkably diminished in size, and the extremities of the nerves terminated in tumours which could be felt through the integuments. The largest were connected with the median and radial nerves; and that belonging to the former was prolonged to a certain height in front of the trunk of the nerve. Below it terminated in a thick, fibrous cord, which became confounded with the cicatrix.—Cruveilhier, liv. xxxv., pl. 2.

FIGS. 5, 6.—Fig. 5 represents a tumour connected with the extremities of the nerves of the brachial plexus, in a case in which amputation at the shoulder-joint was performed by Baron Larrey. Three of the nerves of the plexus terminated in this tumour, and the closed extremities of the axillary artery and vein were also connected with it. The termination of the fibres of the nerves in the interior of the tumour is seen in Fig. 6.—Cruveilhier, liv. vi., pl. 5.

FIG. 7.—A portion of the median nerve in the fore-arm, removed from a stump.

FIGS. 8, 9.—The sciatic nerves of stumps. In addition to the tumours at the extremities of the nerves, these figures exhibit the relaxed appearance to which I have alluded at p. 25.

FIG. 10.—The sciatic nerve of a stump. The tumour at its extremity has been divided longitudinally, and the section exhibits the nervous fibres separated from each other, but running through the entire length of the tumour.

FIG. 11.—Traumatic neuromatous tumour of the median nerve. Case of Catherine Mulvany, detailed at p. 31.

PLATE XV.

Fig. 2.

Fig. 1.

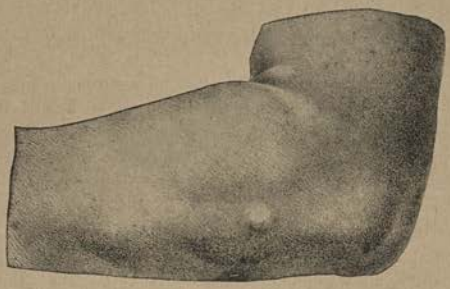

Fig. 3.

Fig. 7.

Fig. 8.

Fig. 4.

Fig. 10.

Fig. 13.

Fig. 11.

Fig. 9.

Fig. 5.

Fig. 6.

Fig. 14.

Fig. 12.

PLATE XV.

FIG. 1.—The cast from which this drawing has been executed was laid before the Pathological Society of Dublin, by Mr. Adams in 1846. It represents the disease generally known by the name of the "Painful subcutaneous Tubercle." The patient was a female, aged 30, and the tumour, which was not larger than a barley-corn, had existed for thirteen years. It was, when she first noticed it, moveable beneath the skin, very hard, but not painful. She stated, however, that about three months previous to her application at the Richmond Hospital (October 2, 1845), she was attacked with pains like those of neuralgia, darting from the situation of the tumour downwards to the hand, and upwards to the shoulder. She said that, in her suffering and impatience, she often prayed, mentally, that some one would amputate her arm; that every night, on going to bed, she was visited with a paroxysm of acute pain in the tumour, which continued for an hour; and she remarked that the paroxysm was worse during frosty or wet weather. Upon the day of her application at the hospital the tumour was removed, together with the portion of integument which covered and adhered to it. The patient was permanently relieved by the operation from her dreadful suffering. The tumour, which was firm and elastic, exhibited, when cut into, a whitish, semi-transparent structure, like fibro-cartilage. There entered into its composition a large quantity of areolar tissue, but no nervous fibre could be discovered connected with it, and the microscope failed to discover anything like nervous structure in its interior.

This disease is so well known to every surgeon, and has been described by so many writers, that I have thought it unnecessary to devote any portion of this memoir to its special consideration. I may, however, remark that, although pathologists have hitherto failed to discover anything like nervous structure in these tumours, I still incline to the opinion that they are connected with the minute filaments and ultimate ramifications of the nerves. Upon any other supposition it is, I conceive, impossible to offer a rational explanation to account for the dreadful severity of the sufferings which they induce.

FIG. 2.—The left semilunar ganglion greatly enlarged.—See case of George Ambruester, related at p. 20.

FIG. 3.—The right semilunar ganglion in the same case.

FIG. 4.—Hypertrophy of the cervical ganglia of the sympathetic nerve.—See p. 29.

FIG. 5 represents the inferior, and Fig. 6 the superior cervical ganglion, in the case of Erasmus Saulich, detailed at p. 20.

FIGS. 7, 8, 9.—These figures represent the tumours upon the extremities of the nerves in the case of John Byrne, recorded at p. 36.

FIG. 10.—A magnified view of the nerve fibres in the interior of a tumour which formed upon the extremity of the nerve of a stump. The tumour was not painful.

FIG. 11.—This figure exhibits the appearance which a portion of the neuroma of the Gasserian ganglion, described at p. 31, presented, when examined by the aid of the microscope. The structure is entirely cellular.

FIG. 12 exhibits the cellular structure of a portion of an idiopathic neuroma.—See p. 25.

FIG. 13 represents the Pacinian corpuscles connected with the digital branches of the median nerve. They are, in this instance, of unusual size, many of them being twice as large as natural. The name of Pacinian corpuscles has been assigned to them by Henle and Kolliker,* from their discoverer, Filippo Pacini.† The exceedingly beautiful preparation, however, of these remarkable bodies, represented in the Plate, was made and placed in the Museum of the Royal College of Surgeons in Ireland, by the late Dr. Shekleton, who died in 1824, six years previous to their discovery by Pacini, who first noticed them in 1830, and published his description of them in 1840. For an account of the structure of these singular bodies, see Todd and Bowman's Physiology, p. 395.

FIG. 14.—Atrophy of the right optic nerve and of the left optic tract, in a case where the right eye had been destroyed by small-pox many years previous to death.

* Ueber die Pacinischen Körperchen an den Nerven des Menschen und der Säugethiere; Zurich, 1844.

† Nuovi Organi scoperti nel corpo umano dal Dott. Filippo Pacini; Pistoja, 1840.

AN

ATLAS OF ILLUSTRATIONS

OF

PATHOLOGY

COMPILED (CHIEFLY FROM ORIGINAL SOURCES)

FOR

THE NEW SYDENHAM SOCIETY.

FASCICULUS XII.

INFECTIVE DISEASE OF THE LYMPHATIC SYSTEM:

LYMPH-ADENOMA, OR HODGKIN'S MALADY.

(PLATES LXV. TO LXVIII.)

LONDON:

THE NEW SYDENHAM SOCIETY.

AGENT—H. K. LEWIS, 136, GOWER STREET, W.C.

1898.

INFECTIVE DISEASE OF THE LYMPHATIC SYSTEM.

THE four Plates which constitute the present Fasciculus all illustrate the same Case. They are copied from drawings made by Sir Robert Carswell in Paris, and are unique in the completeness with which they exhibit the pathological appearances which they concern. In English practice opportunities for such extensive post-mortem dissections seldom or never occur. It has therefore seemed desirable that they should be reproduced in this Atlas, more especially as they have never before been published. The Society is indebted to the courtesy of the Council of University College for permission to publish them, and for the loan of the originals from the College Museum.

The Plates illustrate that form of the disease which approaches most nearly to malignancy. The name lympho-sarcoma would possibly be quite as appropriate as lymph-adenoma. The large size of the mass developed in connection with the liver, its apparent softness and hæmorrhagic tendency, are features which suggest a rapidly growing form of "cancer." As such it was, indeed, regarded by the pathologists by whom the post-mortem was made. It will be seen, however, that the condition of the enlarged glands in the neck and other parts does not imply such a diagnosis. These glands remain loose from each other, are firm in texture, not very large, and indeed in all features resemble those of lymph-adenoma. The almost universal implication of the glandular system is also in keeping with the latter malady. On this point, however, it will be sufficient to say that Dr. Hodgkin himself had seen the portraits in the portfolio of his friend Dr. Carswell, and that he at once claimed them as excellent illustrations of the form of gland-disease about which he was then writing. The case is recorded in Hodgkin's paper in the 'Transactions' of the Royal Medical and Chirurgical Society, and from it the following particulars are quoted.

EXTRACT FROM DR. HODGKIN'S PAPER.

"Whilst examining the unrivalled collection of pathological drawings made by my friend Dr. Carswell, I was struck with one representing a greatly enlarged spleen, loaded with large tubercles of a rounded figure and light colour. I immediately recognized it as a fine example of the affection I have been describing, and my suspicions were presently confirmed by the Doctor's showing me another fine drawing of the greatly enlarged glands of the neck, axillæ, and groins of the same subject.

"The Doctor has favoured me with a copy of the case, and allowed me to place the drawings themselves before you."

'CANCER CEREBRIFORMIS OF THE LYMPHATIC GLANDS, AND OF THE SPLEEN.

'The delineations of this very remakable case were taken from a man who died in the Hôpital St. Louis, at Paris, in the month of April. Mons. Lugol, one of the physicians of the hospital, and under whose care the patient was, has promised to give me the particulars of this case. I was told, however, that the patient, who was between thirty and forty years of age, stout made, and not lean, had been affected with swelling of the glands under the jaws, along both sides of the neck, in the axillæ and groins, for between three and four months, from

which he had suffered but little inconvenience, to which he had paid but little attention, and had employed no remedies. It was only a short time before he applied to be taken into the hospital that he felt a difficulty in swallowing, which rapidly increased, and for the last two or three days was such as to prevent him from taking any kind of food whatever. As his appetite had never been affected by the disease, he was, when he came to the St. Louis Hospital, in a state of great suffering, not only from want of food and from debility, but from the idea that he was rendered incapable of satisfying the cravings of hunger, together with the prospect of inevitable death.

'He lived rather more than two days.

'*Inspection of the Body.*—On each side of the neck were large groups of glands extending from the angle of the jaw down to the clavicle, where they were joined to another group coming up from the axillæ and passing under the clavicle. The submaxillary and sublingual glands were greatly enlarged, and, united with the other lymphatic glands, formed an almost continuous chain stretching along the border of the jaw, and uniting under the chin. These glands were, of various sizes—some of them were not larger than a pea, while others were as large as a hen's egg; they were round, oval, or of an irregular form, particularly where they were united by a common capsule. A great many of them presented the colour which distinguishes them in the healthy state; others were of a yellowish tinge, with more or less redness and vascularity; whilst a few were of a deep red colour and highly vascular. The greater number of them, when pressed between the fingers, felt pretty firm and somewhat elastic; those that were red and vascular were softer. All of them were enclosed in a thin but firm capsule, which contained a substance of the colour and consistence of brain, and in which were distributed a considerable number of blood-vessels. In the softest the vascularity was such as to give to the cerebriform matter an appearance resembling a mixture of equal parts of brain and blood. A similar state of the glands was observed in both groins. The greater number of them were as large as pigeons' eggs, and could be followed passing upwards under Poupart's ligament, surrounding the great blood-vessels, and terminating in the diseased lymphatic and mesenteric glands. The diseased appearances observed in the glands of the groin are represented in Pl. LXVI.; those of the neck and axillæ, No. 4, a. In Pl. LXV. is seen the appearance of the substance of which the glands were formed; in one of them the vascularity of this substance is seen to be very great, whilst in the other the vessels are few in number, long, and slender. The quantity of cerebriform matter is also seen to differ considerably in each. Besides, in the lower figure the lobulated structure which it presents is pretty well marked. In Pl. LXVI. Figs. IV., V. two of the glands are represented after having been injected. In Fig. IV. a large vein is seen coming out from it, and arising from a great number of minute vessels, which apparently are situated near the surface of the gland. In Fig. V. the corresponding artery is shown, dividing and subdividing into an immense number of extremely fine branches, which are distributed throughout the substance of the gland. Pl. LXVIII. Fig. II. represents an enormous tumour formed by the lymphatic glands situated under the liver, duodenum, pancreas, and great blood-vessels of these parts. It was as large as an adult's head, projecting forwards on a level with the convex surface of the liver, and carried before it the duodenum, pancreas, and gall-ducts, which passed over its anterior surface. Fig. I. represents a section of this tumour, which is seen to be formed of a great number of glands, some of which are as large as a small orange. Like those of the neck and axillæ, they were composed of cerebriform matter, possessing a greater or less degree of vascularity. In the centre of the tumour considerable hæmorrhage had taken place, the centre of the hæmorrhagic effusion was occupied by coagulated blood, and the *circumference* by layers of fibrine. The vena cava and aorta passed through the tumour, and the former was nearly perforated by one of the diseased glands.

'The same pathological conditions were observed in the glands situated in the posterior fauces. The glands situated around the root of the tongue were so much enlarged as to shut up completely by their projecting upwards, backwards, and forwards the posterior nares and superior aperture of the œsophagus. I could not ascertain the precise state of the epiglottis, but it must to a certain extent at least have been free, as it did not appear that inspiration had been much impeded. The amygdalæ, formed entirely of cerebriform matter, presented a pale yellow colour tinged here and there with red specks, produced apparently from the rupture of

minute blood-vessels. They have also lost that characteristic appearance from which they derive their name, having become almost perfectly smooth from the accumulation of the cerebriform matter and the distension of their envelope.

'The spleen was the only organ apart from the lymphatic glands which presented a similar or indeed any disease in this remarkable case. The external surface of this organ is shown in Pl. LXVII. Fig. II. Besides great increase of its bulk, it presented externally a great number of irregular elevations surrounded by redness and vascularity. When divided longitudinally (Fig. I.) it appeared to be formed entirely of cerebriform matter and fine blood-vessels, hardly any trace of its natural structure being observable. It presented a lobulated structure, the lobules varying from the size of a small pea to that of a large gooseberry; these being again divided and subdivided into smaller ones—the boundaries of the lobules and the intersections of the latter were the parts in which vascularity was greatest —it did appear indeed as if the lobulated structure had been the result of a vascular network so disposed as to enclose and separate more or less completely portions of different sizes of the cerebriform matter. It depended, however, in all likelihood, on the structure of the spleen, in the cells of which, or in the blood which they contain, the cerebriform matter was deposited or formed; whilst the blood-vessels which surrounded the lobules and ramified in their intersections arose from those which belong to the splenic cells.

'The body having been removed by inadvertence before I had time to examine the chest, I did not ascertain the state of the bronchial glands; but I was informed by one of the house physicians that they were not diseased.'

"Although the Doctor (Carswell) has employed the term 'cerebriform matter,' which conveys a ready idea of the texture of the diseased glands, he will excuse my differing from him so far as to regard the affection in this case as distinct from cerebriform cancer. I feel the less difficulty in doing so in the recollection that one of the cases of which I had given the details was, like Dr. Carswell's, considered as fungoid until a special and close inspection had detected the difference."

The above is a verbatim extract from Dr. Hodgkin's paper, with the exception that the references in the text have been altered so as to correspond with the present Plates. The description given of the post-mortem appearances are Sir R. Carswell's. In the concluding paragraph Hodgkin expresses his dissent from his friend's nomenclature, and claims the case as one of those which he had just described as a malady beginning in the lymphatic system, spreading through it, and wholly restricted to it and its companion organ the spleen. It may be regretted that no microscopic examination is recorded, but enough has been done since these drawings were taken to enable us to feel tolerably certain as to what would have been observed. In all regions, excepting the large mass under the liver, the glands retain the well-known features of "lymph-adenoma," or "Hodgkin's malady."

PLATE LXV.

The neck and armpit dissected, showing enlarged glands grouped in bunches of very various sizes, and with but little tendency to become adherent together. The infection has evidently travelled with the vessels under the clavicle to the armpit.

PLATE LXVI.

The iliac fossa and upper part of thigh dissected, showing enlarged glands surrounding the iliac vessels, and passing with them under Poupart's ligament. A large mass of still isolated glands is seen in Scarpa's triangle.

Figs. II., III., IV., and V. show the appearances presented by single glands, more especially the vascularity of their capsules, &c. (in Fig. II.). In Figs. IV. and V. the blood-vessels have been injected. Fig. II. shows the appearance of a gland in section.

PLATE LXVII.

Fig. I. shows the spleen in section. Fig. II. shows the size and condition of the enlarged spleen.

PLATE LXVIII.

Fig. I. A section through the liver and the large mass of glands beneath it.

Fig. II. Front view of the liver and gland-mass.

In these two Figures it will be seen that the liver itself is not involved, and that the morbid growth is still restricted to lymphatic glands. It will be noticed also that there is no tendency to infiltrate the structures which are surrounded by the diseased glands.

West, Newman chromo

Fig I.

Fig. II.

Fig III.

Fig IV

Fig V

Fig. I.

Fig. II.

West, Newman chromo.

00109544

Digitized with financial assistance from the
Observer Research Foundation
on 25 April, 2019